

Biologically active compounds from cyanobacteria extracts: *in vivo* and *in vitro* aspects

Luciana R. Carvalho,^{*1} Adriana Costa-Neves,² Geanne A. A. Conserva,¹ Rafael L. Brunetti,³ Guilherme S. Hentschke,¹ Camila F. S. Malone,¹ Luce M. B. Torres,¹ Célia L. Sant'Anna,¹ Marisa Rangel³

¹Instituto de Botânica, Núcleo de Pesquisa em Ficologia, SP, Brazil,

²Instituto Butantan, Laboratório de Biologia Celular, Brazil,

³Instituto Butantan, Laboratório de Imunopatologia, Brazil.

Abstract: An investigation was directed towards the antiacetylcholinesterase activity of the acid aqueous and methanolic extracts of five cyanobacterial taxa, which encompasses an enzymatic inhibition assay and the evaluation of the physiological responses of mice to cyanobacterial extracts along with toxicological observations. The strains *Calothrix* sp. CCIBt 3320, *Tolypothrix* sp. CCIBt 3321, *Phormidium* cf. *amoenum* CCIBt 3412, *Phormidium* sp. CCIBt 3265, and *Geitlerinema splendidum* CCIBt 3223 were from the São Paulo Botanical Institute Cyanobacterial Culture Collection and all of them showed inhibitory effect on acetylcholinesterase activity (*in vitro*) and caused systemic effects similar to those described for anticholinesterase drugs (*in vivo*). With the exception of *G. splendidum* and *Tolypothrix* sp. strains, all extracts produced reversible antiacetylcholinesterase effects in mice. Complementary histopathological studies were carried out on tissues from animals administered with *Phormidium* sp. and *P. cf. amoenum*.

Introduction


Cyanobacteria are common members of microscopic populations of freshwater lakes and reservoirs worldwide. They are capable of forming blooms and producing potent toxins, which can present serious human and animal health problems (Van Apeldoorn et al., 2007; Pearson et al., 2010). Besides cyanotoxins, these organisms have the ability to synthesize considerable amounts of structurally distinct compounds that can be used as food and feed, fuel, dyes, sunscreen agents, as well as therapeutic drugs (Abed et al., 2009).

In scientific literature there is an appreciable amount of studies on the potential use of cyanobacterial compounds as medication, along with cyanotoxin poisoning cases in humans by ingesting contaminated water and food or by accidental administration during dialysis treatment. Some of these compounds are already being employed in anal fissures and common fistula treatment, as well as anti-HIV drugs (Botos & Swlodawer, 2003; Garrido et al., 2007), however, one of the most interesting set of activities displayed by cyanobacterial metabolites is their inhibitory action on certain enzymes

(Grainger et al., 1989; Chen et al., 2007; Zelik et al., 2009). The cyanotoxins microcystins and anatoxin-a(S) have anti-phosphatase and anticholinesterase effects, respectively (Van Apeldoorn et al., 2007). However, there are other antienzymatic activities described for compounds synthesized by these organisms (Radau, 2000; Sisay et al., 2009; Matthew et al., 2010).

Compounds bearing antiacetylcholinesterase action play a very important role in the search for potential drug candidates against Alzheimer disease (AD); this neurodegenerative condition is associated with brain neurotransmitter deficits and its symptomatic treatment is the restoration of cholinergic function by inhibiting acetylcholinesterase (Francis et al., 1999; Trevisan et al., 2003).

Therefore, the effect of an antiacetylcholinesterase drug is a long-lasting and more effective stimulation of the cholinergic system, which results in responses from autonomic effector organs, autonomic ganglia, as well as skeletal muscles, and from cholinergic receptors in the Central Nervous System. According to its molecular structure, each antiacetylcholinesterase compound



Article

Received 26 Nov 2012
Accepted 16 Apr 2013
Available online 14 May 2013

Keywords:

acetylcholinesterase activity
Calothrix sp.
Geitlerinema splendidum
Phormidium cf. *amoenum*
Phormidium sp.
Tolypothrix sp.

ISSN 0102-695X
DOI: 10.1590/S0102-695X2013005000037

has its own chemical characteristics that determine its reactivity. As a consequence, the binding between the antiacetylcholinesterase compound and the enzyme shall be either a short, medium (reversible), or long-term (irreversible) association, being considered as potential therapeutic drugs only the ones which form reversible bonds (Nair et al., 2004).

There is an ongoing search for new bioactive compounds in cyanobacterial extracts from the São Paulo Institute of Botany Cyanobacterial Culture Collection strains, where some caused similar physiological responses in the mouse bioassays, which relate to responses demonstrated by antiacetylcholinesterase compounds. Such extracts were evaluated for AChE inhibition and short-term toxicity to mammals; a first step for further studies.

Materials and Methods

The organisms and extract preparation

Five different cyanobacterial strains were studied: *Calothrix* sp. CCIBt 3320, *Tolypothrix* sp. CCIBt 3321, and *Phormidium* cf. *amoenum* CCIBt 3412, isolated from soil samples in the Atlantic Rainforest, State Park of the Serra do Mar, SP (23°24' S and 45°11'06'' W); *Phormidium* sp. CCIBt 3265, isolated

from an alkaline lake from the Pantanal, MS (18°57'42'' and 56°37'26''); and *Geitlerinema splendidum* CCIBt 3223, from Guarapiranga Reservoir waters, SP (23°43' S and 46°32') (Figure 1). The strains were cultured under the following conditions: ASM-1 medium, temperature 23±1 °C, and continuous irradiance 40-50 Mmol/m² s⁻¹ (Azevedo & Sant'Anna, 2003).

For each strain, the biomass obtained was freeze-dried, divided into two halves: one of them subjected to ultrasound-assisted extraction (5x, 30 s, 100 W) with 0.1 M aqueous acetic acid (AAE) and the other, with methanol 100% (ME). After centrifugation (1,750 x g, 50 min), the aqueous supernatants were lyophilized and the methanolic ones were dried via speed-vac centrifugation. The dried samples were stored in hermetically sealed vials, at -20 °C, until analysis (Conserva et al., 2011).

In vitro assay: qualitative evaluation of acetylcholinesterase inhibitory activity

This *in vitro* assay was accomplished following Rhee et al. (2001) TLC autographic protocol: aliquots of 100 µg of each dried extract were dissolved and spotted on a pre-coated plate (Silica gel 60 F₂₅₄, 10x 10 cm, layer thickness 0.2 mm, E. Merck, Germany). The chromatogram was developed with mobile phase CHCl₃: MeOH:H₂O (64:36:8, v/v/v), dried and sprayed with the enzyme




Figure 1. a. *G. splendidum* CCIBt 3223; b. *Calothrix* sp. CCIBt 3320; c. *Tolypothrix* sp. CCIBt 3321; d. *Phormidium* sp. CCIBt 3265; e. CCIBt 3412 *Phormidium* cf. *amoenum*.

solution (6,66 U mL), thoroughly dried and incubated in a humid atmosphere, at 37 °C, for 20 min. Subsequently, the plate was sprayed with a 0.25% 1-naphthylacetate in ethanol plus 0.25% aqueous Fast Blue B salt solution. The spots corresponding to potential acetylcholinesterase inhibitors were unambiguously identified as clear zones against a purple background. The Electric eel AChE type V (Product no C 2888, 1000 U) was purchased from Sigma as well all analytical grade reagents.

The retention factors (R_f) of the compounds that positively reacted against the enzyme were also calculated.

In vivo assay: acute toxicity study (i.p.)

Toxicological assays were performed in triplicate on each crude extract by using mice of the same sex, which simultaneously allowed the achievement of reliable data and the use of a minimum number of animals (Rangel et al., 2012). The procedures were carried out according to the WHO guidelines (Harada et al., 1999) and a single dose of 1,000 mg dried cells/kg body weight was used, which enabled extracts to be ranked as low toxicity, if animal death was caused (Lawton et al., 1994). Ethical clearance was obtained from the Ethical Committee for Animal Research of Butantan Institute - Protocol No. 385/07.

Male Swiss mice (19-21 g, 50 days) were intraperitoneally (*i.p.*) treated with dried aqueous acetic acid or methanolic cyanobacterial extracts dissolved in Milli-Q water; the control animals received only the vehicle (Milli-Q water), according to WHO protocol. Any changes in the skin, fur, eyes and respiratory, autonomic and central nervous system, somamotor activity and behavior pattern were observed, and signs of tremors, convulsions, salivation, diarrhea and lethargy and coma were noted as well. The animals were observed for 8

days following administration because, after an extended observation time, notable findings on tissue lesions can be observed (Rangel et al., 2012). Surviving animals were euthanized with CO₂, necropsy findings were recorded and tissue samples were taken.

Results and Discussion

Extract preparation and qualitative evaluation of AChE inhibitory activity

The freeze-dried cyanobacterial biomass and the dried extract weights are displayed in Table 1, along with the qualitative results of the antiacetylcholinesterase bioautographic assay (Figure 2) and the R_f (retention factors) of spots corresponding to antiacetylcholinesterase compounds.

All extracts were previously analyzed for the presence of microcystins (Conserva et al., 2011).

In vivo assays: acute toxicity study (i.p.)

In acute toxicity testing, among the treated animals, the ones that received the AAE *G. splendidum* CCIBt 3223 and only one administered with AAE *Tolypothrix* CCIBt 3321 died, while all the others showed mild and transient physiological effects, which can be associated with the intrinsic side effects induced by anti-AChE drugs (McGleenon et al., 1999; Xavier et al., 2007; 2008).

The physiological responses, time to death, and gross changes seen post-mortem are compiled in Chart 1.

Similar responses were observed in animals treated with extracts of all studied strains, which are also very similar to those observed in the mouse studies on anti-AChE drugs (McGleenon et al., 1999; Xavier, 2008) and such responses are related to muscarinic and nicotinic

Table 1. Biomass and extract dry weights, qualitative anticholinesterase assay results and Rf of the AntiAChE compounds.

Extract strains	Freeze-dried biomasses (g)	Dried extracts (g)	AntiAChE activity	Rf of antiAChE compounds
AAE <i>G. splendidum</i> CCIBt 3223	0.7847	0.3941	+	0.28; 0.66
ME <i>G. splendidum</i> CCIBt 3223	0.6675	0.2308	+	0.26; 0.58
AAE <i>Calotrix</i> sp. CCIBt 3320	0.4937	0.1888	+	0.64
EM <i>Calotrix</i> sp. CCIBt 3320	0.2242	0.1135	+	0.37
AAE <i>Tolypothrix</i> sp. CCIBt 3321	0.4050	0.1868	+	0.62
EM <i>Tolypothrix</i> sp. CCIBt 3321	0.3813	0.1144	+	0.38
AAE <i>Phormidium</i> sp. CCIBt 3265	0.4871	0.1727	+	0.66
EM <i>Phormidium</i> sp. CCIBt 3265	0.6398	0.1875	+	0.45; 0.59; 0.66; 0.73
AAE <i>Phormidium</i> cf. <i>amoenum</i> CCIBt 3412	0.5052	0.1485	+	0.66
EM <i>Phormidium</i> cf. <i>amoenum</i> CCIBt 3412	0.8941	0.2129	+	0.55; 0.59; 0.58

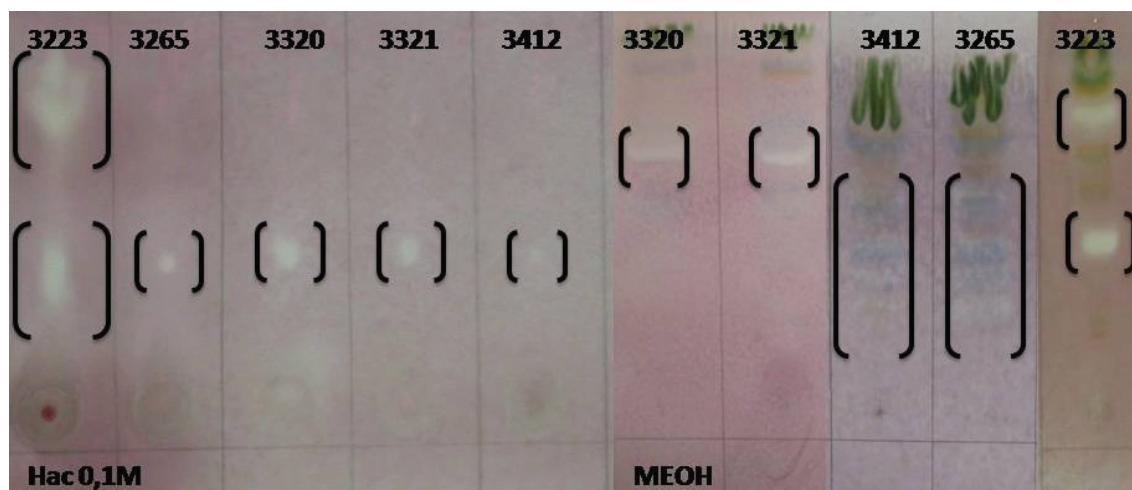


Figure 2. AE CCIBt 3223, 3265, 3320 and 3421 TLC qualitative antiacetylcholinesterase assay (a, b, c, d and e); ME CCIBt 3223, 3265, 3320 and 3421 TLC qualitative antiacetylcholinesterase assay (f, g, h, i, and j). Brackets indicate the anticholinesterase compounds.

Chat 1. Physiological responses, observation time or time to death, and macroscopic lesions observed *post-mortem*.

Strains/extract	Physiological responses	Observation time	Main necropsy findings
AAE- <i>G. splendidum</i> CCIBt 3223	Dyspnea, loss of reflexes, and prostration	Deaths two hours after extract administration	With no apparent macroscopic changes
ME- <i>G. splendidum</i> CCIBt 3223	Abdominal contractions, loss of reflexes, and agitation	Euthanasia seven days after administration	Hemorrhagic lungs
AAE- <i>Calotrix</i> sp. CCIBt 3320	Piloerection, dyspnea, abdominal contractions, eyebrow ptosis, loss of reflexes and transitory paralysis	Euthanasia seven days after administration	White spots on the liver; liver adhered to the intestines.
ME- <i>Calotrix</i> sp. CCIBt 3320	Loss of reflexes, transitory paralysis, intense abdominal contractions, dyspnea and eyebrow ptosis	Euthanasia seven days after administration	Black spots located between the liver lobes (N=1)
AAE- <i>Tolypothrix</i> sp. CCIBt 3321	Transitory paralysis, abdominal contractions, piloerection, dyspnea, and diarrhea	Death four days after administration (N=1); euthanasia seven days after administration (N=2)	Diminished liver size, fusion of lobes and white spots on the liver. (N=1)
ME- <i>Tolypothrix</i> sp. CCIBt 3321	Agitation, itch, scrotal edema, and abdominal contractions.	Euthanasia seven days after administration	With no apparent macroscopic changes
AAE- <i>Phormidium</i> sp. CCIBt 3265	Dyspnea, abdominal contractions, and loss of reflexes.	Euthanasia seven days after administration	Hemorrhagic lungs, white spots on the liver; abnormalities in gallbladder morphology
ME- <i>Phormidium</i> sp. CCIBt 3265	Abdominal contractions, piloerection, prostration, eyebrow ptosis transitory paralysis, and dyspnea	Euthanasia seven days after administration	Hemorrhagic lungs (N=2), and degraded lungs (N=1); green spot on the stomach
AAE- <i>Phormidium</i> cf. <i>amoenum</i> CCIBt 3412	Prostration, piloerection abdominal contractions, and loss of reflexes	Euthanasia seven days after administration	Hemorrhagic lungs (N=1); fusion of liver lobes; increased peritoneal thickness, with hemorrhagic area (N=1)
ME- <i>Phormidium</i> cf. <i>amoenum</i> CCIBt 3412	Muscle spasms, abdominal contractions, eyebrow ptosis, dyspnea, and loss of reflexes	Euthanasia 7 days after administration	Hemorrhagic lungs; diminished liver size and presence of black spots; bubble on the left kidney (N=2); green spot on the stomach

actions as well as on the central nervous system.

Among the muscarinic manifestations are dyspnea, abdominal cramps and diarrhea; among those resulting from overstimulation of the nicotinic receptors are muscle cramps, motor weakness, paralysis, tachycardia, and piloerection, and among those due to Central Nervous System are tremors, ataxia, and walking difficulty. The extent, the progression and the persistence of clinical observations depend on administration route, bioactive compound structure, and exposure magnitude (Andrade Filho & Romano, 2001). The compound structure defines the bond nature to the enzyme, which can be reversible, or irreversible, being the intermediate compound short, medium (reversible), or long acting (irreversible), respectively. The long acting intermediates are considered to be toxic (Nair et al., 2004).

The clinical signs complete regression ranged between two to three hours in three out of five groups of mice tested; that is, AAE *G. splendidum* CCIBt 3223 caused acute intoxication and only one animal that received AAE *Tolypothrix* sp. CCIBt 3321 died after four days from administration.

The results also showed that the AAE of the strain *G. splendidum* CCIBt 3223 possessed a lethal anti-AChE activity, most likely by the presence of long acting inhibitory substances to the enzyme (Nair et al., 2004), but there is insufficient information on the AE *Tolypothrix* sp. effects.

Anatoxin-a(S), anticholinesterase with potent lethal effect, is the only organophosphate produced by Cyanobacteria (Van Apeldoorn et al., 2007); meanwhile, great part of the compounds considered highly toxic are synthetic, such as carbamate Aldicarb (Cazenave et al., 2005) and of the organophosphate Parathion (Bardin et al., 1994).

Our results of the *in vitro* anti-AChE assay and clinical observations indicate that the methanolic and aqueous extracts of *Calothrix* sp. CCIBt 3320, *Tolypothrix* sp. CCIBt 3321, *Phormidium* sp. CCIBt 3265, *Phormidium* cf. *amoenum* CCIBt 3412, and *G. splendidum* CCIBt 3223 contain compounds which inhibit the enzyme acetylcholinesterase in a transient or reversible way.

Compounds which act as transient anticholinesterase drugs should be evaluated as potential therapeutic drugs because the current cholinesterase inhibitors prescribed for the treatment of AD are tacrine, donepezil, rivastigmine, galantamine, and serine which present several adverse side-effects such as hepatotoxicity, gastrointestinal disturbance and depression (Yoon et al., 2008). Due to these limiting factors for their use, new anticholinesterase drugs will be well received.

Aside from allowing a detailed observation of the biological responses to active compounds, an important outcome of the mouse bioassay is to determine the nature and extent of the adverse effects to a single

dose or an overdose of a toxic or a therapeutic compound (Xavier, 2008). In our studies, with the exception of the acetic acid extract from *G. splendidum* CCIBt 3223 and *Tolypothrix* sp. CCIBt 3321, all other extracts are not lethal and caused physiological responses associated with the pharmacological actions of antiacetylcholinesterase compounds.

Complementary histopathological studies were carried out on liver, kidney, and lung tissues of animals intoxicated with extracts of *Phormidium* sp. CCIBt 3265 and *P. cf. amoenum* CCIBt 3412.

Previous studies have described and illustrated the microscopic lesions caused by CCIBt strain 3223 (Rangel et al., 2012). The mice lungs were severely affected, presenting hemorrhage foci, edema, alveolar collapse, and hyperplasia, due to an increase in the number of immune system cells (macrophages). Disorganization of the hepatic parenchyma, necrosis, loss of vein endothelium, and presence of giant multinuclear cells and polymorphonuclear cells in the liver were observed. Finally, the kidneys of mice intoxicated with AAE CCIBt 3223 (*G. splendidum*) presented alterations in the convoluted tubules and necrotic areas (Rangel et al., 2012).

Histological sections from control animal are shown in Figure 3. The main alterations observed in the organs of animals tested with AAE CCIBt 3265 were: in the lungs, edema, hemorrhage, and alveolar collapse and in the liver, areas of necrosis and steatosis (Figure 4).

In the animals that received ME CCIBt 3265, necrosis, steatosis, damage in endothelial cells of central lobular veins, enlarged sinusoids, inflammatory infiltrate close to bile duct, and giant multinuclear cells were observed in the liver; in the lungs, hemorrhage and alveolar collapse; and in the kidneys, the interstitial space between tubules was greater than normal and there was increase in light of convoluted tubules (Figure 5).

The microscopic lesions provoked by AAE CCIBt 3412 were shown in the Figure 6: granulomatous foci, hemorrhage, and alveolar collapse were seen in the lungs, large amounts of inflammatory infiltration close or not to bile duct cells were seen in the liver, and enlarged convoluted tubules were seen in the kidneys.

In the only study concerning antiacetylcholinesterase effects on mice, the microscopic lesions observed were: in the lungs, hemorrhage, edema and congestion; in the liver, vacuolar degeneration and in the kidneys, hemorrhage, congestion and tubular degeneration (Xavier, 2008). Comparison between the findings on AAE and ME CCIBt 3265 microscopic lesions showed similarity with the results obtained by Xavier (2008). Other histological findings could be attributed to unknown substances in the extracts.

In conclusion, the present study identifies *G. splendidum* CCIBt 3223 as a producer of a toxin, which administered as a single dose of 1,000 mg dried cells/kg

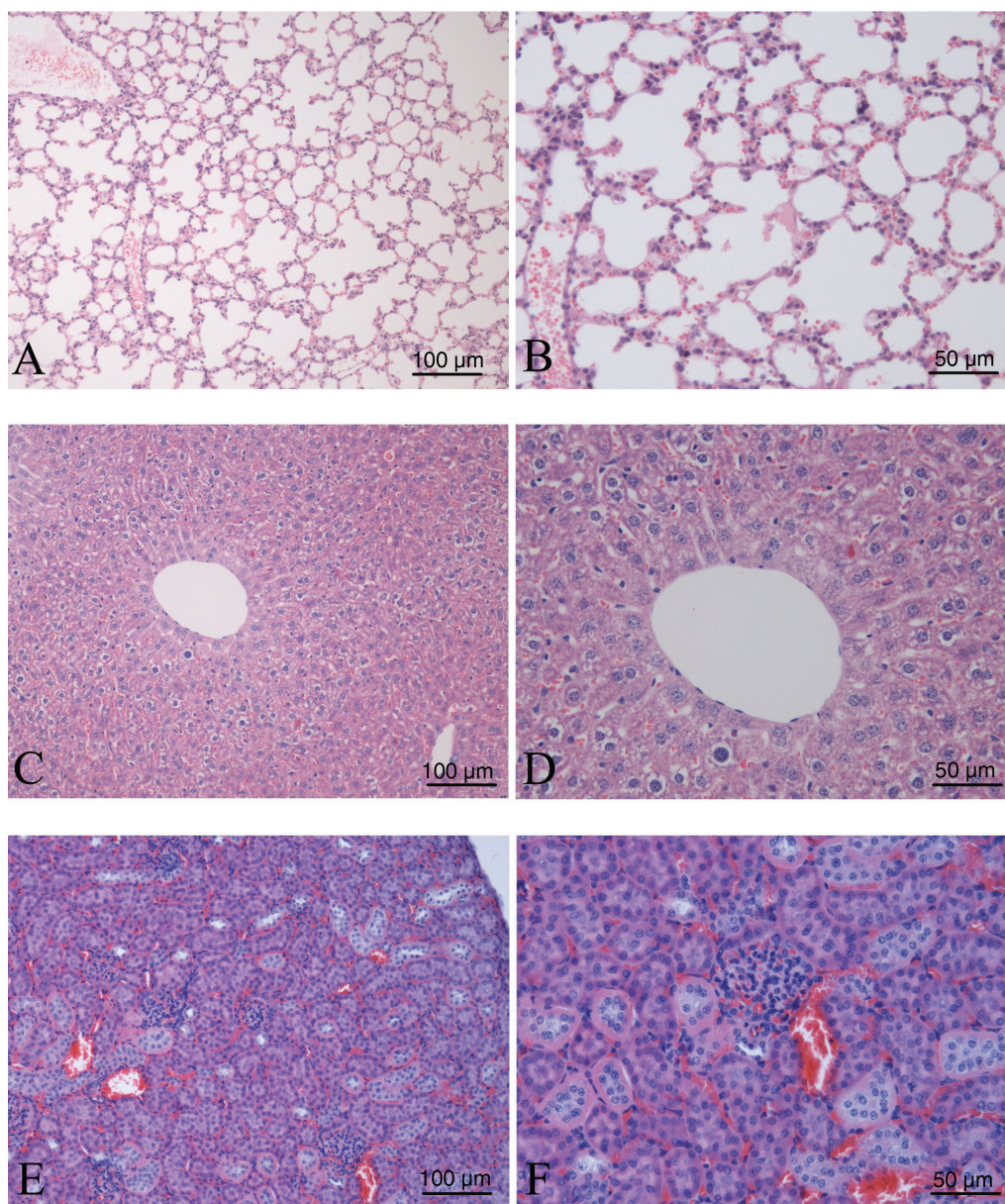


Figure 3. Histological sections from control animals (HE). A and B: Lung (100x, 200x). C and D: Liver (100x, 200x). E and F: Kidney (100x, 200x).

body weight, causes animal death within 2 h and indicates ME- *Tolypothrix* sp. CCIBt 3321 as a candidate for further studies for potential anticholinesterase drugs.

Acknowledgments

The authors thank the Instituto Nacional em Ciência e Tecnologia em Toxinas; Conselho Nacional de Desenvolvimento Científico e Tecnológico; Fundação de Amparo à Pesquisa do Estado de São Paulo.

Author's contributions

LRC designed the study, supervised the laboratory work, contributed to analysis of the data and drafted the paper and wrote the final manuscript; ACN contributed to histological studies and to critical reading of the manuscript; GAAC contributed in running the laboratory work and to chemical and biological studies; RLB contributed to toxicological analysis; GSH and CFMSM contributed to cyanobacterial collection, identification and culture. LMBT contributed to biological analysis and to

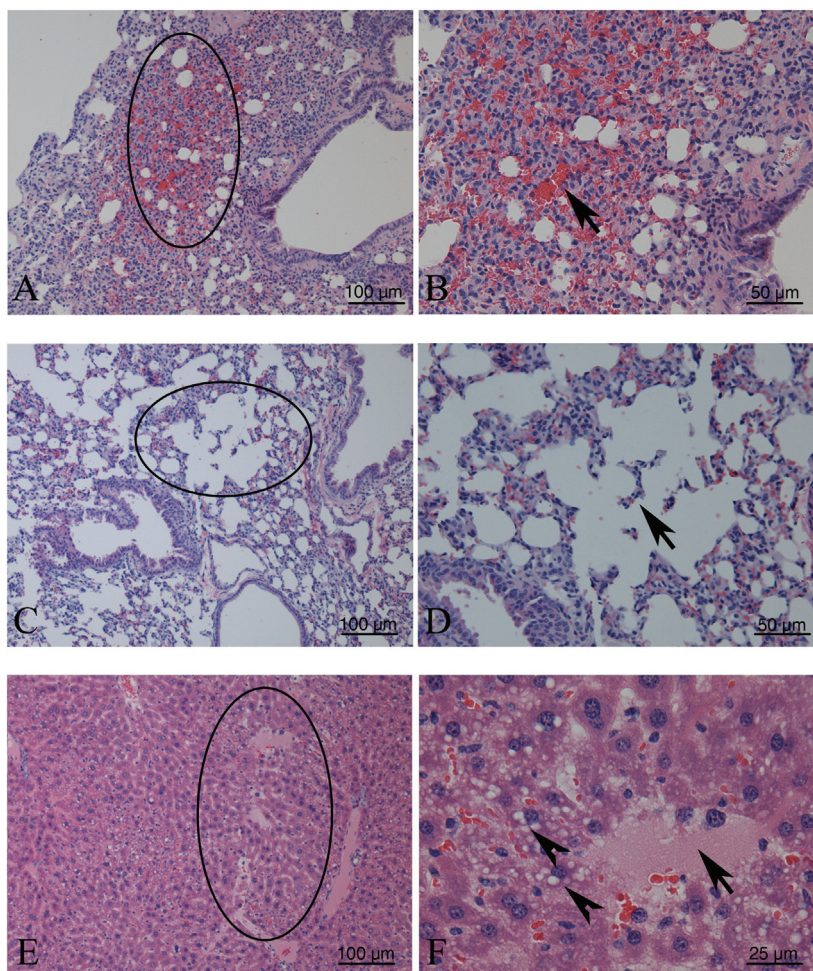


Figure 4. Histological alterations observed in the organs of animals tested with AAE CCIBt 3265 (HE). A, B, C and D: Lung. A: Hemorrhagic area and alveolar collapse (circle) (100x). B: Erythrocytes extravasation (arrow) (200x). C: Edema (circle) (100x). D: Disruption the wall of a pulmonary alveolus (200x). E and F: Liver. A: Areas of necrosis and steatosis (100x). B: Necrotic area (arrow), steatotic cells (arrow heads) (400x).

critical reading of the manuscript; CLS contributed to cyanobacterial identification and to critical reading of the manuscript and MR contributed to toxicological studies and to critical reading of the manuscript. All the authors have read the final manuscript and approve the submission.

References

- Abed RMM, Dobretsov S, Sudesh K 2009. Applications of cyanobacteria in biotechnology. *J Appl Microbiol* 106: 1-12.
- Andrade Filho A, Romano C 2001. Anticolinesterásicos. In: Andrade Filho A, Campolina D, Dias MB (eds.) *Toxicologia na Prática Clínica*. Belo Horizonte: Editora Folium, p 53-60.
- Azevedo MTP, Sant'Anna CL 2003. *Sphaerocavum brasiliense*, a new planktic genus and species of Cyanobacteria from reservoirs of São Paulo State, Brazil. *Algol Stud* 109: 79-92.
- Bardin PG, Van Eeden SF, Moolman JA, Foden AP, Joubert JR 1994. Organophosphate and carbamate poisoning. *Arch Intern Med* 154: 1433-1441.
- Botos I, Swlodawer A 2003. Cyanoviridin-N: a sugar-binding antiviral protein with a new twist. *Cell Mol Life Sci* 60: 277-287.
- Cazenave SOS, Itho SF, Lanaro R, Chasin AAM 2005. Aldicarb: uma possibilidade de análise com finalidade forense. *Rev Bras Toxicol* 18: 105-111.
- Chen S, Zhang X, Li L, Le W 2007. Current experimental therapy for Alzheimer's disease. *Curr Neuropharmacol* 5: 127-134.
- Conserva GAA, Sant'Anna CL, Cambui CCN, Brunetti RL, Rangel M, Torres LMB, Young MCM, Carvalho LR 2011. Prospecção de atividades toxicológicas e farmacológicas em cepas de cianobactérias da Coleção de Culturas do Instituto de Botânica. <http://www.raibt.net.br/cdraibt2011/Busca.html>.
- Francis PT, Palmer AM, Snape M, Wilcock GK 1999. The

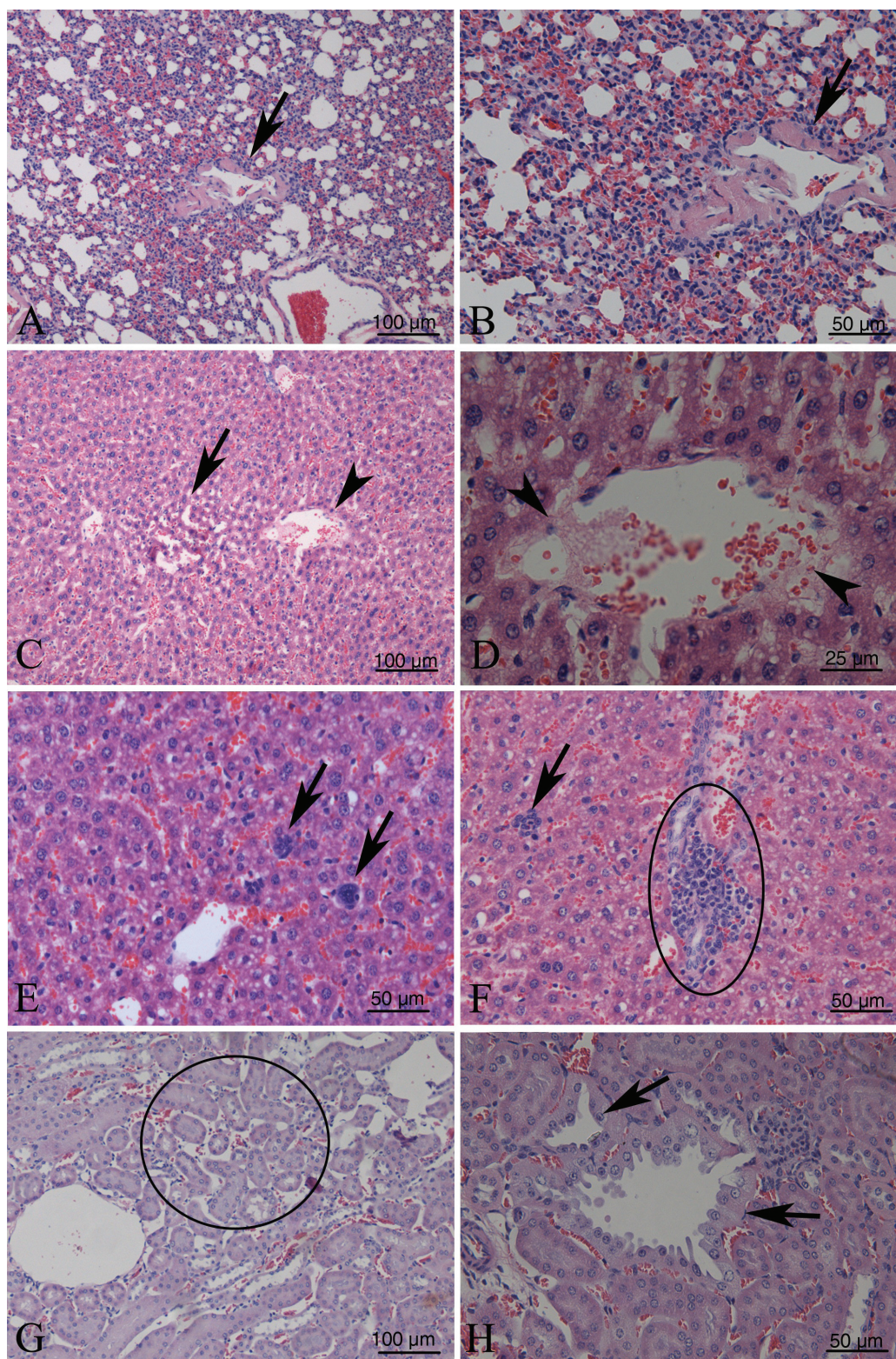


Figure 5. Histological alterations observed in the organs of animals tested with ME CCIBt 3265. A and B: Lungs. Hemorrhage and alveolar collapse. Collapse of an artery. (arrow) (100x, 200x). C, D, E and F: Liver. C and D: Enlarged sinusoids (arrow) and damage in endothelial cells of central lobular veins (arrow head) (100x, 400x), E: Giant multinuclear cells (200x), F: Mononuclear inflammatory infiltrate (arrow) inflammatory infiltrate close to bile duct (circle) (200X). G and H: Kidney, G: Interstitial space between tubules was greater than normal (circle) (100x). H) Increase in light of convoluted tubules (arrow) (200x).

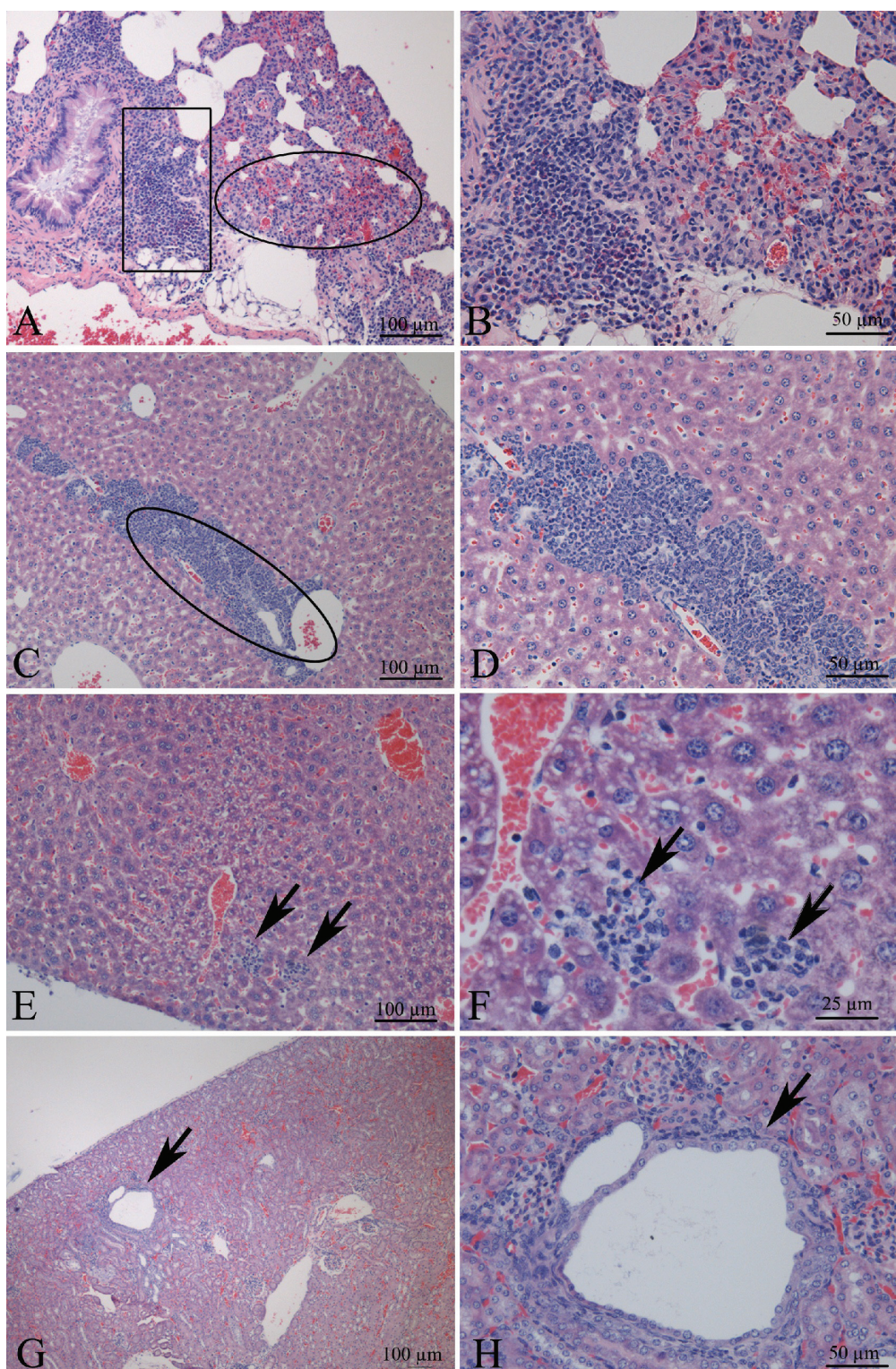


Figure 6. Histological alterations observed in the organs of animals tested with AE CCIBt 3412. A and B: Lungs. Granulomatous foci (rectangle), hemorrhage and alveolar collapse (circle) (100x, 200x), C, D, E and F: Liver. C and D) Large amounts of inflammatory infiltration close to bile duct (100X, 200X). E and F) Mononuclear inflammatory infiltrate (arrows) (100X, 400X). G and H) Kidney. Enlarged convoluted tubules (arrow) (100X, 200X).

- cholinergic hypothesis of Alzheimer disease; a review of progress. *J Neurol Neurosurg Psychiatry* 66: 137-147.
- Garrido R, Lagos N, Lagos M, Rodriguez-Navarro AJ, Garcia C, Truan D, Henriquez A 2007. Treatment of chronic anal fissure by gonyautoxin. *Colorect Dis* 9: 619-624.
- Grainger SL, Peat A, Tiwari DN, Whitton BA. 1989. Phosphomonoesterase activity of the cyanobacterium (blue-green alga) *Calothrix parietina*. *Microbios* 59: 7-17.
- Harada KI, Kondo F, Lawton L 1999. Laboratory analysis of cyanotoxins. In: Chorus I & Bartram J (org.) *Toxic cyanobacteria in water: A guide to their public health consequences, monitoring and management*. New York: E & FN SPON, p 369-405.
- Lawton LA, Beattie KA, Hawser SP, Campbell DL, Codd GA 1994. Evaluation of assay methods for the determination of cyanobacterial hepatotoxicity. In: Codd GA, Jefferies TM, Keevil CW, Potter E (org) *Detection methods for cyanobacterial toxins*. Cambridge: The Royal Society of Chemistry, Special Publication No 149.
- Matthew S, Ratnayake R, Becerro MA, Ritson-Williams R, Paul VJ, Luesch H. 2010 Intramolecular modulation of serino-protease inhibitor activity in a marine cyanobacterium with antifeedant properties. *Mar Drugs* 8: 1803-1816.
- McGleenon BM, Dynan KB, Passmore AP 1999. Acetylcholinesterase inhibitors in Alzheimer's disease. *Br J Clin Pharmacol* 48: 471-480.
- Nair VP, Hunter JM 2004. Anticholinesterases and anticholinergic drugs. *Cont Edu Anaest Crit Care Pain* 4: 164-168.
- Pearson L, Mihali T, Moffitt M, Kellmann R, Neilan B 2010. On the chemistry, toxicology and genetics of the cyanobacterial toxins, microcystin, nodularin, saxitoxin and cylindropemopsin. *Mar Drugs* 8: 1650-1680.
- Radau G 2000. Serino proteases inhibiting cyanopeptides. *Pharmazie* 55: 555-560.
- Rangel M, Brunetti RL, Garcia AN, Cambui CCN, Conserva GAA, Neves AC, Sant'Anna CL, Carvalho LR 2012. Acute effects of three *Geitlerinema* spp.(Cyanobacteria) extracts administered in mice: symptoms and histopathological aspects. *Phytochem Rev* DOI 10.1007/s11101-012-9240-x.
- Rhee K, Meent M, Ingkaninan K, Veerporte R 2001. Screening for acetylcholinesterase inhibitors from Amaryllidaceae using silica gel thin-layer chromatography in combination with bioactivity staining. *J Chromatogr A* 915: 217-223.
- Sisay MT, Hautmann S, Mehner C, Konig GM, Bajorath J, Gustschow M 2009. Inhibition of human leukocyte elastase by brunsvicamides A-C: cyanobacterial cyclic peptides. *J Med Chem* 4: 1425-1429.
- Trevisan MTS, Macedo FVV, Meent MV, Rhee IK, Verpoorte R 2003. Seleção de plantas com atividade anticolinesterásica para tratamento da doença de Alzheimer. *Quim Nova* 26: 301-304.
- Van Apeldoorn ME, Van Egmond HP, Speijers GJA, Bakker GJI 2007. Review - Toxins of cyanobacteria. *Mol Nutr Food Res* 51: 1-60.
- Xavier FG, Righi DA, Spinosa, HS 2007. Toxicologia do praguicida Aldicarb ("chumbinho"): aspectos gerais, clínicos e terapêuticos em cães e gatos. *Cienc Rural* 37: 1206-1211.
- Xavier FG 2008. Intoxicação por Aldicarb ("chumbinho"): I. Estudo das alterações "post-mortem" microscópicas em cães e gatos. II. Avaliação dos efeitos tóxicos agudos em camundongos. São Paulo, 201 p. PhD Thesis, Faculdade de Medicina Veterinária e Zootecnia da Universidade de São Paulo.
- Zelik P, Lukesova A, Voloshko LN, Stys D, Kopecky J. 2009. Screening for acetylcholinesterase inhibitory activity in cyanobacteria of the genus *Nostoc*. *J Enzym Inhib Med Ch* 24: 531-536.
- Yoon NI, Chung HY, Kim HR, Choi JS 2008. Acetyl- and butyrylcholinesterase inhibitory activities and phlorotannins from *Ecklonia stolonifera*. *Fish Sci* 74: 200-207.

***Correspondence**

Luciana Retz de Carvalho
Instituto de Botânica, Núcleo de Pesquisa em Ficologia
Av. Dr. Miguel Stéfano, 3689, Água Funda, 04301-902 São Paulo-SP, Brasil
lretz@ibot.sp.gov.br
Tel. 55 11 5067 6119
Fax: 55 11 5073 6378