



## Original Article

## *Punica granatum* suppresses colon cancer through downregulation of Wnt/ $\beta$ -Catenin in rat model



Hanaa H. Ahmed<sup>a</sup>, Hanan S. El-Abhar<sup>b</sup>, Elsayed Abdul Khalik Hassanin<sup>c</sup>, Noha F. Abdelkader<sup>b</sup>, Mohamed B. Shalaby<sup>c,\*</sup>

<sup>a</sup> Department of Hormones, Medical Research Division, National Research Centre, Cairo, Egypt

<sup>b</sup> Department of Pharmacology and Toxicology, Faculty of Pharmacy, Cairo University, Cairo, Egypt

<sup>c</sup> National Nutrition Institute, General Organization for Teaching Hospitals and Institutes, Ministry of Health, Cairo, Egypt

## ARTICLE INFO

## Article history:

Received 17 March 2017

Accepted 17 May 2017

Available online 15 August 2017

## Keywords:

Colon cancer  
Pomegranate  
Wnt/ $\beta$ -Catenin  
Inflammation  
Proliferation  
Apoptosis

## ABSTRACT

This study aims to elucidate the beneficial effect of *Punica granatum* L., Lythraceae (pomegranate) peel extract in the management of colon cancer induced intrarectally with *N*-methylnitrosourea. Adult male Sprague–Dawley rats were administered *N*-methylnitrosourea (2 mg in 0.5 ml water/rat) intrarectally three times/week for five weeks to induce colorectal cancer, followed by treatment with either 5-fluorouracil (12.5 mg/kg, *i.p.*) or *Punica* peel extract (2.25 or 4.5 g/kg, *p.o.*). Developed tumor elevated plasma TGF- $\beta$ , and Bcl2, serum epidermal growth factor, carcinoembryonic antigen, colon cancer specific antigens, and matrix metalloproteinase-7. Besides, immune-histochemical studies revealed an increase in COX-2, cyclin D1 and survivin content, as well as upregulation of the expression of colonic  $\beta$ -Catenin, K-ras and C-myc genes. These results were further supported by the histological findings. *Punica* peel extract-treated rats, particularly those treated with a high dose, exhibited a marked reduction in the aforementioned parameters and improved the histological organization of the colon tissue. These alterations were consistent with those mediated through 5-fluorouracil. The present study encourages the use of *P. granatum* L. against colon cancer. Because *Punica* peel extract promotes apoptosis, mitigates inflammation and suppresses tumor cell proliferation *in vivo*, the potential mechanism underlying these activities might depend on the inhibition of the Wnt/ $\beta$ -Catenin signaling pathway.

© 2017 Published by Elsevier Editora Ltda. on behalf of Sociedade Brasileira de Farmacognosia. This is an open access article under the CC BY-NC-ND license (<http://creativecommons.org/licenses/by-nc-nd/4.0/>).

## Introduction

Colorectal cancer (CRC) is the leading cause of cancer-related mortality worldwide and is the third most commonly diagnosed cancer in men and the second most commonly diagnosed cancer in women in terms of incidence (Zhao et al., 2014). The onset and progression of CRC involves unregulated epithelial cell proliferation reflecting accumulated genetic mutations (Zhao et al., 2014). Recent evidence has shown that the prolonged survival of genetically unstable colorectal epithelial cells, eventually leading to malignant transformation is accompanied by the progressive suppression of apoptosis (Zhao et al., 2014).

The majority of sporadic forms of CRC harbor genetic alterations in key elements of the Wnt/ $\beta$ -Catenin signaling cascade, particularly in Adenomatous polyposis coli (APC) and  $\beta$ -Catenin,

thereby increasing the transcriptional activity of the latter (Kundu et al., 2006).  $\beta$ -Catenin target genes play an ultimate role in tissue homeostasis, and the initiation and progression of CRC through the regulation of various cellular processes, including proliferation, stem cell fate, survival, differentiation, migration and angiogenesis (Srimuangwong et al., 2012). Particularly, the genes involved in proliferation and migration were overexpressed in CRC (Srimuangwong et al., 2012).

Interestingly, the ingestion of a phytochemical-rich diet, including fruits and vegetables, has been associated with a decreased risk of CRC incidence (Sharma et al., 2010). Among foods, small fruits and berries have attracted much attention, and the association between their bioactive components and cancer prevention has become the focus of keen scientific interest.

The fruit of *Punica granatum* L., Lythraceae (pomegranate), possesses many medicinal properties, reflecting anti-oxidant and anti-inflammatory potentials (Adhami et al., 2009). The compounds present in *P. granatum*, which have been largely investigated for cancer preventive properties, include polyphenols,

\* Corresponding author.

E-mail: [mohamed.shalaby@std.pharma.cu.edu.eg](mailto:mohamed.shalaby@std.pharma.cu.edu.eg) (M.B. Shalaby).

particularly ellagitannins (ET), punicalagins, flavonoids and the 3-glucosides/3,5-diglucosides of the anthocyanins delphinidins, cyanidins and pelargonidins (Middha et al., 2013). Ellagitannins are metabolized into two active compounds, viz., ellagic acid (Sharma et al., 2010) and urolithin A (UA), generated through the action of gut microbiota on ET (Sharma et al., 2010). Urolithins suppress the proliferation of colon cancer cells, stimulate cell cycle arrest, ameliorate key cellular processes associated with colon cancer development, such as mitogen-activated protein kinase (MAPK) signaling (González-Sarriás et al., 2009); they also reduced the colonic mucosa inflammatory progression in a rat colitis model (Larrosa et al., 2009). Furthermore, rutin (a flavonol glycoside) promotes apoptosis and cell cycle arrest in human colon cancer (Vijay et al., 2016). Noteworthy, the peel, which is the non-edible part of fruits, contains larger quantities of these polyphenols than the edible parts, accompanied by higher cancer anti-proliferative potential (Orgil et al., 2014). A recent study showed that *P. granatum* peel extract (PPE) reduces cell proliferation and induces apoptosis in MCF-7 human breast cancer cells via anti-oxidant and apoptotic activities (Shirode et al., 2014). Accordingly, the present study was delineated to explore the underlying mechanism (s) in favor of the antitumor activity of *P. granatum* against colon cancer induced in the experimental animals.

## Materials and methods

### Herbal extract

*Punica granatum* L., Lythraceae, peel extract (PPE) was supplied by United Group Pharma Co. (Bader city, Cairo, Egypt). Test plants were authenticated by Prof. Ibrahim El-Garf, Department of Botany, Faculty of Science, Cairo University, Egypt. Voucher specimen (number 20170402M) was kept in the herbarium of Pharmacognosy Department, Faculty of Pharmacy, Cairo University.

### Preparation of Punica granatum peel extract (PPE)

Four kilograms of peel were separated from *P. granatum* fruits in August 2014 (5–6 kg). The peels were cut into small pieces and blended with 4 l of methanol (70%) using an electric blender, followed by incubation for 10–12 h. The extract was filtered through filter paper and the solvent was evaporated using a rotary evaporator (Büchi Labortechnik AG, Flawil, Switzerland). The resulting extract was dehydrated in an oven at 50 °C for 24 h (El-Toumy and Rauwald, 2002).

### Chemicals

Gallic acid, protocatechuic acid, catechin, rutin, ellagic acid, punicalagin were obtained from Sigma–Aldrich Chemical Company (St. Louis, USA).

### Determination of polyphenols by HPLC-DAD

The HPLC system was an Agilent 1100 equipped with a quaternary pump, online degasser, autosampler and diode-array detector (DAD). Data collection and analyses were performed using Chemstation software. Chromatographic separations of the extracts were carried out on a Zorbax C18 column (250 × 4.6 mm, particle size 5 μm, Agilent) using water/acetic acid (98:2, v/v) (Solvent A) and methanol (Solvent B) as the mobile phases at a flow rate of 1 ml/min. The elution program used was as follows: 5% B for 5 min, 5–70% B for 25 min, and 70–5%B for 10 min. The column temperature was maintained at 35 °C and the detection was monitored at 254, 280, and 360 nm. UV spectra of the components were taken continuously between 200 and 400 nm throughout the elution in order

to determine component identity and peak purity. The injection volume for standards and samples was 10 μl.

### Animals and ethics statement

Adult male Wistar rats, weighing 150–170 g, were obtained from the Animal Facility Breeding Colony of the National Research Center, Cairo, Egypt. The animals were acclimatized for one week in a specific pathogen-free barrier area at constant temperature (25 ± 1 °C), humidity (55%), and a 12 h light/dark cycle. Rats were housed with a standard laboratory diet recommended by the American Institute of Nutrition (Reeves et al., 1993) and had free access to food and water and their body weight was assessed daily. The animals were managed according to the Guide for the Care and Use of Laboratory Animals published by the US National Institutes of Health (NIH Publication No. 85–23, revised 1996) and the study protocol was approved by the Ethical Committee for Animal Experimentation at the Faculty of Pharmacy, Cairo University (Permit Number: PT 664).

### Experimental design

Forty adult male Sprague-Dawley rats, weighing 150–170 g, were randomly allocated into five groups (8 rats/each group); animals of the first group received vehicle (1 ml DMSO (5%), *p.o.*) and served as the normal control group. Rats in the other four groups were rectally administered *N*-MNU (2 mg in 0.5 ml water/rat) three times/week for five weeks to induce CRC (Ahmed et al., 2013) a model that was reported to mimic histopathologically human colon tumors (Narisawa and Fukaura, 2003). CRC animals were divided into group II, which received the vehicle and served as the CRC untreated group, while the remaining three groups were treated throughout the four months experimental period with the following treatments. In group III, rats were treated with 5-fluorouracil (5-FU; 12.5 mg/kg, *i.p.* [equivalent to 2 mg/kg for humans (Shin et al., 2010)]) on days 1, 3 and 5, with the cycle repeated every four weeks (Watson et al., 1998). Animals in groups IV and V were treated daily with PPE for four months at two dose levels (2.25 and 4.5 g/kg in DMSO (5%), *p.o.*). The selected doses of PPE; viz., 4.5 g/kg b.wt [equivalent to 0.729 g/kg for humans (Shin et al., 2010)] and its half dose 2.25 g/kg b.wt [equivalent to 0.365 g/kg for humans (Shin et al., 2010)] were administered daily for 6 months. After an overnight fast, the final body weights were measured and the rats were euthanized using CO<sub>2</sub>. Blood was collected through cardiac puncture, and the blood samples were divided into two aliquots for the separation of plasma and serum. Subsequently, the plasma and serum samples were acquired through centrifugation at 2555 × *g* for 30 min at 4 °C. The colon tissues were rapidly excised, cleaned and washed in ice-cold saline, blotted dry and equally divided into two longitudinal portions. The first portion was preserved in formalin saline for histological and immunohistochemical examination, respectively, while the second portion was collected in liquid nitrogen and stored at -80 °C for subsequent biochemical and molecular genetic analyses.

### Biochemical measurements

Plasma transforming growth factor-beta (TGF-β), Bcl2 levels, and serum levels of epidermal growth factor (EGF), colon cancer-specific antigen (CCSA-4), carcino-embryonic antigen (CEA), and matrix metalloproteinase-7 (MMP-7) were assayed using commercial ELISA kits (Glory Science Co., Ltd, Del Rio, TX, USA) according to the manufacturer's instructions.

### Semi-quantitative real-time PCR (sqRT-PCR) detection of $\beta$ -Catenin, K-ras and C-myc gene expressions

#### Isolation of total RNA

Total RNA was extracted from the colon tissue of rats using TRIzol<sup>®</sup> reagent (Cat#15596-026, Invitrogen, Darmstadt, Germany) according to the manufacturer's instructions with minor modifications. The tissue samples (50 mg) were homogenized in 1 ml of TRIzol<sup>®</sup> reagent and the RNA was dissolved in diethylpyrocarbonate (DEPC)-treated water. Total RNA was treated with 1U of RQ1 RNase-free DNase (Invitrogen, Darmstadt, Germany) to digest DNA residues and re-suspended in DEPC-treated water. The purity of total RNA was assessed according to the 260/280 nm ratio (between 1.8 and 2.1), and the integrity was assessed through ethidium bromide staining analysis of 28S and 18S bands after formaldehyde-containing agarose gel electrophoresis.

#### Reverse transcription (RT) reaction

The complete poly(A)<sup>+</sup> RNA, isolated from each colon tissue, was reverse transcribed into cDNA in a total volume of 20  $\mu$ l using the Revert Aid<sup>™</sup> First Strand cDNA Synthesis Kit (MBI, Opelstrasse, Germany) according to manufacturer's instructions. The RT reaction was performed at 25 °C for 10 min, followed by 1 h at 42 °C, and completed with a denaturation step at 99 °C for

5 min. Subsequently, the reaction tubes containing RT preparations were flash-cooled in an ice chamber until further use for DNA amplification through sqRT-PCR.

#### Semi-quantitative real-time-polymerase chain reaction

An iQ5-BIO-RAD Cycler (Cepheid, CA, USA) was used to determine the cDNA copy number. PCR reactions were set up in 25  $\mu$ l reaction mixtures containing 12.5  $\mu$ l 1  $\times$  SYBR<sup>®</sup> Premix ExTaq<sup>™</sup> (Takara, Biotech Co. Ltd., Saint-Germain-en-Laye, France), with 0.5  $\mu$ l of sense primers (0.2  $\mu$ M), 0.5  $\mu$ l of antisense primer (0.2  $\mu$ M), 6.5  $\mu$ l of distilled water, and 5  $\mu$ l of cDNA template. The sequences of the primers are described in Box 1. At the end of each sqRT-PCR a melting curve analysis was performed at 95 °C to assess the quality of the used primers. The relative quantification of the target genes was determined through the  $\Delta$ C<sub>T</sub> method using  $\beta$ -actin as a reference gene.

#### Immuno-histochemical and histological examination

After the colon tissues were fixed in formalin saline for 24 h, the specimens were processed for paraffin embedding and two sets of 4  $\mu$ m sections were prepared. In the first set, the sections were prepared for immune-histochemical examination. The sections were collected onto glass-positive slides and were fixed in

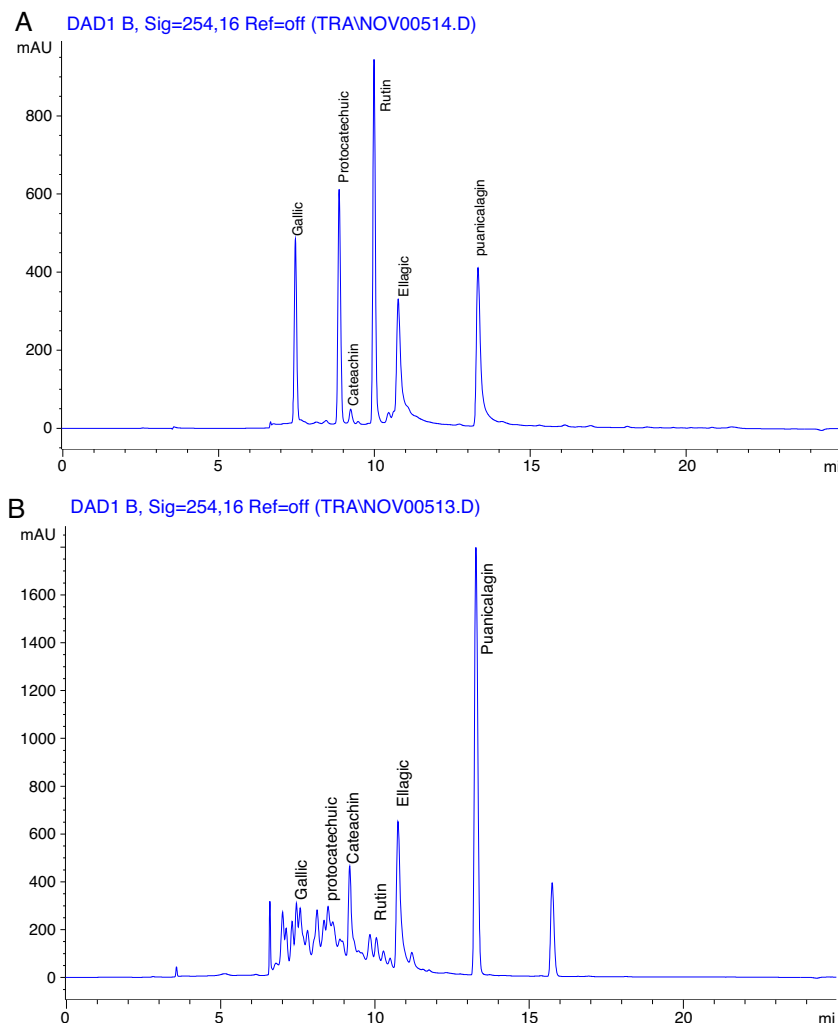


Fig. 1. HPLC chromatogram of standards (A) and pomegranate peel extract (B) at 254 nm.

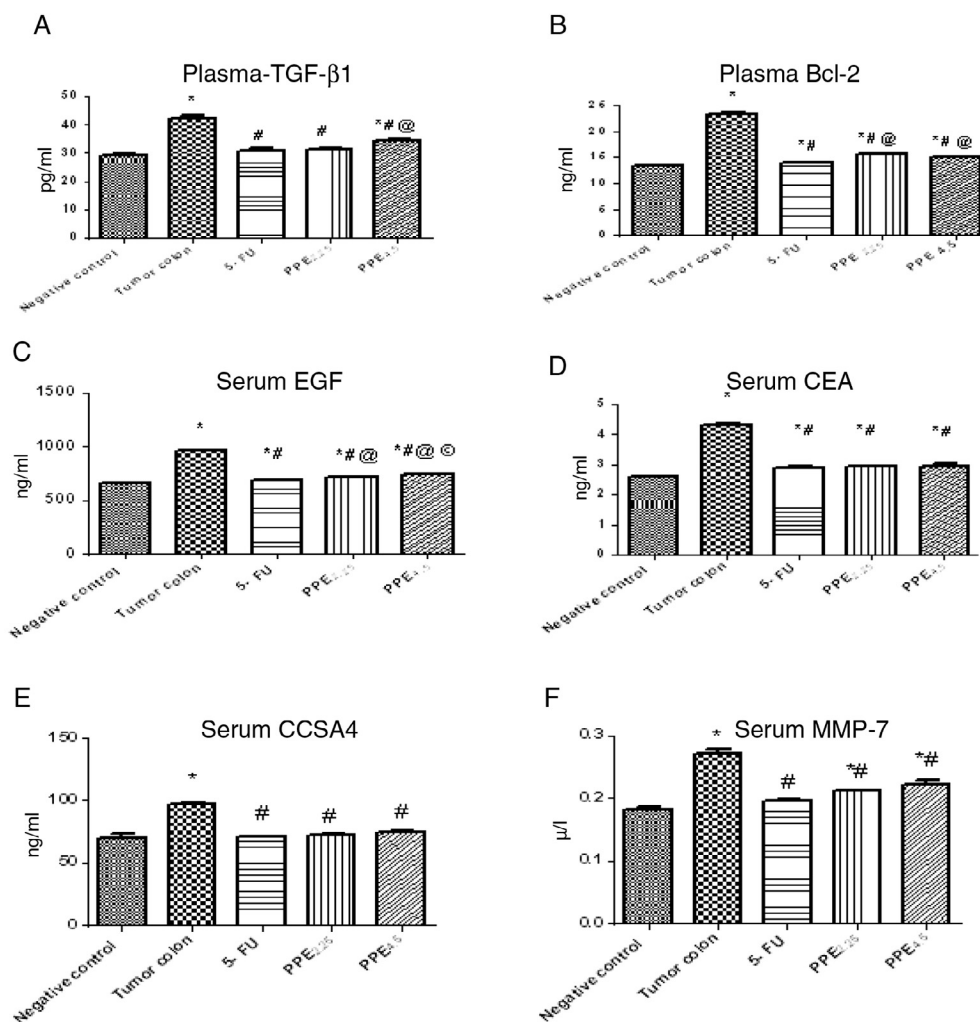
Box 1: Primer sequences used for sqRT-PCR		
Gene	Primer sequence (5'–3')	Sequence references
β-Catenin	F: CAAT GGG TCA TAT CAC AGA TTC TT	Austinat et al. (2008)
	R: TCT CTT TTC TTC ACC ACA ACA TTT	
K-ras	F: AGT ACG ACC CTA CGA TAG AGG ACT CCT	Fuentes-Calvo et al. (2010)
	R: CAA TCT GTA CTG TCG GAT CTC TCT CAC C	
C-myc	F: TGA CGA GAC CTT CGT GAA GA	Tao et al. (2002)
	R: ATT GAT GTT ATT TAC ACT TAA GGG T	
β-Actin	F: CCC CAT CGA GCA CGG TAT TG	Eshak et al. (2010)
	R: ATG GCG GGG GTG TTG AAG GTC	

a 65 °C oven for 1 h. Subsequently, the slides were deparaffinized and the samples were blocked for endogenous peroxidase activity after immersing the slides in 3% hydrogen peroxide for 10 min. Next, the sections were washed with Tris buffered saline, and similarly treated according to the immune-histochemical procedure described above. The Power-Stain™-1.0 Poly HRP DAB Kit (Cat# 54-0017, Genemed Biotechnologies, San Francisco, CA, USA) was used to visualize any antigen-antibody reaction on the tissues. The slides were subsequently incubated with rabbit primary polyclonal

antibody cyclooxygenase-2 (COX-2; Cat# RB-9072-R7, Thermo-scientific, Waltham, MA, USA), cyclin D1 (Cat#RB-9041-R7, Thermo-scientific, Waltham, MA, USA) or survivin (Cat# RB-9245-R7, Thermo-scientific, Waltham, MA, USA) overnight at 4 °C in a humidity chamber. Henceforward, poly-horse-radish peroxidase enzyme conjugate was applied for 20 min, and 3,3'-diaminobenzidine chromogen was prepared and applied for 2 min. Subsequently, the slides were rinsed, counterstained with Mayer's hematoxylin, followed by cover-slipping as the final step prior to examining the slides under the light microscope. Image J Software (NIH, version v1.45e, Bethesda, MD, USA) was calibrated for image analysis. In the second set, the sections were collected onto glass slides, deparafinized and stained with hematoxylin and eosin (H&E) for light microscopic examination (Nikon Microscope SE, Nippon Kogaku KK, Tokyo, Japan) at 40× and 64× magnifications of the histological changes.

### Statistical analysis

The study results were analyzed using GraphPad Prism 5 (GraphPad Software, Inc, La Jolla, CA, USA). The results are expressed as the means ±SD; a probability level of less than 0.05 was accepted as statistically significant. The results from each experimental group were compared using one-way ANOVA



**Fig. 2.** Effect of PPE and 5-FU on plasma/serum levels of TGF-β, Bcl2, EGF, CEA, CCSA-4 and MMP-7 in N-MNU-induced CRC in rats. The data are presented as the means ±SD (n=8). Statistical analysis was carried out using one way ANOVA followed by Tukey's multiple comparison test. As compared with negative (\*), tumor (#) and 5-FU (@) treated groups (p < 0.05).

**Table 1**  
Body weight.

Groups	Normal group	Tumor group	5-FU	PPE <sub>2,25</sub>	PPE <sub>4,5</sub>
Initial body weight	171.4 ± 4.0	181.1 ± 3.3	175.3 ± 2.3	173.5 ± 2.4	173.8 ± 2.5
Final body weight	199.0 ± 6.5	150.8 ± 4.1 <sup>a</sup>	184.5 ± 4.8 <sup>b</sup>	178.6 ± 4.2 <sup>b</sup>	181.1 ± 6.2 <sup>b</sup>

Values are means ± SD. Statistical analysis was carried out using one way ANOVA followed by Tukey's multiple comparison test. As compared with control (a) and tumor/N-MNU (b) control groups ( $p < 0.05$ ). PPE: *P. granatum* peel extract.

analysis of variance followed by Tukey's *post hoc* test. Differences in mean values among the groups were tested using Tukey's test.

## Results

### Analysis of the extract by HPLC

HPLC chromatograms have affirm six marker components existent in ethanol extract of *P. granatum* peel as shown in Fig. 1. These phenolic components have been identified as gallic acid (Rt: 7.4 min; 1.366 mg/ml), protocatechuic acid (Rt: 8.8 min; 0.047 mg/ml), catechin (Rt: 9.2 min; 0.377 mg/ml), rutin (Rt: 9.9 min; 0.136 mg/ml), ellagic acid (Rt: 10.7 min; 4.643 mg/ml), and punicalagin (Rt: 13.2 min, 1.910 mg/ml) by their retention time and UV absorbance of purified standards.

### Effect of different treatments on body weight and food intake

The initial body weight was not significantly different among the studied groups. However, the final body weight was significantly decreased in the N-MNU group (tumor group) compared with the negative control group ( $p < 0.05$ ). Treatment with 5-FU and the two doses of PPE significantly increased the body weight vs the N-MNU group ( $p < 0.05$ ) (Table 1).

### Effect of PPE and 5-FU on plasma/serum levels of TGF- $\beta$ , Bcl2, EGF, CEA, CCSA-4 and MMP-7 in N-MNU-induced CRC in rats

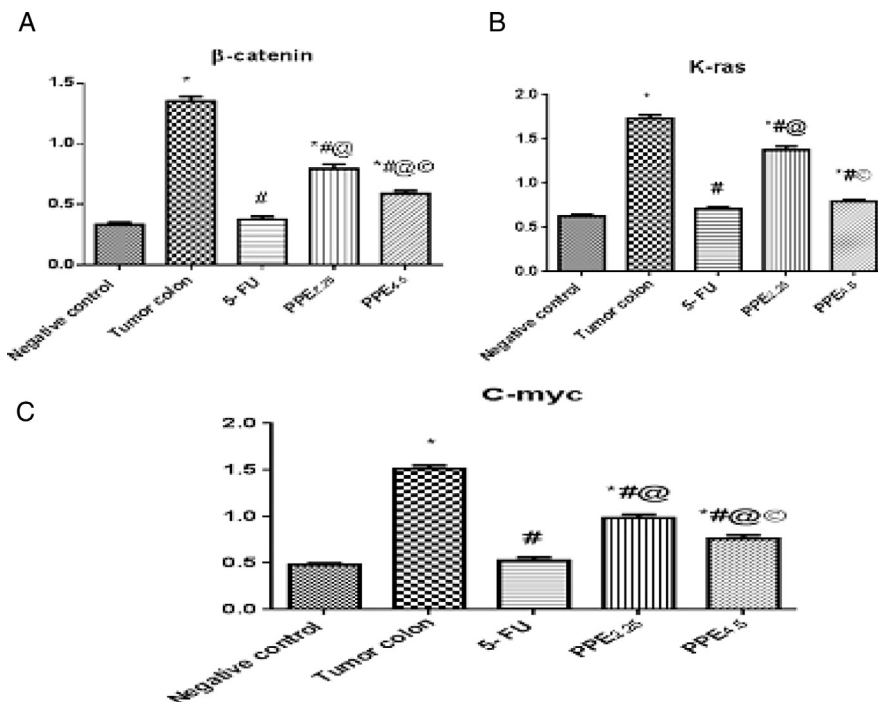
As illustrated in Fig. 2, N-MNU-induced CRC resulted in a 1.5-fold elevation of plasma (A) TGF- $\beta$  and (B) Bcl2, as well as serum (C) EGF, (D) CEA, (E) CCSA-4 and (F) MMP-7 compared with the negative control group. In addition, treatment with PPE reverted such increments in a dose-dependent manner and the high dose effects were consistent with those of 5-FU.

### Effect of PPE and 5-FU on colon tissue mRNA levels of $\beta$ -Catenin, K-ras, and C-myc genes in N-MNU-induced colon cancer in rats

N-MNU markedly up-regulated the expression of  $\beta$ -Catenin, K-ras, and C-myc genes in colon tissues at the mRNA level almost 4-, 2.8-, and 3.2-folds, respectively, versus the negative control group (Fig. 3). Treatment with 5-FU amended these alterations in the gene expression levels 71.85%, 58.95%, and 64.66%, respectively, versus the N-MNU group. Similarly, PPE significantly downregulated the expression level of the tested genes in a dose-dependent manner relative to the N-MNU group.

### Effect of PPE and 5-FU on immune-histochemical parameters in N-MNU-induced colon cancer in rats

As shown in Fig. 4, immune-histochemical staining of the colon tissue in (A) negative control rats using a COX-2 antibody exhibited



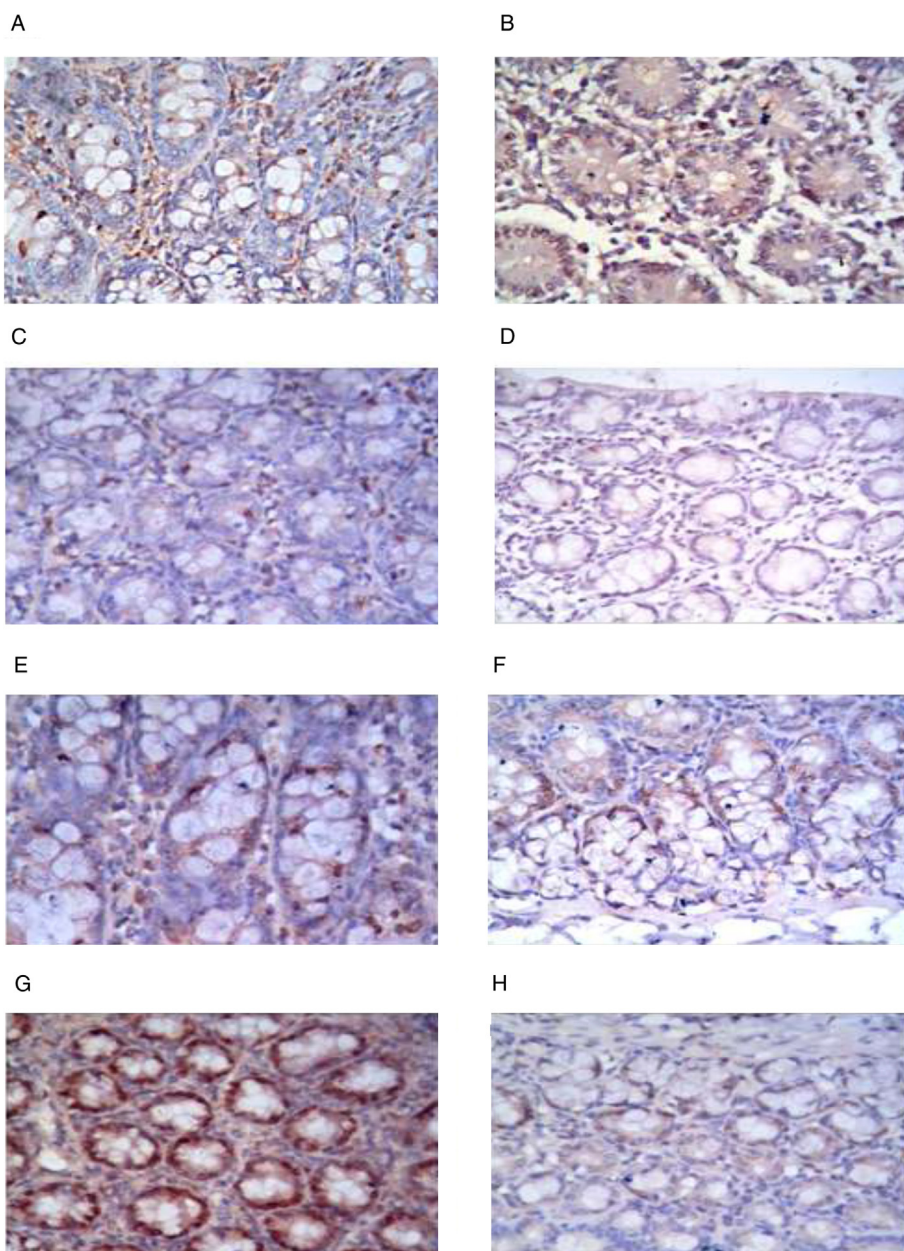
**Fig. 3.** Effect of PPE and 5-FU on (A)  $\beta$ -Catenin, (B) K-ras and (C) C-myc genes expression level in N-MNU-induced colon cancer in rats. The data are presented as the means ± SD ( $n = 8$ ). Statistical analysis was carried out using one way ANOVA followed by Tukey's multiple comparison test. As compared with negative (\*), tumor (#) and 5-FU (@) treated groups ( $p < 0.05$ ).

a mild intracellular positive reaction, while (B) *N*-MNU and (C) 5-FU treated rats revealed a severe intracellular positive reaction. In contrast, PPE significantly alleviated the aforementioned disruptions in a dose dependent manner. (D) A moderate intracellular positive reaction was observed following treatment at a low dose, while (E) a mild intracellular positive reaction was shown in the high dose-treated group. Immuno-histochemical examination of cyclin D1 in colon tissue of (F) negative control rats revealed mild intracellular positive reaction, whereas (G) a pronounced intracellular positive reaction was observed in the cancer group. Treatment with (H) 5-FU showed moderate intracellular positive reaction, while either (I) low or (J) high doses of PPE revealed mild intracellular positive reactions. Similarly, immuno-histochemical reactions of survivin in (K) negative control rats revealed a mild intracellular positive reaction, whereas (L) a distinct intracellular positive reaction was

observed in the colon tissue of the cancer group. Management with (M) 5-FU or (O) a high dose of PPE showed mild intracellular positive reactions, while (N) the low dose of PPE showed moderate intracellular positive reactions.

*Effect of PPE and 5-FU on histopathological alterations in N-MNU-induced colon cancer in rats*

As depicted in Fig. 5, photomicrographs of the (A) negative control section of colon tissue showed the normal histological features of the mucosa, submucosa and muscularis layers. However, the section (B) of *N*-MNU untreated group shows dysplasia and anaplasia in the epithelial cells lining the glandular structure and its (C) magnification shows the mitotic activity of the nuclei (black arrows) and hyperchromasia



**Fig. 4.** Effect of PPE and 5-FU on the immune-histochemical staining of rat colon tissue using antibodies against (A–E) COX-2, (F–J) cyclin-D1 and (K–O) survivin in *N*-MNU-induced colon cancer in rats.

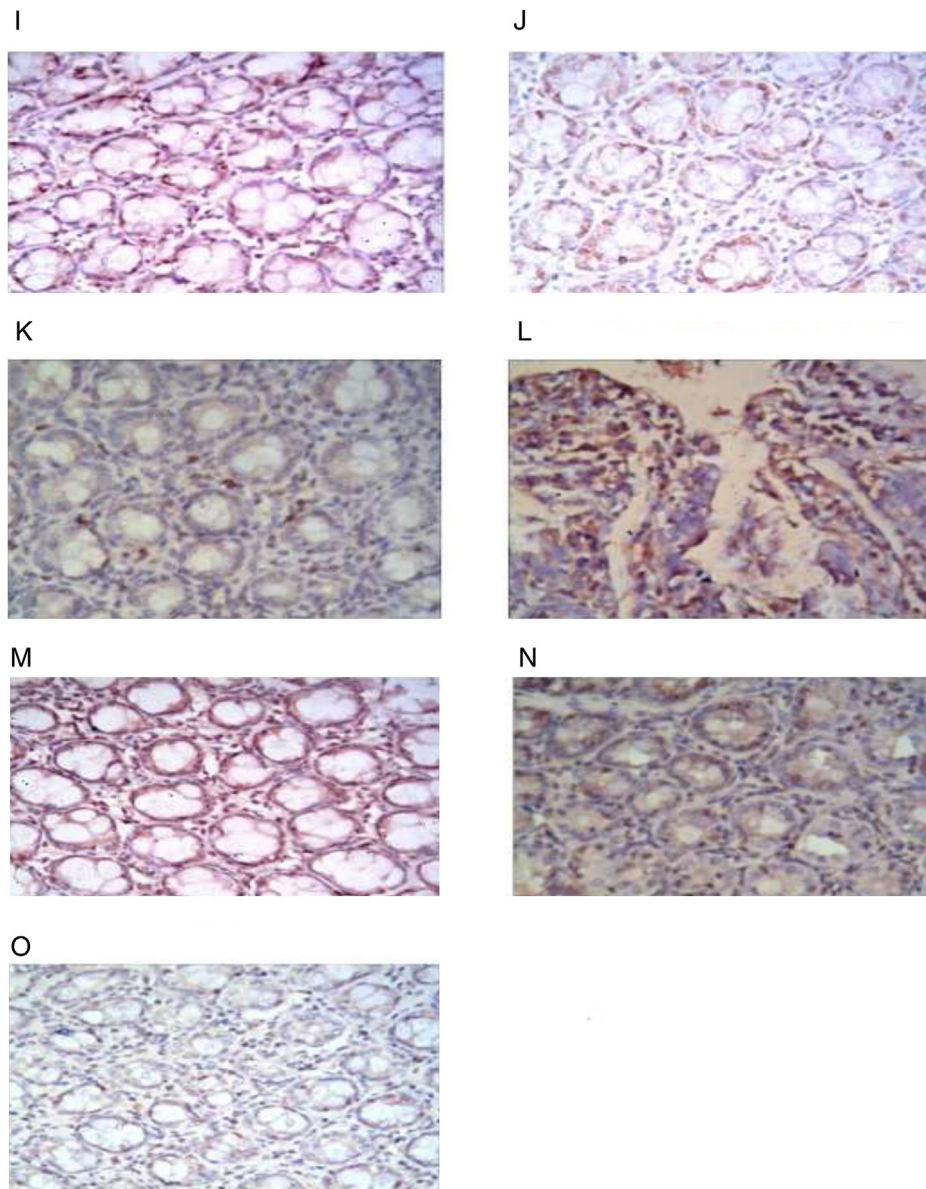


Fig. 4. (continued)

(yellow arrow). (D) Section of the 5-FU treated group shows mild dysplasia, without anaplasia, while (E) the tissue section of low-dose PPE treated group shows inflammatory cell infiltration in the lamina propria of the mucosal layer and the underlying musculature, with intact mucosal epithelium. (F) Section of tissue treated with high-dose PPE shows inflammatory cell infiltration in the lamina propria of the mucosal layer, with intact mucosal epithelium.

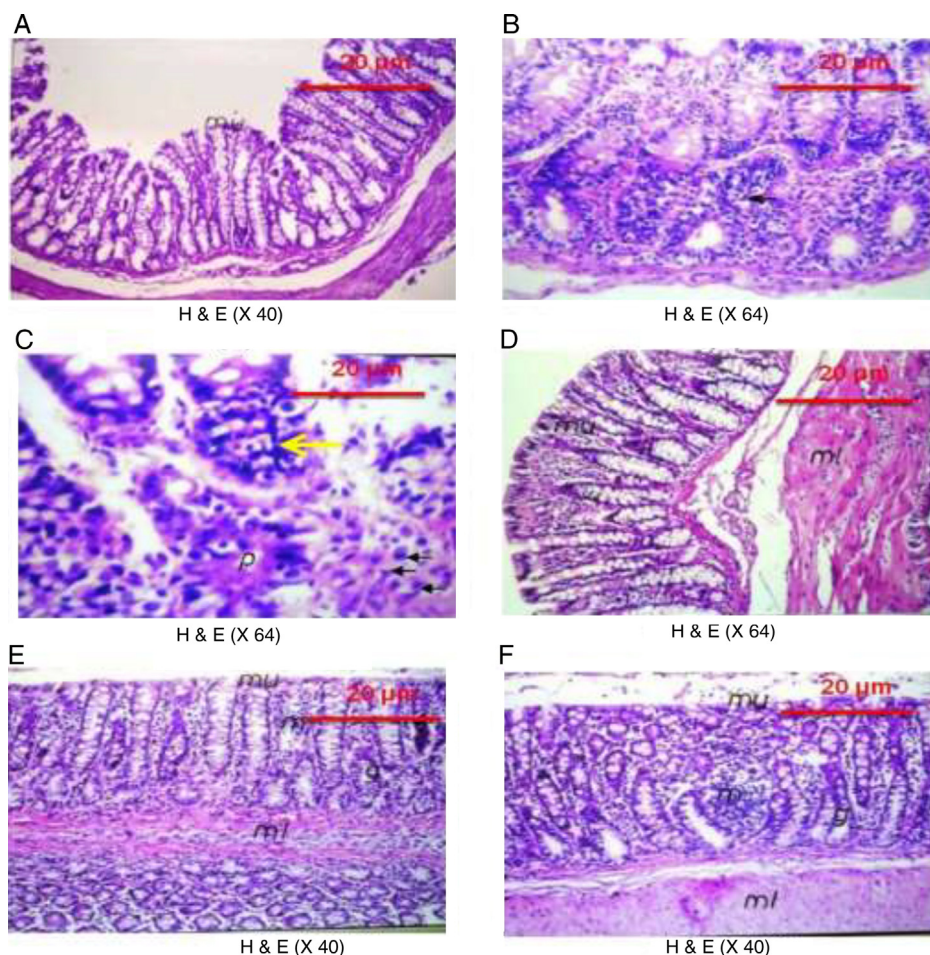
#### Discussion and conclusion

The present study has provided compelling evidence favoring the chemopreventive effect of *P. granatum* L. against colon cancer in the experimental model and validated the suggested hypothesis. In the present work, PPE-treated rats, particularly at the high dose, exhibited a marked reduction in colon cancer as documented by the reduction in the colon cancer markers, viz., CEA and CCSA-4, through an anti-proliferative effect (TGF- $\beta$ , EGF, C-myc and cyclin D1), pro-apoptotic potential (survivin and Bcl2), anti-metastasis

(MMP-7), and anti-inflammatory action (COX-2), and the down-regulation of  $\beta$ -Catenin and K-ras genes.

The Wnt/ $\beta$ -Catenin signaling pathway plays a pivotal role in the transcriptional regulation process that impacts cell growth, development, and differentiation in many malignancies, including CRC (Ashihara et al., 2015). Wnt proteins dysregulated through the activation of  $\beta$ -Catenin, a downstream activator of the Wnt signaling pathway, have been implicated in many cancers (Ashihara et al., 2015).  $\beta$ -Catenin targets genes that regulate different cellular processes involving proliferation (e.g., C-myc, cyclin D1), survival/anti-apoptosis (survivin), differentiation, migration (MMP7), and angiogenesis (Herbst et al., 2014). While  $\beta$ -Catenin plays a key role in embryonic development and tissue homeostasis, this protein also participates in the initiation and progression of colon cancer. In particular, the deregulation of genes involved in proliferation and migration has been frequently observed in colorectal carcinomas (Herbst et al., 2014).

Hence, the positive treatment effect of PPE might reflect an ability to down-regulate the gene expression level of  $\beta$ -Catenin via



**Fig. 5.** Representative photomicrographs of colon tissue with or without *N*-MNU-induced CRC. (A) Normal control section showing the normal histological features of the mucosa, submucosa and muscularis layers, while (B) *N*-MNU untreated section shows dysplasia and anaplasia in the epithelial cells lining the glandular structure and its (C) magnification shows the mitotic activity of the nuclei (black arrows) and hyperchromasia (yellow arrow). (D) 5-FU treated section shows mild dysplasia, without anaplasia, while (E) section treated with low-dose PPE shows inflammatory cell infiltration in the lamina propria of the mucosal layer and the underlying musculature, with intact mucosal epithelium. (F) High-dose PPE section shows inflammatory cell infiltration in the lamina propria of the mucosal layer, with intact mucosal epithelium.

the attenuation of the Wnt signaling pathway in hepatocellular carcinoma (Bhatia et al., 2013). PPE active constituents, such as ellagic acid (EA), have also been demonstrated to modulate the Wnt signaling pathway through the inhibition of casein kinase, a positive regulator of the Wnt signaling pathway; EA also functions as a modulator of the interaction between  $\beta$ -Catenin and members of the  $\beta$ -Catenin destruction complex (Sharma et al., 2010). Rutin has antitumor effect through inducing G2/M cell cycle arrest and promoting apoptosis and decreasing BCL2 expression (Chen et al., 2013). Moreover, PPE accumulates in the G2/M phase of the cell cycle associated with the significant down-regulation of the C-myc gene (Adhami et al., 2009). Furthermore, punicalagin, one of the active anti-cancer components of PPE, inhibits human colon cancer growth associated with the inhibition of cyclin D1 and survivin expression through the Wnt/ $\beta$ -Catenin signaling cascade (Tang et al., 2016). The suppression of  $\beta$ -Catenin translocation and the subsequent expression of the target genes through PPE were reflected in the histological examination of colon tissues through PPE-mediated protection against *N*-MNU-induced colon adenocarcinoma. In addition, PPE mediated apoptosis by enhancing Bcl2 cleavage, an effect presumably resulting from the action of this treatment on the oncogenic Notch and Wnt pathways and their downstream targets, viz.,  $\beta$ -Catenin, C-myc, cyclin D1, cyclin B1, pERK, MMP-7, MMP-9 and EGF (Tao et al., 2002; Middha et al., 2013; Herbst et al., 2014). Treatment with PPE extract also decreased

C-myc and COX-2, which are regulated through  $\beta$ -Catenin (Patel et al., 2008). Moreover, EA down-regulates the expression levels of K-ras (González-Sarrías et al., 2009).

In the present study, the gene expression levels of  $\beta$ -Catenin, K-ras and C-myc in the colon tissues of the 5-FU treated rats in the cancer group were down-regulated in compared with the untreated cancer group. In addition, 5-FU substantially abated the levels of CEA, CCSA-4, TGF- $\beta$ , EGF, cyclin D1, MMP-7, COX-2, Bcl2 and survivin. The activity of 5-FU primarily depends on intracellular delivery to the active metabolite, 5-fluoro-2'-deoxyuridine-5'-monophosphate, which inhibits DNA synthesis through the formation of a stable complex with thymidylate synthase (TS) in the presence of folates, followed by the initiation of cell-cycle arrest or cell death (Kikuchi et al., 2009). TS decreased Bcl-2 expression (Longley et al., 2003), confirming the results of the present and previous studies. 5-FU triggers apoptosis in DN-HIF-transfected A549 cells via the reduction of sicyclin D1 (cyclin D1-specific interference RNA) and the downregulation of C-myc mRNA expression, phosphorylated C-myc in human colon cancer KM12C cells and survivin mRNA expression (Wen et al., 2010). Moreover, 5-FU significantly downregulated the expression of  $\beta$ -Catenin protein and suppressed the Wnt canonical pathway (Refaat et al., 2015).

In summary, this study demonstrated the antitumor activity of *P. granatum* peel extract against colon cancer progression indicated



by decreasing colon cancer markers, viz., CEA and CCSA-4. PPE, which is rich in multiple bioactive natural constituents, mediated its effect possibly by its anti-proliferative effect (TGF- $\beta$ , EGF, C-myc and cyclin D1), pro-apoptotic potential (survivin and Bcl2), anti-metastasis (MMP-7), and anti-inflammatory action (COX-2), and the down-regulation of  $\beta$ -Catenin and K-ras genes. These effects involve the modulation of the Wnt/ $\beta$ -Catenin signaling pathway. The study, hence, nominates the use of PPE as an additive on therapy to be studied in clinical trials.

### Ethical disclosures

**Protection of human and animal subjects.** The authors declare that the procedures followed were in accordance with the regulations of the relevant clinical research ethics committee and with those of the Code of Ethics of the World Medical Association (Declaration of Helsinki).

**Confidentiality of data.** The authors declare that they have followed the protocols of their work center on the publication of patient data.

**Right to privacy and informed consent.** The authors have obtained the written informed consent of the patients or subjects mentioned in the article. The corresponding author is in possession of this document.

### Authors contributions

MBS (PhD student) contributed in collecting and running the laboratory work. HHA supervised the laboratory work. HHA, HSE and NFA contributed in writing the manuscript. HHA and HSE contributed in designing the study, critical analysis of data, supervised the laboratory work. EAKH contributed to molecular and HPLC analysis. All the authors have read the final manuscript and approved the submission.

### Conflicts of interest

The authors declare no conflicts of interest.

### Acknowledgments

The authors express sincere appreciation to Prof. Adel Baker Kholoussy, Faculty of Veterinary Medicine, Cairo University; Prof. Ibrahim El-Garf, Department of Botany, Faculty of Science, Cairo University and United Group Pharma Co. (Bader city, Cairo, Egypt).

### References

- Adhami, V.M., Khan, N., Mukhtar, H., 2009. Cancer chemoprevention by pomegranate: laboratory and clinical evidence. *Nutr. Cancer* 61, 811–815.
- Ahmed, H.H., Abdel-Rahman, M., Salem, F.E.H., Shalby, A.B., Lokman, M.S., 2013. Antitumor efficacy of *Boswellia serrata* extract in management of colon cancer induced in experimental animal. *Int. J. Pharm. Pharmaceut. Sci.* 5, 379–389.
- Ashihara, E., Takada, T., Maekawa, T., 2015. Targeting the canonical Wnt/ $\beta$ -Catenin pathway in hematological malignancies. *Cancer Sci.* 106, 665–671.
- Austinat, M., Dunsch, R., Wittekind, C., Tannapfel, A., Gebhardt, R., Gaultz, F., 2008. Correlation between beta-Catenin mutations and expression of Wnt-signaling target genes in hepatocellular carcinoma. *Mol. Cancer*. <http://dx.doi.org/10.1186/1476-4598-7-21>.
- Bhatia, D., Thoppil, R.J., Mandal, A., Samtani, K.A., Darvesh, A.S., Bishayee, A., 2013. Pomegranate bioactive constituents suppress cell proliferation and induce apoptosis in an experimental model of hepatocellular carcinoma: role of Wnt/ $\beta$ -Catenin signaling pathway. *Evid Based Complement. Alternat. Med.*. <http://dx.doi.org/10.1155/2013/371813>.
- Chen, H., Miao, Q., Geng, M., Liu, J., Hu, Y., Tian, L., Pan, J., Yang, Y., 2013. Anti-tumor effect of rutin on human neuroblastoma cell lines through inducing G2/M cell cycle arrest and promoting apoptosis. *Sci. World J.*. <http://dx.doi.org/10.1155/2013/269165>.
- El-Toumy, S.A., Rauwald, H.W., 2002. Two ellagitannins from *Punica granatum* heartwood. *Phytochemistry* 61, 971–974.
- Eshak, M.G., Ghaly, I.S., Khalil, W.K.B., Farag, I.M., Ghanem, K.Z., 2010. Genetic alterations induced by toxic effect of thermally oxidized oil and protective role of tomatoes and carrots in mice. *J. Am. Sci.* 6, 175–188.
- Fuentes-Calvo, I., Blázquez-Medela, A.M., Santos, E., López-Novoa, J.M., Martínez-Salgado, C., 2010. Analysis of k-ras nuclear expression in fibroblasts and mesangial cells. *PLoS One* 14, e8703.
- González-Sarrías, A., Espín, J.C., Tomás-Barberán, F.A., García-Conesa, M.T., 2009. Gene expression, cell cycle arrest and MAPK signalling regulation in Caco-2 cells exposed to ellagic acid and its metabolites, urolithins. *Mol. Nutr. Food Res.* 53, 686–688.
- Herbst, A., Jurinovic, V., Krebs, S., Thieme, S.E., Blum, H., Göke, B., Kolligs, F.T., 2014. Comprehensive analysis of  $\beta$ -Catenin target genes in colorectal carcinoma cell lines with deregulated Wnt/ $\beta$ -Catenin signaling. *BMC Genomics*. <http://dx.doi.org/10.1186/1471-2164-15-74>.
- Kikuchi, M., Mikami, T., Sato, T., Tokuyama, W., Araki, K., Watanabe, M., Saigenji, K., Okayasu, I., 2009. High Ki67, Bax, and thymidylate synthase expression well correlates with response to chemoradiation therapy in locally advanced rectal cancers: proposal of a logistic model for prediction. *Br. J. Cancer* 101, 116–123.
- Kundu, J.K., Choi, K.Y., Surh, Y.J., 2006. beta-Catenin-mediated signaling: a novel molecular target for chemoprevention with anti-inflammatory substances. *Biochim. Biophys. Acta* 1765, 14–24.
- Larrosa, M., Yañez-Gascón, M.J., Selma, M.V., González-Sarrías, A., Toti, S., Cerón, J.J., Tomás-Barberán, F., Dolara, P., Espín, J.C., 2009. Effect of a low dose of dietary resveratrol on colon microbiota, inflammation and tissue damage in a DSS-induced colitis rat model. *J. Agric. Food Chem.* 57, 2211–2220.
- Longley, D.B., Latif, T., Boyer, J., Allen, W.L., Maxwell, P.J., Johnston, P.G., 2003. The interaction of thymidylate synthase expression with p53-regulated signaling pathways in tumor cells. *Semin. Oncol.* 30, 3–9.
- Middha, S.K., Usha, T., Pande, V., 2013. A review on antihyperglycemic and antihepatoprotective activity of eco-friendly *Punica granatum* peel waste. *Evid Based Complement. Alternat. Med.*. <http://dx.doi.org/10.1155/2013/656172>.
- Narisawa, T., Fukaura, Y., 2003. Prevention by intrarectal 5-aminosalicylic acid of N-methylnitrosourea-induced colon cancer in F344 rats. *Dis. Colon Rectum* 46, 900–903.
- Orgil, O., Schwartz, E., Baruch, L., Matityahu, I., Mahajna, J., Amir, R., 2014. The antioxidative and anti-proliferative potential of non-edible organs of the pomegranate fruit and tree. *LWT-Food Sci. Technol.* 58, 571–577.
- Patel, R., Ingle, A., Maru, G.B., 2008. Polymeric black tea polyphenols inhibit 1,2-dimethylhydrazine induced colorectal carcinogenesis by inhibiting cell proliferation via Wnt/ $\beta$ -Catenin pathway. *Toxicol. Appl. Pharmacol.* 227, 136–146.
- Reeves, P.G., Nielsen, F.H., Fahey, G.C., 1993. AIN-93 purified diets for laboratory rodents: final report of the American Institute of 365 Nutrition ad hoc writing committee on the reformulation of the AIN-76A rodent diet. *J. Nutr.* 123, 1939–1951.
- Refaat, B., El-Shemi, A.G., Kensara, O.A., Mohamed, A.M., Idris, S., Ahmad, J., Khojah, A., 2015. Vitamin D3 enhances the tumoricidal effects of 5-fluorouracil through multipathway mechanisms in azoxymethane rat model of colon cancer. *J. Exp. Clin. Cancer Res.* 34, 71.
- Sharma, M., Li, L., Cerver, J., Killian, C., Kovoor, A., Seeram, N.P., 2010. Effects of fruit ellagitannin extracts, ellagic acid, and their colonic metabolite, urolithin A, on Wnt signaling. *J. Agric. Food Chem.* 58, 3965–3969.
- Shin, J.W., Seol, I.C., Son, C.G., 2010. Interpretation of animal dose and human equivalent dose for drug development. *J. Korean Oriental Med.* 31, 1–7.
- Shirode, A.B., Kovvuru, P., Chittur, S.V., Henning, S.M., Heber, D., Reliene, R., 2014. Antiproliferative effects of pomegranate extract in MCF-7 breast cancer cells are associated with reduced DNA repair gene expression and induction of double strand breaks. *Mol. Carcinog.* 53, 458–470.
- Srimuangwong, K., Tocharus, C., Tocharus, J., Suksamrarn, A., Chintana, P.Y., 2012. Effects of hexahydrocurcumin in combination with 5-fluorouracil on dimethylhydrazine-induced colon cancer in rats. *World J. Gastroenterol.* 18, 6951–6959.
- Tang, J.M., Min, J., Li, B.S., Hong, S.S., Liu, C., Hu, M., Li, Y., Yang, J., Hong, L., 2016. Therapeutic effects of punicalagin against ovarian carcinoma cells in association with  $\beta$ -Catenin signaling inhibition. *Int. J. Gynecol. Cancer* 26, 1557–1563.
- Tao, L., Kramer, P.M., Wang, W., Yang, S., Lubet, R.A., Steele, V.E., Pereira, M.A., 2002. Altered expression of c-myc, p16 and p27 in rat colon tumors and its reversal by short-term treatment with chemopreventive agents. *Carcinogenesis* 23, 1447–1454.
- Vijay, M., Sivagami, G., Thayalan, K., Nalini, N., 2016. Radiosensitizing potential of rutin against human colon adenocarcinoma HT-29 cells. *Bratisl. Lek. Listy.* 117, 171–178.
- Watson, S.A., Michael, D., Justin, T.A., Grimes, S., Morris, T.M., Robinson, G., Clarke, P.A., Hardcastle, J.D., 1998. Pre-clinical evaluation of the gastrimmune immunogen alone and in combination with 5-fluorouracil/leucovorin in a rat colorectal cancer model. *Int. J. Cancer* 75, 873–877.
- Wen, W., Ding, J., Sun, W., Wu, K., Ning, B., Gong, W., He, G., Huang, S., Ding, X., Yin, P., Chen, L., Liu, Q., Xie, W., Wang, H., 2010. Suppression of cyclin D1 by hypoxia-inducible factor-1 via direct mechanism inhibits the proliferation and 5-fluorouracil-induced apoptosis of A549 cells. *Cancer Res.* 70, 2010–2019.
- Zhao, Y., Miao, G., Li, Y., Isaji, T., Gu, J., Li, J., Qi, R., 2014. Microna 130b suppresses migration and invasion of colorectal cancer cells through downregulation of integrin  $\beta$ 1. *PLoS One* 9, e87938.