

Carotid endarterectomy in conscious patient

Endarterectomia de carótida em paciente acordado

Paulo César SANTOS¹, Hélio Antônio FABRI², Cláudio Ribeiro da CUNHA³, Carlos Alberto da Cunha MARTINS⁴, Jullyanna Sabryna Morais SHINOSAKI⁵, Adriano Silva NEVES⁶, Olair Alves de QUEIROZ⁷, Alexandre Menezes RODRIGUES⁸

RBCCV 44205-796

Abstract

Objective: To evaluate morbidity and mortality of carotid endarterectomy performed under regional cervical block, taking into account duration of surgery, use of shunt, conversion to general anesthesia, surgical complications, stay of patients in the intensive care unit (ICU) and in the hospital, and patients' evolution over one year.

Methods: From June 1998 to January 2004, 67 operations were performed on 61 patients with 70% or greater internal carotid stenosis, diagnosed by Doppler and confirmed by carotid angiography. Neurologic monitoring consisted of continuous assessment of alertness and motor activity of patients during the operation. The mean age was 69.7 years old. Regarding concomitant pathologies, 45 (47%) had hypertension; 21 (22%) coronary artery disease; 17 (18%) diabetes and 12 (13%) pneumopathy.

Results: There were three (4.48%) cases of bilateral carotid disease, for which surgery was performed at different times. The mean duration of surgery was 120 minutes. The use of a shunt was necessary in six (8.95%) cases and to convert to general anesthesia in two (2.98%). Two (2.98%) patients evolved with mental confusion after surgery and one (1.49%) presented infection of surgical site. Restenosis occurred in three (4.48%) cases. The mean times in the ICU and hospital were 1.34 and 4.20 days, respectively. There were no deaths, strokes or acute myocardial infarctions.

Conclusion: Carotid endarterectomy with conscious patients is a good alternative for selected patients at high surgical risk for general anesthesia.

Descriptors: Carotid stenosis, surgery. Endarterectomy, carotid. Cervical plexus. Nerve block.

1 - Cardiovascular surgeon. M.Sc in heart surgery by EPM.
2 - Cardiovascular surgeon
3 - Cardiovascular surgeon
4 - Anesthesiologist
5 - Student.
6 - Student.
7 - Cardiovascular surgeon.
8 - Anesthesiologist.

Work performed in the Instituto do Coração de Uberlândia and Hospital das Clínicas da Universidade Federal de Uberlândia, Uberlândia, MG.
Correspondence address: Paulo César Santos. Av. Getúlio Vargas, 161 - Centro - Uberlândia, MG, Brazil. CEP:38400-000.
E-mail:paulocsantos@mac.com

Article received in October, 2005
Article accepted in January, 2006

Resumo

Objetivo: Avaliar a morbidade e mortalidade da endarterectomia de carótida realizada sob bloqueio cervical regional, tendo como variáveis o tempo cirúrgico, uso de shunt, conversão para anestesia geral, complicações cirúrgicas, tempo de permanência dos pacientes na unidade de tratamento intensivo (UTI) e no hospital, e evolução dos pacientes durante um ano.

Método: Durante o período de junho de 1998 a janeiro de 2004, foram realizadas 67 operações em 61 pacientes, com 70% ou mais de estenose de carótida interna, diagnosticada por Doppler e confirmada por angiografia carotídea. A monitorização cerebral intra-operatória consistiu na análise do nível de consciência e da atividade motora dos pacientes. A média de idade dos pacientes foi 69,7 anos. Quanto às doenças concomitantes, 45 (47%) eram hipertensos; 21 (22%), coronariopatas; 17 (18%), diabéticos; 12 (13%), pneumopatas.

Resultados: Houve três (4,48%) casos de doença carotídea

bilateral, sendo a operação realizada em dois tempos. O tempo médio de operação foi de 120 minutos. Foi necessário uso de shunt em seis (8,95%) casos e conversão para anestesia geral em dois (2,98%). Dois (2,98%) pacientes apresentaram confusão mental no pós-operatório e um (1,49%) apresentou infecção da ferida operatória. Ocorreu reestenose de carótida em três (4,48%) casos. Os tempos médios de permanência na UTI e no hospital foram, respectivamente, 1,34 e 4,20 dias. Não houve morte, acidente vascular cerebral ou infarto agudo do miocárdio.

Conclusão: A endarterectomia de carótida com o paciente acordado é uma boa alternativa para pacientes selecionados de alto risco cirúrgico para anestesia geral.

Descritores: Estenose das carótidas, cirurgia. Endarterectomia das carótidas. Plexo cervical. Bloqueio nervoso.

INTRODUCTION

Since the first successful endarterectomy in 1953 by DeBakey [1], this became the first-line treatment for patients with carotid arterial stenosis as it can be safely performed with low morbidity and mortality rates in high-risk patients [2, 3].

Patients with carotid atherosclerotic disease are mostly elderly and have varying associated comorbidities, a situation that limits surgical treatment, due to the necessity of general anesthesia (GA) invasive monitoring and all the consequences involved. Thus, carotid arterial endarterectomy (CAE) using a regional cervical block is a "minimally invasive" intervention as the reduced bleeding and relatively short time of operation interfere less in the homeostatic mechanisms of the patient [4, 5]

Based on this, we independently evaluated the age and surgical risk, the operative time, the necessity of an intra-operative shunt, conversion rate to GA, surgical complications, times in the intensive care unit (ICU) and in the hospital, evolution at one year of follow-up of patients who underwent CAE, using a regional cervical block in our service.

METHOD

The study was approved by Ethics Committees of the two institutions involved.

Sixty-seven CAE were performed with regional cervical blocks in 61 patients in the period from June of 1998 to January of 2004. All patients presented with internal carotid

stenosis of 70% or more diagnosed by Doppler and confirmed by angiography.

Patients

The ages of the patients varied from 47 to 97 years old, with a mean of 69.7 years; 10 (16.40%) of the patients were octogenarians and 2 (3.28%) were nonagenarians. Other data related to the demographic profile and pre-operative symptoms are shown in Table 1. In respect to the comorbidities, 45 patients suffered from hypertension; 17 from diabetes; 21 from coronary arterial disease and 12 from pneumopathy (Figure 1).

Table 1. Demographic profile and preoperative symptoms of studied patients

| | | Number of cases | Percentage |
|---------------------------|----------------------|-----------------|------------|
| Gender | Male | 30 | 49.18 |
| | Female | 31 | 50.82 |
| Symptoms | Asymptomatic | 18 | 26.86 |
| | Dizziness | 30 | 44.78 |
| | Transitory Amaurosis | 6 | 8.95 |
| | Paresis | 11 | 16.41 |
| Bilateral carotid disease | | 3 | 4.48 |

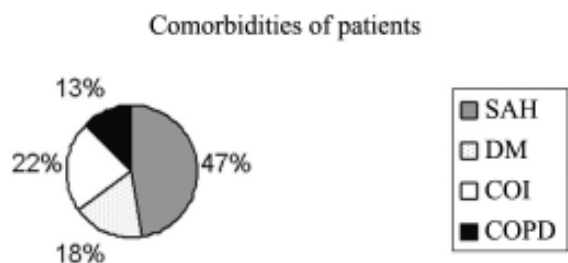


Fig. 1 - Comorbidities presented by the patients. SAH – Systemic arterial hypertension; DM – diabetes mellitus; COI – Coronary insufficiency; COPD – Chronic obstructive pulmonary disease

Anesthetic technique

The anesthetic technique employed was the Labat technique [6]. In dorsal decubitus position the head of the patient is turned to the side. The point of the mastoid process, the transverse process of the 5th cervical vertebra and the anterior tubercle of the 6th cervical vertebra were employed as points of reference in order to locate the ends of the transverse processes of the C2 to C4 vertebrae. Laterally to these processes, intradermic injections of 5 mL of marcaine solution at 0.5% were made followed by an additional subcutaneous infiltration of 15 mL along of posterior edge of the sternocleidomastoid muscle.

Operative technique

A lengthwise cervical incision parallel to the anterior edge of the sternocleidomastoid muscle was performed; internal and external common carotid arteries were individualized and after heparinization were occluded and the neurological conditions of the patient were observed. After that, the plaque was removed by arteriotomy, which was closed using bovine pericardium.

Neurological monitoring was achieved by means of observation of the motor functioning of the contralateral limbs and of the level of conscience, by asking simple questions initiated before the surgery and repeated during the operative course. A shunt was established when there was motor deficits or a drop in the level of consciousness.

After the surgery, the patients were transferred to the ICU. Following the release of the patients from hospital, they were evaluated by the same surgeon 30 days and one year after the surgical procedure when duplex scans of the carotid arteries were performed.

RESULTS

The mean time of surgery was 120 minutes and the mean time of occlusion of the internal carotid artery was 30 minutes.

The surgery was performed on the left artery in 39 (58.20%) cases and on the right in 27 (40.30%). Patients with bilateral carotid disease were submitted to bilateral endarterectomy on two occasions with the symptomatic side operated first. Thirteen (19.40%) patients required coronary artery bypass grafting, which was performed after the carotid procedures.

Conversion to GA was necessary in two cases due to agitation and lack of collaboration of the patients and in six cases the establishment of intra-luminal shunts was necessary, because the patients presented with drops in the level of consciousness and neurological deficits. No deaths, strokes or peri-operative acute myocardial infarcts (AMI) occurred.

Episodes of mental confusion were evidenced in the postoperative periods of two patients as was a case of infection of the operative wound which was successfully treated with oral antibiotic therapy.

In the follow-up period stenosis of the carotid artery due to thrombosis was detected in three cases, two of which were treated by redo endarterectomy and the other, in which bilateral thrombosis occurred, was treated by a redo surgery on one side and angioplasty with stent placement on the other. No deaths, strokes or AMIs were reported during the one-year follow-up period. The complications that occurred are summarized in Table 2.

The mean stays in the ICU and hospital were 1.34 days (range from 1 to 5 days) and 4.20 days (range from 2 to 15 days), respectively.

Table 2. Peri- and post-operative complications presented by analyzed patients

| | Number of cases | Percentage |
|------------------------------|-----------------|------------|
| Death | 0 | 0 |
| Stroke | 0 | 0 |
| Acute myocardial infarction | 0 | 0 |
| Mental confusion | 2 | 2.98% |
| Infection of operative wound | 1 | 1.49% |
| Conversion to GA | 2 | 2.98% |
| Use of peri-operative shunt | 6 | 8.95% |
| Thrombosis of graft | 3 | 4.48% |

GA - General anesthesia

DISCUSSION

Patient inclusion criteria were based on three multicentric studies that demonstrated the efficacy and durability of

surgical reconstruction after carotid atherosclerotic occlusion to be equal to or greater than 70% in preventing strokes [7-9]. In the study of NASCET [7], for stenosis between 70% and 99%, the rate of strokes was 9% in the group that was submitted to endarterectomy and 26% in the clinically treated group, with a reduction in the absolute risk of strokes of $17 \pm 3.5\%$. In the ECST study [8], with the same levels of stenosis, the group treated by endarterectomy presented a rate of strokes (2.8%) approximately 6 times lower when compared to the clinically treated group (16.8%). In the ACAS study [9] of asymptomatic patients with a degree of stenosis greater than 60%, 5.1% of the patients treated by endarterectomy presented with strokes, whilst this rate was 11% in the clinically treated group.

The parameters evaluated in this study were selected with the aim of verifying some of the possible advantages of CAE with regional anesthesia (RA) when compared to GA, as previously reported by several authors. These include more efficient neurological monitoring, reduction in the necessity of intra-operative shunts, lower risks associated to the GA in a high-risk population, greater stability of the arterial pressure with less use of endovenous anti-hypertensive therapy, shorter surgery times, shorter ICU stays, earlier release from hospital and lower rates of peri-operative strokes and cardiovascular complications [4,5,10-14].

The cervical block allowed the continuous monitoring of the neurological state of the patient during surgery. In agreement with Harbaugh & Pikus [5], who reported this to be a surgery better tolerated by totally conscious patients than those under anesthesia, we tried to maintain the minimum anesthesia possible, in order that the evaluation of the level of consciousness was not prejudiced. It is probable that neurological instability is the most accurate predictor of the possibility of strokes after CAE compared to any other previously used technique such as electroencephalography (EEG), the measurement of regional cerebral blood flow, transcranial Doppler, infrared spectroscopy and measurement of the retrograde pressure of the internal carotid artery [4].

A direct consequence of more efficient neurological monitoring of CAE in conscious patients was the possibility of the selective use of shunts, as there are several risks involved in their utilization [10,15]. Due to endothelial dissection of the vessel, the shunt presents a higher risk of severe injury to the intima at the insertion point and a greater probability of thrombosis in the operated area; they can also increase the technical difficulty of the procedure (visualization of the plaque), causing an increase in the arteriotomy and can, also, increase the risk of aerial and atherothrombotic embolization, due to the greater handling of the artery [12, 16, 17].

In spite of elective shunts with EEG monitoring probably being the most common technique used currently, and monitoring based on neurological condition of the patient with RA in second place, it was observed that the false-positive and false-negative results are not uncommon in the shunt technique based on EEG [18]. Moreover, surgery with the patient conscious resulted in the use of shunts in 8.95% of the cases, a rate seen in other works. For the frequencies in the use of shunts in surgeries with RA versus GA the following values were reported: 15% versus 67% [19]; 7.4% versus 17% [18]; 9% versus 39% [3] and 12% versus 52% [14], respectively. Magnadottir et al. [4] used shunts in 6.1% of cases operated on using RA and the lowest rates were registered by Raso et al. [17] who used shunts in 2.7% of cases in surgeries with RA.

In this study a formal analysis of the intra-operative hemodynamical variability was not made, but the use of vasoactive amines was necessary in only two cases. In studies that evaluated the physiological advantages of CAE with RA to the cerebral blood flow showed lower rates of intra-operative hypertension in relation to surgery with GA (8% versus 40%) [11], more hemodynamical instability and a greater necessity of the administration of vasoactive medications in the intra- and post-operative periods in the GA group [13, 14]. In this study, it was also observed that 83% of the patients operated on with GA and 75% of patients who were submitted to RA and who had post-operative complications had presented with severe peri-operative hypertension [14].

In a comparative study of electroencephalograph changes in patients who underwent CAE under GA or RA, it was verified that the best preservation of the ipsilateral cerebral circulation and the greatest tolerance to the effects of carotid clamping with RA is a consequence of the anesthetic technique itself characterizing the AR technique as a cerebral protection factor. This effect may be due to better hemodynamical stability, elimination of the use of other anesthetic medications and preservation of the intrinsic auto-regulation which is perhaps associated to an increase in the intra-operative systemic blood pressure and to the absence of blocking the cerebral perfusion receptors, a fact that is speculated to occur in the GA [19].

Breen & Park [20] recognized that general or regional anesthetic techniques have an influence on the morbidity and mortality of patients, especially in high-risk groups, and the choice of the technique is connected to the results. In the case of CAEs, the authors concluded that the non-randomized studies they analyzed favor regional blocks, due to the reduction in strokes, AMI and death rates, but they warn about the necessity of further randomized studies to better evaluate both anesthetic techniques.

In this study, there were not deaths, strokes or peri- or

post-operative AMI. In a series of 200 patients, Love & Hollyoak [3] did not report deaths or strokes in the first 30 postoperative days. Bowyer et al. [14] noted significantly greater incidences of strokes with GA compared to RA [5.3% versus 1.1%]. Sternbach et al. [13] discovered similar neurological morbidities in both groups, but with lower rates of AMI, congestive heart failure and ventricular arrhythmia in patients who were submitted to RA.

Patients who underwent CAE are frequently elderly with numerous comorbidities. However, there should be a concern that the surgery is minimally invasive, which is achieved with RA. Magnadottir et al. [4] believe that the non-neurological risks inherent to GA and to invasive monitoring can be greater than the risk of the surgical procedure itself in many patients. These authors analyzed 600 CAEs under RA and compared the complications with pre-operative risk factors, such as age over 75 years, diabetes mellitus, coronary artery insufficiency and occlusion of contralateral internal carotid artery, with patients without these risk factors. They did not identify greater peri-operative morbidity rates in the first group of patients. On the contrary, they suggested that RA is a safer technique in respect to cardiopulmonary complications, mainly for higher-risk patients and can have a 13 times lower rate of non-neurological complications than patients who undergo GA.

CAE with RA was seen to be viable and efficient in this study and only 2.98% of the patients requiring conversion to GA. For Bowyer et al. [14], this number was 4.8% and for Love & Hollyoak [3] there was no necessity of conversion.

The occlusion time of the carotid was similar to the other works [4,17] and the total time of surgery was less in comparison to CAE performed under GA in the past in our service, also similar to works by other authors [11,13,14]. The mean time of ICU stay was 1.34 days and the trend is not to routinely refer patients to the ICU, but to carefully monitor them in the recovery room and transfer them to the ICU only when hemodynamically unstable [3,11]. The mean time of hospitalization was also short of around 4 days, comparable to other publications [13,14,17]. These results added to a reduction in the use of intravenous antihypertensive medications and the utilization of shunts, also giving a reduction in costs [11, 14].

McCarthy et al. [21] developed and validated a questionnaire that identified the opinion of the patients in respect to anxiety, satisfaction and tolerance and compared the responses of patients who underwent CAE with RA or with GA. The results showed that the patients had, in general, a positive experience in relation to the CAE, independently of the anesthetic technique employed. However, the perception of recovery, that included the patient's sensations in respect to nausea, anguish, pain, time of stay and return to the day-to-day activities, was significantly in favor of RA.

CONCLUSION

From the satisfactory results obtained in this series in respect to the complications, use of shunts, time of surgery and hospital stay, it was concluded that CAE performed with RA is a safe, minimally invasive technique that is viable for patients with moderate to severe carotid artery stenosis, including the elderly and patients with several comorbidities.

ACKNOWLEDGMENT

The authors wish to thank the staff of Santa Catarina Hospital, Santa Genoveva Hospital and Hospital of the Clinics of Uberlândia and to the Cardiology and Cardiovascular Surgery League of the Federal University of Uberlândia, coordinated by Prof. Dr. Elmiro Santos Resende.

REFERENCES

1. DeBakey ME. Successful carotid endarterectomy for cerebrovascular insufficiency: nineteen-year follow-up. *JAMA*. 1975;233(10):1083-5.
2. Kilaru S, Lee TY, Bush Jr HL, Kent KC. Endarterectomy vs stent angioplasty: what is the optimal treatment of carotid stenosis? *Cardiovasc Surg*. 2002;10(4):366-71.
3. Love A, Hollyoak MA. Carotid endarterectomy and local anaesthesia: reducing the disasters. *Cardiovasc Surg*. 2000;8(6): 429-35.
4. Magnadottir HB, Lightdale N, Harbaugh RE. Clinical outcomes for patients at high risk who underwent carotid endarterectomy with regional anesthesia. *Neurosurgery*. 1999;45(4):786-92.
5. Harbaugh RE, Pikus HJ. Carotid endarterectomy with regional anesthesia. *Neurosurgery*. 2001;49(3):642-5.
6. Collins VJ. *Principles of anesthesiology*. 2a ed. Philadelphia: Lea and Febiger; 1976. p.1671.
7. North American Symptomatic Carotid Endarterectomy Trial Collaborators. Beneficial effect of carotid endarterectomy in symptomatic patients with high-grade carotid stenosis. *N Engl J Med*. 1991;325(7):445-53.

8. European Carotid Surgery Trialists' Collaborative Group. MRC European Carotid Surgery Trial: interim results for symptomatic patients with severe (70-99%) or with mild (0-29%) carotid stenosis. *Lancet*. 1991;337(8752):1235-43.
9. Executive Committee for the Asymptomatic Carotid Atherosclerosis Study. Endarterectomy for asymptomatic carotid artery stenosis. *JAMA*. 1995;273(18):1421-8.
10. Rocha Filho JA. Endarterectomia carotídea. *Cedar - Centro de Estudos de Anestesiologia e Reanimação* 2003;21:4-7.
11. McCarthy RJ, Walker R, McAteer P, Budd JS, Horrocks M. Patient and hospital benefits of local anaesthesia for carotid endarterectomy. *Eur J Vasc Endovasc Surg*. 2001;22(1):13-8.
12. Diaz FG, Velardo B, Johnson R, Malik GM. Carotid endarterectomy: indications and surgical technique. *J Clin Neurosci*. 1994;1(2):98-105.
13. Sternbach Y, Illig KA, Zhang R, Shortell CK, Rhodes JM, Davies MG et al. Hemodynamic benefits of regional anesthesia for carotid endarterectomy. *J Vasc Surg*. 2002;35(2):333-9.
14. Bowyer MW, Zierold D, Loftus JP, Egan JC, Inglis KJ, Halow KD. Carotid endarterectomy: a comparison of regional versus general anesthesia in 500 operations. *Ann Vasc Surg*. 2000;14(2):145-51.
15. Karmeli R, Lubezky N, Halak M, Loberman Z, Weller B, Fajer S. Carotid endarterectomy in awake patients with contralateral carotid artery occlusion. *Cardiovasc Surg*. 2001;9(4):334-8.
16. Cinar B, Goksel OS, Karatepe C, Kut S, Aydogan H, Filizcan U et al. Is routine intravascular shunting necessary for carotid endarterectomy in patients with contralateral occlusion? A review of 5-year experience of carotid endarterectomy with local anaesthesia. *Eur J Vasc Endovasc Surg*. 2004;28(5):494-9.
17. Raso J, Lopes F, Serrano P, Locarno A, Frota EC, Cariri GA. Endarterectomia de carótida sob anestesia local. Evolução de 104 pacientes. *Arq Neuropsiquiatr*. 2004;62(3A):678-81.
18. Illig KA, Sternbach Y, Zhang R, Burchfiel J, Shortell CK, Rhodes JM et al. EEG changes during awake carotid endarterectomy. *Ann Vasc Surg*. 2002;16(1):6-11.
19. McCarthy RJ, Nasr MK, McAteer P, Horrocks M. Physiological advantages of cerebral blood flow during carotid endarterectomy under local anaesthesia: a randomised clinical trial. *Eur J Vasc Endovasc Surg*. 2002;24(3):215-21.
20. Breen P, Park KW. General anesthesia versus regional anesthesia. *Int Anesthesiol Clin*. 2002;40(1):61-71.
21. McCarthy RJ, Trigg R, John C, Gough MJ, Horrocks M. Patient satisfaction for carotid endarterectomy performed under local anaesthesia. *Eur J Vasc Endovasc Surg*. 2004;27(6):654-9.