

# Endovascular repair of ascending aortic dissection

## *Correção endovascular de dissecação de aorta ascendente*

José Carlos Dorsa Vieira Pontes<sup>1</sup>, Amaury Mont'Serrat Ávila Souza Dias<sup>2</sup>, João Jackson Duarte<sup>3</sup>, Ricardo Adala Benfatti<sup>3</sup>, Neimar Gardenal<sup>4</sup>

DOI: 10.5935/1678-9741.20130018

RBCCV 44205-1451

### *Abstract*

Woman, 84 years-old, with Stanford type A thoracic aortic dissection committing aortic arch and descending aorta. Proposed and accepted endovascular treatment according to the severity of the clinical picture. Common femoral artery dissection bilaterally was done. Aortography confirmed the exclusion of the false lumen and patency of the coronary ostia.

**Descriptors:** Aneurysm, dissecting. Endovascular procedures. Stents.

### *Resumo*

Paciente de 84 anos com dissecação de aorta torácica tipo A de Stanford comprometendo todo o arco aórtico e aorta descendente. Proposto e aceito o tratamento endovascular em função da gravidade do quadro clínico. Procedeu-se à dissecação das artérias femorais comum bilateralmente. A aortografia confirmou a exclusão da falsa luz e a patência dos óstios coronarianos.

**Descritores:** Aneurisma dissecante. Procedimentos endovasculares. Stents.

## INTRODUCTION

There is a consensus that the treatment for type A dissections is immediate surgery in order to prevent fatal complications such as cardiac tamponade, aortic rupture, myocardial infarction, acute aortic insufficiency and neurological complications [1]. However, the conventional surgical treatment, with a mortality rate of 10% to 30%, has its own complications arising from surgical trauma, the patient undergoing cardiopulmonary bypass, the extent of the aortic lesion and vessel impairment as well as complications related to the natural progression of the disease. Furthermore, conventional surgical treatment has a high mortality rate when associated with serious systemic diseases such as emphysema, diabetes and renal failure, and advanced age.

Endovascular treatment has been widely used to treat diseases of the thoracic aorta and isolated cases of the endovascular approach for repairing ascending aortic dissection have described in the literature. The present paper describes an endovascular repair of a patient with ascending aortic dissection.

## CASE REPORT

An 84-year-old patient from Mato Grosso do Sul suffering from chest pain and dyspnea was admitted to a hospital in Campo Grande, MS in October, 2011. The patient was diagnosed with chronic obstructive pulmonary disease, diabetes mellitus, decompensated congestive heart failure, pneumonia and chronic renal failure.

1 - Doctorate (Managing Director at Núcleo do Hospital Universitário – Universidade Federal do Mato Grosso do Sul-UFMS)

2 - Specialist in Cardiovascular Surgery

3 - Masters in Cardiovascular Surgery

4 - Masters in Cardiovascular Surgery – Cardiovascular Surgeon

Correspondence address:

José Carlos Dorsa Vieira Pontes

Hospital Universitário-UFMS

Avenida Senador Filinto Muller 355, Vila Ipiranga, Campo Grande, MS, Brazil. Zip code: 79080-190

E-mail: carlosdorsa@uol.com.br

**Abbreviations, acronyms & simbols**

<b>ASD</b>	Atrial Septal Defect
<b>ITU</b>	Intensive Therapy Unit

Chest radiography showed mediastinal enlargement. Bedside echocardiogram showed dilated cardiomyopathy (FE 0.4) in addition to an image typical of ascending aortic dissection.

A CT angiogram was performed showing “Stanford type A aortic dissection compromising the aortic arch and descending aorta” without damage to the supra-aortic branches and the beginning of the dissection at 1.0 cm from the right coronary ostium (Figure 1). No reentry points were observed.

According to the severity of the patient’s clinical picture, conventional surgical treatment was deemed unfeasible due to her comorbidities and a high risk of death (EuroSCORE 83%). Thus, the patient and her relatives consented to the endovascular treatment suggested.

The manufacture of a 40-mm-diameter stent graft, containing an 8-cm covered segment and a 2-cm uncovered free flow segment, was ordered. The uncovered segment allows for increased anchoring area since it is fixed in the aortic arch without the risk of occlusion of its branches. The patient underwent bilateral femoral artery dissection under general anesthesia and in a hemodynamic environment. Since it was an exception and a high risk procedure, the contralateral femoral artery was dissected in case a sudden emergency cardiopulmonary bypass was needed.

The left femoral artery was catheterized to insert the aortography catheter and locate the coronary ostia. The right femoral artery was dissected, exposed, and the guidewire was inserted, with its end passing through the aortic valve and entering the left ventricular chamber. The patient was put under induced hypotension and the stent was placed above the coronary ostia. The coronary ostia were only marked, not catheterized, as to better visualize the correct placement of the stent directly above the right ostium. Therefore, the coronaries were not selected, but rather contracted in the ASD acquisition mode to determine the distance from the right coronary to the dissection entry point. The rigid guidewire was placed inside the left ventricle, since the device had to be in a transvalvular position (Figure 2).

The aortography confirmed the exclusion of the false lumen and the patency of the coronary ostia.

The patient was extubated in the operating room and sent to the ITU.

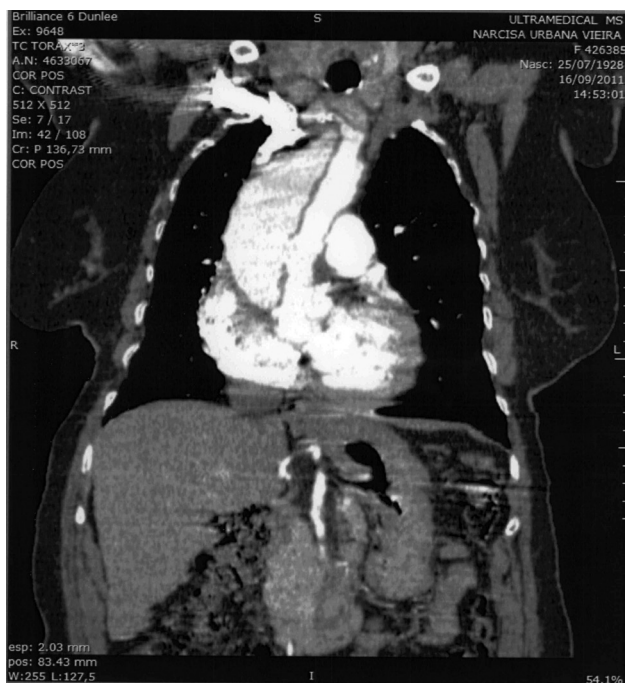


Fig. 1 – Stanford type A thoracic aortic dissection, compromising the aortic arch and the descending aorta

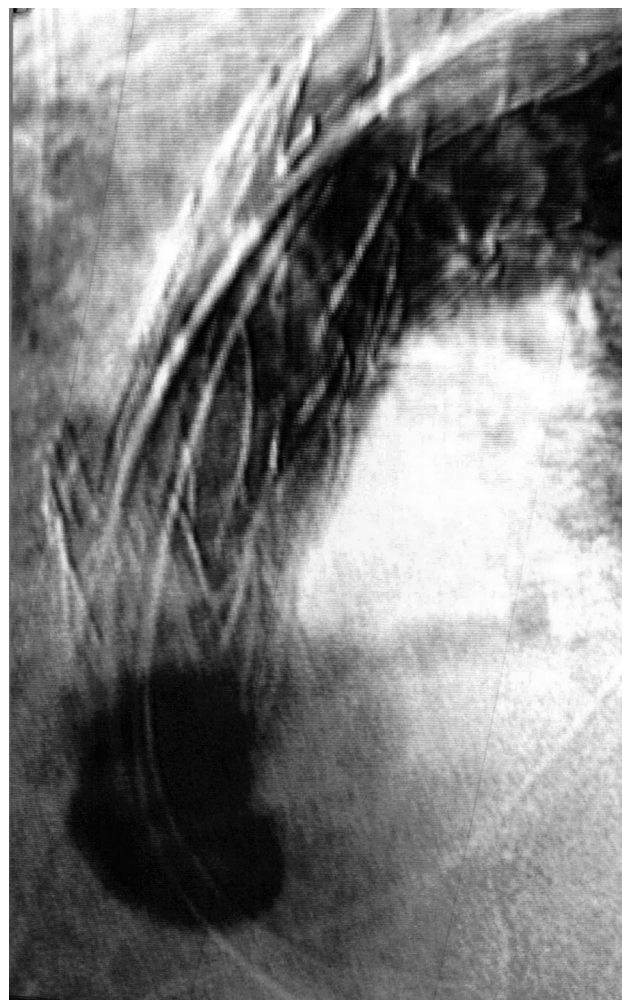

Fig. 2 – Rigid guidewire positioned inside the left ventricle

Patient's progress was satisfactory and she was discharged from the hospital. As requested by the nephrology team, no contrast exams were performed prior to the discharge. During follow-up, since the patient was well and her creatinine clearance was below 25%, imaging exams with contrast were not performed, as they would have been just for control purposes and not for a prescribed medical reason, outweighing cost effectiveness.

## DISCUSSION

The use of a custom-made stent graft has been studied as an alternative approach to ascending aorta lesions, hence, being reserved for patients who are not able to withstand conventional surgery, but still need an immediate solution to this serious aortic disease. Endovascular treatment for aortic diseases is widely used for Stanford type B dissections [1]; however, its use for the treatment of the ascending aorta is a challenge.

The procedure has a highly specific technique that demands preparation, refinement and sharp skills. The first report of the use of a stent graft for Stanford type A aortic dissection was published in October, 2007 [3].

The literature is limited to examples of isolated cases where a stent was used in ascending dissection as part of a hybrid procedure. In 2007, a stent implant was reported; however, the patient was under cardiopulmonary bypass [4]. Recent cases have shown the use of endovascular therapy for ascending aorta in the treatment of pseudo-aneurysms [5]. Recently, in 2012, a case of type A ascending aortic dissection was published, in which the treatment was a stent implant and exclusion of the false lumen.

Our work shows that this technique is feasible and promising, and training of the surgical team is essential to its execution. A well trained surgical team can use this technique to approach complex aortic lesions, such as the one described, with an entry point at 1.0 cm from the coronary ostium.

## CONCLUSION

The surgical outcome depends not only on the training of the team, but also on the attention paid to the stent itself, such as the appropriate radial force used for its setting and non-displacement,

which could compromise, in case of ostial lesions, the occlusion of the false lumen, and obstruct the supra-aortic branches. Endovascular repairs for ascending aorta diseases are still emerging and they are not statistically significant in terms of medium-term mortality rates, as a longer follow-up period of patients who underwent these new procedures is needed to prove their success.

## REFERENCES

1. Albuquerque LC, Braile DM, Palma JH, Saadi EK, Almeida RMS, Gomes WJ, et al. Diretrizes para o tratamento cirúrgico das doenças da aorta da Sociedade Brasileira de Cirurgia Cardiovascular: atualização 2009. *Rev Bras Cir Cardiovasc.* 2009;24(2 supl. 1):7-33.
2. Borst HG, Heinemann MK, Stone CD. *Surgical treatment of aortic dissection.* New York: Churchill Livingstone; 1996. p.357.
3. Senay S, Alhan C, Toraman F, Karabulut H, Dagdelen S, Cagil H. Endovascular stent-graft treatment of type A dissection: case report and review of literature. *Eur J Vasc Endovasc Surg.* 2007;34(4):457-60.
4. Dias RR, Silva IA, Fiorelli AI, Stolf NAG. Tratamento híbrido com endoprótese não recoberta nas disseções agudas da aorta tipo A. *Rev Bras Cir Cardiovasc.* 2007;22(4):495-7.
5. Saadi EK, Moura L, Zago A, Zago A. Endovascular repair of ascending aorta and coronary stent implantation. *Rev Bras Cir Cardiovasc.* 2011;26(3):477-80.