

Thymoquinone protects end organs from abdominal aorta ischemia/reperfusion injury in a rat model

Timoquinona protege órgãos terminais da isquemia/reperfusão da aorta abdominal em modelo com ratos

Mehmet Salih Aydın¹, MD; Aydemir Kocarslan¹, MD; Sezen Kocarslan², MD; Ahmet Kucuk⁴, MD; İrfan Eser⁴, MD; Hatice Sezen⁵, MD; Evren Buyukfirat³, MD; Abdussetmet Hazar¹, MD

DOI 10.5935/1678-9741.20140066

RBCCV 44205-1617

Abstract

Introduction: Previous studies have demonstrated that thymoquinone has protective effects against ischemia reperfusion injury to various organs like lungs, kidneys and liver in different experimental models.

Objective: We aimed to determine whether thymoquinone has favorable effects on lung, renal, heart tissues and oxidative stress in abdominal aorta ischemia-reperfusion injury.

Methods: Thirty rats were divided into three groups as sham (n=10), control (n=10) and thymoquinone (TQ) treatment group (n=10). Control and TQ-treatment groups underwent abdominal aorta ischemia for 45 minutes followed by a 120-min period of reperfusion. In the TQ-treatment group, thymoquinone was given 5 minutes before reperfusion at a dose of 20 mg/kg via an intraperitoneal route. Total antioxidant capacity, total oxidative status (TOS), and oxidative stress index (OSI) in blood serum were measured and lung, kidney, and heart tissue histopathology were evaluated with light microscopy.

Results: Total oxidative status and oxidative stress index activity in blood samples were statistically higher in the control group compared to the sham and TQ-treatment groups ($P<0.001$ for TOS and OSI). Control group injury scores were

statistically higher compared to sham and TQ-treatment groups ($P<0.001$ for all comparisons).

Conclusion: Thymoquinone administered intraperitoneally was effective in reducing oxidative stress and histopathologic injury in an acute abdominal aorta ischemia-reperfusion rat model.

Descriptors: Aorta, Abdominal. Ischemia-Reperfusion Injury. Oxidative Stress.

Resumo

Introdução: Estudos prévios demonstraram que a timoquinona tem efeitos protetores contra a lesão de isquemia/reperfusão em vários órgãos como pulmão, rins e fígado em diferentes modelos experimentais.

Objetivo: Determinar se timoquinona tem efeitos positivos em tecidos do pulmão, rim e coração e no estresse oxidativo em lesão de isquemia/perfusão da aorta abdominal.

Métodos: Trinta ratos foram divididos em três grupos: sham (n=10), controle (n=10) e tratamento com timoquinona (TQ) (n=10). Os grupos controle e de tratamento com TQ foram

¹Harran University Faculty of Medicine, Department of Cardiovascular Surgery, Sanliurfa, Turkey.

²Harran University Faculty of Medicine, Department of Pathology, Sanliurfa, Turkey.

³Harran University Faculty of Medicine, Department of Anesthesiology and Reanimation, Sanliurfa, Turkey.

⁴Harran University Faculty of Medicine, Department of Thoracic Surgery, Sanliurfa, Turkey.

⁵Harran University Faculty of Medicine, Department of Biochemistry, Sanliurfa, Turkey.

No financial support.

This study was carried out at Harran University Faculty of Medicine, Department of Cardiovascular Surgery, Sanliurfa, Turkey.

Correspondence address:

Mehmet Salih Aydın

Department of Cardiovascular Surgery, Harran University Faculty of Medicine 63000 Sanliurfa, Turkey

E-mail: drmsalihaydin@gmail.com

Article received on February 19th, 2014

Article accepted on March 31st, 2014

Abbreviations, acronyms & symbols	
I/R	Ischemia-Reperfusion
OSI	Oxidative Stress Index
ROS	Reactive Oxygen Species
TAC	Total Antioxidant Capacity
TOS	Total Oxidant Status
TQ	Thymoquinone

submetidos à isquemia da aorta abdominal durante 45 minutos, seguido por um período de 120 minutos de reperfusão. No grupo de tratamento com TQ, a timoquinona foi administrada 5 minutos antes da reperfusão, dose de 20 mg/kg através da via intraperitoneal. A capacidade total antioxidante, estado oxidativo total (TOS) e o índice de estresse oxidativo (OSI) no soro

do sangue foram medidos, e a histopatologia dos tecidos do pulmão, rim e coração foram avaliados com microscopia de luz.

Resultados: Estado oxidativo e índice de estresse oxidativo total em amostras de sangue foram estatisticamente mais altos no grupo controle em relação aos grupos sham e tratamento com TQ ($P<0,001$ para TOS e OSI). Escores de lesões no grupo controle foram estatisticamente mais altos em relação aos grupos sham e tratamento com TQ ($P<0,001$ para todas as comparações).

Conclusão: A timoquinona administrada por via intraperitoneal foi eficaz na redução do estresse oxidativo e lesão histopatológica em modelo de rato de isquemia/reperfusão aguda da aorta abdominal.

Descritores: Aorta Abdominal. Isquemia Traumática por Reperfusão. Estresse Oxidativo.

INTRODUCTION

Acute abdominal aorta ischemia followed by reperfusion may be encountered in several clinical circumstances, such as abdominal aortic aneurysm or dissection repair, acute thromboembolism with aortic atherosclerosis, or trauma surgery being brought to the emergency room. Such clinical scenarios are associated with high mortality and morbidity rates due to a systemic inflammatory response and multiple organ dysfunction occurring during the reperfusion phase. Reperfusion of an acutely ischemic aorta may, paradoxically, lead to systemic complications that account for significant morbidity and mortality^[1,2]. Overproduction of reactive oxygen species (ROS) and proinflammatory molecules and the subsequent inflammatory response is one of the most crucial underlying mechanisms^[2] that initiates injury, especially in the lungs and vital organs, such as kidney and heart, with a subsequent high morbidity^[1-4].

Thymoquinone (TQ; 2-isopropyl-5-methyl-1, 4-benzoquinone), the active constituent of *Nigella sativa* seeds, is a pharmacologically active quinone that has been shown to have pharmacological actions, such as antibacterial^[5], antihypertensive^[6], antidiabetic^[7], neuroprotective^[8], anti-inflammatory^[9] and antiapoptotic^[10] as well as, in some studies, apoptotic^[11,12].

It has been reported that TQ prevents oxidative injury in various in vitro and in vivo studies^[13,14]. TQ possesses strong antioxidant properties through its ability to scavenge different free radicals^[15,16]. It has also been reported that TQ attenuated several organ injuries (lung, renal, hepatic) in different ischemia-reperfusion (I/R) models (renal, hepatic). However, no studies have evaluated the protective effects of TQ in an aorta I/R model^[17-20].

The purpose of this study was to determine the efficacy of TQ in preventing injury in vital organs (lung, heart and kidney) in an acute abdominal aorta ischemia-reperfusion model in rats.

METHODS

The experimental study was performed on a total of 30 three-month-old Wistar-albino rats weighing 200–250 g. All animals were maintained under standard conditions and treated in compliance with National Institutes of Health guidelines. They were housed on a 12-h dark/light cycle schedule with lights on at 06.00 h. Rats were deprived of food, though not water, for 12 hours before surgery. Experiments were done in the Harran University Experimental Research Center. The rats were randomly assigned to three experimental groups: sham operation, control (I/R; non-treated), and TQ-treated I/R. Rats were anesthetized using ketamine hydrochloride (0.2mL/100 g) in all experiments. The abdomen was explored through a midline incision after shaving and disinfection. In the sham group, only laparotomy was performed. In the control group, I/R injury was induced by clamping the aorta under renal vascular pedicles for 45 minutes, followed by 2 hours of reperfusion. In the TQ-treated I/R group, I/R injury was also induced by clamping the aorta under renal vascular pedicles for 45 minutes and TQ was given 5 minutes before reperfusion at a dose of 20 mg/kg via the intraperitoneal route, and again reperfusion was established for 2 hours. Heparin was not used due to possibility of affecting histopathological or biochemical results. At the end of the procedures, the rats were sacrificed after blood sampling, and then kidney, lung, and heart tissues were obtained from all rats.

TQ were purchased from Sigma–Aldrich (St. Louis, MO). The purity (GC) of TQ was $\geq 98.5\%$ as per the manufacturer's specification and was dissolved in dimethyl sulphoxide.

Biochemical Analyses

Measurement of Total Antioxidant Capacity

TAC of supernatant fractions was determined using a novel automated measurement method developed by Erel^[21].

Hydroxyl radicals, the most potent biological radicals, are produced in this method. In the assay, the ferrous ion solution present in Reagent 1 is mixed with hydrogen peroxide, which is present in Reagent 2. The subsequently produced radicals, such as brown-colored dianisidiny radical cations produced by the hydroxyl radicals, are also potent radicals. Using this method, the antioxidative effect of the sample was measured against the potent-free radical reactions initiated by the produced hydroxyl radicals. The assay has excellent precision, with values lower than 3%. The results are expressed as nmolTrolox Equiv./mg protein.

Measurement of Total Oxidant Status

TOS of supernatant fractions was determined using a novel automated measurement method developed by Erel^[22]. Oxidants present in the sample oxidize the ferrous ion–o-dianisidine complex to ferric ion. The oxidation reaction is enhanced by glycerol molecules, which are abundant in the reaction medium. The ferric ion produces a colored complex with xylenol orange in an acidic medium. The color intensity, which can be measured spectrophotometrically, is related to the total amount of oxidant molecules present in the sample. The assay was calibrated with hydrogen peroxide, and the results are expressed in terms of nmol H₂O₂ Equiv/mg protein.

Oxidative Stress Index

The percent ratio of TOS level to TAC level was defined as OSI. OSI values were calculated according to the following formula^[23]:

$$OSI \text{ (arbitrary unit)} = \frac{TOS \text{ (nmol H}_2\text{O}_2 \text{ Equiv/mg protein)}}{TAC \text{ (nmolTroloxEquiv/mg protein)}}$$

Histopathological Evaluation

The kidney, lung, and heart of each animal were obtained for histological evaluation. Samples of these organs were placed in formalin and embedded in wax according to standard protocols. They were subsequently sectioned at 5 μm slice thickness and stained with hematoxylin and

eosin. Magnification of × 20 was used (Olympus BX51 TF, USA). Samples were then graded histologically according to the severity of injury using a predetermined scoring system^[24]. The predetermined scoring system, from Solez et al.^[24], included tubular necrosis, interstitial edema, loss of brush border, and cast formation, in which the score was 0 for absent; 1 for mild to moderate; and 2 for marked renal involvement. The histological parameters for lung evaluation were alveolar congestion, intra-alveolar hemorrhage, and interstitial-perivascular infiltration of neutrophils, in which the assessment score was 0 for absent; 1 for mild focal; 2 for moderate focal; and 3 for severe marked lung involvement. Interstitial edema, inflammatory cell infiltration, and coagulation necrosis were assessed for heart examination, in which the score was 0 for absent; 1 for mild focal; 2 for moderate focal; and 3 for severe marked heart involvement. Histological analysis was performed by a blinded expert.

Statistical Analysis

Statistical analyses were performed using SPSS 11.5 (SPSS for Windows 11.5, Chicago, IL). Continuous data are expressed as mean±SD whereas categorical variables are presented as number (count) and percentage. Distribution of continuous variables was assessed with one-sample Kolmogorov-Smirnov test and indicated that all variables were abnormally distributed. Therefore, nonparametric independent group comparisons were made: for multiple comparisons, the Kruskal-Wallis test was used, and for comparisons between groups, the Mann-Whitney test was used if any statistical significance was found. A two-sided P value of <0.05 was considered statistically significant.

RESULTS

All animals survived through the experimental protocol. TAC activity in blood samples were significantly higher in the sham group than in the treatment and control groups

Table 1. Oxidative and antioxidative parameters and histopathological evaluation in Sham, Control and TQ + I/R rats.

	Sham (n=10)	Control (n=10)	TQ+I/R (n=10)	P
TAC (nmolTroloxEquiv/mg protein)	1.39±0.18*	0.53±0.12	0.65±0.12	P<0.001
TOS (nmol H ₂ O ₂ Equiv./ mg protein)	28.3±8.5	44.1±8.1 ⁺	25.8±2.3	P<0.001
OSI (arbitrary units)	2.0±0.44	8.35±1.23 ⁺	1.30±0.41	P<0.001
Renal Pathology score	1.7±1.25	4.4±0.69 ⁺	2.1±1.37	P<0.001
Lung Pathology score	1.7±1.15	4.6±0.51 ⁺	3.0±1.24	P<0.001
Heart Pathology score	0.3±0.48	1.5±0.52 ⁺	0.9±0.73	P<0.001

TAC=Total Antioxidant Capacity; TOS=Total Oxidant Status; OSI=Oxidative Stress Index

P<0.05 was considered as statistically significant.

* P<0.001 (for all comparisons) compared with I/R and TQ+I/R

+ P<0.001 (for all comparisons) compared with sham and TQ+I/R

($P < 0.001$; for all comparisons) but there were no statistically significant differences between the treatment group and control group for TAC activity ($P > 0.05$). TOS and OSI activity in blood samples were statistically higher in the control group than in the sham and thymoquinone group ($P < 0.001$ for all comparisons). Histopathologic injury scores of renal, lung and heart tissues are summarized in Table 1. Control group injury scores were statistically increased compared to sham and thymoquinone groups ($P < 0.001$ for all comparisons). The results are summarized in Figures 1, 2, and 3.

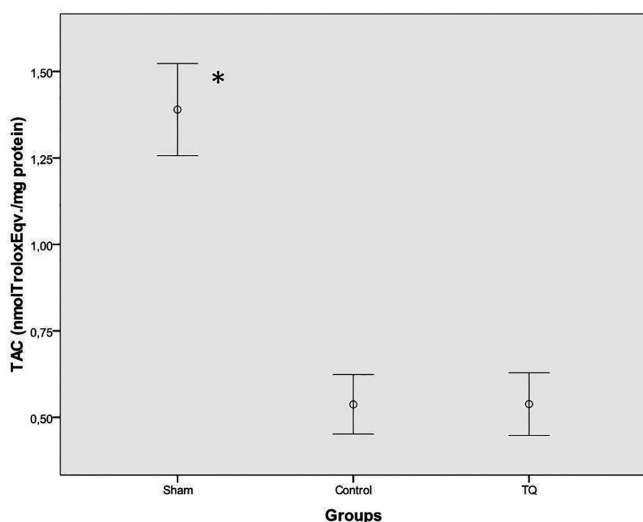


Fig. 1 - TAC levels for sham, control, and thymoquinone groups. * $P < 0.001$ (for all comparisons) compared with I/R and I/R+TQ

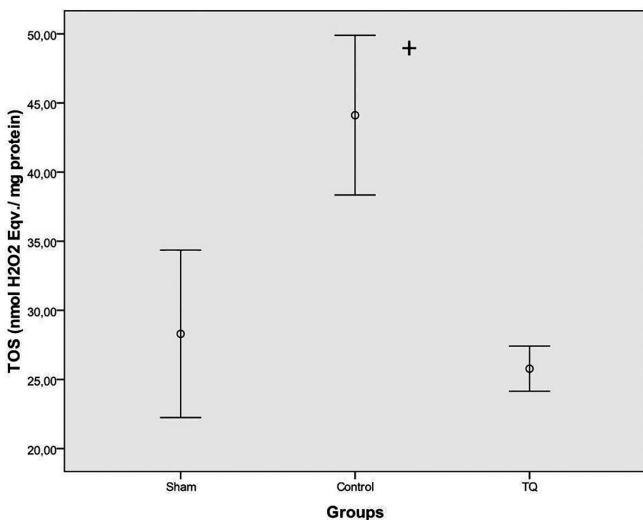


Fig. 2 - TOS levels in sham, control, and thymoquinone groups. + $P < 0.001$ (for all comparisons) compared with sham and thymoquinone groups

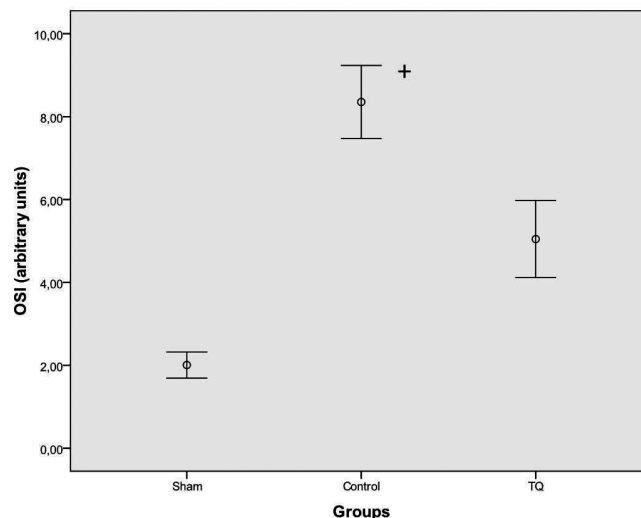


Fig. 3 - OSI levels in sham, control, and thymoquinone groups. + $P < 0.001$ (for all comparisons) compared with sham and thymoquinone groups

Upon histopathological evaluation, renal, lung and heart tissues were found to be normal with no pathological changes in the sham group (Figures 4A and 4D). Histopathological examination of the tissues in the control group revealed severe lesions, such as tubular damage characterized by cast formation, the loss of brush border and interstitial edema in the kidney. Histopathological examination of the tissues in the control group revealed neutrophil and leukocyte infiltration with alveolar congestion in the lung. Histopathological examination of the tissues in the control group revealed interstitial edema in the heart (Figures 4B and 4E). In rats receiving TQ intraperitoneally, these lesions were less severe than in the control group (Figures 4C and 4F).

DISCUSSION

In our experimental study, we hypothesized that abdominal aorta ischemia for 45 minutes followed by reperfusion for 2 hours would cause renal, lung, and heart pathology and we have found that (i) abdominal aorta ischemia for 45 minutes followed by reperfusion for 2 hours caused significant pathology in lung, renal, and heart tissues (ii) TOS and OSI levels were increased in the control group and (iii) TOS, OSI, and histopathological injury scores were decreased in sham and TQ+IR groups.

It has been recognized that multiple organ dysfunction syndrome is a major cause of morbidity and mortality after abdominal aortic surgery and contributes to approximately 25% of all deaths in elective abdominal aorta repair. It is postulated that aortic cross-clamping during open repair may cause ischemia-reperfusion (I/R) injury of the intestine and subsequently result in the translocation of bacteria and

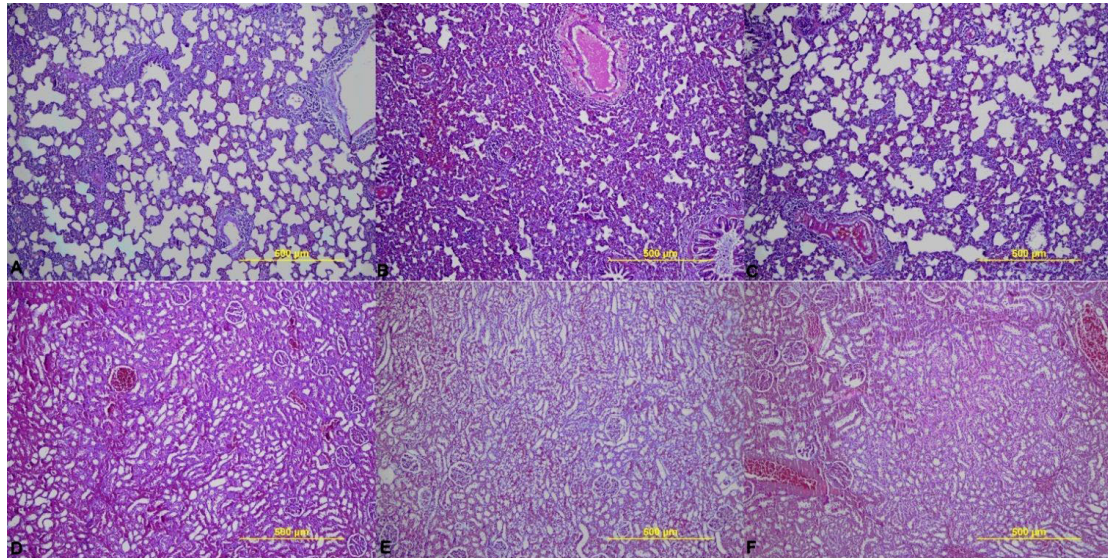


Fig. 4 - A and D show renal and lung tissues samples of the sham group and there were no pathological changes. B) shows lung tissues samples of control group and neutrophil and leukocyte infiltration with alveolar congestion were observed. E) shows renal tissues samples of control group and tubular damage characterized by cast formation; the loss of brush border and interstitial edema were observed. C and F show lung and renal tissues samples of thymoquinone treated group and there were less severe lesions than in the control group.

endotoxin across the intestinal mucosal barrier, leading to the systemic release of reactive oxygen species (ROS) and inflammatory cytokines, which not only damage the gut itself but also harm distant organs, including heart, kidney, and lung^[25].

Nigella sativa (NS), also known as black seed or black cumin, has long been used in folk medicine. NS contains more than 30% of a fixed oil and 0.40-0.45 w/w of a volatile oil. The volatile oil has been shown to contain 18-24% thymoquinone (TQ) and 46% monoterpenes^[7]. NS has been reported to exhibit anti-inflammatory, immunomodulatory, and anti-neoplastic effects in many experimental and clinical studies^[26-28]. TQ, the active constituent of *Nigella sativa* seeds similar to NS, also showed favorable effects with respect to oxidative stress and inflammation. Thus, TQ has attracted the attention of scientists to investigate its molecular mechanisms and potential use in the treatment of different diseases. It has been shown to have antioxidant/anti-inflammatory effects in several diseases, including experimental allergic encephalomyelitis, colitis, arthritis encephalomyelitis, diabetes, asthma, and carcinogenesis^[10]. TQ attenuated lipid peroxidation and increased antioxidant enzyme activities. It has been reported to have strong antioxidant potential through its ability to scavenge different free radicals, its scavenging power being as effective as SOD against superoxide anions^[16-18]. It acts as a scavenger of superoxide, hydroxyl radicals and singlet molecular oxygen^[29]. Furthermore, recent studies have demonstrated that TQ supplementation increases

the expression of antioxidant genes, SOD, catalase and glutathione peroxidase in rat liver. Thus, TQ may reduce oxidative stress through a direct antioxidant effect as well as through the induction of endogenous antioxidant enzymes^[30].

TQ also inhibited inducible nitric oxide synthase mRNA expression in rat lipopolysaccharide-stimulated peritoneal macrophage cells^[31,32], which has been attributed to its ability to reduce oxidative stress-induced inflammation leading to the prevention of inducible NOS (nitric oxide synthase) upregulation.

Several studies reported protective effects in the lung in different situations with different mechanisms. Suddek et al. showed that TQ produces a protective mechanism against cisplatin-induced pulmonary damage with anti-oxidant and anti-inflammatory properties and, in addition, TQ has been found to have potential antifibrotic effects besides its antioxidant activity, which could be through NF- κ B inhibition, in bleomycin-induced oxidative stress of rat lungs^[20,33]. Renal protective effects of TQ have also been discussed in several studies, including vancomycin induced nephrotoxicity, inorganic mercury intoxication, and gentamicin-induced acute renal toxicity. These studies highlight the importance of reactive oxygen species in renal pathophysiology and the intriguing possibility of TQ play a role in the prevention of and/or protection from renal injury in humans^[17,34-36]. Myocardial protective effects of TQ have also been demonstrated in injury induced by isoproterenol, cyclophosphamide-induced cardiotoxicity, and doxorubicin-induced cardiotoxicity^[37-39]. TQ

has also been widely studied in different ischemia reperfusion models and reported to have favorable effects with different potential mechanisms, including primarily antioxidant mechanisms^[18,40]. In this study we also found protective effects of TQ in the lung, kidney, and heart with histopathologic evaluation. Significant oxidative stress in the control group compared to sham and TQ groups also emphasizes that the anti-oxidant properties of TQ might be the probable protective mechanism in the acute abdominal aorta ischemia-reperfusion model in the rat.

We believe that there are sufficient preclinical research results with a considerable amount of information about TQ regarding its molecular antioxidant, anti-inflammation, anti-cancer activity, drug toxicity, bioavailability and pharmacokinetics, and novel drug delivery approaches, to encourage the use of TQ in clinical settings^[41]. However, the clinical implications and appropriate pathophysiological mechanisms of the findings of the present study remain to be elucidated with further large-scale clinical studies.

Several limitations of this study should be considered. One of the potential limitations is the absence of oral administration of TQ versus an intraperitoneal route. Another limitation is the absence of biochemical analysis of different biochemical markers, including urea, creatinine, creatinine phosphokinase and creatinine kinase MB for the heart. Further studies focusing on IR injury of other end organs, such as intestine, brain and medulla spinalis injury are needed.

CONCLUSION

In conclusion, TQ administered intraperitoneally was effective in reducing oxidative stress and histopathologic injury in an acute abdominal aorta I/R rat model. Oxidative stress indices and tissue injuries might be modified with TQ treatment in different clinical settings. However, further large scale studies are needed to define the possible favorable effects of TQ in clinical settings.

Authors' roles & responsibilities	
MSA	Analysis and /or interpretation of data, statistical analysis, final approval of the manuscript conception and study design, conduct of procedures, and/or experiments, writing of the manuscript or review of its content
AK	Analysis and/or interpretation of data, final approval of manuscript
SK	Statistical analysis, conception and study design, conduct of procedures, and/or experiments
AK	Conduct of procedures and/or experiments, writing of the manuscript or review of its content
IE	Statistical analysis, final approval of manuscript
HS	Statistical analysis, final approval of the manuscript, conception and study design, conduct of procedures, and/or experiments
EB	Statistical analysis, final approval of the manuscript, drafting the manuscript or revising it critically for its content
AH	Drafting of the manuscript or review of its content

REFERENCES

1. Yassin MM, Harkin DW, Barros D'Sa AA, Halliday MI, Rowlands BJ. Lower limb ischemia-reperfusion injury triggers a systemic inflammatory response and multiple organ dysfunction. *World J Surg.* 2002;26(1):115-21.
2. Carvalho AC, Guillaumon AT, Cintra EdeA, Figueiredo LC, Moreira MM, Araújo S. Plasmatic vasopressin in patients undergoing conventional infra-renal abdominal aorta aneurysm repair. *Rev Bras Cir Cardiovasc* 2011;26(3):404-12
3. Harkin DW, Barros D'sa AA, Mccallion K, Hoper M, Halliday MI, Campbell FC. Circulating neutrophil priming and systemic inflammation in limb ischaemia-reperfusion injury. *IntAngiol* 2001;20(1):78-89.
4. Groeneveld AB, Rajmakers PG, Rauwerda JA, Hack CE. The inflammatory response to vascular surgery-associated ischaemia and reperfusion in man: effect on postoperative pulmonary function. *Eur J Vasc Endovasc Surg* 1997;14(5):351-9.
5. Hanafy MS, Hatem ME. Studies on the antimicrobial activity of *Nigella sativa* seed (black cumin). *J Ethnopharmacol.* 1991;34(2-3):275-8.
6. el-Tahir K, Ashour M, al-Harbi M. The cardiovascular actions of the volatile oil of the black seed (*Nigella sativa*) in rats: elucidation of the mechanism of action. *Gen Pharmacol* 1993;24(5):1123-31.
7. Kanter M. Effects of *Nigella sativa* and its major constituent, thymoquinone on sciatic nerves in experimental diabetic neuropathy. *Neurochem Res.* 2008;33(1):87-96.
8. Al-Majed AA, Al-Omar FA, Nagi MN. Neuroprotective effects of thymoquinone against transient forebrain ischemia in the rat hippocampus. *Eur J Pharmacol.* 2006;543(1-3):40-7.
9. Mutabagani A, El-Mahdy SA. Study of the anti-inflammatory activity of *Nigella sativa* L. and thymoquinone in rats. *Saudi Pharm J.* 1997;5(2-3):110-3.
10. Woo CC, Kumar AP, Sethi G, Tan KH. Thymoquinone: potential cure for inflammatory disorders and cancer. *Biochem Pharmacol.* 2012;83(4):443-51.
11. Wirries A, Breyer S, Quint K, Schobert R, Ocker M. Thymoquinone hydrazone derivatives cause cell cycle arrest in p53-competent colorectal cancer cells. *Exp Ther Med.* 2010;1(2):369-75.
12. Roepke M, Diestel A, Bajbouj K, Walluscheck D, Schonfeld P, Roessner A, et al. Lack of p53 augments thymoquinone-induced apoptosis and caspase activation in human osteosarcoma cells. *Cancer Biol Ther.* 2007;6(2):160-9.
13. Suguna P, Geetha A, Aruna R, Siva GV. Effect of thymoquinone on ethanol and high fat diet induced chronic pancreatitis--a dose response study in rats. *Indian J Exp Biol.* 2013;51(4):292-302.
14. Rifaioğlu MM, Nacar A, Yuksel R, Yonden Z, Karcioğlu M, Zorba OU, et al. Antioxidative and anti-inflammatory effect of thymo-

- quinone in an acute pseudomonas prostatitis rat model. *Urol Int*. 2013;91(4):474-81.
15. Selçuk CT, Durgun M, Tekin R, Yolbas L, Bozkurt M, Akçay C, et al. Evaluation of the effect of thymoquinone treatment on wound healing in a rat burn model. *J Burn Care Res*. 2013;34(5):e274-81.
16. Badary OA, Taha RA, Gamal el-Din AM, Abdel-Wahab MH. Thymoquinone is a potent superoxide anion scavenger. *Drug Chem Toxicol*. 2003;26(2):87-98.
17. Fouda AM, Daba MH, Dahab GM, Sharaf El-Din OA. Thymoquinone ameliorates renal oxidative damage and proliferative response induced by mercuric chloride in rats. *Basic Clin Pharmacol Toxicol*. 2008;103(2):109-18.
18. Awad AS, Kamel R, Sherief MA. Effect of thymoquinone on hepatorenal dysfunction and alteration of CYP3A1 and spermidine/spermine N-1-acetyl-transferase gene expression induced by renal ischemia reperfusion in rats. *J Pharm Pharmacol*. 2011;63(8):1037-42.
19. Abd El-Ghany RM, Sharaf NM, Kassem LA, Mahran LG, Heikal OA. Thymoquinone triggers anti-apoptotic signaling targeting death ligand and apoptotic regulators in a model of hepatic ischemia reperfusion injury. *Drug Discov Ther*. 2009;3(6):296-306.
20. Suddek GM, Ashry NA, Gameil NM. Thymoquinone attenuates cyclophosphamide-induced pulmonary injury in rats. *Inflammopharmacology*. 2013;21(6):427-35.
21. Erel O. A novel automated method to measure total antioxidant response against potent free radical reactions. *Clin Biochem*. 2004;37(2):112-9.
22. Erel O. A new automated colorimetric method for measuring total oxidant status. *Clin Biochem*. 2005;38(12):1103-11.
23. Bolukbas C, Bolukbas FF, Horoz M, Aslan M, Celik H, Erel O. Increased oxidative stress associated with the severity of the liver disease in various forms of hepatitis B virus infection. *BMC Infect Dis*. 2005;5:95.
24. Solez K, Morel-Maroger L, Sraer JD. The morphology of "acute tubular necrosis" in man: analysis of 57 renal biopsies and a comparison with the glycerol model. *Medicine (Baltimore)*. 1979;58(5):362-76.
25. Li C, Li YS, Xu M, Wen SH, Yao X, Wu Y, et al. Limb remote ischemic preconditioning for intestinal and pulmonary protection during elective open infrarenal abdominal aortic aneurysm repair: a randomized controlled trial. *Anesthesiology*. 2013;118(4):842-52.
26. Ammar el-SM, Gameil NM, Shawky NM, Nader MA. Comparative evaluation of anti-inflammatory properties of thymoquinone and curcumin using an asthmatic murine model. *Int Immunopharmacol*. 2011;11(12):2232-6.
27. Keyhanmanesh R, Boskabady MH, Khamneh S, Doostar Y. Effect of thymoquinone on the lung pathology and cytokine levels of ovalbumin-sensitized guinea pigs. *Pharmacol Rep*. 2010;62(5):910-6.
28. Yildiz F, Coban S, Terzi A, Savas M, Bitiren M, Celik H, et al. Protective effects of *Nigella sativa* against ischemia-reperfusion injury of kidneys. *Ren Fail*. 2010;32(1):126-31.
29. Mansour MA, Nagi MN, El-Khatib AS, Al-Bekairi AM. Effects of thymoquinone on antioxidant enzyme activities, lipid peroxidation and DT-diaphorase in different tissues of mice: a possible mechanism of action. *Cell Biochem Funct*. 2002;20(2):143-51.
30. Ismail M, Al-Naqeep G, Chan KW. *Nigella sativa* thymoquinone-rich fraction greatly improves plasma antioxidant capacity and expression of antioxidant genes in hypercholesterolemic rats. *Free Radic Biol Med*. 2010;48(5):664-72.
31. Nagi MN, Almakki HA, Sayed-Ahmed MM, Al-Bekairi AM. Thymoquinone supplementation reverses acetaminophen-induced oxidative stress, nitric oxide production and energy decline in mice liver. *Food Chem Toxicol*. 2010;48(8-9):2361-5.
32. El-Mahmoudy A, Matsuyama H, Borgan MA, Shimizu Y, El-Sayed MG, Minamoto N, et al. Thymoquinone suppresses expression of inducible nitric oxide synthase in rat macrophages. *Int Immunopharmacol*. 2002;2(11):1603-11.
33. El-Khouly D, El-Bakly WM, Awad AS, El-Mesallamy HO, El-De-merdash E. Thymoquinone blocks lung injury and fibrosis by attenuating bleomycin-induced oxidative stress and activation of nuclear factor Kappa-B in rats. *Toxicology*. 2012;302(2-3):106-13.
34. Basarslan F, Yilmaz N, Ates S, Ozgur T, Tutanc M, Motor VK, et al. Protective effects of thymoquinone on vancomycin-induced nephrotoxicity in rats. *Hum Exp Toxicol*. 2012;31(7):726-33.
35. Ragheb A, Attia A, Eldin WS, Elbarbry F, Gazarin S, Shoker A. The protective effect of thymoquinone, an anti-oxidant and anti-inflammatory agent, against renal injury: a review. *Saudi J Kidney Dis Transpl*. 2009;20(5):741-52.
36. Sayed-Ahmed MM, Nagi MN. Thymoquinone supplementation prevents the development of gentamicin-induced acute renal toxicity in rats. *Clin Exp Pharmacol Physiol*. 2007;34(5-6):399-405.
37. Nagi MN, Mansour MA. Protective effect of thymoquinone against doxorubicin-induced cardiotoxicity in rats: a possible mechanism of protection. *Pharmacol Res*. 2000;41(3):283-9.
38. Nagi MN, Al-Shabanah OA, Hafez MM, Sayed-Ahmed MM. Thymoquinone supplementation attenuates cyclophosphamide-induced cardiotoxicity in rats. *J Biochem Mol Toxicol*. 2011;25(3):135-42.
39. Randhawa MA, Alghamdi MS, Maulik SK. The effect of thymoquinone, an active component of *Nigella sativa*, on isoproterenol induced myocardial injury. *Pak J Pharm Sci*. 2013;26(6):1215-9.
40. Gökçe A, Oktar S, Koc A, Gonenci R, Yalcinkaya F, Yonden Z, Duru M. Protective effect of thymoquinone in experimental testicular torsion. *Urol Int*. 2010;85(4):461-5.
41. Abukhader MM. Thymoquinone in the clinical treatment of cancer: Fact or fiction? *Pharmacogn Rev*. 2013;7(14):117-20.