

## Hysteroscopy and the butyl-cyanoacrylate on experimental sterilization of rabbit uterine tubes<sup>1</sup>

### Butil-cianoacrilato e histeroscopia na esterilização experimental de tubas uterinas de coelhas

Henri Chaplin Rivoire<sup>2</sup>, Djalma José Fagundes<sup>3</sup>, Sergio Bigolin<sup>4</sup>, Anna Tereza Negrini Fagundes<sup>5</sup>

1. Research performed at Department of Surgery, Postgraduate Surgery and Experimentation Program, Federal University of São Paulo (UNIFESP), São Paulo, Brazil.
2. PhD, Associate Professor, Department of Surgery, Head Rio Grande Federal Foundation University, Rio Grande, RS, Brazil.
3. PhD, Associate Professor, Department of Surgery, UNIFESP, São Paulo, Brazil.
4. Master, Assistant Professor, University Regional Integrada do Alto Uruguai (URI), Erechim, RS, Brazil.
5. Medical Student, Santo Amaro University (UNISA), São Paulo, Brazil.

---

#### ABSTRACT

**Purpose:** To assess the sterilization effectiveness on uterine tube of rabbit by the cyanoacrylate adhesive. **Methods:** Hysteroscopy tubal catheterization was performed randomly in 12 animals (24 uterine tubes) assigned to the sham group (GS) and 15 animals (30 uterine tubes) to the n-butyl-cyanoacrylate (GB). The female rabbits were observed during 30, 90 and 180 days and mated to fertile males. The no pregnant rabbits were submitted to in vitro burst pressure test for patency by air insufflation (40 mmHg). The microscopic assessment was performed to parameters of damages in epithelium caused by the adhesive, the degree of inflammatory process, morphometry data values of tube diameter (UT) (cm), mucosa thickness (MT) and the myosalpinx thickness (MyT) (mm). The mucosa cells densitometry (total optical density) was expressed by the amount of DNA. The significance of the differences in histological scores and in thickness measurements were made by ANOVA test (P value < 0.05). **Results:** In all animals of GB: the adhesive was attached to the mucosa; there was no pregnancy; no records of significant degree on inflammatory process; the patency test was negative and densitometry of DNA showed similar values to the both groups independently of observation periods. The layers thickness of GB-UT(1.118±0.117), GB-MT(0.447±0.247) and GB-MyT(0.853±0.097) were larger than the GS-UT(0.666±0.409), GS-MT(0.211±0.070) and GS-MyT(0.442±0.143). **Conclusion:** This approach offers a safe and feasible method of uterine tube obstruction. **Key words:** Sterilization, Reproductive. Tissue Adhesives. Fallopian Tubes. Rabbits.

---

#### RESUMO

**Objetivo:** Verificar a eficácia do adesivo de cianoacrilato na esterilização de tubas uterinas de coelhas. **Métodos:** A cateterização tubária por histeroscopia foi realizada randomicamente em 12 animais (24 tubas uterinas) formando o Grupo Sham (GS) e 15 animais (30 tubas uterinas) para o grupo do n-butil-cianoacrilato (GB). As coelhas foram observadas por 30, 90 e 180 dias e acasaladas com machos férteis. As tubas uterinas das fêmeas que não ficaram grávidas foram submetidas ao teste de pressão de rompimento in vitro, com insuflação de ar (40mmHg). A microscopia óptica estudou os danos causados ao epitélio pelo adesivo, o grau de processo inflamatório, a morfometria do diâmetro tubário (UT) (cm), da mucosa (MT) e do miosalpinge (MyT) (mm). A densitometria das células da mucosa (Densidade Óptica Total) foi expressa pela contagem do DNA. As significâncias dos diferentes escores histológicos e das medidas das camadas foram avaliadas pelo Teste de ANOVA (P<0,005). **Resultados:** Em todos os animais do GB: o adesivo estava aderido na mucosa tubária, não ocorreu prenhez, não houve significância nos graus do processo inflamatório, o teste de perviedade foi negativo e a densitometria do DNA apresentou valores similares em todos os grupos, independente do período de observação. A medida das camadas do GB-UT(1.118±0.117), GB-MT(0.447±0.247) e GB-MyT (0.853±0.097) foi maior que as dos GS-UT(0.666±0.409), GS-MT(0.211±0.070) e GS-MyT(0.442±0.143). **Conclusão:** O procedimento proposto foi de fácil execução e eficaz para obstrução da tuba uterina de coelhas.

**Descritores:** Esterilização Reprodutiva. Adesivos Teciduais. Tubas Uterinas. Coelhos.

---

## Introduction

Tubal sterilization has become one of the most used methods for definite contraception on family planning in the world<sup>1</sup>. The hysteroscopy approach, which can be fitted under local anesthesia in an ambulatory setting, might lessen postoperative pain and allow faster recovery than the incisional surgery with general anesthesia<sup>2</sup>. Fallopian tubes occlusion by transcervical route has been attempted through electrocoagulation and diode laser<sup>3,4,5</sup>, sclerosing substances<sup>6,7</sup> or tissue adhesives<sup>8,9</sup>, and mechanical occlusive devices or plugs<sup>10,11,12</sup>. Nevertheless, until now, no method has been widely adopted owing to safety or effectiveness limitation so far<sup>2</sup>. Recently, new methods for transcervical sterilization include the Essure™ (Conceptus, San Carlos, CA, USA) and the Adiana™ (Cytoc Corp., Marlborough, MA, USA) procedures that involve hysteroscopic placement of devices that rely on both mechanical occlusion and stimulation of tissue in-growth to effect tubal occlusion<sup>10,11,12</sup>. Preliminary reports showed that these new devices can be delivered to over than 90% of tubes, with very high success rates of pregnancy prevention<sup>2</sup>. The office-hysteroscopic placement of the mechanical occlusion device is a more cost-effective method than laparoscopic tubal ligation<sup>11</sup>. The permanent retention of both microinserts in the proximal tube is achieved upon to the inflammatory reaction and subsequent fibrous tissue in-growth<sup>12</sup>. In a previous study in rabbits<sup>13</sup> using the n-butyl-cyanoacrylate by hysteroscopic application for proximal uterine tube occlusion it was shown that past 30 days the adhesive plug was strongly adherent to the tubal mucosa with a minimal inflammatory reaction. The adhesive plug remained attached to the mucosa in spite of over pressure (40 mmHg) hydraulic burst test in vitro. The pregnancy rate was null although the female rabbits, that had at least a prior pregnancy before, remained in company of fertile males during third days. These results suggested that the adhesive could be an option for uterine tube occlusion with less inflammatory reaction (with eventual advantage in less discomforts symptoms and could be easily removed without surgical procedure) and a low cost procedure. The aim of this study was to assess the results of implantation of the adhesive of cyanoacrylate in uterine tube of rabbits on a wide observation period of six months.

## Methods

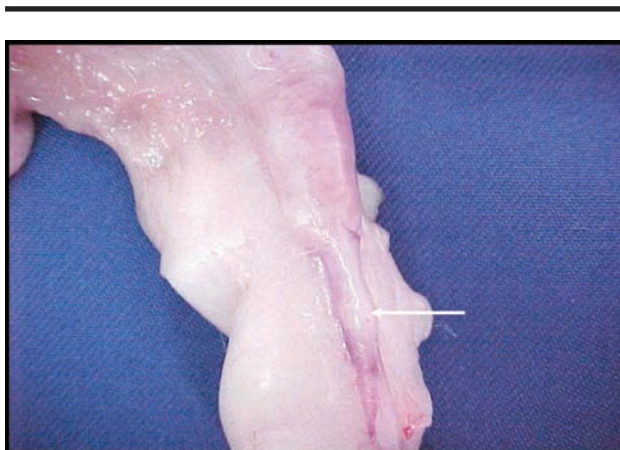
The experimental protocol (CEP 835/01) was approved by the Ethics Committee of the Federal University of São Paulo (UNIFESP – EPM). All the procedures followed strictly the existing regulations about animal experimentation. 27 female albino New Zealand rabbits weighing 2.8–3.0 Kg were fed standard chow and water ad libitum. All the female rabbits remained with one of ten fertile male rabbit during 20 days and become

pregnant and delivered at once three months before the experimental procedures. All the surgical procedures were performed under anesthesia, using IM diazepam 0.5mg/Kg (Diazepam™ - Cristália Ltd.-Brazil), 25mg/Kg tiletamine/zolazepam (Zoletil™ - Virbac do Brasil S.A.) and fentanyl citrate 0.05mg/Kg (Fentanil™ - Cristália Ltd.-Brazil). 12 animals (24 uterine tubes) were randomly assigned to the sham group (GS) and another 15 animals (30 uterine tubes) to the n-butyl-cyanoacrylate group (GB). The videovaginoscopy was performed with optical system of 4mm/30° (Storz™), and a 2.2mm instrument channel, coupled to a microcamera (Digital Samsung™ Color CCS-212N) with halogen source light (Source Xenon Storz™ - 300 watts) and linked the a capture system and image transmission (Telecam.Storz™) for a color monitor (Monitor Sony™- 20 inches). For tubal catheterization were used a 5 Fr, 42cm long, polyethylene catheter tapered radiopaque tip (BD™ Industries Ltd.- Brazil) and a 2.5 Fr, 43cm long, polyethylene microcatheter (BD™ Industries Ltd.-Brazil) for adhesive (Histoacryl™ - B. Braun, Melsugen, GE) or saline solution injections. To provide a better access to the cervix the vagina was distended with a 20mL of Ringer-lactate solution (Braun™ Laboratories- Brazil). When stable visualization was achieved the hysteroscope was introduced through the cervix in the uterus and localized both tubal ostia. The 5Fr (42cm) catheter strengthened by the guide wire was introduced through the working channel and directed to the right (at first) and left (at least) ostium. After introduced about 1cm in the ostium (with fluoroscopy control)<sup>14,15</sup>, the guide wire was substituted by the 2.5 Fr (43cm) catheter and the adhesive (0.25mL) or saline solution (0.25mL) was injected. About one minute after the catheter was removed and the ostia reviewed. Randomly the animals of each group were assigned for 30 (GS1-n=8 and GB1-n=10), 90 (GS2-n=8 and GB2-n=10) or 180 (GS3-n=8 and GB3-n=10) days of observation. The female rabbits were mated to the same fertile males during 30 days immediately before the euthanasia date. At the end of the respective period of observation the no pregnant rabbits, under anesthesia, were submitted to laparotomy with removal of uterus, uterine tubes and ovaries. In the pregnant rabbits the surgical procedure occurred 30 after the delivery. The macroscopic assessment was performed using the follow grading scoring: 1 (no changes), 2 (mild), 3 (moderate) and 4 (severe). The evaluated parameters were degree of inflammatory response of tube to the adhesive, serosa aspect, adherences and the adhesive presence into the lumen. A 5Fr polyethylene probe was introduced and tied in the uterine ostium by the inflated ballonet. The 2-way probe was connected into a Y device with a syringe (20ml) used to inject the air and a manometer (Welch Allyn Tycos™) used to measure intrauterine pressure (mmHg). The uterus and uterine tubes were immersed in saline solution and the patency of uterine tubes was tested by air insufflation until reach at least the pressure of 40 mmHg. The burst pressure test was positive when

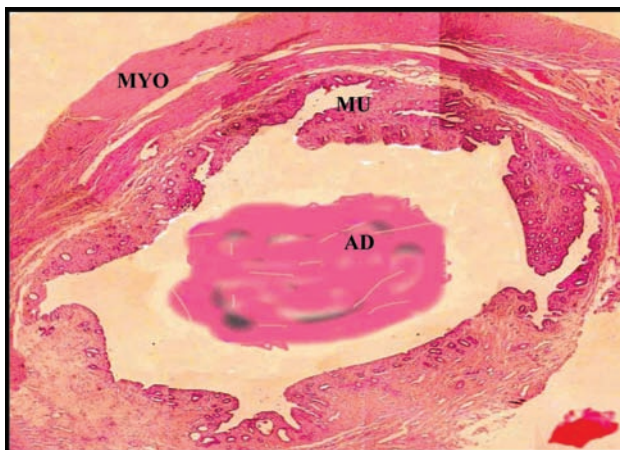air bubbles came out from the fimbriae. The uterine tubes were removed fixed in 10% formalin solution, embedded in paraffin wax and 5 µm sections were cut and stained with hematoxylin and eosin. Histological evaluation was undertaken by an independent pathologist who had no knowledge of the experimental groups from which the specimens were derived. The microscopic assessment was performed using a grading scoring: 1 (no changes), 2 (mild), 3 (moderate) and 4 (severe) to parameters of damages in epithelium caused by the adhesive, presence or adherence of the adhesive in tube lumen and the degree of inflammatory process. The images were captured through a high resolution camera from a CARL ZEISS Axilab® optic microscope. The software Image Proplus version 4.5® program was used for analysis of morphometry data values of tube diameter (cm), the mucosa and the myosalpinx thickness (mm). Other histological sections were stained for densitometry by the Feulgen reaction (Merck™ KGaA). The mucosa cells densitometry (total optical density) expressed the amount of desoxyribonucleic acid (DNA) ploidy, measured in 400 cells per section. The continuous variables were represented by mean (± sd). The significance of the differences in histological scores and in thickness measurements were made by ANOVA test. A P value < 0.05 was considered to be statistically significant.

**Results**

All the animals in the sham group (GS), as expected, were pregnant at the end of the three observation periods (30, 90 and 180 days). That demonstrated that the hysteroscopic probe introduction and saline solution instillation was not harmful to the uterine tube morphology and physiology and not impaired the pregnancy. On the other hand, all animals in the n-butyl-cyanoacrylate group (GB) were not pregnant in all three observation periods, in spite of mated with fertile male rabbits. The macroscopic aspects of uterine tubes were normal without any adhesions or inflammatory reaction. The blue adhesive plug should be identified always by transparency near the uterine isthmus (Figure 1). The burst pressure test was positive with air bubbles came out from the fimbriae in all animals of GS, but was negative for all animals from adhesive group. The cyanoacrylate produced an effectiveness uterine tube obstruction in the three observation periods. The evaluated histological parameters demonstrated an absence of damages in epithelium caused by the adhesive. The adhesive was always present and attached to the mucosa. There were no records of significant degree on inflammatory process related to the adhesive plug (Figure 2). The analysis of the sections stained for densitometry by the Feulgen reaction to express the amount of Deoxyribonucleic Acid (DNA) ploidy showed similar values to the both groups independently of observation periods.



**FIGURE 1** – Photography of uterine tube isthmus and the n-butyl-cyanoacrylate plug (arrow) in an animal from 180 observation days



**FIGURE 2** – Photomicrography of uterine tube transversal cut in an animal of 180 observation days. AD (adhesive), MU (mucosa) and MYO (myosalpinx). (HE-20X)

**TABLE 1** – Uterine tube diameters (cm) in the three observation periods (30, 90 and 180 days) in the animals of GS (sham) and n-butyl-cyanoacrylate (GB) tube obstruction. Values are given as mean ± SD and median

Periods	GS (sham)	GB (cyanoacrylate)
30 days	0.557 (±0.331) <sup>a</sup>	0.947 (±0.234) <sup>b</sup>
	0.438	0.900
90 days	0.656 (±0.428) <sup>c</sup>	1.159 (±0.382) <sup>d</sup>
	0.500	1.215
180 days	0.666 (±0.409) <sup>e</sup>	1.118 (±0.117) <sup>f</sup>
	0.570	1.070

Different superscript letters indicate statistically significant differences with regard to the corresponding control (GS) value (ANOVA p<0.001).

a = c = e (p= 0.128) no statistical difference  
 b = d = f (p= 0.208) no statistical difference  
 a < b (p= 0.023\*); c < d (p= 0.042\*) e < f (p= 0.047\*)

**TABLE 2** – Uterine mucosal thickness (mm) in the three observation periods (30, 90 and 180 days) in the animals of GS (sham) and n-butyl-cyanoacrylate (GB) tube obstruction. Values are given as mean  $\pm$  SD and median

Periods	GS (sham)	GB (cyanoacrylate)
<b>30 days</b>	0.194 ( $\pm$ 0.083) <sup>a</sup> 0.181	0.300 ( $\pm$ 0.210) <sup>b</sup> 0.200
<b>90 days</b>	0.249 ( $\pm$ 0.121) <sup>c</sup> 0.222	0.430 ( $\pm$ 0.259) <sup>d</sup> 0.395
<b>180 days</b>	0.211 ( $\pm$ 0.070) <sup>e</sup> 0.200	0.447 ( $\pm$ 0.247) <sup>f</sup> 0.430

Different superscript letters indicate statistically significant differences with regard to the corresponding control (GS) value (ANOVA  $p < 0.001$ ).

a = c = e (  $p = 0.692$  ) no statistical difference

b = d = f (  $p = 0.753$  ) no statistical difference

a < b (  $p = 0.004^*$  ); c < d (  $p = 0.006^*$  ) e < f (  $p = 0.009$  )

### Discussion

This study demonstrated that hysteroscopic tubal sterilization with n-butyl-cyanoacrylate was well tolerated and effectiveness to produce a total pregnancy impairment on female rabbits until 180 days after the procedure. Regarding the vital cycle of these animals the six months period may be considered an effective long-acting result. The tissue inflammatory reaction was minimal and the adhesive plug remained unabsorbable in all the three periods of observation. This procedure, therefore, offers an attractive alternative to microinserts Essure™ and Adiana™ which are associated to intense inflammatory and fibrosis reaction in the uterine tube<sup>1</sup>. In contrast, the use of methyl-cyanoacrylate was less favorable. A report of tube sterilization in female rabbits by transvaginal application of methyl-cyanoacrylate, after two weeks, demonstrated the presence of cellular necrosis, inflammatory cells, fibrin and fibrosis<sup>16</sup>. After two months and six months were noticed the total absorption of the adhesive and all tubes showed segment tubal wall fibrosis and a chronic inflammatory process<sup>16</sup>. Another report of application of 0.15ml of methyl-cyanoacrylate in the tubal lumen of female rabbits, thought an incision in the uterine cornu 2cm far from the uterotubal junction. After six weeks all the tubes were obstructed with histological evidence of tubal epithelium destruction, with massive fibrosis and absence of the adhesive. Polymer particles were found on the macrophages<sup>17</sup>. On the other hand, there is no one report describing the use of n-butyl-2-cyanoacrylate in animal model and only one report in human beings. Two women were submitted to transvaginal application of the adhesive, guided by radiological method, and after four years of follow-up, their tubes remained occluded<sup>8</sup>. The hysterosalpingography was the unique image control and there was any another information about uterine tube morphology and function. In attention of this, we hypothesized that the n-butyl-cyanoacrylate should be more

**TABLE 3** – Myosalpinx thickness (mm) in the three observation periods (30, 90 and 180 days) in the animals of GS (sham) and n-butyl-cyanoacrylate (GB) tube obstruction. Values are given as mean  $\pm$  SD and median

Periods	GS (sham)	GB (cyanoacrylate)
<b>30 days</b>	0.274 ( $\pm$ 0.108) <sup>a</sup> 0.233	0.442 ( $\pm$ 0.143) <sup>b</sup> 0.424
<b>90 days</b>	0.375 ( $\pm$ 0.281) <sup>c</sup> 0.360	0.721 ( $\pm$ 0.196) <sup>d</sup> 0.705
<b>180 days</b>	0.335 ( $\pm$ 0.168) <sup>e</sup> 0.310	0.853 ( $\pm$ 0.097) <sup>f</sup> 0.820

Different superscript letters indicate statistically significant differences with regard to the corresponding control (GS) value (ANOVA  $p < 0.001$ ).

a = c = e (  $p = 0.160$  ) no statistical difference

b = d = f (  $p = 0.335$  ) no statistical difference

a < b (  $p = 0.001^*$  ); c < d (  $p = 0.001^*$  ) e < f (  $p = 0.002^*$  )

effectiveness than the methyl derivate. In a report published elsewhere<sup>13</sup>, we demonstrated that the hysteroscopic application of n-butyl-cyanoacrylate on rabbit uterine tubes, in a short period of 30 days of observation, was effectiveness to promote the total obstruction with minimal histological damage and persistent presence of the adhesive plug. The females remained no pregnant, in spite of mated with fertile males. The in vitro patency test with hydraulic burst test or over pressure of dye solution demonstrated a total occlusion in all the uterine tubes<sup>13</sup>. In comparison, with the same procedure but using the fibrin glue the results were worse and the female rabbits were pregnant after 30 days of observation<sup>18</sup>. Conversely to observed with the other tissues the n-butyl-cyanoacrylate was not absorbed by the uterine mucosa. The histological analysis of twenty randomly sites in each plates of each animal do not noted the macrophages presence, nor any morphological signal of adhesive degradation. The leucocytes presence was mild only in the initial phase of observation (30 days) and not statistical significantly in comparison with 90 or 180 observation days. In spite of the poor inflammatory reaction, there was an enlargement of the diameter of uterine tube, in the mucosa and myosalpinx thickness, in comparison with the control saline group (GS). The diameter enlargement was present in all the observation periods (Table 1), it was near the double of the normal tube and was due to both layer enlargement: mucosa (Table 2) and myosalpinx (Table 3). This should be associated to cellular proliferation, although the amount of deoxyribonucleic acid (DNA) ploidy showed similar values to the both groups. Probably the adhesive plug can acting as a cellular stimulating and promote it effective attaching to the implant site. Further research must clarify the different behavior of n-butyl-cyanoacrylate in uterine tube lumen. Why it was not absorbed? Why it was firmly attached to the mucosa? How long it remains attached? Other larger animal, non-rodent mammals, such as the sheep, shall be used in further studies to test the adhesive for long periods of 6 or 12-month, since these

questions remains unanswered. Further technical details on tubal catheterization shall be provided and adapted to other animal species, and particularly to human beings. Nevertheless, on the basis of the evidence, this approach offers a safe and feasible method of uterine tube obstruction and could be a low cost-effective alternative to sterilization on familiar planning setting to public health system.

## References

1. Chapman L, Magos A. Currently available devices for female sterilization. *Expert Rev Med Devices*. 2005;2(5):623-34.
2. Cooper JM, Carignan CS, Cher D, Kerin JF. Microinsert nonincisional hysteroscopic sterilization. *Obstet Gynecol*. 2003;102(1):59-67.
3. Spörri S, Bell B, Dreher E, Schneider H, Motamedi M. Tubal sterilization by means of endoluminal coagulation: an in vivo study in rabbits. *Contraception*. 2000;62(3):141-7.
4. Seo TS, Oh JH, Yoon Y, Ryu KN, Lim JW. Occlusion of the Fallopian tube by selective transcatheter radiofrequency electrocoagulation: an experimental study in rabbits. *J Vasc Interv Radiol*. 2002;13(4):399-404.
5. Spörri S, Bell B, Yandell R, Motamedi M. Diode laser assisted transcervical tubal sterilization: an in vivo study in rabbits. *Lasers Surg Med*. 2001;29:379-85.
6. Abdala N, Levitin A, Dawson A, Maffra Jr R, Munoz-Ramirez H, Godec K, Dolmatch BL. Use of ethylene vinyl alcohol copolymer for tubal sterilization by selective catheterization in rabbits. *J Vasc Interv Radiol*. 2001;12(8):979-84.
7. McLemore R, Kim EJ, Brandon TA, Aerni G, Roy KH, Vernon BL. Tubal sterilization with a waterborne polyethylene glycol in situ cross-linking material: a minimally invasive approach. *Fertil Steril*. 2005;83(Suppl 1):1284-92.
8. Pelage JP, Herbreteau D, Paillon JG, Murray JM, Rymer R, Garance P. Selective salpingography and fallopian tubal occlusion with n-butyl-2-cyanoacrylate: report of two cases. *Radiology*. 1998;207(3):809-12.
9. Shuber J. Transcervical sterilization with use of methyl 2-cyanoacrylate and a newer delivery system (the FEMCEPT device). *Am J Obstet Gynecol*. 1989;160(4):887-9.
10. Abbott J. Transcervical sterilization. *Best Pract Res Clin Obstet Gynaecol*. 2005;19(5):743-56.
11. Levie MD, Chudnoff SG. Office hysteroscopic sterilization compared with laparoscopic sterilization: a critical cost analysis. *J Minim Inv Gynecol*. 2005;12(4):318-22.
12. Ubeda A, Labastida R, Dexeus S. Essure: a new device for hysteroscopic tubal sterilization in an outpatient setting. *Fertil Steril*. 2004;82(1):196-9.
13. Rivoire HC, Fagundes DJ, Taha MO, Novo NF, Juliano Y. Esterilização tubária com adesivo cirúrgico sintético: estudo experimental. *Rev Col Bras Cir*. 2003;30(5):337-43.
14. Ross PL, Thurmond AS, Uchida BT, Jones MK, Scanlan RM, Kessel E. Transcatheter tubal sterilization in rabbits, technique and results. *Invest Radiol*. 1994;29(5):570-3.
15. Maubon AJ, Thurmond AS, Nikolchev J, Khera A, Machan LS, Rouanet JP. Endoscopic transvaginal approach to the rabbit uterine cervix: improvement in the technique of selective tubal catheterization. *Acad Radiol*. 1997;4(4):270-4.
16. Berkey GS, Nelson R, Zuckerman AM, Dillehay D, Cope C. Sterilization with methyl cyanoacrylate-induced fallopian tube occlusion from a nonsurgical transvaginal approach in rabbits. *J Vasc Interv Radiol*. 1995;6(5):669-74.
17. Corfman PA, Richart RM, Taylor HC. Response of the rabbit oviduct to a tissue adhesive. *Science*. 1965;48:1348-50.
18. Sonmez AS, Arub I, Dunn RC, Kaufman RH, Chuong CJ. Sterilization with fibrin sealant in a rabbit uterine horn model. *Am J Obstet Gynecol*. 1997;177(3):573-8.

---

## Correspondence:

Prof. Dr. Henri Chaplin Rivoire  
Rua Barão de Cotegipe, 682  
96200-290 Rio Grande – RS Brazil  
[henri@mikrus.com.br](mailto:henri@mikrus.com.br)

Conflict of interest: none  
Financial source: none

Received: March 20, 2007  
Review: May 23, 2007  
Accepted: June 19, 2007

---

## How to cite this article

Rivoire HC, Fagundes DJ, Bigolin S, Fagundes ATN. Hysteroscopy and the butyl-cyanoacrylate on experimental sterilization of rabbit uterine tubes. *Acta Cir Bras*. [serial on the Internet] 2007 Sept-Oct;22(5). Available from URL: <http://www.scielo.br/acb>

---

\*Color figures available from [www.scielo.br/acb](http://www.scielo.br/acb)