

Anatomopathological study of cardiomyopathy induced by doxorubicin in rats¹

Estudo anatomopatológico da miocardiopatia induzida pela doxorubicina em ratos

José Carlos Dorsa Vieira Pontes^I, Jandir Ferreira Gomes Júnior^{II}, Guilherme Viotto Rodrigues da Silva^{III}, Ricardo Adala Benfatti^{II}, Amaury Edgardo Mont'Serrat Ávila Souza Dias^{IV}, João Jackson Duarte^{II}, Neimar Gardenal^{II}, Maçanori Odashiro^V, Carlos Henrique Marques dos Santos^{VI}

^I PhD, Associate Professor, Surgery Department, UFMS, Mato Grosso do Sul, Brazil.

^{II} Master, Assistant Professor, Surgery Department, UFMS, Mato Grosso do Sul, Brazil.

^{III} Graduate Student, Medical School, UFMS, Mato Grosso do Sul, Brazil.

^{IV} Specialist, Fellow Master Degree, Assistant Professor, Surgery Department, UFMS, Mato Grosso do Sul, Brazil.

^V Associate Professor, Surgery Department, UFMS, Mato Grosso do Sul, Brazil.

^{VI} PhD, Assistant Professor, Surgery Department, UFMS, Mato Grosso do Sul, Brazil.

ABSTRACT

Purpose: The development of an experimental model of myocardial pathology induced by Doxorubicin in rats. **Methods:** 16 wistar male rats were randomized in two groups: Group I (placebo) and Group II (Doxorubicin – 5mg/kg). After six months, the animals were subjected to cardiomy and their hearts were weighted and submitted to transversal cuts, from which fragments for a macro and micro study were obtained. These fragments were studied considering their external and internal diameters and the thickness of the left ventricle (LV). The histological pieces were analyzed for the presence of fibrosis, cytoplasmic vacuolization, necrosis and size of nucleus variation. Data obtained was submitted to statistical analysis with Student's t test. **Results:** The hearts of the animals in Group II increased 41% in relation to their weight; 33% in the internal diameter and 14% in the external diameter of the LV cavity; and 24% in the thickness of the wall. Fibrosis of the myocardial tissue was observed in 75% of the animals of Group II; all the animals presented miocyte cytoplasmic vacuolization; myocardial necrosis was present in 75% of the animals; and 87% presented variation in the size of myocyte nuclei. The presence of polymorphonuclear cells was also observed. **Conclusion:** Doxorubicin was effective in the promotion of macro and microscopic alterations in the cardiac tissue of rats, possibly constituting a model for the experimental study of myocardial pathology.

Key words: Cardiomyopathies. Doxorubicin. Rats.

RESUMO

Objetivo: Desenvolver um modelo experimental de miocardiopatia induzida por doxorubicina em ratos. **Métodos:** 16 ratos Wistar machos foram randomizados em 2 grupos: Grupo I (placebo) e Grupo II (doxorubicina 5mg/kg). Após 6 meses, os animais foram submetidos a cardiomi e seus corações foram pesados e submetidos a cortes transversais. Estes fragmentos foram estudados considerando seus diâmetros externos e internos e a espessura do ventrículo esquerdo. As peças histológicas foram analisadas quanto à presença de fibrose, vacuolização citoplasmática, necrose e variação do tamanho do núcleo. Os resultados foram submetidos a análise estatística pelo teste t de Student. **Resultados:** Os corações dos animais do grupo II aumentaram 41% em relação ao peso; 33% no diâmetro interno e 14% no diâmetro externo; e 24% na espessura da parede do VE. Fibrose do tecido miocárdico foi observada em 75% dos animais do grupo II; todos os animais apresentaram vacuolização citoplasmática dos miócitos; Houve necrose miocárdica em 75% dos animais e 87% apresentaram variação no tamanho do núcleo. A presença de células polimorfonucleares também foi observada. **Conclusão:** A doxorubicina foi efetiva na promoção de alterações macro e microscópicas no tecido cardíaco de ratos, possivelmente constituindo-se num modelo experimental para estudo da miocardiopatia.

Descritores: Cardiomiopatas. Doxorubicina. Ratos.

¹Research performed at Laboratory of Researches, Federal University of Mato Grosso do Sul (UFMS), Brazil.

Introduction

Cardiovascular diseases are presently considered an important problem in public health, causing a high rate of mortality in the general population. Among these diseases, heart failure, defined as the heart's incapacity to adequately pump blood to meet the necessities of tissue metabolism or when it does pump blood at an anomalously elevated diastolic ventricular volume¹.

Heart failure may have many etiologies. It may be due to cardiac muscle abnormalities such as myocardopathy or cardiomyopathy (primary or idiopathic – no definite etiology) or specific of the myocardium. Myocardopathy presents three distinct clinicopathological functional forms: dilated myocardopathy, hypertrophic myocardopathy and restrictive myocardopathy. Dilated myocardopathy is the most common form of the disease (90%), while the restrictive form is less prevalent. The specific diseases of the cardiac muscle, in other words, those which present and known cause or that are associated to other systems' disorders, may cause any of the three functional patterns. This kind of myocardopathy probably results from the final result of a myocardial lesion caused by many toxic, metabolic and infectious agents, neuromuscular diseases, storage disorders or other deposits, infiltrative or immunological disease².

Many pharmacological agents (toxic agents) may acutely lesion the myocardium either causing myocarditis or a chronic lesion like that caused by dilated idiopathic myocardopathy. Among these agents, we point out Doxorubicin².

Doxorubicin chloridrate (Adriamicin, Adriblastine) is one of the most effective anti-neoplastic agents in the treatment of a great variety of malignant tumors, including lymphoma, leukemia and solid tumors^{1,2}. Doxorubicin is an anthracycline anti-cancer antibiotic that has cytotoxic action. Its main cytotoxic action is the inhibition of type II topoisomerase that induces DNA fragmentation, and eventually, cellular death. These agents also suffer the reduction of one and two electrons, generating intracellular free radicals, especially hydroxyl radicals that are highly cytotoxic³. Doxorubicin is intravenously administered and is quickly captured by many kinds of tissues. Extra-vascular infusion may cause local necrosis. It is mainly eliminated by bile.

Among Doxorubicin adverse side-effects, such as nausea, vomit, myelosuppression, and hair loss, is cardiotoxicity which limits its potential therapeutic use³. Cardiotoxicity is dose dependent, causing irreversible damage to the myocardium, leading to the development of myocardopathy and ensuing heart failure⁴. This type of cardiopathy develops itself when high doses are administered (>550mg/m²). Approximately 7% of the patients to whom 550mg/kg doxorubicin are administered for anticancer treatment will develop dilated myocardopathy. This percentage increases when higher doses are administered⁵.

Symptoms occur earlier when the individual is already a cardiopathic patient. Doxorubicin acute toxicity occurs during or immediately following its administration and includes the following symptoms: tachycardia, hypotension, ST segment depression, T-waves electrocardiographic alterations. These are not worrisome symptoms since they disappear when the drug is suspended. The chronic effect, therefore, is irreversible myocardopathy that may develop heart failure, after months or years of the beginning of the

treatment, with the presentation of symptoms of congestive heart failure⁵.

It has been proved that the development of good models of experimental studies is necessary to understand cardiomyopathies and heart failure better, due to their importance and prevalence in the general population. Singal *et al.*⁶ demonstrated the use of Doxorubicin in the induction of myocardopathy. Myocardopathy comparative studies demonstrated that the rat is the animal that is the most similar animal to a human being⁷.

Taking into consideration what was discussed above, this work aims at the elaboration of an experimental study in rats, in order to evaluate the macro and micro anatomopathological alterations of myocardopathy induced by Doxorubicin.

Methods

The ethical principles of animal testing were followed, which have been established by the Brazilian School of Animal Testing (*Colégio Brasileiro de Experimentação Animal* - (COBEA). The research received approval from Ethic Committee of Federal University of Mato Grosso do Sul. Sixteen male, adult Wistar rats (*Rattus norvegicus albinus*) were studied. They came originally from the Animal Room of the Federal University of Mato Grosso do Sul with average weight 312g. The animals were randomized into two groups of eight rats: Group I – animals treated with placebo; group II animals treated with Doxorubicin.

The animals were anesthetized orally with sulfuric ether in a closed bell-jar. The caudal vein was submitted to cauterization with no 27 scalpel. Group II animals were administered 60U doxorubicin (unique dose), equivalent to 5mg/kg. Animals in Group I were administered the same volume of 0, 9% physiological serum. During six months, the animals were kept in cages, being fed adequate food and water *ad libitum*.

After this period, cardiomyotomy was performed. The animals were anesthetized with the inhalation of sulfuric ether in closed bell-jars. Ample thoracotomy was performed with the resection of the costal cartilage for the exposition of the heart. Transversal cuts were made from 2cm of the cardiac basis, obtaining fragments for the macroscopic study and for the microscopic study, afterwards. The heart of each animal was weighted in a AND HR-202 precision scale, soon after resection and adequately identified. The animals' hearts were studied as to the internal and external diameter of the left ventricle.

Hematoxylin-Eosin staining and Masson Trichromic were used. The histological pieces were evaluated for the presence of fibrosis, cytoplasmatic vacuolization, necrosis and size of nucleus variation.

Student's t Test was used at a 0.05 significance level.

Results

Macroscopic analysis

Heart weight

An average 41% increase in Group II animal heart weight was observed compared to Group I animal heart weight (Table 1).

TABLE 1 – Heart's weight (g) of each rat in Groups I and II

	GRUPO I	GRUPO II
R1	1,272	1,8083
R2	1,0019	2,1879
R3	1,0336	1,5022
R4	1,1517	1,1885
R5	1,0421	1,2563
R6	1,1345	1,3598
R7	1,1218	1,597
R8	1,0876	1,6241
Mean	1,10565	1,5655125
SD	0,85528391	0,323995774
p	0,002348715	

Internal diameter of the left ventricle cavity

A 33% average increase in the internal diameter of the left ventricle cavity was observed in the hearts of Group II rats when compared to those of Group I (Table 2).

TABLE 2 – Internal diameter (mm) of the left ventricle cavity of each rat in Groups I and II

	GRUPO I	GRUPO II
R1	1,8	2,4
R2	1,8	2,4
R3	2,4	3
R4	1,8	2,4
R5	1,8	2,4
R6	1,8	3,6
R7	1,8	1,8
R8	3	3,6
Mean	2,025	2,7
SD	0,446414285	0,641426981
p	0,015135988	

External diameter of the left ventricle cavity

An average 14% increase in the external diameter of the left ventricle cavity was observed in Group II rats when compared to those of Group I (Table 3).

TABLE 3 – External diameter (mm) of the left ventricle cavity of each rat in Groups I and II

	GRUPO I	GRUPO II
R1	9,6	13,2
R2	8,4	13,2
R3	10,8	11,4
R4	10,2	10,8
R5	10,8	11,4
R6	10,2	10,8
R7	10,2	10,8
R8	11,4	12
Mean	10,2	11,7
SD	0,907114735	1,014185106
p	0,003825851	

Thickness of left ventricle wall

An average 24% increase on the thickness of the left ventricle wall was observed in the hearts of Group II rats when compared to those of Group I (Table 4).

TABLE 4 – Thickness (mm) of the left ventricle wall of each rat in Groups I and II

	GRUPO I	GRUPO II
R1	2,4	3,6
R2	2,4	3,6
R3	3	3,6
R4	3	3,6
R5	3	3
R6	2,4	3
R7	3	3,6
R8	2,4	3
Mean	2,7	3,375
SD	0,32071349	0,310529502
p	0,000384541	

Macroscopic analysis

Fibrosis

75% of Group II rats presented myocardial fibrosis (Figure 1).

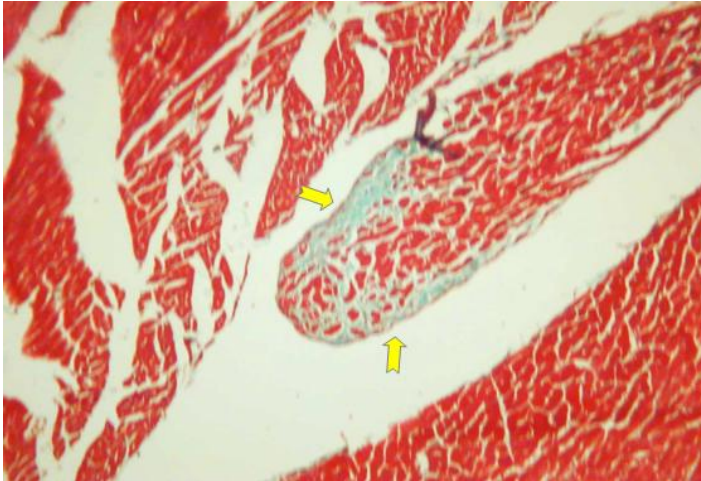


FIGURE 1 – Microscopic aspect of the myocardial tissue, showing the presence of fibrosis in the hearts of rats treated with Doxorubicin. Collagen fibers are stained blue. Masson's Trichome Staining. 100x amplified

Cytoplasmatic vacuolization

Myocyte cytoplasmatic vacuolization was observed in 100% of Group II rats (Figure 2).

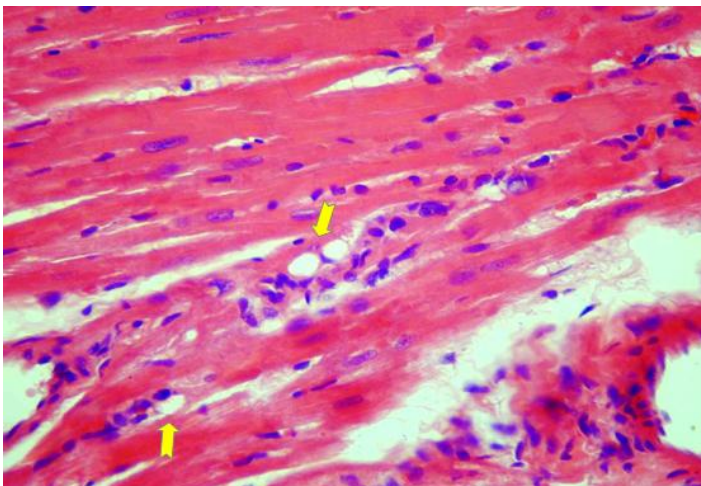


FIGURE 2 – Microscopic aspect of the myocardial tissue, showing the presence of cytoplasmatic myocyte vacuolization in the animals treated with Doxorubicin. Hematoxylin - Eosin staining

Necrosis

75% of Group II rats presented myocardial necrosis (Figure 3).

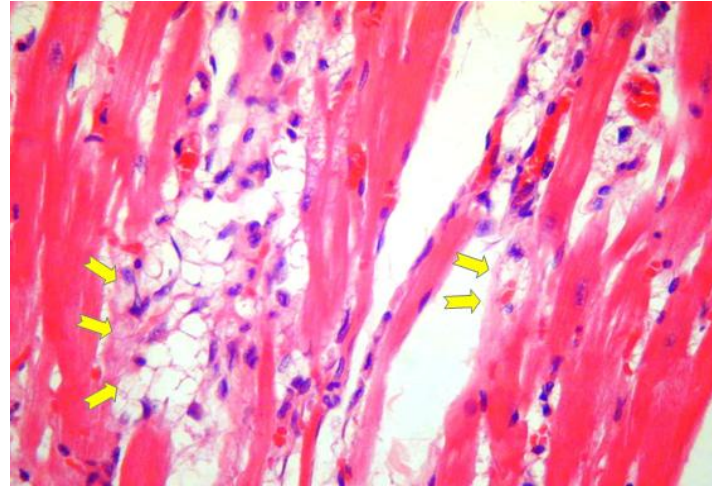


FIGURE 3 - Microscopic aspect of the myocardial tissue showing the presence of necrosis in animals' hearts treated with doxorubicin

Variation in nucleus size

87% of Group II rats presented a variation in the size of the myocyte nucleus (Figure 4).

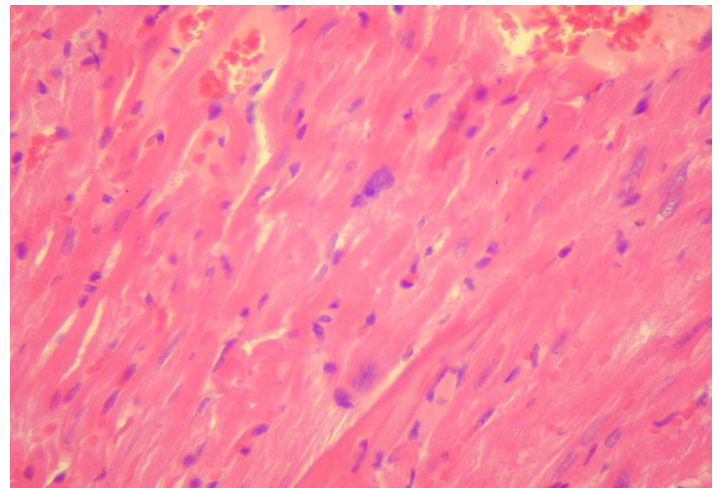


FIGURE 4 – Microscopic aspect of myocardial tissue showing size variation in myocyte nuclei of rats treated with Doxorubicin

Other findings

The presence of polymorphonuclear cells was also found in Group II animals (Figure 5).

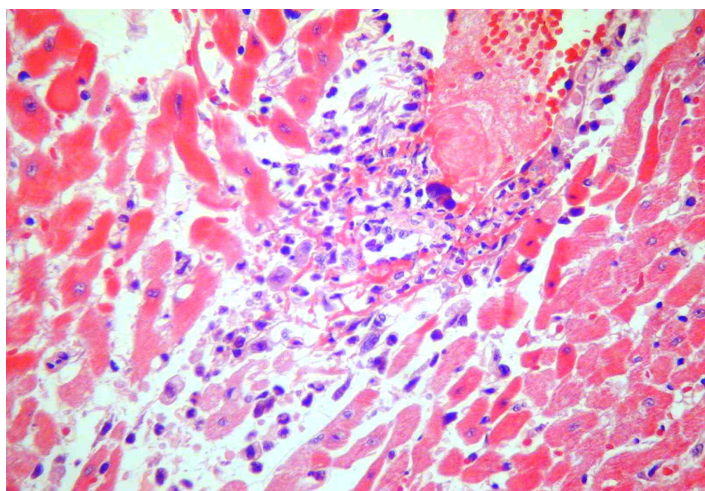


FIGURE 5 – Microscopic aspect of myocardial tissue showing the presence of polymorphonuclear infiltrate in the hearts of rats treated with Doxorubicin. Sub-endocardial necrosis was also observed. Hematoxylin - Eosin staining. 440x amplified

Discussion

The literature on the subject registers that idiopathic cardiomyopathy generally presents the dilation of all compartments, with determined thickening of the ventricular wall. Studies on histological cuts show the presence of fibrous myocardial scars in plaques (the major part of them are subendocardial). The histological alterations that occur in the process of dilated cardiomyopathy show that the size of individualized muscular cells varies; most of them are hypertrophied, and some others are elongated. Interstitial endomyocardial fibrosis of various degrees is usually present and small scars frequently substitute isolate cells or group of cells, in other words, substitution fibrosis. Vacuolization is also present as well as muscular edema, fat alteration, lise of the individual cells and, sometimes, focal necrosis.

Many authors describe that Doxorubicin induced cardiomyopathy may be established reproductively in rats^{8,9}. Studies with rats showed histological alterations similar to those that occur in humans: degeneration and loss of myocytes, myocyte compensatory hypertrophy of the rest of the myocytes and interstitial fibrosis. The literature also reports the presence of cytoplasmatic vacuolization². Majno *et al.*⁹ have observed fragmented and pycnotic nuclei, suggesting the possibility of apoptotic death⁹.

This study confirms the presence of such alterations in Doxorubicin induced cardiomyopathy. In this investigation, a significant statistical increase in the rats' heart weight, in the thickness of the wall and in the internal and external diameter of the left ventricle was observed in rats treated with Doxorubicin, when compared with the control group. Microscopic analysis registered the presence of cytoplasmatic vacuolization in all studied pieces. Variation in nucleus size was observed in almost all samples. Interstitial fibrosis and necrosis was present in 75% of the animals' hearts.

The presence of polymorphonuclear cells was also registered.

The precise molecular mechanism of Doxorubicin induced cardiomyopathy is still unknown. Many mechanisms have been proposed to explain the pathogenicity of this drug's cardiotoxicity. Some authors report an increase in the production of free radicals (FR) and a decrease in antioxidant enzymes activity. These FR (superoxide anion) produce a lipid peroxidation on the cellular membranes^{6,10,11}. According to Graves *et al.*¹², interference in the DNA replication occurs, due to Doxorubicin capacity to intercalate itself among the pairs of the basis¹². There are, also, other reports on inhibition of DNA topoisomerase II¹³, mitochondrial damage, myocyte disorder of the adrenergic function^{14,15}, Ca⁺⁺ intracellular overcharge¹⁶, and cytotoxic cytokine¹⁷. Apoptosis is very important not only in relation to cell loss during the physiological phenomenon, but also in relation to pathological processes, playing an important role in cardiomyopathy pathogenicity^{18,19}. Chen *et al.*²⁰ observed alterations in the cytoskeleton and myocyte contractile elements which are, probably, related to myocardial dysfunction. Modification and inhibition of these mechanisms should be the objective of future studies.

This study observed that the presence of macro and microscopic myocardial alterations in rats treated with Doxorubicin are comparable to those observed in dilated cardiomyopathies. Therefore, we can deduce that this experimental model will be helpful in future studies on heart failure.

Conclusion

Doxorubicin was effective in promoting macro and microscopic alterations in the cardiac tissue of rats, and can, therefore, be used as a model for experimental studies in cardiomyopathy.

References

- Henderson IC, Frei E 3rd. Adriamycin and the heart. *N Engl J Med*. 1979;300:310-2.
- Lefrak EA, Pitha J, Rosenheim S, Gottlieb JA. A clinicopathologic analysis of adriamycin cardiotoxicity. *Cancer*. 1973 32(2):302-14.
- Epstein RJ. Topoisomerases in human disease. *Lancet*. 1988;1(8584):521-4.
- Von Hoff DD, Layard MW, Basa P, Davis HL Jr, Von Hoff AL, Rozenzweig M, Muggia FM. Risk factors for doxorubicin-induced congestive heart failure. *Ann Intern Med*. 1979;91(5):710-7.
- Singal PK, Iliskovic N, Li T, Kumar D. Adriamycin cardiomyopathy: pathophysiology and prevention. *FASEB J*. 1997;11(12):931-6.
- Iliskovic N, Singal PK. Lipid lowering: an important factor in preventing adriamycin-induced heart failure. *Am J Pathol*. 1997;150(2):727-34.
- Mazue G, Iatropoulos M, Imondi A, Castellino S, Brughera M, Podesta A, Torre PD, Moneta D. Anthracyclines: a review of general and special toxicity studies. *Int J Oncol*. 1995;7(4):713-24.
- Podestà A, Della Torre P, Pinciroli G, Iatropoulos MJ, Brughera M, Mazué G. Evaluation of 4'-iodo-4'-deoxydoxorubicin-induced cardiotoxicity in two experimental rat models. *Toxicol Pathol*. 1994;22(1):68-71.
- Majno G, Joris I. Apoptosis, oncosis and necrosis. An overview of cell death. *Am J Pathol*. 1995;146(1):3-15.
- Olson RD, Mushlin PS. Doxorubicin cardiotoxicity: analysis of prevailing hypotheses. *FASEB J*. 1990;4(13):3076-86.
- Abdel-aleem S, el-Merzabani MM, Sayed-Ahmed M, Taylor DA, Lowe JE. Acute and chronic effects of adriamycin on fatty acid oxidation in isolated cardiac myocytes. *J Mol Cell Cardiol*. 1997;29(2):789-97.

12. Graves DE, Krugh TR. Adriamycin and daunorubicin bind in a cooperative manner to deoxyribonucleic acid. *Biochemistry*. 1983;22(16):3941-7.
13. Holm C, Stearns T, Botstein D. DNA topoisomerase II must act at mitosis to prevent nondisjunction and chromosome breakage. *Mol Cell Biol*. 1989;9(1):159-68.
14. Solem LE, Heller LJ, Wallace KB. Dose-dependent increase in sensitivity to calcium-induced mitochondrial dysfunction and cardiomyocyte cell injury by doxorubicin. *J Moll Cell Cardiol*. 1996;28(5):1023-32.
15. Valdés Olmos RA, ten Bokkel Huinink WW, ten Hoeve RF, van Tinteren H, Bruning PF, van Vlies B, Hoefnagel CA. Assessment of anthracycline-related myocardial adrenergic derangement by (123I) metaiodobenzylguanidine scintigraphy. *Eur J Cancer*. 1995;31A(1):26-31.
16. Wang YX, Korth M. Effects of doxorubicin on excitation-contraction coupling in guinea pig ventricular myocardium. *Circ Res*. 1995;76(4):645-53.
17. Torre-Amione G, Kapadia S, Benedict C, Oral H, Young JB, Mann DL. Proinflammatory cytokine levels in patients with depressed left ventricular ejection fraction: a report from the studies of left ventricular dysfunction (SOLVD). *J Am Coll Cardiol*. 1996;27(5):1201-6.
18. Saraste A, Pulkki K, Kallajoki M, Henriksen K, Parvinen M, Voipio-Pulkki LM. Apoptosis in human acute myocardial infarction. *Circulation*. 1997;95(2):320-3.
19. Olivetti G, Abbi R, Quaini F, Kajstura J, Cheng W, Nitahara JA, Quaini E, Di Loreto C, Beltrami CA, Krajewski S, Reed JC, Anversa P. Apoptosis in the failing human heart. *N Engl J Med*. 1997;336(16):1131-41.
20. Chen J, Chien KR. Complexity in simplicity: monogenic disorders and complex cardiomyopathies. *J Clin Invest*. 1999;103(11):1483-5.

Conflict of interest: none
Financial source: none

Correspondence:

José Carlos Dorsa Vieira Pontes
Av. Afonso Pena, 3088
79002-075 Campo Grande – MS Brazil
Phone: (55 67)3028-3380 / 8112-9986
carlosdorsa@uol.com.br

Received: September 15, 2009
Review: November 17, 2009
Accepted: December 15, 2009

How to cite this article

Pontes JCDV, Gomes Júnior JF, Silva GVR, Benfatti RA, Dias AEMSAS, Duarte JJ, Gardenal N, Odashiro M, Santos CHM. Anatomopathological study of cardiomyopathy induced by doxorubicin in rats. *Acta Cir Bras*. [serial on the Internet] 2010 Mar-Apr;25(2). Available from URL: <http://www.scielo.br/acb>
