

Geraldo Ângelo Gonçalves¹,
Eduardo Della Valle Prezzi²,
Guilherme Marinho Carletti³,
Giuseppe Chindamo⁴, Tito
Henrique Noronha Rocha⁵,
Eduardo Varella⁵, Arthur Oswaldo
de Abreu Vianna⁶

Use of noninvasive positive pressure ventilation and spinal anesthesia during hip replacement arthroplasty in a patient with severe chronic obstructive pulmonary disease. Case report

Uso da ventilação não-invasiva e anestesia espinal durante artroplastia de quadril de paciente com doença pulmonar obstrutiva crônica avançada. Relato de caso

1. Masters, Physician from Hospital Geral de Bonsucesso and Clínica São Vicente, Rio de Janeiro (RJ), Brazil.
2. Student from the Intensive Care Unit of the Clínica São Vicente and from the Universidade Federal do Rio de Janeiro – UFRJ, Rio de Janeiro (RJ), Brazil.
3. Physician from the Intensive Care Unit of the Hospital Barra D'Or and from the Hospital do Andaraí, Rio de Janeiro (RJ), Brazil.
4. Physician from the Instituto Nacional de Traumatologia e Ortopedia and Clínica São Vicente, Rio de Janeiro (RJ), Brazil.
5. Physician from the Clínica São Vicente, Rio de Janeiro (RJ), Brazil.
6. Masters, Physician from the Intensive Care Unit of the Clínica São Vicente, Rio de Janeiro (RJ), Brazil.

ABSTRACT

Anesthetic management of patients with severe chronic obstructive pulmonary disease is extensively discussed, due to the high rates of complications in this subtype of patients submitted to medium and high complexity surgical procedures. The objective of this study is to report use of noninvasive positive pressure mechanical ventilation - bi-level positive airway pressure - and spinal anesthesia in a patient with severe chronic obstructive pulmonary disease during total hip arthroplasty. An 81 year old, male patient with severe chronic obstructive pulmonary disease (GOLD 4) was submitted to total hip arthroplasty due to a femoral bone fracture under spinal anesthesia and noninvasive positive pressure mechanical ventilation - bi-level positive airway pressure with expiratory pressure of 7

cmH₂O, inspiratory pressure of 15 cmH₂O and O₂ flow of 3 L/min. During the procedure, the patient had one episode of bronchospasm that was promptly reverted pharmacologically with no complications in the postoperative period. The combination of less invasive anesthetic and ventilation techniques is easy to apply and may be useful in the perioperative management of patients with high anesthetic morbidity. Interaction between clinical, surgical and anesthetic teams for these cases is very important to reduce the mortality associated with extensive procedures in severe patients.

Keywords: Pulmonary disease, chronic obstructive; Arthroplasty, replacement, hip; Respiration, artificial; Positive pressure respiration Anesthesia, epidural; Human; Male; Aged; Case reports

INTRODUCTION

Chronic obstructive pulmonary disease (COPD) is an increasingly prevalent condition in the overall population¹ and is considered an independent risk factor for cardiopulmonary mortality and morbidity at postoperative period.² While general anesthesia has been associated to a higher risk of complications during and after surgical procedure, regional anesthesia has the advantage of avoiding tracheal intubation and worsening of the postoperative pulmonary function.³ With improvement of anesthetic techniques, of drugs utilized and of intra- and postoperative cares, it became possible to reduce morbidity and mortality of patients, classically viewed as contraindicated for surgery. Interaction between the clinical, surgical and anesthetic teams becomes essential in the management of such patients.

The objective of this study was to present a case of application of noninvasive mechanical ventilation (NIMV) during hip arthroplasty of a patient with severe COPD, associated to regional anesthesia (spinal).

Received from the Clínica São Vicente, Rio de Janeiro (RJ), Brazil.

Submitted on May 5, 2008

Accepted on July 28, 2008

Address for correspondence:

Geraldo Ângelo Gonçalves, MD
R. Hildebrando de Araújo Góes 55,
Bloco 1/203
Barra da Tijuca
22793-250 Rio de Janeiro, (RJ), Brazil.
Phone: 21 3325-2294
E-mail: geraldoangelo@uol.com.br

CASE REPORT

A male, 81 years old, 75 kg patient was admitted after a fall from his own height, presenting with pain, external rotation deformity and shortening of the lower right limb and was diagnosed as displaced femoral neck fracture Garden IV (Figure 1) with indication for partial hip arthroplasty. Bearer of severe COPD, presenting respiratory function test (RFT) with a forced expiratory volume in 1 second (FEV_1) <20%, while using domestic oxygen therapy, corticoid therapy and presenting with dyspnea at minimal efforts.

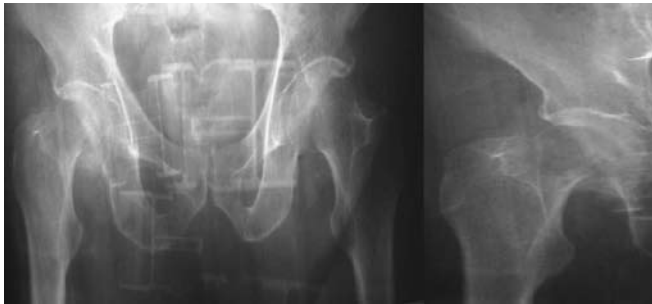

Figure 1 – Non-pathological fracture of the right femoral neck .

Furthermore, the patient had undergone a coronary angioplasty with placement of a drug-eluting stent two years earlier. As comorbidities he has hypothyroidism and diabetes mellitus type II with regular use of prednisone, bamifylline, inhalatory β -agonist and ipatropium, acetylsalicylic acid and pantoprazole.

At pre-operative evaluation he was bedridden, with

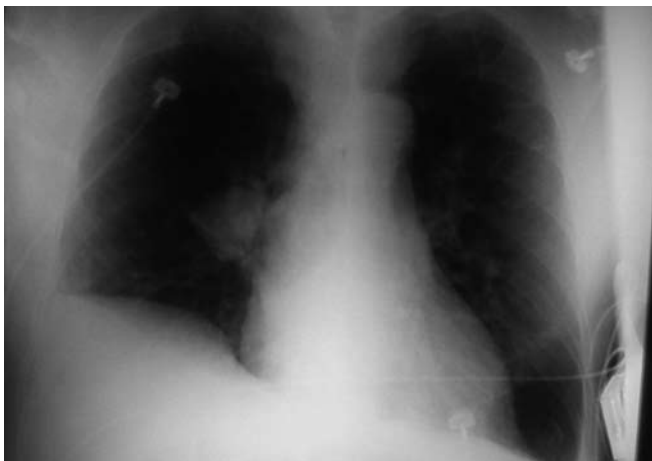

Figure 2 – Chest x-ray disclosing pulmonary hyperinsufflation, elevation of the right phrenic dome previous lobectomy due to benign pulmonary nodule and calcified hilar mass also to the right.

pain in the lower right limb, tachypnea, hemodynamically stable and with 88% oxygen saturation. Patient alternated use of NIMV/ *Bi-level Positive Airway Pressure* (BIPAP) with nasal 3L/min oxygen O_2 . Complementary exams showed hematocrit 36%; normal leukogram and coagulogram; echocardiogram with mild ventricular dysfunction; chest X-ray (Figure 2). arterial pre-operative gasometry under O_2 at 4 L/min showed pH – 7.38, pCO_2 - 54 mmHg, pO_2 - 93 mmHg, HCO_3 – 31.2 mmol/L, *base excess*: 4.9, SpO_2 : 96%.

After monitoring by cardioscope, noninvasive pressure and pulse oximetry, a peripheral venous access was punctured and cefazolin 2 g and hydrocortisone 200 mg were administered. NIMV with BIPAP under full face mask (Figure 3) was administered with the parameters expiratory positive airway pressure (EPAP) of 7cmH $_2$ O, inspiratory positive airway pressure (IPAP) 15 cmH $_2$ O and O_a flow of 3 L/min.

Diazepam 1 mg and cefotamine 5 mg both intravenous, for positioning on left lateral decubitus were administered. Simple isobaric spinal anesthesia was given in the subdural space in the L $_3$ -L $_4$, spaces, needle 25G. First trial, liquor was clear and injection of isobaric bupivacaine 16mg with final sensory level at T $_{10}$. Continuous infusion of dexmedetomidine 0.2 μ g/kg/min was begun for sedation. The surgical procedure was comprised of partial bipolar arthroplasty of the hip with the contemporary technique of femoral stem cementing, on the left lateral decubitus for some 75 minutes. During implant of the medullary cemented prosthesis, patient presented with temporary oxygen desaturation to 80% and bronchospasm which was reverted by adjusting parameters to

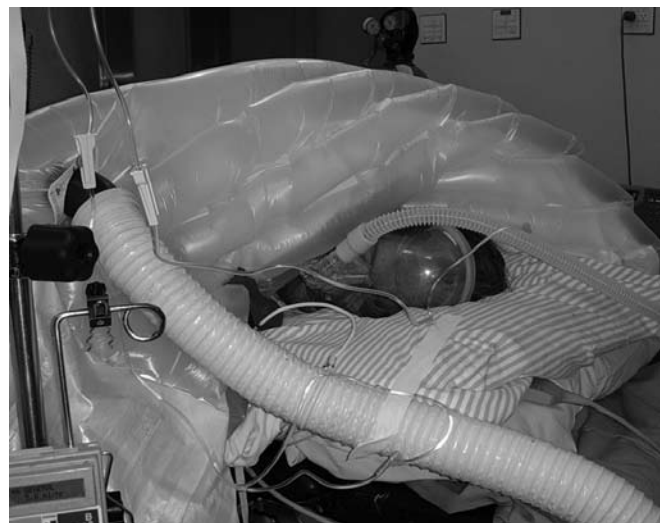


Figure 3 - Patient using noninvasive ventilation in the intraoperative.

IPAP 17 cmH₂O and EPAP 8 cmH₂O associated with administration of inhalatory β -agonist and ipatropium. He was then referred to intensive care unit (ICU) hemodynamically stable, with a 94% saturation on BIPAP, lucid, oriented and painless.

Postoperative progressed with hemodynamic stability; good control of pain using dipyrone associated to tramadol and continued use of NIMV/BIPAP during the first 24 hours following procedure. Thereafter, the patient resumed use of nasal oxygen and intermittent NIMV. Post-procedure arterial gasometry showed: pH – 7.38, pCO₂ – 54 mmHg, pO₂ – 63 mmHg, HCO₃ – 31.2 mmol/L, base excess: 4.8, sO₂: 92%. Patient was transferred to the semi-intensive care unit 10 days after procedure.

DISCUSSION

Prevalence of COPD is estimated at 6% and became the main cause of mortality among respiratory diseases.^{1,4} Adequate pre and intraoperative assessments estimates of surgery cost-benefit, type of anesthesia, ventilation assistance and hemodynamic support increase survival of these patients at postoperative.

The patient presented a pulmonary condition with severe restrictions; however acute disease worsened the condition requiring a planning of intraoperative ventilation support appropriate for the situation.

While, among the general population the rate of postoperative pulmonary complications ranges from 5% to 12%⁵⁻⁶, in patients with COPD, the number and type of complications increase substantially (37% of cases)³ for this reason in the decade of 1970, some authors recommended that only life-saving surgeries should be carried out in patients with a FEV₁ < 0.5L. The option of not operating this patient was considered, because of the severity of the condition, however this would mean an increase of morbidity, mortality (60 to 70%)⁷ and would increase the patient's physical impairment.

A recent study³ stated that, in patients with COPD, the most common postoperative complications are an increase in ICU length of stay and bronchospasm. Yet the risk factors associated to respiratory complications observed were: American Society of Anesthesiology (ASA) score > 4, Shapiro score > 5 and decrease of FEV₁. The patient under study presented risk factors for the described complications, so much so that during the postoperative period he presented bronchospasm. If the ventilatory mode used during surgery of hip arthroplasty alters the intra- and postoperative complications of these patients is a fact that still remains unknown.

Due to the restricted number of patients with COPD submitted to hip arthroplasty and the large variation in the severity of this disease it is difficult to carry out a randomized study with a large population in order to evaluate the morbidity/mortality inherent to the ventilation mode.

Regional anesthesia is described as the preferential mode for patients with COPD and respiratory failure when compared to general anesthesia.² Factors of general anesthesia such as atelectasia, cephalic displacement of the diaphragm and loss of respiratory stimulus are attributed to this worsening.⁸ Notwithstanding that regional anesthesia is also associated to a decrease of the respiratory function, occurrence of such an event is less frequent and intense when compared to general anesthesia.

General anesthesia, in addition to be considered a risk factor for mortality in hip surgery, is associated to complications and worsening in the ventilation pattern at intra- and postoperative of patients with COPD.⁹ Although regional anesthesia is suitable for hip surgery, factors related to its use, such as positioning, surgical stress, sedation and neuromuscular block may worsen the respiratory condition, therefore the need arises for adequate intraoperative support in patients with a previously poor pulmonary function, such as patients with COPD.¹⁰

The combination of regional anesthesia associated to NIMV during intraoperative of patients with COPD and respiratory failure was recently described in literature¹¹⁻¹⁵, with few reports on hip arthroplasty.¹²⁻¹³

NIMV is a well-known method for decrease of mortality, improvement of respiratory distress and correction of blood gas disorders in exacerbation of COPD.¹⁶⁻¹⁷ During surgery, tracheal intubation may also be used as a support ventilatory mode in respiratory failure and in COPD. Although it is not associated to an increase of mortality in patients with COPD admitted to ICU¹⁸ tracheal intubation may entail spirometric worsening at postoperative of healthy patients.¹⁹ However it is not known whether this worsening observed in the spirometric pattern of healthy patients, also takes places in patients with COPD and whether it may contribute to increased mortality or postoperative cost – when compared to patients who have used NIMV in the intraoperative.

Management of an obese patient with severe COPD submitted to hip arthroplasty under spinal anesthesia and BIPAP was previously described.¹² Risks of general anesthesia with tracheal intubation in this population are reported, as well as need for compliance to the method as the essential problem. In the case reported, previous

knowledge of the patient's tolerance regarding NIMV facilitated its use. The patient of the study was discharged 7 days after surgery, while the patient in this case remained in the ICU for 10 days. It is noteworthy that although intensive care length of stay is longer in the report on our patient, he showed more severity factors in surgery (lower FEV₁, older, obesity).

NIMV has also been reported in patients with acute ventilation impairment. One case of worsened chronic respiratory failure, submitted to spinal anesthesia and support with NIMV avoiding general anesthesia, was reported.¹³ Warren et al. described the case of a patient with myasthenia gravis and acute respiratory failure submitted to obstetric surgery under peridural anesthesia using noninvasive ventilation support.¹⁴ The position required for the surgical procedure often involves undesirable and intolerable ventilatory alterations in pulmonary sick patients.¹⁰ An English group described use of NIMV in a severe COPD patient submitted to resection of a carcinoma of the rectum, under spinal anesthesia in lithotomic position¹¹. NIMV allowed the patient to tolerate the respiratory restriction imposed by the position of lithotomy, avoiding general anesthesia.

In view of this evidence, NIMV has been evaluated in patients with chronic and acute ventilation impairment. However, other groups of patients and surgical procedures may benefit from this intraoperative ventilation mode.

NIMV was also described by a Japanese group for patients submitted to craniotomy for cerebral mapping¹⁶. NIMV allowed for a sufficient anesthetic depth during bone opening and closure, total awareness during mapping, smooth transition between anesthesia and consciousness, suitable ventilation and immobility with comfort for the patient.

NIMV has been well documented in COPD during periods of acute exacerbations, reducing the respiratory work and improving clinical results^{8,20}, however its benefit during the anesthetic-surgical procedure remains undefined.

CONCLUSION

This case and the others reported in literature have proven the simple and easy applicability of NIMV at intraoperative period. NIMV appears to be a useful intraoperative ventilation support in situations of chronic disease, such as advanced COPD, as well as in worsened chronic and acute situations. Other groups of patients have been reported and may benefit. The anesthesiologist must become familiar with the noninvasive method and together with the clinical team, evaluate which patients will truly benefit from this type of support.

RESUMO

O manuseio anestésico de pacientes com doença pulmonar obstrutiva crônica grave é extensamente discutido devido ao elevado número de complicações destes pacientes, quando submetidos à procedimentos cirúrgicos de médio e grande porte. O objetivo deste estudo foi relatar um caso de paciente idoso portador de doença pulmonar obstrutiva crônica grave e coronariopatia, submetido a artroplastia de quadril sob anestesia espinal e suporte intra-operatório de ventilação mecânica não-invasiva – *bilevel positive airway pressure*. Paciente do sexo masculino, 81 anos, doença pulmonar obstrutiva crônica grave (GOLD 4), submetido à artroplastia de quadril devido à fratura de fêmur sob anestesia espinal e suporte intra-operatório de ventilação mecânica não invasiva – *bilevel positive airway pressure*, sob parâmetros de pressão expiratória de 7 cmH₂O, pressão inspiratória 15 cmH₂O e fluxo de O₂ de 3 L/min. Apresentou um episódio de broncoespasmo, revertido farmacologicamente, sem apresentar complicações no pós-operatório. A combinação de técnica anestésica regional com ventilação mecânica não-invasiva é de fácil aplicação e pode ser útil no intra-operatório destes pacientes de alto risco anestésico. A interação entre a equipe clínica, cirúrgica e de anestesia propiciou benefícios e reduz a morbimortalidade associada a procedimentos de grande porte em pacientes graves.

Descritores: Doença pulmonar obstrutiva crônica; Artroplastia de quadril; Respiração artificial; Respiração com pressão positiva; Anestesia epidural; Humano; Masculino; Idoso; Relatos de casos

REFERENCES

- Mannino DM. COPD: epidemiology, prevalence, morbidity and mortality, and disease heterogeneity. *Chest*. 2002; 121(5 Suppl):121S-126S. Review.
- Licker M, Schweizer A, Ellenberger C, Tschopp JM, Diaper J, Clergue F. Perioperative medical management of patients with COPD. *Int J Chron Obstruct Pulmon Dis*. 2007; 2(4):493-515.
- Wong DH, Weber EC, Schell MJ, Wong AB, Anderson CT, Barker SJ. Factors associated with postoperative pulmonary complications in patients with severe chronic obstructive pulmonary disease. *Anesth Analg*. 1995; 80(2):276-84.
- Menezes AM, Jardim JR, Perez-Padilla R, Camelier A, Rosa F, Nascimento O, et al. Prevalence of chronic obstructive

- pulmonary disease and associated factors: the PLATINO Study in Sao Paulo, Brazil. *Cad Saude Publica*. 2005; 21(5):1565-73.
05. Mircea N, Constantinescu C, Jianu E, Busu G. Risk of pulmonary complications in surgical patients. *Resuscitation*. 1982; 10(1):33-41.
 06. Wightman JA. A prospective survey of the incidence of postoperative pulmonary complications. *Br J Surg*. 1968; 55(2):85-91.
 07. de Luise C, Brimacombe M, Pedersen L, Sorensen HT. Chronic obstructive pulmonary disease and mortality following hip fracture: a population-based cohort study. *Eur J Epidemiol*. 2008; 23(2):115-22.
 08. Henzler D, Rossaint R, Kuhlen R. Anaesthetic considerations in patients with chronic pulmonary disease. *Curr Opin Anaesthesiol*. 2003; 16(3):323-30.
 09. Radcliff TA, Henderson WG, Stoner TJ, Khuri SF, Dohm M, Hutt E. Patient risk factors, operative care, and outcomes among older community-dwelling male veterans with hip fracture. *J Bone Joint Surg Am*. 2008; 90(1):34-42.
 10. Smetana GW. Preoperative pulmonary evaluation. *N Engl J Med*. 1999; 340(12):937-44. Review.
 11. Bapat PP, Anderson JA, Bapat S, Sule A. Use of continuous positive airway pressure during spinal anaesthesia in a patient with severe chronic obstructive pulmonary disease. *Anaesthesia*. 2006; 61(10):1001-3.
 12. Leech CJ, Baba R, Dhar M. Spinal anaesthesia and non-invasive positive pressure ventilation for hip surgery in an obese patient with advanced chronic obstructive pulmonary disease. *Br J Anaesth*. 2007; 98(6):763-5.
 13. Thys F, Delvau N, Roeseler J, Spencer S, Singelyn F, Manche E, et al. Emergency orthopaedic surgery under noninvasive ventilation after refusal for general anaesthesia. *Eur J Emerg Med*. 2007; 14(1):39-40.
 14. Warren J, Sharma SK. Ventilatory support using bilevel positive airway pressure during neuraxial blockade in a patient with severe respiratory compromise. *Anesth Analg*. 2006;102(3):910-1. Comment in: *Anesth Analg*. 2006; 103(6):1603-4.
 15. Watanabe M, Kanda T, Maruyama S, Ikeda Y, Endo K, Susa R, et al. Gastrectomy performed with noninvasive positive pressure ventilation for a patient with severe chronic obstructive pulmonary disease: report of a case. *Surg Today*. 2005; 35(8):696-9.
 16. Yamamoto F, Kato R, Sato J, Nishino T. Anaesthesia for awake craniotomy with non-invasive positive pressure ventilation. *Br J Anaesth*. 2003; 90(3):382-5.
 17. Lumbierres M, Prats E, Farrero E, Monasterio C, Gracia T, Manresa F, et al. Noninvasive positive pressure ventilation prevents postoperative pulmonary complications in chronic ventilators users. *Respir Med*. 2007; 101(1):62-8.
 18. Afessa B, Morales IJ, Scanlon PD, Peters SG. Prognostic factors, clinical course, and hospital outcome of patients with chronic obstructive pulmonary disease admitted to an intensive care unit for acute respiratory failure. *Crit Care Med*. 2002; 30(7):1610-5.
 19. Natalini G, Franceschetti ME, Pletti C, Recupero D, Lanza G, Bernardini A. Impact of laryngeal mask airway and tracheal tube on pulmonary function during the early postoperative period. *Acta Anaesthesiol Scand*. 2002; 46(5):525-8.
 20. Collaborative Research Group of Noninvasive Mechanical Ventilation for Chronic Obstructive Pulmonary Disease. Early use of non-invasive positive pressure ventilation for acute exacerbations of chronic obstructive pulmonary disease: a multicentre randomized controlled trial. *Chin Med J*. 2005; 118(24):2034-40.