

Submucous Implant of Abrasive Dental Materials in Rat Tongues: Clinical and Histological Evaluation

Alexandre Dorneles PISTÓIA¹
Maria Antonia Zancanaro de FIGUEIREDO²

¹*School of Dentistry, Federal University of Santa Maria, Santa Maria, RS, Brazil*

²*School of Dentistry, Pontifical Catholic University of Rio Grande do Sul, Porto Alegre, RS, Brazil*

This study evaluated the clinical and histological manifestations produced by the submucous implant of abrasive dental materials in the rat tongue. A total of 128 rats were divided into 4 groups of 32 rats each, according to the material selected for the implant: Herjos-F prophylactic paste both in its normal composition as well as lacking its abrasive components, SS White pumice stone and the abrasive powder of the 3M finishing and polishing sandpaper. The specimens were submitted to clinical and histological analyses at 30, 60, 90 and 120 days. After 90 days, the formation of nodular lesions in animals implanted with materials containing abrasive substances was observed. Histologically, these materials produced marked chronic granulomatous reactions. Herjos-F prophylactic paste produced the greatest reaction. However, without the abrasive components, this paste caused the mildest tissue reactions, with no inflammatory response, that was seen in a progressively greater number of cases after 90 days.

Key Words: dental materials, foreign bodies, oral mucous membrane, rats.

INTRODUCTION

A great variety of exogenous bodies have been identified and described as acting as foreign bodies when inside the oral tissues. In many cases, dental materials may accidentally be introduced into these tissues.

Daley and Wysocki (1) and Gordon and Daley (2) have reported that abrasive dental materials may be responsible for many foreign body reactions developed in the soft oral tissues. Using ultra-structural studies, they detected the presence of particles containing silicon, calcium and aluminum in a considerable number of cases. These materials are usual components of abrasive dental materials such as dentifrices, prophylactic pastes and sandpaper for polishing. Those containing silicon (especially in the form of silica) have been receiving the most attention from researchers. When implanted in the human soft tissues, these substances have been associated with the development of foreign body granulomas (3-6).

The Oral Diagnosis Service at São Lucas Hospital of the Pontifical Catholic University of Rio Grande do Sul was consulted by a patient who was suffering

from an ulcerous-vegetating lesion on the sublingual region of the mouth. This lesion developed 3 months after trauma during abrasion of a dental calculus, followed by polishing with a prophylactic paste. There was an intense inflammatory reaction of a foreign body granuloma. However, the exogenous body which may have caused this reaction was not identified, but was observed microscopically to be composed of crystal particles, suggesting the presence of abrasive materials.

Thus, the aim of this investigation was to detect and compare the tissue reactions clinically and histologically produced by the submucous implantation of abrasive dental materials in the oral cavity.

MATERIAL AND METHODS

In this study, 128 Wistar rats were randomly divided into 4 groups of 32 rats each, according to the material implanted: Herjos-F prophylactic paste (Vigodent S.A., Rio de Janeiro, RJ, Brazil), containing pumice stone (composed basically of silica) and calcium carbonate as abrasive substances (group 1); Herjos-F prophylactic paste without its abrasive com-

ponents (group 2) (control 1); SS White pumice stone (Rio de Janeiro, RJ, Brazil), composed basically of silica (group 3); 3M dental finishing and polishing sandpaper (Sumaré, SP, Brazil), with aluminum oxide as the abrasive substance (group 4).

After anesthesia and incision in the middle third of the mucosa of the tongue dorsum, group 1 animals received an injection of 0.1 ml Herjos-F paste with a hypodermic syringe (Terumo Medical Co., São Paulo, SP, Brazil). Group 2 animals also received the injection of 0.1ml of the Herjos-F paste but without abrasive components. Group 3 animals were implanted with 0.1 g SS White pumice stone using an amalgam holder (Golgran, São Paulo, SP, Brazil), and group 4 animals were implanted with 0.1 g abrasive powder of the 3M sandpaper, also with the amalgam holder. In group 4 animals, a control incision was additionally executed (Control 2) on the posterior third of the mucosa of the tongue dorsum, without the implantation of any material. All incisions were sutured with 4-0 mononylon (Ethicon, São José dos Campos, SP, Brazil) that was removed after 7 days.

After 30, 60, 90 and 120 days, 8 animals of each group, selected randomly, received anesthesia for visual inspection by two observers, who registered the absence or presence of clinical alteration, as well as its form of presentation and diameter in mm. The animals were then sacrificed and tissue was removed and submitted to routine histological processing with hematoxylin and eosin. The sections were analyzed by two observers, and the presence or absence of foreign material, neutrophils, eosinophils, lymph and plasma cell infiltrates, macrophages, giant cells, granulomas, fibroblastic condensation, hyperkeratosis, acanthosis and hyperplasia were recorded.

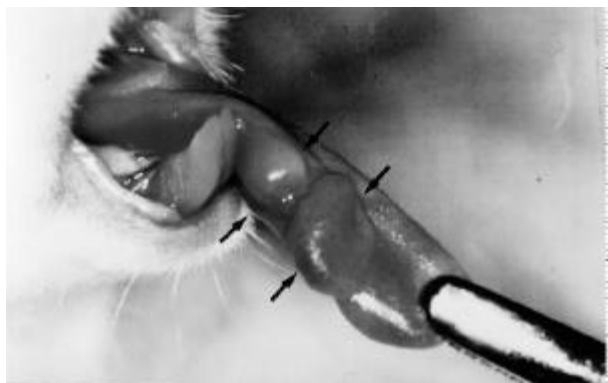

Figure 1. Lesion caused by the implantation of the Herjos-F prophylactic paste at 120 days.

Descriptive statistics and the chi-square and Mann-Whitney tests were utilized for the statistical analysis.

RESULTS

Clinical Evaluation

Nodular lesions were observed at 90 days with Herjos-F paste, SS White pumice stone and abrasive powder of the 3M sandpaper. Herjos-F paste lesions were found in 3 (37.5%) and 5 (62.5%) specimens at 90 and 120 days, respectively (Figure 1). There were lesions in 3 (37.5%) and 2 (25%) animals 90 and 120 days, respectively, in the group implanted with SS White pumice stone and lesions were observed in 2 (25%) and 4 (50%) animals implanted with the abrasive powder of the 3M sandpaper. On the other hand, the Herjos-F paste without its abrasive components did not induce the formation of clinical lesion in any specimen.

The diameters of these oral mucosa lesions were the largest at 120 days (Mann-Whitney nonparametric test, $p < 0.05$): Herjos-F (90 days: 0.3-0.4 cm; 120 days: 0.4-0.6 cm); SS White pumice stone (90 days: 0.3-0.4 cm; 120 days: 0.4-0.6 cm); 3M sandpaper (90 days: 0.3 cm; 120 days: 0.4-0.6 cm).

Histologic Evaluation

The presence of foreign material could be observed in all specimens that had been implanted with the materials containing abrasives; however, no structure was observed in the group implanted with Herjos-F paste without abrasive materials indicating that it had been previously absorbed.

Neutrophils were present in 50% of the cases in the 4 groups that were implanted with Herjos-F paste. The Herjos-F paste without abrasives produced neutrophils in only 25% of the cases on the 30th day. Neutrophils were observed in the SS White pumice stone group in 75% of the specimens at 30 days but were not observed in the animals implanted with 3M sandpaper abrasive powder.

Eosinophils were seen extensively with the use of Herjos-F paste in 100% of the cases at 90 days and 87.5% at 120 days (Figure 2). The Herjos-F paste without abrasives produced a discrete presence of eosinophils in 25% of the cases at 30 days. The SS White

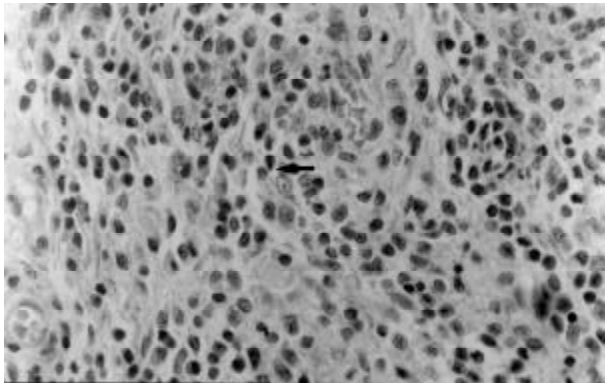


Figure 2. Presence of eosinophils caused by the implantation of Herjos-F prophylactic paste. Magnification 400X.

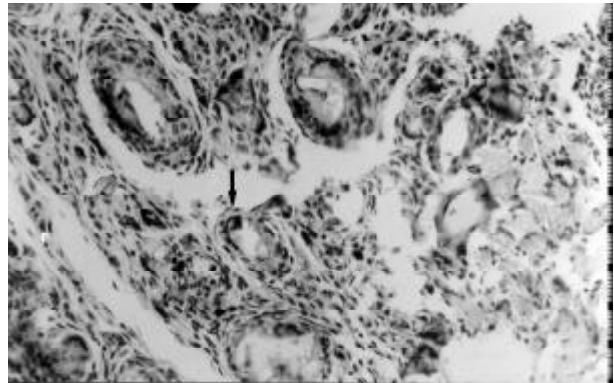


Figure 5. Presence of multinucleated giant cells phagocytizing the abrasive powder of the 3M sandpaper. Magnification 200X.

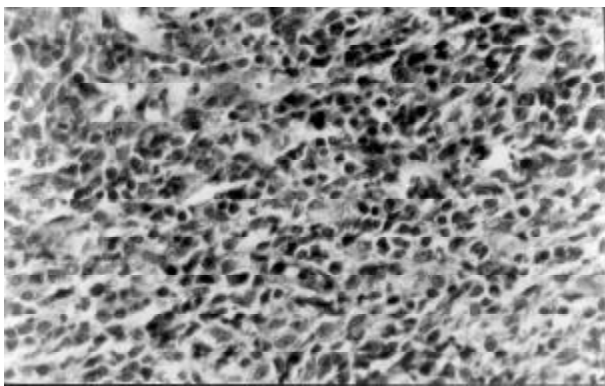


Figure 3. Presence of intense lympho-plasmocyte infiltrates caused by the implantation of Herjos-F prophylactic paste. Magnification 400X.

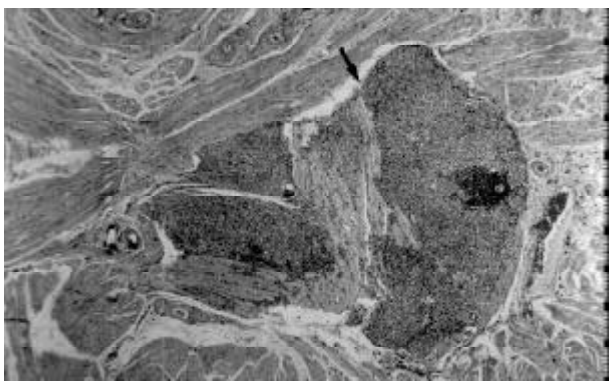


Figure 6. Presence of granuloma caused by the implantation of Herjos-F prophylactic paste. Magnification 100X.

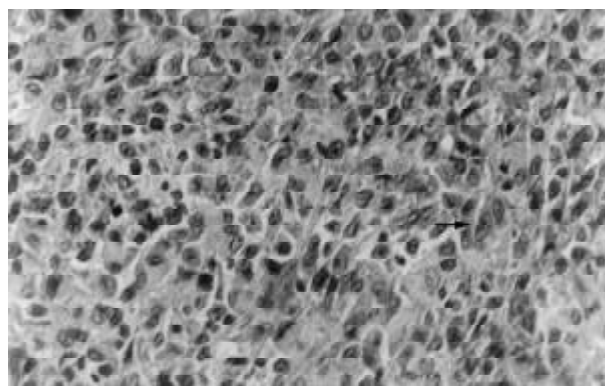


Figure 4. Presence of macrophages caused by the implantation of Herjos-F prophylactic paste. Magnification 400X.

pumice stone induced eosinophilia in 75% of the specimens at 30 and 60 days and in 37.5% and 25% at 90 and 120 days, respectively. Eosinophils were not observed with the use of the powder of the 3M sandpaper.

There was a discrete to moderate presence of lymphocyte and plasma cell infiltrates in all animals implanted with SS White pumice stone and the 3M sandpaper powder. In the specimens in which the Herjos-F paste without abrasives was used, lymphocyte and plasma cell infiltrates were present in 100% of the cases at 30 and 60 days, and decreased to 62.5% and 37.5% at 90 and 120 days. With the use of the Herjos-F paste, these infiltrates were intensively present in all animals (Figure 3).

Macrophages and giant cells were detected in 100% of the cases at all times when the materials containing abrasives were implanted (Figures 4 and 5).

The Herjos-F paste without abrasives caused macrophages in 100% of the cases at 30 and 60 days, and 62.5% and 37.5% at 90 and 120 days, respectively. There were no giant multinucleous cells in any time with this same paste.

Granuloma was present in all specimens in which the materials containing abrasive substances were used (Figure 6), but this was not observed with the Herjos-F paste without abrasives. Hyperkeratosis of the epithelial coating was not observed in the animals which had been implanted with the Herjos-F paste, Herjos-F without abrasives and abrasive powder of the 3M sandpaper; however, with the SS White pumice stone, hyperkeratosis was present in 50% of the cases at 30 days and 25% at the other intervals.

Acanthosis was not observed with the use of the Herjos-F paste and the Herjos-F paste without abrasives but it was observed among the specimens implanted with the SS White pumice stone in percentages of 50%, 75%, 87.5% and 50% at 30, 60, 90 and 120 days, respectively. With the 3M sandpaper powder, acanthosis occurred in 12.5% of the cases at 60 days, 25% at 90 days and 50% at 120 days.

Hyperplasia was not present in the animals that were implanted with Herjos-F paste and Herjos-F without abrasives. The SS White pumice stone caused hyperplasia in 37.5% of the cases at 30 and 120 days and in 75% at 60 and 90 days. The 3M sandpaper caused hyperplasia in only 25% of the specimens at 120 days.

DISCUSSION

The involuntary implantation of abrasive dental materials in soft oral tissues is an issue that has received very little attention by the scientific community. Moreover, the few authors who discuss this issue do so in a much more suggestive rather than conclusive manner. There is no experimental research related to this subject, only a few isolated clinical reports that did not provide any definitions regarding the inherent aspects to this theme. In 1938, Kaletski (7) reported only the clinical and histological findings of a case and did not suggest a possible source for the foreign particles in the tissues. Similarly, Kramer (8), Marsland and Fox (9), Daley and Wysocki (1) and Gordon and Daley (2) have described clinical and histological findings limiting to the supposition that the exogenous materials observed had probably originated from abrasive dental materials.

The abrasive materials evaluated in the present study were chosen because they are the most used by professionals in dentistry. It is of utmost importance that these materials contain abrasive substances including silicon, aluminum and calcium as their main components, chemical elements detected in a great variety of cases of foreign body reactions in the oral cavity (1,2,10). Moreover, there are many authors who have reported granulomatous lesions caused by silica (3-6,9,11).

Herjos-F paste without its abrasive components was included in the present study to verify to what extent these elements influence tissue response especially because the Herjos-F paste is a product which presents a considerable variety of substances in its composition. Thus, it was possible to observe the differences between the tissue reactions as well as attribute, without doubt, the effect of the presence of abrasive elements in tissues.

In this investigation, lesions in the oral mucosa of rats began between the 60th and 120th day of contact with the abrasive materials. The results of the Herjos-F prophylactic paste and the SS White pumice stone (materials with silica in their composition) are in agreement with those of Moore and Barker (11) who reported a clinical case in which a lesion developed 3 months after the introduction of a dental material containing silica. On the other hand, the presents results differ considerably from the clinical reports of Shattock (3), Epstein (4) and Hannon et al. (6), who reported that clinical alterations occurred only after 10, 12 and 13 years, respectively, after the accidental implantation of silica composites.

Many authors (4,6,12,13) consider that substances containing silica produce granulomatous lesions only after many years. This latency period is believed to be due to the theory that gross silica, such as the one present in sand, does not present a potential to induce this type of alteration. These authors believe that the harmful effects of this material are dependant on a slow dissolution of its particles by tissue fluids, thus originating the so-called colloidal state (particles with the size between 1 and 200 nanometers) with the capacity to cause granulomatous reactions. The results obtained in the present study do not follow this line of reasoning because SS White pumice stone, which only contains pumice stone in its composition, developed these lesions in less than 6 months. This material is composed

of small abrasive particles (mean diameter 5 micrometers) and because the action of phagocytes and tissue fluids takes much longer to produce colloidal particles, the results obtained lead us to believe that small particles not necessarily in a colloidal state present potential for the development of clinical lesions. Therefore, the findings are in accordance with the observations of Cataldo and Santis (14) who analyzed many cases of oral tissue reactions to composites containing silica, and have detected results which are contrariwise proportional to the size of the particles: the smaller particles induced greater reactions. Nevertheless, they did not mention the need of a colloidal state for reactions.

The occurrence of neutrophils was maintained during all time periods only with the Herjos-F prophylactic paste. With implantation of the Herjos-F paste without abrasives as well as the SS White pumice stone, neutrophils were present only at 30 days. This indicates that the abrasive substances contained in the Herjos-F paste caused the different results compared to the paste without abrasives, and the presence of calcium carbonate in this paste caused the differences observed with the SS White pumice stone. Contrasting with the reports involving abrasive substances or chemical elements which are part of them, only Sheikh et al. (15) reported the presence of acute inflammatory infiltrate when magnesium silicate was subcutaneously implanted in mice.

Eosinophils were found in a higher and constant number with the use of the Herjos-F prophylactic paste, and were present in only 25% of the cases on the 30th day with the Herjos-F paste without abrasives. The SS White pumice stone produced eosinophils at all times, however from the 90th day on the percentage declined and on the 120th day eosinophils were found in only 25% of the specimens. Polymorphonuclear eosinophils were not detected with the implantation of the abrasive powder of the 3M sandpaper. Only Hannon et al. (6) reported a case in which a dispersion of eosinophils was verified with responses presented by the tissues implanted with a substance containing silica (sand).

With the use of the Herjos-F paste without abrasives, at 30 and 60 days the lympho-plasmocytes appeared in all animals, though in a discrete and moderate way. At 90 days, the percentage of discrete to moderate cases was 62.5%, decreasing to 37.5% at the end of 120 days. It is important to note that this material was the only one to elicit no inflammatory reaction in some of the specimens. This contrasts with the use of

regular Herjos-F paste, which had the greatest and most constant lympho-plasmocyte reaction. Thus, we deduce this was produced exclusively by the action of abrasive substances contained in the paste. The SS White pumice stone and the abrasive powder of the finishing and polishing 3M sandpaper produced discrete to moderate forms of lympho-plasmocytes in all samples at all times. These findings are in agreement with the literature (3-5,7-9,11,13-15). The presence of lympho-plasmocyte cells is also reported by Daley and Wisocki (1) and Gordon and Daley (2) where foreign particles frequently containing calcium, silicon and aluminum were found in the interior of gingival tissues.

Macrophages and giant multinucleated cells were present at all time intervals, in all specimens in which the Herjos-F paste, the SS White pumice stone and the abrasive powder of the finishing and polishing 3M sandpaper were implanted. These cells were concentrated in the vicinities of the implanted material and it was possible to observe the presence of the material in its interior. It is important to observe that macrophages predominated during the experiment in accordance with the findings of others (3-9,13-16). In publications involving not only silica but also aluminum and calcium, the presence of macrophages and multinucleated giant cells was also reported (1,2).

The formation of granulomas of high cell renewal with the use of materials containing silica (Herjos-F paste and SS White pumice stone) are in agreement with the findings of Catanzaro-Guimarães (17) and Pinto et al. (18). They consider the granulomatous inflammation caused by silica to be of high cellular renewal, i.e., that develops when the phlogogen interacts with macrophages, that, once activated, secrete hydrolytic enzymes that generate chemotactil factors for new blood cells and activate substances of macrophages. This agent is harmful to these cells, and great loss occurs as well as an increase of local proliferation that also contributes to increase cellular renewal.

We conclude that further studies should be carried out to search for abrasive dental materials that are efficacious but are not harmful to the oral tissues in case involuntary implantation occurs.

RESUMO

Pistóia AD, Figueiredo MAZ. Implante submucoso de materiais abrasivos de uso odontológico em língua de ratos: avaliação clínica e histológica. *Braz Dent J* 2002;13(x):103-108.

Este estudo foi realizado com o objetivo de avaliar as manifestações clínicas e histológicas produzidas a partir da implantação submucosa, em língua de ratos, de materiais abrasivos de uso odontológico. Foram utilizados 128 ratos divididos em 4 grupos de 32 ratos cada, de acordo com o material a ser implantado. Deste modo, a pasta profilática Herjos-F tanto na sua composição normal como desprovida de seus componentes abrasivos, a pedra-pomes da SS White e o pó abrasivo da lixa de acabamento e polimento dental 3M foram implantados individualmente, na submucosa do dorso lingual, em 32 animais para cada material. Os espécimes foram submetidos às análises clínica e histológica em intervalos temporais de 30, 60, 90 e 120 dias. Na avaliação clínica, a partir do observado aos 90 dias, constatou-se que houve formação de lesões nodulares em animais implantados com os materiais contendo substâncias abrasivas na composição. Histologicamente, tais materiais produziram marcantes reações crônicas granulomatosas, onde as de maior exuberância e variedade celular foram promovidas pela pasta profilática Herjos-F. Por outro lado, esta mesma pasta, quando desprovida de seus componentes abrasivos, suscitou as mais brandas reações teciduais, inclusive com ausência de resposta inflamatória, verificada, em um número progressivamente maior de casos, a partir do intervalo de 90 dias.

Unitermos: materiais dentários, corpos estranhos, mucosa bucal, ratos.

REFERENCES

- Daley TD, Wysocki GP. Foreign body gingivitis: an iatrogenic disease? *Oral Surg* 1990;69:708-712.
- Gordon SC, Daley TD. Foreign body gingivitis: clinical and microscopic features of 61 cases. *Oral Surg* 1997;83:562-570.
- Shattock SG. Pseudotuberculoma silicoticum of the lip. *Proc R Soc Med* 1916;10:6-19.
- Epstein E. Silica granuloma of the skin. *Archs Derm* 1955;71:24-35.
- Miller WA. Foreign body reaction to an industrial polishing agent containing silicate. *Dent Practnr Dent Rec* 1970;20:314-316.
- Hannon SM, Pickett AB, Frost JM. Foreign body (silica) granuloma of the lip. *J Oral Maxillofac Surg* 1983;41:470-472.
- Kaletsky T. Chronic granulomatous inflammation. *Archs Clin Oral Path* 1938;2:70-73.
- Kramer IRH. Silicious granulomatosis of the gingiva. *Br Dent J* 1951;91:309-313.
- Marsland A, Fox EC. A case of ulceration and pain of the gingival and oral mucosa associated with the presence of silica. *Br Dent J* 1955;16:115-118.
- Gordon SC, Daley TD. Foreign body gingivitis: identification of the foreign material by energy-dispersive X-ray microanalysis. *Oral Surg* 1997;83:571-576.
- Moore DL, Barker BF. A foreign body lesion of the gingiva subsequent to the placement of a composite resin restoration. *Quintessence Int* 1986;17:785-787.
- Gardner LV. The similarity of the lesions produced by silica and by the tubercle bacillus. *Am J Pathol* 1937;13:13-23.
- Shelley WB, Hurley HJ. The pathogenesis of silica granulomas in man: a non-allergic colloidal phenomenon. *J Invest Derm* 1960;34:107-123.
- Cataldo E, Santis H. Response of the oral tissue to exogenous foreign materials. *J Periodontol* 1974;45:93-106.
- Sheikh KMA, Duggal K, Relfson M, Gignac S, Rowden G. An experimental histopathologic study of surgical glove powders. *Archs Surg* 1984;119:215-219.
- Forman L, Shuttleworth CW. Chronic granuloma of the gum with swelling of the lip in a patient handling sodium silicate solution. *Proc R Soc Med* 1956;49:815-816.
- Catanzaro-Guimarães SAC. *Patologia Básica da Cavidade Bucal*. Rio de Janeiro: Guanabara Koogan, 1982.
- Pinto LP, Souza LB, Freitas RA, Figueiredo CRLV, Galvão HC, Câmara MLAS, Carvalho RA. *Patologia Bucal: Sinopse*. PROIN/EDUFRN, Natal 1997.

Accepted February 25, 2002