

Necrotic enterocolitis in pigs naturally infected by porcine circovirus type 2

Enterocolite necrótica em suínos naturalmente infectados por circovírus suíno tipo 2

Priscila Zlotowski^I André Mendes Ribeiro Corrêa^I David Emílio Santos Neves de Barcellos^{II}
Marisa Ribeiro de Itapema Cardoso^{III} Anílton Cesar Vasconcelos^{IV}
Luiza Amaral de Castro^I David Driemeier^{I*}

ABSTRACT

Samples of intestine with necrotic enteritis from 63 pigs naturally infected with porcine circovirus type 2 (PCV2) were studied. Colon was the main target of PCV2 associated necrotic enteritis in 60 cases. Immunohistological investigations were carried out to detect the presence of PCV2 in necrotic lesions and to identify the type of cells infected by the virus. Crypt epithelial cells had positive labelling for PCV2 in 17 cases. Depletion of goblet cells occurred in 10 cases. In 24 necrotic enteritis cases, co-infection of PCV2 and Salmonella was identified. An increased rate of apoptosis in the crypt epithelial cells of the large intestine from PCV2 of naturally infected pigs was observed. Immunohistochemical findings confirmed the presence of PCV2 within cells from necrotic intestinal tissue, suggesting that PCV2 may play a role in the development of those lesions. Diagnosis of necrotic enteritis associated with PCV2 should be based on the detection of PCV2 antigen or DNA in the necrotizing lesions. However, bacteriological examination should be performed to rule out the presence of bacterial agents, since co-infections are likely to occur in PCV2 affected pigs.

Key words: necrotic enterocolitis, PCV2 infection, swine.

RESUMO

Foram selecionadas amostras intestinais com enterite necrótica de 63 suínos naturalmente infectados pelo circovírus suíno tipo 2 (PCV2). Enterite necrótica associada com PCV2 ocorreu principalmente no cólon, em 60 casos. Análise imuno-histoquímica foi realizada para identificar a presença de PCV2 em lesões necróticas e o tipo de células

infectadas pelo vírus. Células epiteliais das criptas apresentaram marcação positiva para PCV2 em 17 casos. Depleção de células caliciformes ocorreu em 10 casos. Em 24 casos de enterite necrótica, observou-se co-infecção por PCV2 e Salmonella. Foi observado um aumento no índice de apoptose nas células das criptas do intestino grosso de suínos naturalmente infectados com PCV2. Os achados imuno-histoquímicos e histopatológicos sugerem que a infecção por PCV2 das células do tecido intestinal pode ocasionar enterite necrótica. O diagnóstico de enterite necrótica associada com PCV2 deve ser baseado na detecção do antígeno ou do DNA viral nas lesões necróticas. Contudo, análise bacteriológica deve ser realizada para descartar a presença de agente bacteriano, já que co-infecções são comuns.

Palavras-chave: enterocolite necrótica, infecção por PCV2, suíno.

INTRODUCTION

Porcine circovirus type 2 (PCV2) has been associated with several clinical diseases in pig herds worldwide. Postweaning multisystemic wasting syndrome (PMWS) was the first syndrome associated with PCV2 and is characterized by wasting, weight loss, and respiratory or intestinal problems (CLARK, 1997; SEGALÉS et al., 2005). However, PCV2 has also been associated with respiratory and enteric disease, reproductive failure and dermatitis and nephropathy syndrome (OPRIESSNIG et al., 2007), among other disorders.

^IDepartamento de Patologia Clínica Veterinária, Faculdade de Medicina Veterinária, Universidade Federal do Rio Grande do Sul (UFRGS). Av. Bento Gonçalves, 9090, CP 15094, 91540-000, Porto Alegre, RS, Brasil. E-mail: davetpat@ufrgs.br. *Autor para correspondência.

^{II}Setor de Suínos, UFRGS, Porto Alegre, RS, Brasil.

^{III} Departamento de Medicina Veterinária Preventiva, UFRGS, Porto Alegre, RS, Brasil.

^{IV}Departamento de Patologia Geral, Instituto de Ciências Biológicas, Universidade Federal de Minas Gerais (UFMG), Belo Horizonte, MG, Brasil.

In general, diseases affecting the intestinal tract are the most important economic problems in pig production. The prevalence and dynamic of enteric pathogens within a herd can be variable with several enteric infectious agents occurring concurrently. This gives rise to complex clinical patterns that make successful control measures difficult (THOMSON, 2006). The study of pathogens associated with enteric disorders and the possible interaction between them may provide important tools for the diagnosis and control of these diseases.

PCV2 infection has been associated with granulomatous enteritis (KIM et al., 2004). Moreover, the virus has been identified in enterocytes (JENSEN et al., 2006) and in feces (YANG et al., 2003), suggesting its participation in the development of diarrhea in PMWS affected pigs and the possibility of its transmission through feces. Mild to severe lymphohistiocytic enteritis is the main intestinal lesion described in PMWS pigs, but a study showed that 3% of these animals also had necrotic colitis (SEGALÉS et al., 2004). Lymphocytes, plasma cells, eosinophils, giant cells and intracytoplasmic inclusions bodies in macrophages can be found in intestinal lesions in variable numbers and distribution. In some cases of PCV2-associated enteritis, varying degrees variation of mucosal necrosis have been associated to the presence of PCV2 antigen in a variety of cell types within the mucosa of the intestine, including crypt cells, histiocytes, giant cells, and lymphatic endothelial cells. However, the PCV2 role in necrotizing intestinal lesions remains unclear as only a few reports described necrotic enteritis in PMWS affected pigs (CLARK, 1997; SEGALÉS et al., 2004; JENSEN et al., 2006). The objective of the present study was to evaluate cases of necrotic enteritis in PMWS affected pigs and to investigate the potential role of PCV2 in the development of this condition.

MATERIAL AND METHODS

Intestinal segments of 63 naturally occurring PMWS cases submitted for diagnostic work-up between 2005 and 2006 were analysed. The affected animals were 45 to 120 days old and originated from swine herds with history of wasting and diarrhea. Farms were located in the states of Rio Grande do Sul and Santa Catarina. The diagnosis of PMWS was performed according to the methodology described by Sorden (2000). The samples were selected based on the presence of gross and/or microscopic alterations of necrotic enteritis. The herds were serologically negative for Aujeszky disease and classical swine

fever. Samples of 10 slaughtered pigs intestine were used as negative control.

Immunohistochemistry (IHC) staining for PCV2 was performed on formalin-fixed paraffin-embedded tissues with a rabbit polyclonal antibody (SORDEN et al., 1999) at a 1:1000 dilution, using the streptavidin-biotin immunoperoxidase (Dako, Carpinteria, CA) technique and diaminobenzidine (Dako, Carpinteria, CA) as chromogen.

Cecal and colonic samples of 38 cases were submitted for bacteriological examinations using standard procedures, which included isolation of *Salmonella* spp. (MICHAEL et al., 2003), *Escherichia coli* (BARROW & FELTHAM, 1993), and *Brachyspira* spp. (HAMPSON & TROTT, 1999).

Immunohistochemistry against *Lawsonia intracellularis* (GUEDES et al., 2002; GUEDES & GEBHART, 2003) and *Brachyspira* spp. (PAULOVICH et al., 2004) was performed. Double IHC for simultaneous demonstration of PCV2 and cytokeratin (DAKO-pancytokeratin, 1:200 dilution) was applied with diaminobenzidine and alkaline phosphatase as chromogens, respectively. Additionally, selected IHC-labelled sections of intestine of PCV2-infected pigs and negative control animals were counterstained with Alcian blue pH 2.5 and hematoxylin (GAFFNEY, 1992). The counterstaining was applied to provide a comparison between the quantity of goblet cells in samples of PCV2 infected and non-infected pigs. Goblet cells were quantified under an optical microscope. Ten colonic crypts were analyzed per field adjacent to necrotic areas and compared with equal number of crypts of negative controls pigs.

Sections of colon, in which PCV2 was the only pathogen observed and PCV2 antigen was detected in crypt epithelial cells, as well as sections of colon of PCV2 negative control pigs, were processed for terminal deoxynucleotidyl transferase-mediated dUTP-biotin nick end labelling (TUNEL) to detect DNA strand breaks, which are known to precede apoptosis and cell elimination (GAVRIELI et al., 1992; POTTEN et al., 1997). The rate of apoptosis was determined by dividing the number of TUNEL positive cells by the total number of crypt epithelial cells. To perform morphometric analysis, colon images of 20 cross-section fields per slide ($8,533\mu\text{m}^2 \text{field}^{-1}$) were obtained with a 40 planapochromatic objective in light microscopy (final magnification = 1000 x). The images were digitized through a JVC TK-1270/JGB microcamera and transferred to an analyzer (Media Cybernetics Image Pro Plus, version 4.50.29 for Windows).

Apoptosis results and goblet cell depletion were expressed as means \pm SD. Comparisons between

groups were made using one-way analysis of variance (ANOVA). Statistical analysis was performed using Graph-Pad Prism 2.01. Differences between means were considered significant when P values were < 0.05.

RESULTS

Grossly, multifocal to locally extensive reddening of the intestinal mucosa with necrosis, often located in the colon (Figure 1), were observed in 43 cases. In 3 cases, necrotic enteritis was grossly observed only in the ileum. Additional gross findings included mesenteric edema (18/63) and thickening of the ileal wall (7/63).

Microscopically, mucosal necrosis ranged from erosion covered with fibrin exudate (14/63) to full-thickness coagulative necrosis of the mucosa (49/63). Mucosal necrosis was observed in 60 samples of the colon and in 3 samples only in the ileum. In 5 cases necrotic enteritis was observed in the colon and in the ileum. Mixed infiltrate with histiocytic predominance and variable amounts of neutrophils was present within the mucosa. In severe cases, inflammatory infiltrates were also observed in the submucosa and muscular layer. Giant cells (4/63) and histiocytic intracytoplasmic

inclusion bodies (11/63) were located predominantly in the Peyer's patches in the small intestine. In the large intestinal mucosa, histiocytic intracytoplasmic inclusion bodies were observed in one case and giant cells in 2 cases. Epithelial necrosis with crypt dilatation and accumulation of necrotic debris within the crypt lumen (Figure 2) occurred in the large intestine of 17 cases and in the small intestine of 4 cases.

Except for the control cases, all animals of this study had positive staining for PCV2 by IHC in intestine sections. In severe cases of coagulative mucosal necrosis, PCV2 staining appeared as multifocal spots in the necrotic debris within the mucosa. In moderate and mild cases of PCV2 infection, antigen was observed mainly in histiocytes in the mucosa and lymphoid follicles. Epithelial cells and cellular debris in the crypt lumen also stained positively in 17 cases.

Salmonella spp. was isolated from 24 samples and *Escherichia coli* was isolated from 1 sample. Immunohistochemistry was positive in 2 and 1 case for *Brachyspira* spp and *Lawsonia intracellularis*, respectively. *Salmonella* typification was performed in 7 samples and *Salmonella typhimurium* was identified in 6 and *S. enterica* subsp. *enterica* in 1 case.

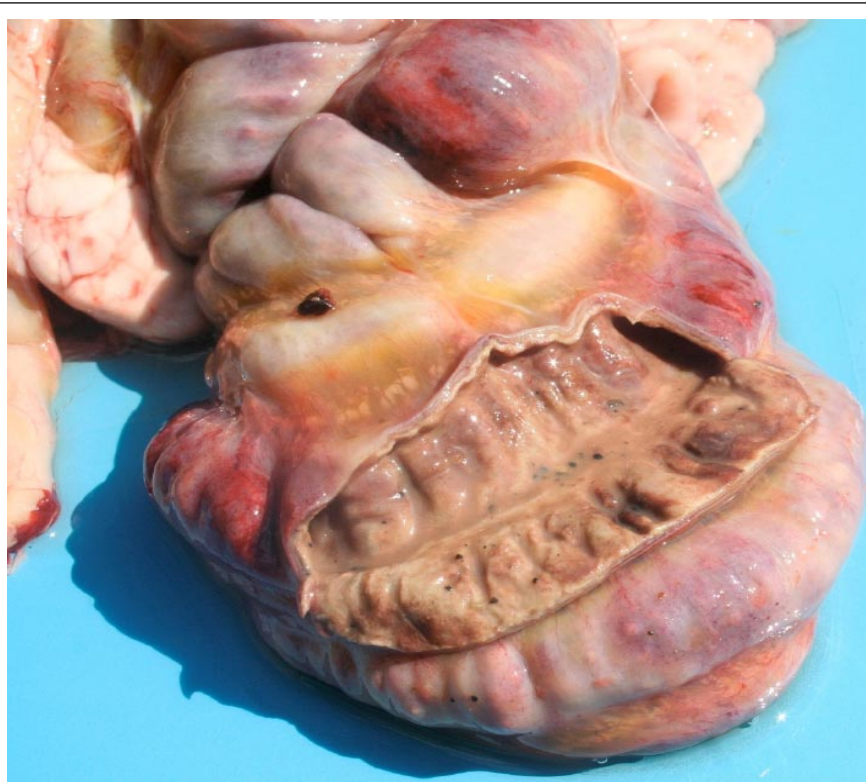
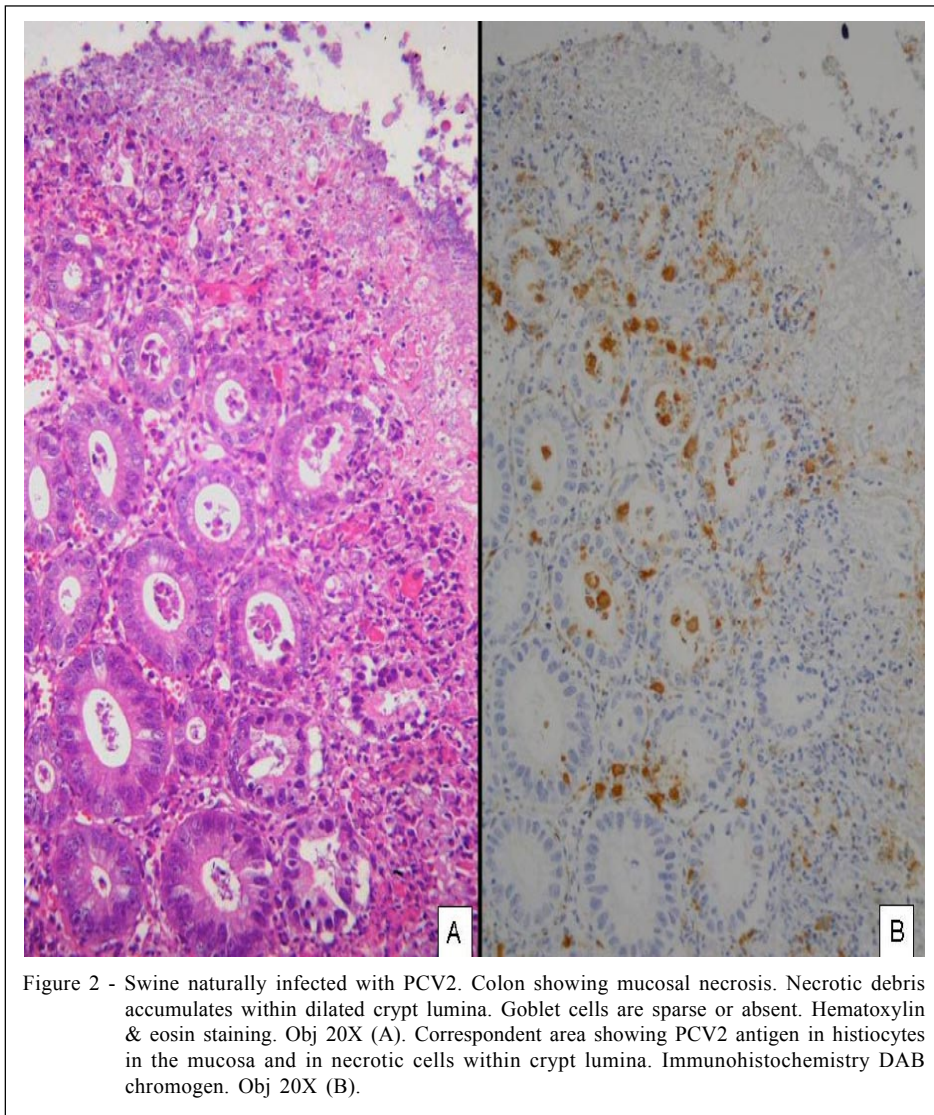


Figure 1 - Swine naturally infected with PCV2. Colon showing extensive mucosal necrosis with reddening of the serosal surface and mesenteric edema.



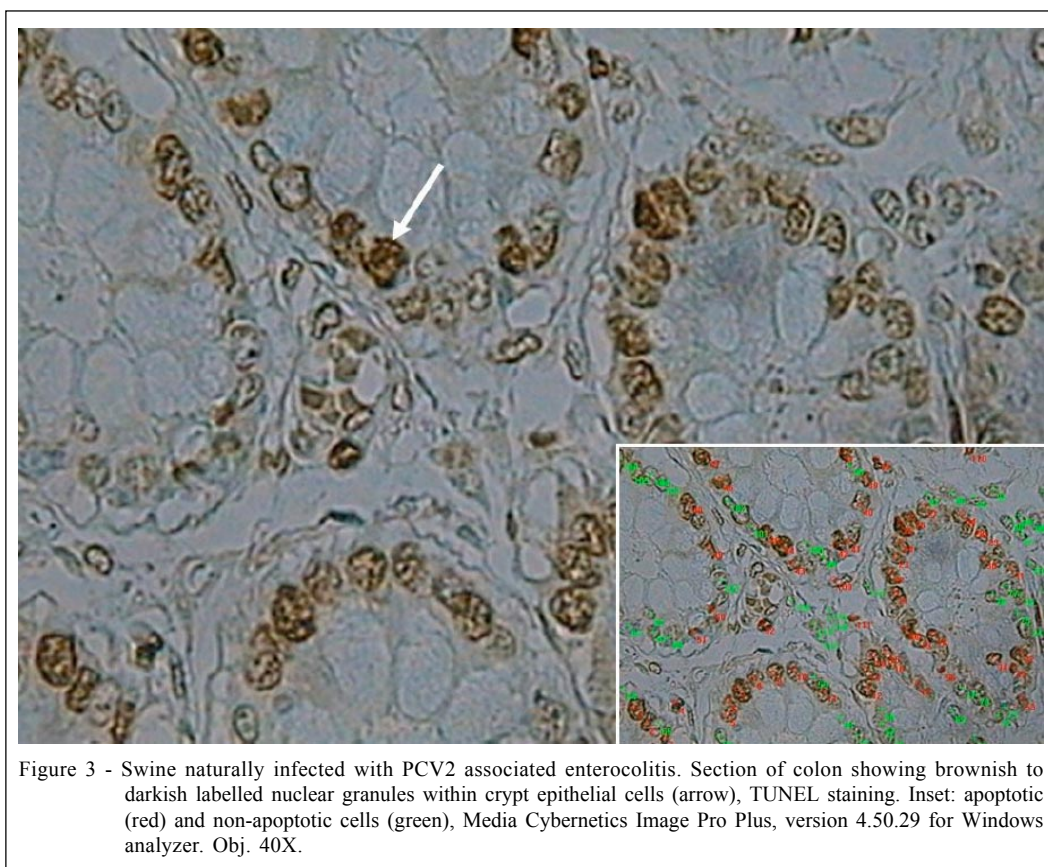
Depletion of intestinal goblet cells was observed in 10 cases of PCV2 IHC-stained sections of colon counterstained with Alcian blue and hematoxylin. PCV2 positive cases had a statistically significant decreased rate of goblets cells with 15.87 ± 0.95 labelled cells. Control cases had a rate of 30.99 ± 6.59 labelled cells.

Apoptotic crypt cells were detected as presenting brownish to blackish nuclear granules in the TUNEL assay (Figure 3). Both PCV2 positive and negative samples had apoptotic cells, but there was a statistically significant increase in the number of labelled cells in PCV2 positive samples (PCV2 positive: 47.07 ± 3.501 labelled cells; PCV2 negative: 12.26 ± 4.378 labelled cells).

DISCUSSION

Clinico-pathological findings observed here suggest that PCV2 is an important causal agent of necrotic enterocolitis in growing pigs. The main affected segment of intestine in the herein reported cases of PCV2-associated necrotic enteritis appeared to be the colon, although the ileum was also affected in some cases.

There were 24 cases of PCV2 and *Salmonella* co-infection, with *S. typhimurium* being the most common serovar identified. This serotype is frequently identified as a sequel to other enteric or debilitating enterocolitic diseases. Known predisposing causes for *Salmonella* infection include disruption of normal microbiota or increased ease of *Salmonella* replication



due to impairment of normal intestinal defences (GRIFFITH *et al.*, 2006). An enhanced susceptibility to salmonellosis has been previously reported in PMWS affected pigs (HA *et al.*, 2005).

In our studies, depletion of goblet cells was observed in the colon of PCV2-infected pigs. Goblet cells secrete mucin, which together with enterocytes forms a physical barrier in the intestinal tract. A likely contributing cause for inflammation of the intestinal mucosa is the damage of the epithelium that may affect the protective properties offered by the secretory products of the goblet cells. Van der SLUIS *et al.* (2006) demonstrated an association between the deficiency of the gene MUC2 (the main gene responsible for mucin secretion in rat, mice, and humans) and the formation of crypt abscesses and colonic inflammation. The failure of intestinal defences due to deficient mucin production by depletion of goblet cells may play a role in the development of mucosal necrosis in necrotic enterocolitis associated with PCV2. In addition, PCV2 has been shown to induce an increase in pro-inflammatory cytokines such as IL-1 β and IL-8 in peripheral blood mononuclear cells (DARWICH *et al.*, 2003). The cytokine production stimulated by PCV2

infection of enterocytes may potentially stimulate the recruitment of inflammatory cells to the intestinal tract, facilitating inflammation in the intestine and the formation of necrosis.

Apoptosis is a form of cellular death, which is important for tissue morphogenesis and homeostasis. This programmed cell death occurs spontaneously in the normal intestine, as part of the cell turnover mechanism. Apoptosis can also be induced in several tissues by cytotoxic agents (RAMACHANDRAN *et al.*, 2000). In the large intestine, spontaneous and damage-induced apoptosis occurs throughout the crypt (POTTEN *et al.*, 1997). Apoptosis was reported in the liver of pigs naturally infected with PCV2 on the basis of histopathological changes (ROSSEL *et al.*, 2000). Additional studies confirmed the presence of apoptosis, through the activation of caspases 8 and 3, in spleen, lymph nodes and Peyer's patches of mice experimentally infected with PCV2 (KIUPEL *et al.*, 2005). Recent studies demonstrated that PCV2 has an open read frame 3 (ORF3) that causes apoptosis in PCV2 infected cells (LIU *et al.*, 2005) and plays a role in the pathogenesis of PCV2 infection (KARUPPANNAN *et al.*, 2009). We found an increased

rate of apoptosis in the crypt cells of the large intestine of PCV2-infected pigs, suggesting that the virus may interfere with the epithelial turnover by increasing the apoptosis rate of infected cells.

Diagnosis of necrotic enterocolitis associated with PCV2 should be based on the detection of PCV2 antigen or DNA in necrotic areas, since giant cells and intracytoplasmic inclusion bodies (typical of PCV2 infection) may not be present in microscopical lesions. Moreover, bacteriological examination remains important to further determine the etiologic diagnosis, since co-infections with bacteria are likely to occur in PCV2-infected pigs.

ACKNOWLEDGEMENTS

Authors are grateful to Alessandra Blacene Sella for technical assistance in bacteriological procedures and to CAPES and CNPq for financial support.

REFERENCES

- BARROW, G.I.; FELTHAM, R.K.A. **Cowan and steel's manual for the identification of medical bacteria**. 3.ed. New York: Cambridge University, 1993. 351p.
- CLARK, E.G. Post-weaning multisystemic wasting syndrome. In: ANNUAL MEETING OF AMERICAN SWINE PRACTITIONERS, 28., 1997, Quebec City, Quebec. **Proceedings...** Quebec: AASP, 1997. p.499-501.
- DARWICH, L. et al. Cytokine profiles of peripheral blood mononuclear cells from pigs with postweaning multisystemic wasting syndrome in response to mitogen, superantigen or recall viral antigens. **Journal of General Virology**, v.84, p.3453-3457, 2003. Disponível em: <<http://vir.sgmjournals.org/cgi/content/abstract/84/12/3453>>. Acesso em: 15 mai. 2007. doi: 10.1099/vir.0.19364-0.
- GAFFNEY, E. Carbohydrates. In: PROPHET, E.B. et al. **Laboratory methods in histotechnology**. Washington, DC: American Registry of Pathology, 1992. 274p. P.149-174
- GAVRIELI, Y. et al. Identification of programmed cell death in situ via specific labeling of nuclear DNA fragmentation. **Journal of Cell Biology**, v.119, p.493-501, 1992. Disponível em: <<http://jcb.rupress.org/cgi/reprint/119/3/493>>. Acesso em: 10 jan. 2008.
- GRIFFITH, R.W. et al. Salmonella. In: LEMAN, A.D. et al. **Diseases of swine**. 9.ed. Ames: Iowa State University, 2006. Cap.45, p.739-754.
- GUEDES, R.M.C. et al. Comparison of different methods for diagnosis of porcine proliferative enteropathy. **Canadian Journal of Veterinary Research**, v.66, p.99-107, 2002.
- GUEDES, R.M.C.; GEBHART, C.J. Preparation and characterization of polyclonal and monoclonal antibodies against *Lawsonia intracellularis*. **Journal of Veterinary Diagnostic Investigation**, v.15, p.438-448, 2003.
- HA, Y. et al. Outbreak of salmonellosis in pigs with postweaning multisystemic wasting syndrome. **Veterinary Record**, v.156, p.583-584, 2005.
- HAMPSON, D.J.; TROTT, D.J. Spirochetal diarrhea/porcine intestinal spirochetosis. In: LEMAN, A.D. et al. **Diseases of swine**. 8.Ed. Ames: Iowa State University, 1999. Cap.40, p.553-562.
- JENSEN, T.K. et al. Distinction between porcine circovirus type 2 enteritis and porcine proliferative enteropathy caused by *Lawsonia intracellularis*. **Journal of Comparative Pathology**, v.135, p.176-182, 2006. Disponível em: <<http://dx.doi.org/10.1016/j.jcpa.2006.08.006/>>. Acesso em: 10 dez. 2006. doi:10.1016/j.jcpa.2006.08.006.
- KARUPPANNAN, A.K. et al. Attenuation of porcine circovirus 2 in SPF piglets by abrogation of ORF3 function. **Virology**, v.383, p.338-347, 2009. Disponível em: <<http://dx.doi.org/10.1016/j.virol.2008.10.024/>>. Acesso em: 15 set. 2008. doi:10.1016/j.jcpa.2006.08.006.
- KIM, J. et al. Enteritis associated with porcine circovirus 2 in pigs. **Canadian Journal of Veterinary Research**, v.68, p.218-221, 2004.
- KIUEP, M. et al. Porcine Circovirus type 2 (PCV2) causes apoptosis in experimentally inoculated BALB/c mice. **BioMed Central Veterinary Research**, v.1, p.7, 2005. Disponível em: <<http://dx.doi.org/10.1186/1746-6148-1-7/>>. Acesso em: 17 ago. 2007. doi:10.1186/1746-6148-1-7.
- LIU, J., et al. Characterization of a previously unidentified viral protein in porcine circovirus type 2-infected cells and its role in virus-induced apoptosis. **Journal of Virology**, v.79, p.8262-8274, 2005. Disponível em: <<http://dx.doi.org/10.1128/JVI.79.13.8262-8274.2005/>>. Acesso em: 10 abr. 2007. doi:10.1128/JVI.79.13.8262-8274.2005.
- MICHAEL, G.B. et al. Comparison of different selective enrichment steps to isolate *Salmonella* sp. from feces of finishing swine. **Brazilian Journal Microbiology**, v.34, p.138-142, 2003. Disponível em: <<http://dx.doi.org/10.1590/S1517-83822003000200009/>>. Acesso em: 11 jun. 2008. doi: 10.1590/S1517-83822003000200009.
- OPRIESSNIG, T. et al. Porcine circovirus type 2-associated disease: update on current terminology, clinical manifestations, pathogenesis, diagnosis, and intervention strategies. **Journal of Veterinary Diagnostic Investigation**, v.19, p.591-615, 2007.
- PAULOVICH, F. et al. Avaliação da patogenicidade de amostras de *Brachyspira pilosicoli* através de técnicas histopatológicas convencionais e por imuno-histoquímica. **Pesquisa Veterinária Brasileira**, v.24, p.144-148, 2004. Disponível em: <<http://dx.doi.org/10.1590/S0100-736X2004000300005/>>. Acesso em: 04 jun. 2006. doi: 10.1590/S0100-736X2004000300005.
- POTTEN, C.S. et al. Regulation and significance of apoptosis in the stem cells of the gastrointestinal epithelium. **Stem Cells**, v.15, p.82-93, 1997.
- RAMACHANDRAN, A. et al. Apoptosis in the intestinal epithelium: its relevance in normal and pathophysiological conditions. **Journal of Gastroenterology and Hepatology**,

- v.15, p.109-120, 2000. Disponível em: <<http://dx.doi.org/10.1046/j.1440-1746.2000.02059.x/>>. Acesso em: 16 ago. 2008. doi: 10.1046/j.1440-1746.2000.02059.x.
- ROSSEL, C. et al. Hepatitis and staging of hepatic damage in pigs naturally infected with porcine circovirus type 2. **Veterinary Pathology**, v.37, p.687-692, 2000.
- SEGALÉS, J. et al. Pathological findings associated with naturally acquired porcine circovirus type 2 associated disease. **Veterinary Microbiology**, v.98, p.137-149, 2004. Disponível em: <<http://dx.doi.org/10.1016/j.vetmic.2003.10.006/>>. Acesso em: 02 mar. 2005. doi: 10.1016/j.vetmic.2003.10.006.
- SEGALÉS, J. et al. Porcine circovirus diseases. **Animal Health Research Reviews**, v. 6, p. 119-142, 2005. Disponível em: <<http://dx.doi.org/10.1079/AHR2005106/>>. Acesso em: 08 mai. 2006. doi: 10.1079/AHR2005106.
- SORDEN, S.D. et al. Development of a polyclonal-antibody-based immunohistochemical method for the detection of type 2 porcine circovirus in formalin-fixed, paraffin-embedded tissues. **Journal of Veterinary Diagnostic Investigation**, v.11, p.528-530, 1999. Disponível em: <<http://jvdi.org/cgi/content/abstract/11/6/528>>. Acesso em: 10 jan. 2005.
- SORDEN, S.D. Update on porcine circovirus and postweaning multisystemic wasting syndrome. **Swine Health Production**, v.8, p.133-136, 2000.
- THOMSON, J.R. Diseases of the digestive system. In: LEMAN, A.D. et al. **Diseases of swine**. 9.ed. Ames: Iowa State University, 2006. Cap.3, p.37-55.
- VAN DER SLUIS, M. et al. Muc2-deficient mice spontaneously develop colitis, indicating that Muc2 is critical for colonic protection. **Gastroenterology**, v.131, p.117-129, 2006. Disponível em: <<http://dx.doi.org/10.1053/j.gastro.2006.04.020/>>. Acesso em: 02 set. 2008. doi:10.1053/j.gastro.2006.04.020.
- YANG, J.S. et al. Detection of porcine circovirus type 2 in feces of pigs with or without enteric disease by polymerase chain reaction. **Journal of Veterinary Diagnostic Investigation**, v.15, p.369-373, 2003.