











Intra-abdominal torsion of a non-neoplastic cryptorchid testis in an adult dog

Sandy Liara Primaz¹  Aline de Moura Jacques¹  Natalia Horstmann Risso¹ 
 Maria Lígia de Arruda Mestieri¹  Marília Teresa de Oliveira¹  Maria Elisa Trost² 
 Fabiana Wurster Strey²  Diego Vilibaldo Beckmann^{1*} 

¹Programa de Pós-graduação em Ciência Animal, Universidade Federal do Pampa (UNIPAMPA), 97501-970, Uruguaiana, RS, Brasil. E-mail: dvbeckmann@hotmail.com. *Corresponding author.

²Laboratório de Patologia Veterinária, Universidade Federal do Pampa (UNIPAMPA), Uruguaiana, RS, Brasil.

ABSTRACT: Intra-abdominal or intrascrotal testicular torsion in dogs occurs due to spermatic cord rotation. Dogs with testicular torsion commonly present severe pain and require surgical intervention. Torsion of intra-abdominal retained testicles in cryptorchid adult dogs is often associated with the presence of testicular neoplasia. Herein, we reported the case of a 5-year-old male poodle with uncommon intra-abdominal testicular torsion (ITT) of a non-neoplastic testicle. The dog was referred to the veterinary hospital with acute abdominal pain in the hypogastric region. An intra-abdominal gonad and alterations compatible with testicular torsion were visualized during ultrasound examination. Orchiectomy and histopathological analysis of the testes confirmed the diagnosis of ITT in the absence of neoplasia. The patient recovered uneventfully from the situation. This report showed that ITT can occur in adult dogs in the absence of testicular neoplasia and reinforce the message that it should be included as a differential diagnosis in cases of acute abdominal pain in cryptorchid dogs. Furthermore, the ultrasound examination in this case of pain in the hypogastric region was decisive for the diagnosis of ITT.

Key words: acute abdomen, cryptorchidism, ultrasound exam, surgery.

Torção intra-abdominal de testículo criptorquideo sem neoplasia em cão adulto

RESUMO: A torção testicular intra-abdominal ou intra-escrotal em cães ocorre devido à rotação do cordão espermático. Os cães com torção testicular apresentam comumente dor intensa e necessitam de intervenção cirúrgica. Em cães adultos, a torção de testículos retidos no abdômen está geralmente associada à presença de neoplasia testicular. Este relato descreve um caso incomum de cão macho, de cinco anos de idade, da raça Poodle, encaminhado ao Hospital Veterinário com dor abdominal aguda na região hipogástrica. Durante o exame ecográfico, foi possível evidenciar um testículo e alterações compatíveis com torção testicular. A orquiectomia intra-abdominal e posterior análise histopatológica confirmaram a ITT sem neoplasia associada. O paciente apresentou evolução clínica satisfatória. Este relato mostra que a ITT na ausência de neoplasia pode ocorrer em cães adultos, reforçando a mensagem de que deve ser considerada como um diferencial diagnóstico em casos de dor abdominal aguda. Além disso, o exame ultrassonográfico realizado neste caso de dor na região hipogástrica foi decisivo para o diagnóstico de ITT.

Palavras-chave: dor abdominal aguda, criptorquidismo, ultrassom, cirurgia.

Testicular torsion is uncommon in dogs. It caused by the rotation of the intrascrotal or intra-abdominal testis around its own axis (PEARSON & KELLY, 1975; CRIVELLENTI et al., 2013; QUARTUCCIO et al., 2012; VILIOTTI et al., 2018). Acute pain is the main clinical sign of spermatic cord torsion (HECHT et al., 2004; QUARTUCCIO et al., 2012; CARR et al., 2015); the situation requires a surgical intervention (SCHNECK & BELLINGER, 2007; QUARTUCCIO et al., 2012). Ultrasound is a routine complementary exam to distinguish testicular torsion diagnose from other pathologies also cause abdominal pain (PINTO et al., 2001; HECHT et al., 2004; FELUMLEE et al., 2012).

Cryptorchidism is frequently associated with testicular neoplasia, such as Sertoli cell tumors and

seminoma, in dogs of all ages (PEARSON & KELLY, 1975; QUARTUCCIO et al., 2012; KHAN et al., 2018; SANTOS & ALESSI, 2010; HAYES JÚNIOR et al., 1985). The presence of testicular neoplasia results in the progressive gonadal enlargement, which increases the possibility of torsion (PEARSON & KELLY, 1975; HAYES JÚNIOR et al., 1985). In cryptorchid adult dogs, torsion of the testis in the absence of neoplasia has occasionally been reported (HECHT et al., 2004; CRHA et al., 2015; CARR et al., 2015). This report described an uncommon case of intra-abdominal testicular torsion (ITT) of a non-neoplastic testicle in a dog presenting acute abdominal pain in the hypogastric region.

A 5-year-old male poodle (weight: 2.8 kg) was presented to the veterinary hospital with acute

abdominal pain and a history of neutering performed 3 years before. During physical exam, the patient evidenced intense pain on abdominal palpation of the right hypogastric region, mild dehydration, tachycardia, and tachypnea. The main differential diagnoses were urinary tract diseases, intestinal intussusception, and the existence of bodies. Initially, the neutering history disregarded testicular torsion and complications associated with cryptorchidism. The patient underwent an abdominal ultrasound examination to determine the diagnosis.

The abdominal ultrasound examination revealed an oval structure ($5 \times 3 \times 2$ cm) with a mixed echotexture and a central hyperechoic line in the right caudal abdominal quadrant, compatible with a testicle (Figure 1A and 1B). The patient presented with severe pain during the ultrasound examination, particularly during the intra-abdominal testicle evaluation, for which it was administered

tramadol hydrochloride 3 mg/kg intravenous (IV) and replacement fluid therapy (Ringer's lactate solution, 3mL.kg/h). Ultrasound findings associated with severe pain were suggestive of ITT. Ultrasound examination also revealed the presence of gallstones and splenic lesions. The hemogram and serum biochemistry values are shown in table 1. Hemogram showed mild neutrophilia, moderate eosinophilia, and moderate monocytosis. Moreover, serum biochemical analysis showed a marked increase in the levels of alanine aminotransferase (220 UI/L) and alkaline phosphatase (218 UI/L).

A median laparotomy was performed for intra-abdominal orchietomy. During surgery, the testicle was localized in the right caudal abdominal quadrant and removed. The testicle presented edema and congestion. The abdominal cavity was inspected during the surgery, and gallstones were removed (cholecystectomy). Splenectomy was also performed

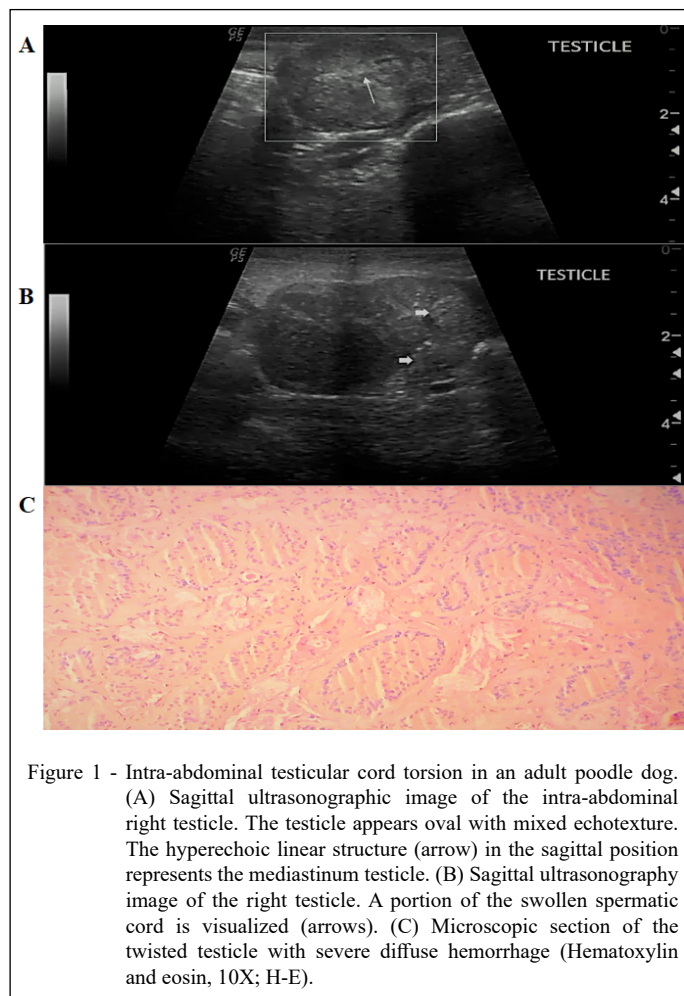


Figure 1 - Intra-abdominal testicular cord torsion in an adult poodle dog. (A) Sagittal ultrasonographic image of the intra-abdominal right testicle. The testicle appears oval with mixed echotexture. The hyperechoic linear structure (arrow) in the sagittal position represents the mediastinum testicle. (B) Sagittal ultrasonography image of the right testicle. A portion of the swollen spermatic cord is visualized (arrows). (C) Microscopic section of the twisted testicle with severe diffuse hemorrhage (Hematoxylin and eosin, 10X; H-E).

Table 1 - Hematology and serum biochemistry of an adult dog with intra-abdominal torsion of a non-neoplastic cryptorchid testis.

Parameter	Values	Reference interval
Erythrocytes ($\times 10^6/\mu\text{L}$)	5.5	5.5–8.5
Hemoglobin (g/dL)	13.2	12–18
Hematocrit (%)	36.0	37–50
Platelets ($\times 10^3/\mu\text{L}$)	441	200–500
Leucocytes ($\times 10^3/\mu\text{L}$)	16.4	6–17
Neutrophil ($/\mu\text{L}$)	11.8	3–11.5
Eosinophil ($/\mu\text{L}$)	2.1	0.1–1.25
Monocytes ($/\mu\text{L}$)	1.8	0.15–1.35
Lymphocytes ($/\mu\text{L}$)	2.1	1–4.8
Plasma proteins (g/dL)	7.0	5.5–7.5
Fibrinogen (g/dL)	0.6	0.1–0.5
Total Protein (g/dL)	6.3	5.4–7.1
Albumin (g/dL)	3.2	2.6–3.3
Globulin (g/dL)	3.0	2.5–4.1
Creatinine (mg/dL)	0.8	0.5–1.5
Urea (mg/dL)	27.0	20–60
ALT (UI/L)	220	21–102
ALP (UI/L)	218	20–156
AST (UI/L)	33.0	23–66

ALT, alanine aminotransferase; ALP, alkaline phosphatase; AST, aspartate aminotransferase.

to avoid complications. The histopathology report mentioned that the microscopic sections of the testis showed ischemia, severe diffuse hemorrhage with moderate neutrophilic inflammation suggestive of torsion, and parenchyma with normal architecture, without evidence of neoplasia (Figure 1C). It confirmed the clinical diagnoses of ITT in the absence of neoplasia as well as splenic scar nodules.

The dog was hospitalized for 3 days. During the first 2 days, no postoperative pain was detected, and the patient was maintained on fluid therapy (2 mL.kg/h) with Ringer's lactate. Treatment with cephalothin (30 mg/kg, IV) TID; Omeprazole (1 mg/kg, IV), SID; Meloxicam (0.1 mg/kg, SC), SID; Methadone (0.3 mg/kg, IM) TID was also implemented. On the 3 day post-surgery, the patient was discharged with a prescription for oral cephalexin (30 mg/kg, PO) BID. Ten days after surgery, the patient returned for evaluation and presented a satisfactory clinical progress. Physical examination failed to reveal any abnormalities on abdominal palpation.

Testicular cord torsion of a non-neoplastic testicle is uncommon in adult cryptorchid dogs.

Generally, the prevalence of testicular torsion in adult cryptorchid dogs is frequently associated with testicular neoplasia (QUARTUCCIO et al., 2012; PEARSON & KELLY, 1975; KHAN et al., 2018). Progressive enlargement of the gonad due to the presence of neoplasia predisposes the gonad to testicular rotation (PEARSON & KELLY, 1975; HAYES JÚNIOR et al., 1985). ITT of a non-neoplastic testicle has only been reported in cryptorchid puppy dogs (HECHT et al., 2004; CARR et al., 2015). It is likely that the gubernaculum laxity of the testis retained in the abdominal cavity predisposes testicular rotation (BOOTHE, 2003; GRADIL et al., 2006). This report described the clinical conduct, ultrasound and histopathological findings, and surgical treatment of a case of ITT of a non-neoplastic testicle.

Cryptorchidism is a common developmental defect in dogs, and it often occurs in small purebreds such as poodles (BOOTHE, 1998; VERONESI et al., 2009; MEMON, 2007). The right hypogastric region is a common location for retained testicles (ROMAGNOLI, 1991; AMANN & VEERAMACHANENI, 2007). Complications associated to an intra-abdominal testicle is infertility, increased risk of neoplasia, and testicular torsion, which can result in acute pain (HECHT et al., 2004; QUARTUCCIO et al., 2012; CARR et al., 2015; KHAN et al., 2018). Consequently, dogs with cryptorchidism should be neutered at a younger age to avoid complications (BOSSCHERE & DEPREST, 2010; BUFALARI et al., 2015; STOKOWSKI et al., 2016; KHAN et al., 2018). The clinical diagnosis of cryptorchidism cannot be excluded in the case of pain in the right hypogastric region (AMANN & VEERAMACHANENI, 2007; HECHT et al., 2004; QUARTUCCIO et al., 2012) and was supported by the ultrasound findings (HRICAK et al., 1983; HECHT et al., 2004).

The ultrasound examination was preponderant to reach the diagnosis of ITT in this clinical case as the dog was presumedly spayed, corroborating with previous case reports (MIYABAYASHI et al., 1990; HECHT et al., 2004; CARR et al., 2015). Other image diagnostic methods can support the diagnosis of ITT, such as color Doppler ultrasound (HECHT et al., 2004; ERDOĞAN et al., 2021), computed tomography (KLANG et al., 2017; STOKOWSKI et al., 2016), laparoscopy (FERANTI et al., 2015; CARR et al., 2015), and contrast-enhanced ultrasound scanning (METZGER-ROSE et al., 1997).

The enlargement of a retained testicle and the presence of mixed echogenicity are the predominant findings of acute testicular torsion with or

without neoplasia (HRICACK et al., 1983; PALTIEL et al., 2002; QUARTUCCIO et al., 2012; CARR et al., 2015). However, the ultrasound examination did not disregard the presence of testicular neoplasia (HRICACK et al., 1983; HECHT et al., 2003). The absence of testicular neoplastic characteristics in the histopathological analysis confirmed the diagnosis of ITT of a non-neoplastic testicle (VERONESI et al., 2009; AGNEW & MACLACHLAN, 2017).

Median laparotomy enables the visualization and removal of the altered testicle (QUARTUCCIO et al., 2012; CRIVELLENTI et al., 2013), along with performing splenectomy (FOSSUM et al., 2021) and cholecystectomy (AGUIRRE et al., 2007). The marked increase in alanine aminotransferase and alkaline phosphatase levels may be related to the presence of gallstones, which is a determinant of cholecystectomy performance (AGUIRRE et al., 2007; NELSON & COUTO, 2010). Splenic scars and cholelithiasis generally do not cause pain, and if existing it would result in pain in the mesogastric region not in the hypogastric region (CENTER, 2009; NELSON & COUTO, 2010; NYLAND et al., 2004). Consequently, meticulous abdominal palpation was used to determine the focus of pain and increased ITT diagnoses (DYE, 2003; ABDELLATIF et al., 2017).

This report showed that intra-abdominal torsion of a non-neoplastic testicle can occur in cryptorchid adult dogs and, consequently cause severe abdominal pain. The acute abdominal pain in the right hypogastric region and the findings of the abdominal ultrasound examination were preponderant for the ITT diagnosis. Therefore, neutering cryptorchid dogs is necessary to avoid complications such as testicular torsion and, consequently, severe abdominal pain. Furthermore, this case reinforces that the ITT should be included as a clinical suspicion in cases of acute abdominal pain.

ACKNOWLEDGEMENTS

The Coordenação de Aperfeiçoamento de Pessoal de Nível Superior (CAPES), Brasil.

BIOETHICS AND BIOSECURITY COMMITTEE APPROVAL

The report was performed with an animal routinely treated by the HUVET-UNIPAMPA and was not part of any project; it was simply a clinical case report.

DECLARATION OF CONFLICT OF INTEREST

The authors have no conflict of interest to declare.

AUTHORS' CONTRIBUTIONS

The authors contributed equally to the manuscript.

REFERENCES

- ABDELLATIF, A. et al. Correlation between preoperative ultrasonographic findings and clinical, intraoperative, cytopathological, and histopathological diagnosis of acute abdomen syndrome in 50 dogs and cats. **Veterinary Sciences**, v.4, n.3, p.39, 2017. Available from: <<https://www.ncbi.nlm.nih.gov/pmc/articles/PMC5644663/>>. Accessed: Mar. 18, 2021. doi: 10.3390/vetsci4030039.
- AGNEW, D. W.; MACLACHLAN, J. N. Tumors of the genital systems. In: MEUTEN, D. J. **Tumors in domestic animals**. North Carolina: Wiley, 2017. Cap.16, p.694-709.
- AGUIRRE, A. L., et al. Gallbladder disease in Shetland Sheepdogs: 38 cases (1995-2005). **Journal of the American Veterinary Medical Association**, v.231, n.1, p.79-88, 2007. Available from: <<https://avmajournals.avma.org/doi/abs/10.2460/javma.231.1.79>>. Accessed: Mar. 18, 2021. doi: 10.2460/javma.231.1.79.
- AMANN, R. P.; VEERAMACHANENI, D. N. Cryptorchidism in common eutherian mammals. **Reproduction**, v.133, n.3, p.141-161, 2007. Available from: <<https://rep.bioscientifica.com/view/journals/rep/133/3/1330541.xml>>. Accessed: Mar. 18, 2021. doi: 10.1530/rep-06-0272.
- BOOTHE, H. W. Testículos e epidídimos. In: SLATTER, D. H. **Manual de cirurgia de pequenos animais**. São Paulo: Manole, 1998. Cap.97, p.1581-1592.
- BOOTHE, H. W. Testes and epididymides. In: Slatter D. **Textbook of small animal surgery**. Philadelphia: Elsevier Science, 2003. Cap. p.1521-1530.
- BUFALARI, A. et al. The lameness in a cryptorchid dog with intra-abdominal torsion of one of the two neoplastic testicles: a case report. **Veterinarni Medicina**, v.60, n.8, p.456-459, 2015. Available from: <<https://www.agriculturejournals.cz/publicFiles/160382.pdf>>. Accessed: Mar. 18, 2021. doi: 10.17221/8421-VETMED.
- CARR, J. G. et al. Laparoscopic treatment of testicular torsion in a puppy. **Journal of the American Animal Hospital Association**, v.51, n.2, p.97-100, 2015. Available from: <<https://pubmed.ncbi.nlm.nih.gov/25654442/>>. Accessed: Mar. 18, 2021. doi: 10.5326/JAAHA-MS-6055.
- CENTER, S. A. Diseases of the gallbladder and biliary tree. **Veterinary Clinics of North America-Small Animal Practice**, v.39, n.3, p.543-598, 2009. Available from: <<https://pubmed.ncbi.nlm.nih.gov/19524793/>>. Accessed: Mar. 18, 2021. doi: 10.1016/j.cvsm.2009.01.004.
- CRHA, M. et al. Emergency laparoscopic cryptorchidectomy for acute abdomen due to testicular torsion in a dog. **Acta Veterinaria Brno**, v.84, n.2, p.167-171, 2015. Available from: <<https://doi.org/10.2754/avb201584020167>>. Accessed: Feb. 18, 2022. doi: 10.2754/avb201584020167.
- CRIVELLENTI, L. Z. et al. Intrascrotal testicular torsion and seminoma in a dog with chronic renal failure. **Turkish Journal of Veterinary and Animal Sciences**, v.37, n.1, p.113-116, 2013. Available from: <<https://journals.tubitak.gov.tr/veterinary/abstract.htm?id=13404>>. Accessed: Mar. 18, 2021. doi: 10.3906/vet-1007-416.
- DYE, T. The acute abdomen: A surgeon's approach to diagnosis and treatment. **Clin. Tech. Small Anim. Pract.** v.18, n.1, p.53-65, 2003.

- Available from: <[https://doi.org/10.1016/1096-2867\(03\)90026-0](https://doi.org/10.1016/1096-2867(03)90026-0)>. Accessed: Mar. 18, 2021. doi: 10.1016/1096-2867(03)90026-0.
- ERDOĞAN, G. et al. Ultrasonographic findings of intrascrotal testicular torsion at the early stage in a rabbit model. **Journal of the Hellenic Veterinary Medical Society**, v.72, n.2, p.2903-2908, 2021. Available from: <<https://doi.org/10.12681/jhvms.27530>>. Accessed: Sept. 18, 2021. doi: 0.12681/jhvms.27530.
- FERANTI, J. P. S., et al. Laparoendoscopic Single-Site Surgery in performing laparoscopic cryptorchidectomy in a cat. **Ciência Rural**, v.45, n.10, p.1826-1829, 2015. Available from: <<https://doi.org/10.1590/0103-8478cr20140611>>. Accessed: Mar. 18, 2021. doi: 10.1590/0103-8478cr20140611.
- FELUMLEE, A. E. et al. Use of ultrasound to locate retained testes in dogs and cats. **Veterinary Radiology & Ultrasound**, v.53, n.5, p.581-585, 2012. Available from: <<https://onlinelibrary.wiley.com/doi/abs/10.1111/j.1740-8261.2011.01943.x>>. Accessed: Mar. 18, 2021. doi: 10.1111/j.1740-8261.2011.01943.x.
- FOSSUM, T. W. **Cirurgia de Pequenos Animais**. Guanabara Koogan: Rio de Janeiro, 2021.
- GRADIL, C. M.; YEAGER, A.; CONCANNON, P. W. Assessment of reproductive problems in the male dog. **Recent Advances in Small Animal Reproduction**. Ithaca, New York, International Veterinary Information Service, 2006.
- HAYES JUNIOR, H. M. et al. Canine cryptorchism and subsequent testicular neoplasia: case-control study with epidemiologic update. **Teratology**, v.32, n.1, p.51-56, 1985. Available from: <<https://onlinelibrary.wiley.com/doi/abs/10.1002/tera.1420320108>>. Accessed: Mar. 18, 2021. doi: 10.1002/tera.1420320108.
- HECHT, S. et al. Ultrasound diagnosis: intra-abdominal torsion of a non-neoplastic testicle in a cryptorchid dog. **Veterinary Radiology & Ultrasound**, v.45, n.1, p.58-61, 2004. Available from: <<https://doi.org/10.1111/j.1740-8261.2004.04009.x>>. Accessed: Mar. 18, 2021. doi: 10.1111/j.1740-8261.2004.04009.x.
- HECHT, S. et al. Die sonographische untersuchung des skrotalinhalts beim hund unter besonderer berücksichtigung testikulärer neoplasien. **Tierärztliche Praxis**, v.31, n.4, p.199-210, 2003. Available from: <<https://www.thieme-connect.com/products/ejournals/abstract/10.1055/s-0037-1622357>>. Accessed: Mar. 18, 2021. doi: 10.1055/s-0037-1622357.
- HRICAK, H. et al. Experimental study of the sonographic diagnosis of testicular torsion. **J Ultrasound Med**, v.2, n.8, p.349-356, 1983. Available from: <<https://onlinelibrary.wiley.com/doi/abs/10.7863/jum.1983.2.8.349>>. Accessed: Mar. 18, 2021. doi: 10.7863/jum.1983.2.8.349.
- KLANG, E. et al. Torsed and nontorsed inguinal undescended testis: comparison of computed tomography findings. **Journal of computer assisted tomography**, v.41, n.4, p.633-637, 2017. Available from: <https://journals.lww.com/jcat/Fulltext/2017/07000/Torsed_and_Nontorsed_Inguinal_Undescended_Testis_20.aspx>. Accessed: Mar. 18, 2021. doi: 10.1097/RCT.0000000000000581.
- KHAN, F. A. et al. Canine cryptorchidism: an update. **Reproduction in Domestic Animals**, v.53, n.6, p.1263-1270, 2018. Available from: <<https://onlinelibrary.wiley.com/doi/abs/10.1111/rda.13231>>. Accessed: Apr. 20, 2021. doi: 10.1111/rda.13231.
- MIYABAYASHI, T. et al. Ultrasonographic appearance of torsion of a testicular seminoma in a cryptorchid dog. **Journal of Small Animal Practice**, v.31, n.8, p.401-403, 1990. Available from: <<https://onlinelibrary.wiley.com/doi/abs/10.1111/j.1748-5827.1990.tb00494.x>>. Accessed: Mar. 18, 2021. doi: 10.1111/j.1748-5827.1990.tb00494.x.
- MEMON, M. A. Common causes of male dog infertility. **Theriogenology**, v.68, n.3, p.322-328, 2007. Available from: <<https://doi.org/10.1016/j.theriogenology.2007.04.025>>. Accessed: Mar. 18, 2021. doi: 10.1016/j.theriogenology.2007.04.025.
- METZGER-ROSE, C. et al. Ultrasonographic detection of testicular ischemia in a canine model using phospholipid coated microbubbles (MRX-115). **Journal of ultrasound in medicine**, v.16, n.5, p.317-324, 1997. Available from: <<https://doi.org/10.7863/jum.1997.16.5.317>>. Accessed: Mar. 18, 2021. doi: 10.7863/jum.1997.16.5.317.
- NELSON, R. W.; COUTO, C. G. **Medicina Interna de Pequenos Animais**. São Paulo: Elsevier, 2010.
- NYLAND, T. G. et al. Liver Disease. In: Farrow, C. S. **Veterinary Diagnostic Imaging the Dog and Cat**. Mosby: Missouri, 2004.
- PEARSON, H, KELLY, D. F. Testicular torsion in the dog: a review of 13 cases. **The Veterinary Record**, v.13, n.97, p.200-20, 1975. Available from: <<https://europepmc.org/article/med/1162870>>. Accessed: Mar. 18, 2021. doi: 10.1136/vr.97.11.200.
- PINTO, C. R. et al. Theriogenology question of the month. Torsion of the spermatic cord. **Journal of the American Veterinary Medical Association**, v.219, n.10, p.1343-1345, 2001. Available from: <<https://europepmc.org/article/med/11724167>>. Accessed: Mar. 18, 2021. doi: 10.2460/javma.2001.219.1343.
- QUARTUCCIO, M. et al. Sertoli cell tumors associated with feminizing syndrome and spermatic cord torsion in two cryptorchid dogs. **Journal of Veterinary Science**, v.13, n.2, p.207-209, 2012. Available from: 25 <<https://www.ncbi.nlm.nih.gov/pmc/articles/PMC3386348/>>. Accessed: Mar. 18, 2021. doi: 10.4142/jvs.2012.13.2.207.
- PALTIEL, H. J. et al. Testicular volume: comparison of orchidometer and US measurements in dogs. **Radiology**, v.222, n.1, p.114-119, 2002. Available from: <<https://doi.org/10.1148/radiol.2221001385>>. Accessed: Mar. 18, 2021. doi: 10.1148/radiol.2221001385.
- ROMAGNOLI, S.E. Canine cryptorchidism. **Vet Clin North Am Small Anim Pract**, v.21, n.3, p.533-544, 1991.
- SANTOS, R. L; ALESSI, C. A, **Patologia Veterinária**, ed. Roca, São Paulo, p.864, 2010.
- SCHNECK, F. X., BELLINGER, M. F. Abnormalities of the testes and scrotum and their surgical management. In **Urology Campbell-Walsh**. Philadelphia, USA: Saunders Elsevier, 2007. Cap.17, p.3761-3798.
- STOKOWSKI, S. et al. Computed tomographic Features in a case of bilateral Neoplastic Cryptorchidism with suspected torsion in a Dog. **Frontiers in Veterinary Science**, v.3, n.33, p.1-5, 2016. Available from: <<https://www.frontiersin.org/articles/10.3389/fvets.2016.00033/full>>. Accessed: Mar. 18, 2021. doi: 10.3389/fvets.2016.00033.
- VERONESI, M. C. et al. Characteristics of cryptic ectopic and contralateral scrotal testes in dogs between 1 and 2 years of age. **Theriogenology**, v.72, n.7, p.969-977, 2009. Available from: <<https://doi.org/10.1016/j.theriogenology.2009.06.016>>. Accessed: Mar. 18, 2021. doi: 10.1016/j.theriogenology.2009.06.016.
- VILIOTTI, T. A. A. et al. Testicular torsion in the scrotum of a young canine **Acta Scientiae Veterinariae**, v.46, n.1, p.1-6, 2018. Available from: <http://www.ufrgs.br/actavet/46-suple-1/CR_268.pdf>. Accessed: Mar. 18, 2021. doi: 10.22456/1679-9216.86283.