







Guillain-Barré syndrome associated with SARS-CoV-2 infection: a scoping review

Kleyton Santos de Medeiros¹ , Luíza Thomé de Araújo Macêdo² ,
Wederson Farias de Souza² , Ayane Cristine Sarmiento¹ ,
Ana Paula Ferreira Costa¹ , Ana Katherine Gonçalves^{1,3*} 

SUMMARY

BACKGROUND: Severe acute respiratory syndrome coronavirus 2 (SARS-CoV-2) infections can affect the nervous system, triggering problems such as the Guillain-Barre Syndrome (GBS), an association that can bring complications to the patient.

OBJECTIVE: This scoping review aimed to clarify the clinical features and analyze patients with GBS associated with SARS-CoV-2 infection, looking at morbidity, mortality, and neurological outcomes.

SEARCH STRATEGY: The search was conducted through Medline, Web of Science, Embase, CINAHAL, Latin-American and Caribbean Literature in Health Sciences (LILACS), clinicaltrials.gov, SCOPUS, and the Cochrane Central Register of Controlled Trials.

SELECTION CRITERIA: Observational studies, published after 2019, describe patients with GBS associated with SARS-CoV-2 infection. There were no language restrictions while selecting the studies.

DATA COLLECTION AND ANALYSIS: Three authors, Kleyton Santos de Medeiros, Luíza Thomé de Araújo Macêdo, and Wederson Farias de Souza, independently screened the search results using titles and abstracts. Duplicate studies were excluded. The same authors then went through the entire text to determine whether the studies met the inclusion criteria. Discrepancies were resolved by other reviewers, Ana Paula Ferreira Costa, Ayane Cristine Sarmiento, and Ana Katherine Gonçalves. Finally, the selection of the studies was summarized in a PRISMA flow diagram.

MAIN RESULTS: Main manifestations were fever, coughing, dyspnea, sore throat, ageusia, anosmia, and respiratory failure, in addition to paresthesia of the upper and lower limbs, tetraparesis, facial diplegia, areflexia, asthenia, mastoid pain, acute ataxia, fatigue, numbness, swallowing disorder, and moderate low back pain.

CONCLUSION: Coronavirus disease 2019 (COVID-19) can trigger the GBS, despite the few studies on this topic. Patients had clinical manifestations of COVID-19 infection and neurological manifestations characterizing GBS.

KEYWORDS: Coronavirus infections. COVID-19. Guillain-Barre syndrome.

INTRODUCTION

In December 2019, an outbreak of SARS-CoV-2, the virus that causes COVID-19 was detected in Wuhan City, Hubei Province of China. COVID-19 primarily affects

the respiratory tract and the lungs and the appearance of symptoms depends on the age and the patient's underlying medical illness as well as on the condition of the immune system^{1,2}.

¹Universidade Federal do Rio Grande do Norte, Pós-Graduação em Ciências da Saúde – Natal (RN), Brazil.

²Centro Universitário do Rio Grande do Norte – Natal (RN), Brazil.

³Universidade Federal do Rio Grande do Norte, Departamento de Toco-Ginecologia – Natal (RN), Brazil.

*Corresponding author: anakatherine_ufnet@yahoo.com.br

Conflicts of interest: the authors declare there are no conflicts of interest. Funding: none.

Received on August 21, 2020. Accepted on August 30, 2020.

Infected individuals usually have simple respiratory symptoms, fever, dry cough, and tiredness, which can progress to pneumonia and dyspnea³. The reported neurological manifestations and complications of COVID-19 include anosmia, headaches, dizziness, delirium, stroke, epilepsy, encephalitis, encephalopathy, myalgias, and Guillain-Barré syndrome (GBS)^{1,2,4}.

GBS is an acute immune-mediated disease of the peripheral nerves and nerve roots (polyradiculoneuropathy) usually preceded by various infections². Classical clinical manifestations include paresthesia, progressive, ascending, and symmetrical flaccid limbs paralysis, muscle weakness, and areflexia. It may also present an infection of the gastrointestinal or respiratory tract before neurological symptoms¹.

The aims of this scoping review was to clarify the clinical features of patients with GBS associated with SARS-CoV-2 infection, their morbidity and mortality, as well as this important neurological manifestation caused by COVID-19.

METHODS

The Scoping Review was carried out following the Preferred Reporting Items for Systematic reviews and Meta-Analyses extension for Scoping Reviews (PRISMA-ScR) checklist⁵.

Protocol and registration

The review was not registered in the International Prospective Register of Systematic Reviews (PROSPERO), and corresponding authors were not contacted due to time constraints. Ethical approval was not required for this review.

Eligibility criteria

This scoping review included the following studies: observational studies (case report, case series, case-control, and cohort) describing patients with GBS associated with SARS-CoV-2 infection; and studies published after 2019, as the first case of COVID-19 was registered in Wuhan, China, in December 2019⁶. There were no language restrictions while selecting studies.

Information Sources

Medline, Web of Science, Embase, Cumulative Index to Nursing and Allied Health Literature (CINAHAL), Latin American and Caribbean Literature in Health Sciences (LILACS), clinicaltrials.gov, Scopus, and the Cochrane Central Register of Controlled Trials were used to search for articles published between December 2019 and April 2020. We selected the publications starting from December 2019 because the first case of COVID-19 was registered in Wuhan, China, in December 2019⁶.

Search

The medical subject headings (MESH) terms were (COVID-19 OR severe acute respiratory syndrome coronavirus 2 OR SARS-CoV-2) AND (Guillain Barre Syndrome OR Guillain-Barré Syndrome OR Landry-Guillain-Barre Syndrome OR Acute Autoimmune Neuropathy). Eligible studies were also selected from the reference lists of the retrieved articles. The research included articles published until June 26th.

Selection of sources of evidence

Three authors, KSM, LTAM, and WFS, independently screened the search results using the titles and abstracts. Duplicate studies were excluded. The same authors then went through the full text to determine whether the studies met the inclusion criteria. Discrepancies were resolved by others reviewers, APFC, ACAS, and AKG. The selection of the studies was summarized in a PRISMA flow diagram (Figure 1).

Data items and Synthesis of results

Various characteristics of the eligible studies were extracted, including the first authors' last names, year of publication, location of the study (country), study design, primary objective, level of evidence, number of patients, gender, mean age of patients, comorbidities, clinical manifestations, muscle strength assessment, patient outcome, chest imaging, laboratory tests, tests diagnosis, and treatment. Standardized data extraction forms were specifically created in Excel for this review, and the results were entered into a database. All data entries were double-checked. Subsequently, the qualitative synthesis was summarized.

Critical appraisal of individual sources of evidence

The quality of the included studies was assessed using the New JBI Levels of Evidence developed by the Joanna Briggs Institute Levels of Evidence and Grades of Recommendation Working Party of October 2013⁷. Then, a Checklist for Case Series⁸ and a Checklist for case reports were used⁹.

RESULTS

Selection of sources of evidence

The database search identified 196 articles. Excluding duplicates, a total of thirty-eight articles; one hundred and fifty-eight were considered eligible. However, forty-seven were excluded because titles and abstracts were considered

irrelevant to the topic or published before 2019. Subsequently, one hundred and eleven full-text articles were identified and assessed for eligibility. However, eighty-two publications were excluded because the data was insufficient to be extracted or calculated. Thus, twenty-nine articles were analyzed. The PRISMA-ScR flowchart for selecting the available studies is shown in Figure 1.

Characteristics of sources of evidence

The articles were carried out in different places, being Iran¹, Italy¹⁰⁻¹⁵, China¹⁶, the United States¹⁷⁻²⁰, France²¹⁻²⁴, Spain²⁵⁻³⁰, Canada³¹, Switzerland^{32,33}, Austria³⁴, Holland³⁵, Turkey³⁶, and Germany³⁷. Twenty-seven articles were in English and

three in Spanish, published in 2020 and presented in the data extraction Table 1.

Critical appraisal within sources of evidence

Twenty-six articles were case reports (level of evidence 4.d) and three case series (level of evidence 4.c). Therefore, it was observed that the studies included in this review have low levels of evidence, according to the New Levels of Evidence from JBI⁷. This can be explained due to the recent appearance of the disease.

Despite this, all studies were well designed and well evaluated by the JBI Critical Appraisal Checklist for Case Series⁸ and

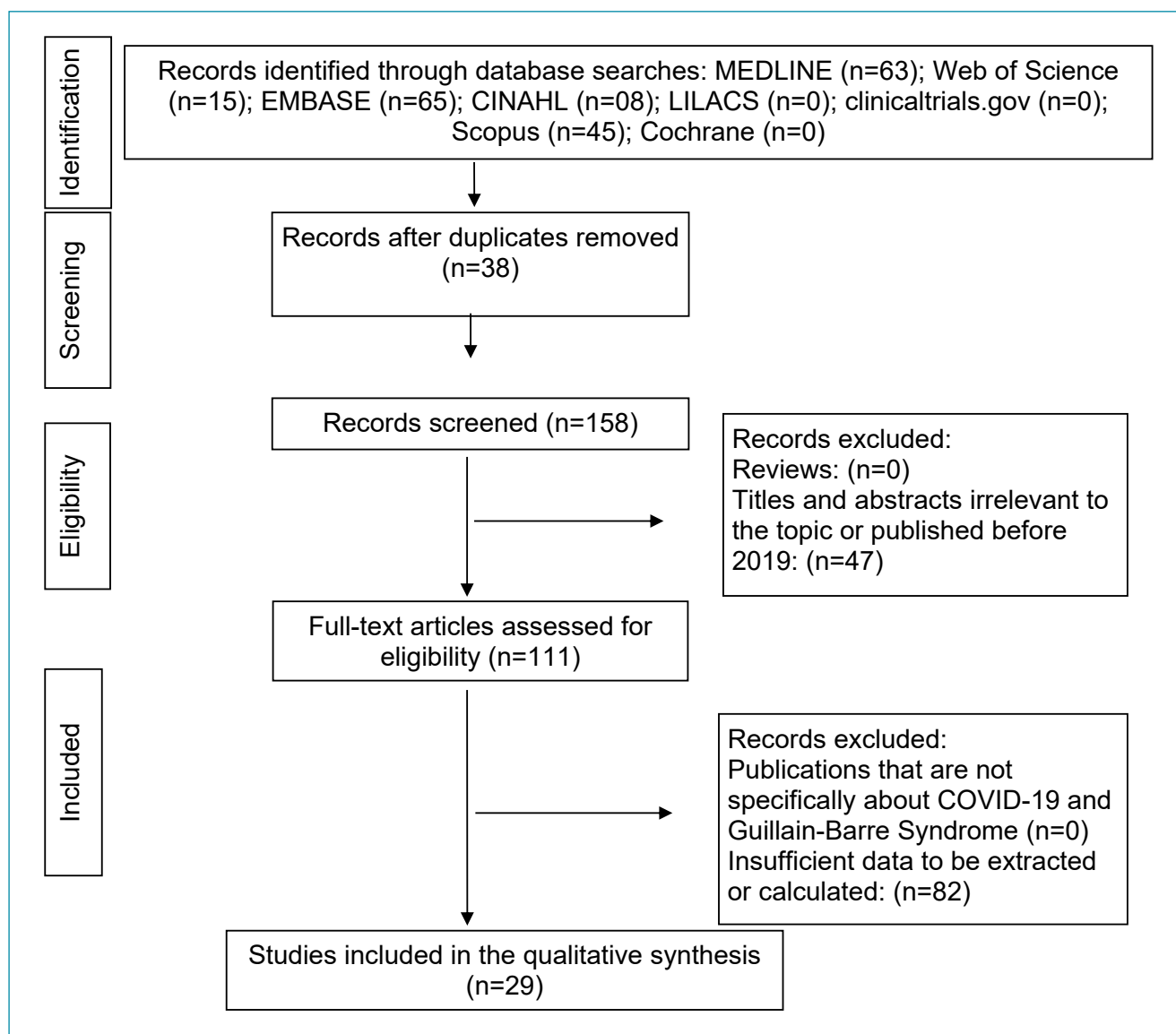


Figure 1. Flow diagram of the search for eligible studies COVID-19 and Guillain-Barre Syndrome: CENTRAL. Cochrane Central Register of Controlled Trials.

Table 1. Description of the characteristics of included studies.

Author	Gender	Age	Comorbidities	Clinical manifestations	Patient outcome	Chest imaging	Treatment	Diagnosis
Sedaghat et al. ¹	Male	65	Diabetes Mellitus 2	Presented neurological manifestations such as acute progressive weakness of the distal lower extremities, progressing from the distal to the proximal limbs and, shortly afterward, he presented quadriplegia and facial paresis bilaterally.	On physical examination, the patient had normal vital symptoms and was conscious.	CT showed diffused consolidations and ground-glass opacities in both lungs, and bilateral pleural effusion.	Hydroxychloroquine, LPV/RTV, and Azithro- mycin. And 0.40 g/kg/ day IVIg; and metformin 2 diabetes mellitus.	RT- PCR; chest CT and EMG.
Toscano et al. ¹⁰	P1 – Female	77	NA	Paresthesia in the lower limbs and hands. Flaccid areflexic tetraplegia evolving to facial weakness, upper-limb paresthesia (36 h), and respiratory failure (day 6)	Lymphocytopenia, Raised CRP, LDH, and ketonuria.	CT scan of the thorax revealed interstitial bilateral pneumonia.	IVIg treatment.	RT-PCR and EMG.
	P2 – Male	23	NA	Upper and lower facial weakness, which became bilateral and complete within 2 days, accompanied by mastoid pain, loss of taste, and lower limb paresthesia.	Lymphocytopenia, raised ferritine, CRP, LDH, and AST.	Normal thorax imaging.	Amoxicillin for five days and IVIg.	RT-PCR, EMG, and brain MRI.
	P3 – Male	55	NA	Flaccid tetraparesis and facial weakness evolving to areflexia (day 2) and respiratory failure (day 5).	Lymphocytopenia, raised CRP, LDH, AST, GGT, and ketonuria.	A CT scan of the thorax revealed multiple bilateral, ground-glass opacities compatible with interstitial pneumonia.	Azithromycin and received 2 cycles of IVIg.	RT-PCR and EMG.
	P4 – Male	76	NA	Lumbar pain and lower limb weakness and, on the 4 th day after admission, muscle weakness rapidly evolved to a flaccid areflexic tetraparesis.	Lymphocytopenia, raised CRP, ketonuria. IVIg treatment resulted in motor improvement, more evident in upper limbs, but still unable to stand.	Normal thorax imaging.	IVIg treatment.	RT-PCR
	P5 – Male	61	NA	Complained of asthenia, loss of taste and smell, for one week.	Lymphocytopenia, raised CRP, LDH, and AST. Developed respiratory failure with neuromuscular features (hypercapnia, paradox respiration, acidosis) and was referred to the ICU, where he received mechanical ventilation through tracheostomy. The patient developed acinetobacter pneumonia.	Thorax X-ray and CT showed interstitial pneumonia, without parenchymal opacities nor alveolar damage.	Received IVIg and plasma exchange; had bacterial pneumonia during IVIg treatment, which delayed plasma exchange.	RT-PCR and EMG.

Continue...

Table 1. Continuation.

Author	Gender	Age	Comorbidities	Clinical manifestations	Patient outcome	Chest imaging	Treatment	Diagnosis
Padroni et al. ¹¹	Female	70	NA	Complaining of asthenia, hands and feet paresthesia, and gait difficulties progressing within 1 day. On March 4 th she had developed fever (BT P= 38.5°C) and dry cough.	Arterial blood gas analysis showed pO ₂ =76 mmHg with normal p/f ratio (=363). The patient was intubated and mechanical ventilation was applied, because of respiratory failure due to the worsening of muscle weakness.	A chest high-resolution computed tomography revealed some small "ground glass" areas in both lungs.	IVIg 400mg/die for 5 days was started.	RT-PCR and the neurological examination disclosed moderate.
Alberti et al. ¹²	Male	71	Hypertension, abdominal aortic aneurysm, and lung cancer treated with surgery only in 2017 with negative oncological follow-up; no previous neurologic history was reported.	Paresthesia at limb extremities, followed by distal weakness rapidly evolving to a severe, flaccid tetraparesis over the previous 3 days. Neurologic examination showed symmetric limb weakness, symmetric and extensive stocking-and-glove hypesthesia at the 4 limbs (more pronounced at lower limbs), absent deep tendon reflexes, and normal plantar response. Moderate low back pain were present.	He showed hemodynamic disturbances with severe drug-resistant hypertension. Arterial blood gases indicated severe hypoxia (paO ₂ 65 mm Hg without supplemental oxygen). Unresponsive to continuous positive airway pressure ventilation and prone positioning. The patient died a few hours later because of progressive respiratory failure.	Brain CT scan was normal, whereas chest CT scan showed multiple bilateral ground glass opacities and consolidations, typical of COVID-19 pneumonia.	High-dose IV immunoglobulins (0.4 g/kg/d for 5 days) were started few hours after admission, together with high-flow 60%–80% oxygen via nonbreather mask, antiviral therapy (LPV + RTV), and hydroxychloroquine	RT- PCR; chest CT and EMG.
Assini et al. ¹³	P1 – Male	55	NA	Severe respiratory syndrome preceded by anosmia and ageusia, fever, and cough; acute onset of bilateral eyelid ptosis, dysphagia, and dysphonia.	Neurological examination showed bilateral masseter weakness, tongue protrusion deficit due to bilateral paralysis of the hypoglossal nerve, and hyporeflexia of upper and lower limbs, without muscle weakness. The patient was moved to ICU for invasive ventilation. Lymphocytopenia.	NA	Hydroxychloroquine, Arbidol, RTV and LPV; IVIg.	RT- PCR; EMG.
	P2 – Male	60	NA	Fever and cough; weakness in lower limbs with distal distribution and foot drop on the right side.	Simultaneously, massive disorders of the vegetative nervous system, consisting of gastroplegia, paralytic ileus, and loss of blood pressure control occurred. Neurological examination showed distal weakness at four limbs, with foot drop. Tracheostomy and assisted ventilation. Blood tests showed lymphocytopenia, increased LDH and GGT, and leukocytosis.	NA	Hydroxychloroquine, antiretroviral therapy, and tocilizumab. IVIg therapy.	RT-PCR and thoracic CT scan.

Continue...

Table 1. Continuation.

Author	Gender	Age	Comorbidities	Clinical manifestations	Patient outcome	Chest imaging	Treatment	Diagnosis
Ottaviani et al. ¹⁴	Female	66	NA	History of increasing difficulty walking and acute fatigue; she had mild fever and cough 10 days earlier. She also manifested a transient pruriginous dorsal rash, in addition to mild hypertension treated with beta-blockers. On evaluation, she was paraparetic with a rapidly progressive symmetric weakness in the lower limbs, leading to falls and paraplegia. Progressively developed proximal weakness in all limbs, dysesthesia, and unilateral facial palsy.	Maintaining reasonable respiratory function with supplemental oxygen. Moreover, gas exchanges worsened with a sudden desaturation, requiring intubation and ICU admission, where she was treated for multi-organ failure along with a leg deep vein thrombosis and a superimposed bacterial infection (<i>ab ingestis</i> pneumonia).	Lung CT scan showed bilateral ground glass opacities.	IVIg; antiretroviral drugs (LPV and RTV) and hydroxychloroquine.	RT-PCR and the neurological examination disclosed moderate (Medical Research Council grade 4/5).
Riva et al. ¹⁵	Male	60	NA	Three-day history of progressive limb weakness and distal paresthesia at four-limbs. His past medical history was unremarkable. Twenty days before, he had developed fever (37.7–38.5 °C), headache, and myalgia followed by anosmia and ageusia.	Cell blood count, CRP, creatine phosphokinase, arterial blood gases, renal and hepatic function tests were normal. Anti-ganglioside antibodies tested negative.	Chest CT scan showed bilateral ground-glass opacities, consistent with COVID-19 pneumonia.	IVIg;	Antibodies for SARS-CoV-2 IgM/IgG and the neurological examination disclosed moderate.
Zhao et al. ¹⁶	Female	61	NA	Presented with acute weakness in both legs and severe fatigue. Neurological examination disclosed symmetric weakness.	Her clinical condition improved gradually and her lymphocyte and thrombocyte counts normalized on day 20. At discharge on day 30, she had normal muscle strength in both arms and legs and return of tendon reflexes in both legs and feet.	Chest CT showed ground-glass opacities in both lungs.	IVIg; infection isolation room and received supportive care and antiviral drugs of arbidol, LPV, and RTV.	RT-PCR
Virani et al. ¹⁷	Male	54	NA	Complaints of numbness and weakness of his lower extremities of 2-day duration. The weakness progressed. The patient complained of difficulty breathing and weakness was noted to ascend up to his nipples.	He was electively placed on mechanical ventilator support for concerns of impending respiratory failure. His clinical course showed improvement in his respiratory status with liberation from mechanical ventilation on day 4 of IVIg therapy. Neurologically, his upper extremity weakness resolved after completion of the course of IVIg. Lower extremity weakness persisted.	MRI of thoracic and lumbar spine that did not reveal any abnormal spinal pathology. This imaging, however, did reveal incidental findings of bilateral basilar opacities in the lungs.	Oral amoxicillin and steroids. 400mg/kg of IVIg therapy for a planned 5-day course. Hydroxychloroquine 400 mg for the first two doses with subsequent 200 mg dose twice a day for an additional eight doses.	RT-PCR and MRI.

Continue...

Table 1. Continuation.

Author	Gender	Age	Comorbidities	Clinical manifestations	Patient outcome	Chest imaging	Treatment	Diagnosis
Rana et al. ¹⁸	Male	54	Hypertension, hyperlipidemia, restless leg syndrome, and chronic back pain.	Ascending limb weakness and numbness that followed symptoms of a respiratory infection. Two weeks before presentation, he initially developed rhinorrhea, odynophagia, fevers, chills, and night sweats; he developed watery diarrhea; Over the next few days, he noted worsening paresthesias of his distal extremities bilaterally. His symptoms progressed to weakness of all limbs and difficulty voiding urine, developed progressive shortness of breath requiring intubation. Quadriparesis and areflexia with mute plantar responses.	He was extubated on hospital day 4. On hospital day 7, he was discharged to an inpatient rehabilitation facility. While in the inpatient rehabilitation, he was noted to have resting tachycardia and persistent difficulty urinating, which eventually required an indwelling catheter. He reported burning dysesthesias in his distal extremities and trunk, and complained of diplopia, which was worse on rightward.	Chest X-ray was negative other than an incidental finding of bibasilar lung infiltrates versus atelectasis. MRI of the thoracic and lumbar spine was reported to show no evidence of myelopathy or radiculopathy.	Amoxicillin; metronidazole. Hydroxychloroquine and azithromycin; IVIg.	RT-PCR; the neurological examination disclosed moderate (Medical Research Council grade 4/5) and EMG.
Su et al. ¹⁹	Male	72	Coronary artery disease, hypertension, and alcohol abuse	Symmetric aresthesias and ascending appendicular weakness. Seven days earlier he had mild diarrhea, anorexia, and chills, without fever or respiratory symptoms. This condition resolved in 5 days. Weakness began 6 days after diarrhea, and the patient presented 1 day after neurological symptom onset. On admission, he was afebrile with normal vital signs. Mental status and CN were normal.	On day 3, the patient developed respiratory distress with a negative inspiratory force of -20 cm H ₂ O and vital capacity of 1,350 mL. He was transferred to the ICU and intubated. He remained afebrile and followed commands. Oxygen saturation was normal on ventilator settings positive end-expiratory pressure 5 cm H ₂ O and fraction of inspired oxygen 30%. Chest X-ray was stable. Sputum culture grew <i>Stenotrophomonas maltophilia</i> .	Chest X-ray showed mild bibasilar atelectasis vs. patchy consolidations. Computed tomography of the head was normal. Incompatible implant precluded MRI. On day 10, his oropharyngeal secretions increased, and chest X-ray showed new right lower lobe consolidation.	IVIg	RT-PCR and the neurological examination disclosed moderate (Medical Research Council grade 4/5).
Lantos et al. ²⁰	Male	36	NA	Presenting with left eye drooping, blurry vision, and reduced sensation and paresthesia in both legs for 2 days. He was in his usual state of health until 4 days before presentation, when he developed viral symptoms in a COVID-19-endemic region, reporting subjective fevers, chills, and myalgia.	Physical examination was notable for a partial left third nerve palsy and decreased sensation below the knees to all modalities. Nonetheless, the patient's hospital course was characterized by progressive ophthalmoparesis (including initial left CN III and eventual bilateral CN VI palsies), ataxia, and hyporeflexia, and the clinical picture was thought to be consistent with MFS from COVID-19 infection.	Brain MRI: prominent enhancement with gadolinium, and T2 hyperintense signal of the left CN III. No other CN demonstrated abnormal signal. No cerebellar lesions were seen to explain the patient's ataxia.	IVIg; hydroxychloroquine.	RT-PCR and RMI.

Continue...

Table 1. Continuation.

Author	Gender	Age	Comorbidities	Clinical manifestations	Patient outcome	Chest imaging	Treatment	Diagnosis
Camdessanche et al. ²¹	Male	64	NA	The patient fell and hurt his left shoulder leading to a tear of the rotator cuff. Eleven days after the symptom onset, the patient complained of paresthesia in feet and hands. In three days, he installed a flaccid severe tetraparesia. The patient complained of swallowing disturbance with a risk of suffocation.	Clinical presentation was moderate with high grade fever for three days requiring oxygen 2–3 L/min through nasal cannula for five days. The patient was admitted in ICU and mechanically ventilated because of respiratory insufficiency.	Thoracic CT scan showed only 10–25% of ground glass opacities.	Paracetamol, preventing thromboembolism by low molecular weight heparin and LPV/RTV 400/100 mg twice a day for ten days. IVIg (0.4g/kg per day during 5 days).	EMG
Arnaud et al. ²²	Male	64	Diabetes mellitus type 2	Cough, dyspnea, diarrhea, and fever. Fast progressive lower-limb weakness; The neurological examination showed generalized areflexia, severe flaccid paraparesis, mainly affecting proximal muscles, and a decreased proprioceptive length-dependent sensitivity involving the four limbs. We also found hypoesthesia to light touch and pinprick in lower extremities rather.	Respiratory rate was 30 breaths/min and oxygen saturation was 93% on ambient air. Lung auscultation revealed diffuse crackles.	A chest CT showed bilateral, diffuse and subpleural ground-glass opacities with a crazy-paving appearance, and a band of air space consolidation.	Cefotaxime, Azithromycin; IVIg and Hydroxychloroquine.	RT-PCR and EMG.
Bigaut et al. ²³	P1 – Male	43	NA	Presented with cough, asthenia, and myalgia in legs, followed by acute anosmia and ageusia with diarrhea the next day. Symptoms resolved spontaneously after 2 weeks. Twenty-one days after the beginning of respiratory symptoms, he presented with a rapidly progressive manner paraesthesia, hypoesthesia, and distal weakness in the lower limbs. In the following 2 days, these symptoms extended to the midhigh and tip of the fingers associated with ataxia, and he was hospitalized at day 4 due to a right peripheral facial palsy.	His BT was 36.9°C and oxygen saturation was 99%.	CT of the chest showed ground-glass opacities; MRI at day 7 showed multiple cranial neuritis (in nerves III, V, VI, VII, and VIII), radiculitis, and plexitis on both the brachial and lumbar plexus.	IVIg.	RT-PCR and the neurological examination disclosed moderate (Medical Research Council grade 4/5).
	P2 – Female	70	Obesity	Anosmia and ageusia, followed by diarrhea for 2 days. She complained of mild asthenia and myalgia without fever. Seven days later, she presented with acute proximal tetraparesis and distal forelimb, perioral dyspnea, and loss of ambulation.	Rapidly transferred to an ICU for noninvasive ventilation for acute respiratory failure with hypercapnia. She was discharged from the ICU 9 days later, without requiring invasive mechanical ventilation. Her clinical condition improved slowly with physiotherapy, needing a transfer in a rehabilitation center.	CT of the chest showed moderate ground-glass opacities in both lungs.	IVIg.	RT-PCR and the neurological examination disclosed moderate (Medical Research Council grade 4/5).

Continue...

Table 1. Continuation.

Author	Gender	Age	Comorbidities	Clinical manifestations	Patient outcome	Chest imaging	Treatment	Diagnosis
El Otmani et al. ²⁴	Female	70	Rheumatoid arthritis	Presented with a rapidly, bilateral weakness and tingling sensation in all four extremities resulting in a total functional disability within 48 hours. The patient denied any sphincter disturbances, dyspnea or swallowing difficulties. Neurological examination showed quadriplegia, hypotonia, areflexia, and bilateral positive Lase'gue sign. CN were intact. Three days prior to the ongoing symptoms' onset, the patient presented an episode of dry cough without dyspnea or fever, spontaneously resolving within 48 hours.	Temperature, lung, and cardiac auscultation were also normal.	Chest CT (day 10) revealed ground-glass opacities in the left lung.	IVIg (2 g/kg for 5 days) and a combination of Hydroxychloroquine (600 mg per day) and Azithromycine.	RT-PCR
Juliao Caamaño et al. ²⁵	Male	61	NA	Fever and coughing without dyspnea on day 1 of the illness; right peripheral facial nerve palsy.	NA	Brain CT and MRI were performed without any acute pathological findings.	Hydroxychloroquine and LPV/RTV; oral prednisone.	X-ray and RT-PCR.
Galán et al. ²⁶	Male	43	NA	Consultation for symmetric and global weakness of the 4 extremities of progressive intensity with impossibility for walking, as well as alteration in the sensitivity of the 4 members at the distal level. Three days before, there was a self-limited diarrhea episode, followed by symptoms of infection of the upper respiratory tract, bilateral facial paresis, and dysphagia.	NA	In the X-ray of thorax there are alterations suggestive of Early pneumonia by COVID-19.	IVIg; sulfate hydroxychloroquine, antiretrovirals (LPV and RTV), antibiotic (amoxicillin), corticosteroids and oxygen therapy low flow.	RT-PCR; EMG and the neurological examination disclosed moderate (Medical Research Council grade 4/5).
Marta-Enguita et al. ²⁷	Female	76	NA	Evolution of low back pain radiating to the posterior aspect of both legs and progressive tetraparesis with paresthesias of distal onset. The pain was bilateral, with right predominance and greater night intensity. He associated progressive weakness predominantly proximal in the lower extremities, and 2 days before our evaluation, he presented weakness in the upper extremities, with functional limitation. Eight days before the onset of the symptoms, he had started with a cough and fever without dyspnea, with 72 hours of evolution; He associated global areflexia and hypoesthesia in both legs.	The patient was admitted and at 4 h presented dysphagia for liquids and progressively for solids, with a nasal voice and difficulty swallowing her own saliva, with progressive onset of a picture of ventilatory failure. She presents progressive deterioration, requiring oxygen therapy (FIO ₂ 60%), with maintained SatO ₂ levels of around 91%, which do not show a problem of alveolar capillary junction or gas exchange. Finally, she dies at 12 h.	Normal cranial CT and cervical spine were performed, showing degenerative signs at the level of the vertebral bodies, without invasion of the spinal canal. On chest CT, a pattern compatible with the level of pulmonary impairment due to SARS-CoV-2 infection was observed.	NSAID, pyrazolones, and transdermal morphics. amoxicillin-clavulanic acid, and azithromycin.	RT-PCR

Continue...

Table 1. Continuation.

Author	Gender	Age	Comorbidities	Clinical manifestations	Patient outcome	Chest imaging	Treatment	Diagnosis
Molina et al. ²⁸	Female	55	Dyslipemia and active smoking.	Fever, unproductive cough and dyspnea after 15 days of evolution. In the past 24 hours, she reported paresthesias in the hands and feet, as well as weakness in the lower extremities. Severe low back pain radiating to both legs with progressive weakness in the 4 extremities associated with dysphagia. At 48 hours, the patient presented worsening of neurological symptoms, with areflexic tetraparesis. Along with this, liquid dysphagia, bilateral facial diplegia, weakness in closing the eyelids, lingual and perioral paresthesias. No meningeal signs.	At initial examination, the patient is conscious and oriented. Blood pressure 155/102 mmHg, heart rate 103 beats per minute, temperature 36.6 °C, oxygen saturation 93% basal (SatO ₂). Eupneic with 20 breaths per minute. Bibasal crackles on pulmonary auscultation. Strength and sensitivity preserved in the 4 limbs. Rest of physical examination without significant changes. Adequate ventilatory mechanics and SatO ₂ without the need for respiratory support. In this context, it was decided to transfer to the ICU.	Chest radiography revealed consolidation in the left lower lobe; Using MRI, a slight leptomeningeal improvement is observed in the brain stem and cervical cord.	hydroxychloroquine, ceftriaxone and azithromycin; IVlg.	RT-PCR and the neurological examination disclosed moderate (Medical Research Council grade 4/5).
Sancho-Saldaña et al. ²⁹	Female	56	NA	Recent unsteadiness and paraesthesia in both hands. Fifteen days earlier, she had reported fever, dry cough, and shortness of breath that was controlled with symptomatic treatment. she developed lumbar pain and progressive proximal lower limb weakness, bilateral facial nerve palsy, oropharyngeal weakness, and severe proximal tetraparesis with cervical flexion.	She was transferred to the ICU for 5 days due to the risk of respiratory insufficiency and began rehabilitation, not needing mechanical ventilation. She started recovering by day 7 after the onset of weakness.	Her chest X-ray showed a lobar consolidation.	hydroxychloroquine and azithromycin; IVlg.	RT-PCR and the neurological examination disclosed moderate (Medical Research Council grade 4/5).
Reyes-Bueno et al. ³⁰	Female	51	NA	Diarrhea, odynophagia, and cough. The condition lasted approximately 10 days, after which she kept feeling discomfort in the throat. She did not refer ageusia or anosmia.	From March 30 th , she started having intense root-type pain in all four limbs, especially in the legs as well as dorsal and lumbar back pain. On April 4 th she started with weakness in her lower limbs, which progressed to the point of preventing her from walking in a few days, associated with double binocular vision. The neurological exploration showed paresis of the left external rectus muscle with horizontal diplopia when looking to the left, discrete predominantly inferior bilateral facial paresis, symmetrical paraparesis with 3+/5 weakness in psoas, hamstrings, gluteus, and quadriceps, 3/5 in gastrocnemius, 2/5 in posterior tibial and peroneal; and global areflexia. She also presented symptoms of autonomic dysfunction such as dry mouth, diarrhea, and unstable blood pressure.	NA	IVlg.	RT-PCR and ELISA technique; the neurological examination disclosed moderate (Medical Research Council grade 4/5).

Continue...

Table 1. Continuation.

Author	Gender	Age	Comorbidities	Clinical manifestations	Patient outcome	Chest imaging	Treatment	Diagnosis
Chan et al. ³¹	Male	58	NA	Presented with acute-onset bilateral facial weakness, dysarthria, and paresthesia in his feet. He denied any other neurological symptoms, including anosmia and ageusia. He denied fever, fatigue, cough, shortness of breath, or any other symptoms on review of systems. Neurological examination demonstrated complete facial diplegia and areflexia in the lower extremities. he had slight movements of his facial muscles and the distal paresthesias of his lower extremities were unchanged.	Temperature of 36.6°C, maximum heart rate of 140 beats/minute, maximum blood pressure of 187/103 mmHg, maximum respiratory rate of 34 breaths/minute, and an oxygen saturation of 96% on room air, with resolution of tachycardia, hypertension, and tachypnea within 12 hours. Auscultation of the lungs revealed diffuse crackles bilaterally.	Chest x-ray demonstrated diffuse heterogeneous infiltration in both lungs. CT and CTA of the head and neck did not demonstrate any intracranial or vascular abnormalities but demonstrated ground-glass opacities in both lung apices.	Empiric ceftriaxone and azithromycin; IVIg.	RT-PCR and EMG;
Coen et al. ³²	Male	70	NA	Paraparesis, distal allodynia, difficulties in voiding and constipation. Ten days before he developed myalgia, fatigue, and a dry cough.	Physical examination revealed fine crackles in the left base, bilateral lower limb flaccid paresis, absent deep tendon reflexes of the upper and lower limb and idiomuscular response to percussion of the muscle tibialis anterior, indifferent plantar reflexes. There was no sensory deficit. FilmArray Meningitis/ Encephalitis (ME) Panel testing (BioFire Diagnostics, Salt Lake City, UT) and SARS-CoV-2 RT-PCR were negative. showed decreased persistence or absent F-waves in tested nerves.	Chest X-ray was normal. Contrast-enhanced MRI excluded myelopathy. Nerve conduction study showed sensorimotor demyelinating polyneuropathy with "sural sparing pattern"; F wave study showed decreased persistence or absent F-waves in tested nerves.	IVIg.	RT-PCR and ELISA technique.

Continue...

Table 1. Continuation.

Author	Gender	Age	Comorbidities	Clinical manifestations	Patient outcome	Chest imaging	Treatment	Diagnosis
Lascano et al. ³³	P1 – Female	52	NA	Dry cough, fever, odynophagia, arthralgia, diarrhoea. Back pain, limb weakness, ataxia, distal paresthesia, dysgeusia, cacosmia. Developed respiratory failure, dysautonomia, and tetraplegia with areflexia.	Improvement of tetraparesis. Able to stand up with assistance. GBS disability clinical score 4/6. Spinal cord: no nerve root gadolinium enhancement.	NA	IVIg	RT-PCR and Antibodies for SARS-CoV-2 IgM/IgG.
	P2 – Female	63	Diabetes mellitus type 2	Dry cough, shivering, odynophagia, breathing difficulties, chest pain. Lower limb pain, mild weakness and normal deep tendon reflexes. Developed tetraparesis, distal paresthesia and areflexia.	Dismissal with full motor recovery. Persistence of lower limb areflexia and distal paresthesia. GBS disability clinical score 1/6.	NA	IVIg	RT-PCR
	P3 – Female	61	NA	Productive cough, fever, myalgia, vasovagal syncope, diarrhoea, nausea and vomiting. Lower limb weakness and distal paresthesia, dizziness, dysphagia, dysautonomia, areflexia. Presented worsening of bulbar symptoms and bilateral facial palsy.	Improvement of tetraparesis and ability to walk with assistance. Persistence of neuropathic pain and distal paresthesia. GBS disability clinical score 3/6. Spinal cord: lumbosacral nerve root enhancement. Normal brain imaging.	NA	IVIg	RT-PCR
Helbok et al. ³⁴	Male	68	NA	Cough, headache, fatigue, myalgia and fever up to 39°C followed by anosmia and ageusia. but still complained of severe fatigue and developed symmetric distal tingling in both feet followed by ascending dysesthesias up to the knees and proximal weakness.	His respiratory condition worsened, and the patient required oxygen supplementation (3L/min) followed by pressure support non-invasive ventilation after 36 h. The next day he presented inability to walk. On examination, the patient was alert and fully oriented, afebrile with normal vital signs (oxygen saturation 98% on room air, blood pressure 143/90mmHg, heat rate 85 bpm). Due to muscle weakness accompanied by respiratory failure the patient underwent elective intubation in a fully conscious state.	Chest Computed tomography was performed and revealed residual ground-glass opacities in both lower lungs	IVIg and plasma exchange	RT-PCR and Antibodies for SARS-CoV-2 IgM/IgG; the neurological examination disclosed moderate (Medical Research Council grade 4/5).

Continue...

Table 1. Continuation.

Author	Gender	Age	Comorbidities	Clinical manifestations	Patient outcome	Chest imaging	Treatment	Diagnosis
Kilinc et al. ³⁵	Male	50	NA	Four days of progressive bilateral facial weakness, paresthesia of distal extremities and an unsteady gait. Four weeks earlier he had experienced an episode of dry cough lasting several days without fever or other symptoms of infection. Neurologic examination showed facial diplegia, normal eye movements, mild symmetric proximal muscle weakness and impaired proprioception in the legs. Patient had an ataxic gait and tendon reflexes were absent.	Routine blood examination showed no abnormalities. Routine analysis of CSF showed a normal cell count and total protein level.			RT-PCR and Antibodies for SARS-CoV-2 IgM/IgG; EMG.
Oguz-Akarsu et al. ³⁶	Female	53	NA	History of dysarthria associated with progressive weakness and numbness of the lower extremities. She had a mild fever (37.5°C) but no cough, dyspnea, anosmia or ageusia.	NA	Focal intensities suspicious for COVID-19 pneumonia were incidentally identified in peripheral areas of lungs on STIR sequence of the brachial plexus MRI; Chest computed tomography showed bilateral peripheral ground-glass opacities and consolidations on both lungs.	Plasma exchange; hydroxychloroquine and azithromycin.	RT-PCR
Scheidl et al. ³⁷	Female	54	NA	Areflexia, numbness, and tingling of all extremities were also found, with initial maintained gain ability. She did not experience fever, respiratory or gastrointestinal symptoms, but reported about a transient loss of smell and taste 2 weeks before the GBS symptoms occurred.	The first electrophysiological evaluation (at admission) showed significantly prolonged distal motor latencies and temporal dispersion of the CMAP of the common peroneal nerve bilaterally.	MRI of the cervical spine and the chest x-ray examination did not show pathological findings. Electrophysiological studies were performed using a Nicolet Viking EMG device.	IVIg	RT-PCR and EMG.

LPV: lopinavir; RTV: ritonavir; RT-PCR: real-time reverse transcriptase; CT: chest tomography; EMG: electromyography; NA: Not Applicable; CRP: C-reactive protein; LDH: lactate dehydrogenase; IVIg: intravenous immune globulin; AST: aspartate aminotransferase; MRI: magnetic resonance imaging; GGT: gamma-glutamyltranspeptidase; ICU: intensive care unit; BT: body temperature; CN: cranial nerve; MFS: Miller Fisher Syndrome; NSAID: non-steroidal anti-inflammatory drugs; ELISA: enzyme-linked immunosorbent assay; CTA: CT angiography; GBS: Guillain-Barre Syndrome; CSF: cerebrospinal fluid; STIR: Short-Tau Inversion Recovery; CMAP: compound muscle action potentials.

Case Reports⁹, that is, they achieved a high score and, thusly, were included in the review.

Synthesis of results

Clinical manifestations

Main clinical manifestations were fever, coughing, dyspnea, sore throat, ageusia, anosmia, respiratory failure, and diarrhea, as shown in Figure 2.

Toscano et al.¹⁰ describing three patients [P1, P3, and P5] who received mechanical ventilation and two who were admitted to the Intensive Care Unit (ICU) [P3 and P5]. The condition of P5 deteriorates during hospitalization, presentation of hypercapnia, paradoxical breathing, and acidosis, leading to admission to the ICU, where mechanical ventilation by tracheostomy and pneumonia by acinetobacter is allowed.

Alberti et al.¹² describing a patient with hemodynamic disorders with severe drug-resistant hypertension and arterial blood gases indicate severe hypoxia.

Assini et al.¹³ described a patient who needs tracheostomy and assisted ventilation [P2].

Ottaviani et al.¹⁴ described a patient who was treated for organ failure, in addition to deep venous thrombosis of the legs and overlapping bacterial infection (pneumonia *ab ingestis*).

Rana et al.¹⁸ described a patient who developed persistent difficulty in urinating, or who ended up requiring a permanent catheter.

Su et al.¹⁹ described a patient who had a sputum culture *Stenotrophomonas maltophilia*, an organism associated with pneumonia associated with mechanical ventilation.

However, Chan et al.³¹ described an asymptomatic patient. In addition, other patients require ventilatory support^{11-14,16,17,19,21,23,27,29,34}, five need intubation^{11,14,18,19,34}, and eight were admitted to the ICU^{11,13,14,17,19,21,23,29}. However, two^{12,27} of the twenty-nine patients died during treatment from progressive respiratory failure.

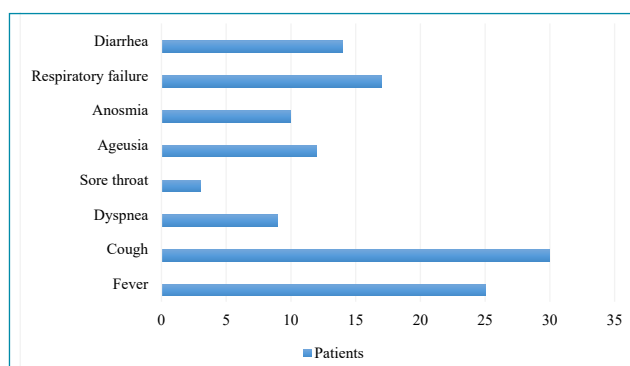


Figure 2. Prevalence of symptoms.

Diagnosis

The main methods for diagnosing SARS-Cov-2 infection (COVID-19) were nasopharyngeal swabs for polymerase chain reaction with real-time reverse transcriptase (RT-PCR), enzyme-linked immunosorbent assay (ELISA) technique, chest radiography, chest tomography (CT), and clinical examination^{1,10-37}.

Sixteen studies used CT and RT-PCR in the chest^{1,10-14,16,17,21-25,27,36,37}; six studies used chest radiography and RT-PCR^{17-19,26,28,29}; five studies used only RT-PCR^{20,31-33,37}; two studies used the ELISA and CT technique^{15,34}; and two studies used only the ELISA technique^{30,35}.

Electromyography and clinical methods were used for the diagnosis of GBS^{1,10-37}, with strong muscle evaluation using the Medical Research Council (MRC)^{1,10,12,14-16,18,19,21,23,26,29,34,36}.

Treatment

The main treatment methods mentioned were empirical antibiotics^{1,10,16-18,21,22,24,26-29,31,36}; Hydroxychloroquine^{1,12-14,16,18,20,22-26,28,29,36}; antivirals (lopinavir and ritonavir)^{1,10,12-14,21,25,26}; room isolation^{10,16}; and plasma exchange^{17,34,36}. Thirty-six patients were treated with intravenous immunoglobulin (IVIg)^{1,10-24,26,28-35,37}.

Neurological outcome

The main neurological manifestations were: weakness in the lower extremities^{1,10,12,14-18,22-24,29,30,33,35}; paresthesia of the upper and lower limbs^{11,12,15,17-19,21,23,24,28,29,31,33-35,37}; tetraparesis^{1,12,17,21,23,27-29,33}; facial diplegia^{1,14,17,23,25,26,28-31,33,35}; areflexia^{10,17,18,22,24,27,30,31,33}; asthenia^{11,17,23}; mastoid pain and sensitive ataxia¹⁷; fatigue^{10,14,32,34}; numbness^{16,18,36,37}; swallowing disorders^{21,26-28,33}; low back pain^{12,27-29}; difficulty or loss in walking^{14,23,26,30,35}; myalgia^{15,20,23,30,32-34}; odynophagia^{18,30,33}; hypoesthesia^{22,23,27}; paraparesis^{22,30,32}; dysarthria^{31,36}; hyporeflexia^{13,20}; bilateral eyelid ptosis¹³; progressive ophthalmoparesis²⁰; desesthesia^{14,34}; dysgeusia, cacosmia, disautonomy, arthralgia, and tetraplegia³³.

Patient outcomes

Main patient outcomes were:

- Only nine studies revealed comorbidities, type 2 diabetes mellitus^{1,22,33}; hypertension, abdominal aortic aneurysm and lung cancer¹²; obesity²³; dyslipidemia and active smoking²⁸; rheumatoid arthritis²⁴; hypertension, hyperlipidemia, restless legs syndrome, and back pain¹⁸; and coronary artery disease, hypertension, and alcohol¹⁹;
- Patients with lymphopenia^{10,13,17,28,33,36};
- Images showing multiple opacities in the ground glass^{1,10-12,14-17,19-24,26,28,29,31,34,36} or inflammation in the lungs and a small amount of pleural effusion^{1,17};

- Muscle strength testing showed failure in four limbs using a MRC scale^{1,10,12,14-16,18,19,21,26,29,34,36};
- Hospitalizations in ICU^{11,13,14,17,19,21,29} and patients with advanced support for mechanical ventilation of the airways^{11-14,16,19,21,23,27,29,34};
- Patients undergoing physical therapy for rehabilitation^{16-18,23};
- Lung auscultation revealed diffuse rales²²;
- Cases presenting variant forms of GBS, such as acute sensory-motor neuropathy, acute axonal neuropathy, and Miller-Fisher syndrome^{1,13,25,30}.

DISCUSSION

Until now, little is known about the neurological manifestations from COVID-19 and its direct relationship with GBS. The first case where neurological characteristics were observed standing out from the COVID-19 clinical symptoms was recently described; main symptoms included acute weakness in the legs and severe fatigue, with rapid progression¹⁰. For this reason, there are concerns that this virus is a possible trigger for GBS.

Sedaghat & Karimi¹, in one case report, described GBS for the first time in a patient infected with COVID-19. The patient reported acute progressive symmetric ascending quadriparesis. Two weeks before hospitalization, the patient suffered from cough, fever, and RT-PCR was reported positive for COVID-19 infection. The electrodiagnostic test showed that the patient had an Acute Motor-Sensory Axonal Neuropathy (AMSAN) variant of GBS.

In the study carried out by Toscano et al.¹⁰, five patients with GBS after the onset of Covid-19 were examined. The first symptoms were lower-limb weakness and paresthesia in four patients and facial diplegia, followed by ataxia and paresthesia in one patient. In summary, flaccid tetraparesis or tetraplegia evolved from 36 hours to 4 days in four patients; three received mechanical ventilation. The interval between the onset of symptoms of Covid-19 and the first symptoms of GBS ranged from 5 to 10 days. This interval is similar that seen with GBS that occurs during or after other infections. As in previous studies, the authors point out that a possible relationship between these two diseases is the fact that COVID-19 through stimulation of inflammatory cells produces various inflammatory cytokines, and as a result, creates immune-mediated processes. As the GBS is an immune-mediated disorder, molecular mimicry as a mechanism of autoimmune disorder plays a vital role in its creation.

Zhao et al.¹⁶ reported a woman who presented with acute weakness in both legs and severe fatigue, progressing within one day. Neurological examination disclosed symmetric weakness

and areflexia in both legs and feet. Three days after admission, her symptoms progressed. Oropharyngeal swabs were positive for SARS-CoV-2 with RT-PCR assay. Considering the temporal association, it was speculated that the SARS-CoV-2 infection might have been responsible for the development of GBS.

Virani et al.¹⁷, in their study, described a case where the patient with COVID-19 presented neurological symptoms, including numbness and weakness of the extremities; consequently, there was a decrease in tendon reflexes with rapid progression. The mechanism proposed for this association is an autoimmune reaction where antibodies to surface glycoproteins are developed in the offending pathogen that also corresponds to similar protein structures of peripheral nerve components (molecular mimicry), leading to neurologic involvement.

Camdessanche et al.²¹, in their study, also reported on one patient without medical history who was admitted after he fell and hurt the left shoulder, leading to a tear of the rotator cuff. He had a fever and cough for two days. SARS-CoV-2 RT-PCR with nasopharyngeal swab was performed and proved to be positive. Eleven days after symptom onset, the patient complained of paresthesia in both feet and hands. In three days, he demonstrated severe flaccid tetraparesis. The patient complained of swallowing disturbance with a risk of suffocation as liquids took the wrong path. The patient was admitted to ICU and mechanically ventilated due to respiratory insufficiency.

Padroni et al.¹¹ described a case of GBS following a clinically resolved paucisymptomatic COVID-19. The patient complained of asthenia, hands, and feet paresthesia, and gait difficulties, progressing within one day. Symptoms of COVID-19 were resolved in a few days. Neurological examination disclosed moderate symmetric distal upper and lower limb weakness, loss of deep tendon reflexes, preserved light touch, and pinpricking sensation.

Assini et al.¹³ described two cases of GBS and COVID-19. In one of them, the patient needed invasive ventilation in the ICU and had an acute onset of bilateral eyelid ptosis, dysphonia, and dysphagia 20 days after admission. Furthermore, through neurological examination, he demonstrated a deficit in the protrusion of the tongue due to bilateral paralysis of the hypoglossal nerve and hyporeflexia of the upper and lower limbs, along with bilateral masseter weakness.

Putting together all of these findings, the causal association between GBS and COVID-19 remains speculative but very probable. Neurologists and other clinicians should be aware of the essential early recognition and treatment of the potential neuromuscular and autonomic worsening leading to cardio-respiratory failure in patients with GBS and mild or controlled pulmonary COVID-19. More in-depth research should be

carried out about this association, so that there is an established protocol of suitable diagnosis and treatment, in order to avoid high degrees of debilitation caused by GBS.

Limitations

The main limitation of this review was the lack of studies with a larger number of patients.

CONCLUSION

In conclusion, through well-designed primary studies, it is evident that COVID-19 can trigger GBS, as patients had clinical manifestations of COVID-19 infection and neurological manifestations characterizing GBS. Although the small number

of patients limited our estimates, we believe that the results listed here are important for a better diagnosis and treatment of patients with neurological symptoms concomitant with respiratory symptoms

AUTHORS' CONTRIBUTIONS

KSM: Conceptualization, Data Curation, Formal Analysis, Supervision, Writing – Original Draft, Writing – Review & Editing. **LTAM:** Conceptualization, Data Curation, Formal Analysis, Writing – Original Draft. **ACS:** Conceptualization, Formal Analysis, Writing – Original Draft. **WFS:** Data Curation, Formal Analysis. **AKG:** Supervision, Writing – Review & Editing. **APF:** Writing – Review & Editing.

REFERENCES

- Sedaghat Z, Karimi N. Guillain Barre syndrome associated with COVID-19 infection: a case report. *J Clin Neurosci*. 2020;76:233-5. <https://doi.org/10.1016/j.jocn.2020.04.062>
- Sejvar JJ, Baughman AL, Wise M, Morgan OW. Population incidence of Guillain-Barré syndrome: a systematic review and meta-analysis. *Neuroepidemiology*. 2011;36(2):123-33. <https://doi.org/10.1159/000324710>
- Huang X, Wei F, Hu L, Wen L, Chen K. Epidemiology and clinical characteristics of COVID-19. *Arch Iran Med*. 2020;23(4):268-71. <https://doi.org/10.34172/aim.2020.09>
- Wu Y, Xu X, Chen Z, Duan J, Hashimoto K, Yang L, et al. Nervous system involvement after infection with COVID-19 and other coronaviruses. *Brain Behav Immun*. 2020;87:18-22. <https://doi.org/10.1016/j.bbi.2020.03.031>
- Tricco AC, Lillie E, Zarin W, O'Brien KK, Colquhoun H, Levac D, et al. PRISMA Extension for Scoping Reviews (PRISMA-ScR): checklist and explanation. *Ann Intern Med*. 2018;169(7):467-73. <https://doi.org/10.7326/M18-0850>
- Huang C, Wang Y, Li X, Ren L, Zhao J, Hu Y, et al. Clinical features of patients infected with 2019 novel coronavirus in Wuhan, China. *Lancet*. 2020;395(10223):497-506. [https://doi.org/10.1016/S0140-6736\(20\)30183-5](https://doi.org/10.1016/S0140-6736(20)30183-5)
- Joanna Briggs Institute. Levels of evidence: developed by the Joanna Briggs Institute. Levels of evidence and grades of recommendation working part. Adelaide: The Joanna Briggs Institute; 2013. [cited on Aug. 01, 2020]. Available from: https://joannabriggs.org/sites/default/files/2019-05/JBI-Levels-of-evidence_2014_0.pdf
- Joanna Briggs Institute. The Joanna Briggs Institute critical appraisal tools for use in JBI systematic reviews checklist for case series. Adelaide: The Joanna Briggs Institute. [cited on Aug. 01, 2020]. Available from: <http://joannabriggs.org/research/critical-appraisal-tools.html>
- Joanna Briggs Institute. The Joanna Briggs Institute critical appraisal tools for use in JBI systematic reviews checklist for case reports. Adelaide: The Joanna Briggs Institute. [cited on Aug. 01, 2020]. Available from: <https://joannabriggs.org/research/critical-appraisal-tools.html>
- Toscano G, Palmerini F, Ravaglia S, Ruiz L, Invernizzi P, Cuzzoni MG. Guillain-Barré syndrome associated with SARS-CoV-2. *N Engl J Med*. 2020;382(26):2574-6. <https://doi.org/10.1056/NEJMc2009191>
- Padroni M, Mastrangelo V, Asioli GM, Pavolucci L, Abu-Rumeileh S, Piscaglia MG, et al. Guillain-Barré syndrome following COVID-19: new infection, old complication? *J Neurol*. 2020;267(7):1877-9. <https://doi.org/10.1007/s00415-020-09849-6>
- Alberti P, Beretta S, Piatti M, Karantzoulis A, Piatti ML, Santoro P, et al. Guillain-Barré syndrome related to COVID-19 infection. *Neurol Neuroimmunol Neuroinflamm*. 2020;7(4):e741. <https://doi.org/10.1212/NXI.0000000000000741>
- Assini A, Benedetti L, Di Maio S, Schirinzi E, Del Sette M. New clinical manifestation of COVID-19 related Guillain-Barré syndrome highly responsive to intravenous immunoglobulins: two Italian cases. *Neurol Sci*. 2020;41(7):1657-8. <https://doi.org/10.1007/s10072-020-04484-5>
- Ottaviani D, Boso F, Tranquillini E, Gapeni I, Pedrotti G, Cozzio S, et al. Early Guillain-Barré syndrome in coronavirus disease 2019 (COVID-19): a case report from an Italian COVID-hospital. *Neurol Sci*. 2020;41(6):1351-4. <https://doi.org/10.1007/s10072-020-04449-8>
- Riva N, Russo T, Falzone YM, Strollo M, Amadio S, Del Carro U, et al. Post-infectious Guillain-Barré syndrome related to SARS-CoV-2 infection: a case report. *J Neurol*. 2020;267(9):2492-4. <https://doi.org/10.1007/s00415-020-09907-z>
- Zhao H, Shen D, Zhou H, Lu J, Chen S. Guillain-Barré syndrome associated with SARS-CoV-2 infection: causality or coincidence? *Lancet Neurol*. 2020;19(5):383-4. [https://doi.org/10.1016/S1474-4422\(20\)30109-5](https://doi.org/10.1016/S1474-4422(20)30109-5)
- Virani A, Rabold E, Hanson T, Haag A, Elrufay R, Cheema T, et al. Guillain-Barré syndrome associated with SARS-CoV-2 infection. *IDCases*. 2020;20:e00771. <https://doi.org/10.1016/j.idcr.2020.e00771>
- Rana S, Lima AA, Chandra R, Valeriano J, Desai T, Freiberg W, et al. Novel coronavirus (COVID-19)-associated Guillain-Barré syndrome: case report. *J Clin Neuromuscul Dis*. 2020;21(4):240-2. <https://doi.org/10.1097/CND.0000000000000309>

19. Su XW, Palka SV, Rao RR, Chen FS, Brackney CR, Cambi F. SARS-CoV-2-associated Guillain-Barré syndrome with dysautonomia. *Muscle Nerve*. 2020;62(2):E48-9. <https://doi.org/10.1002/mus.26988>
20. Lantos JE, Strauss SB, Lin E. COVID-19-associated Miller Fisher syndrome: MRI findings. *AJNR Am J Neuroradiol*. 2020;41(7):1184-6. <https://doi.org/10.3174/ajnr.A6609>
21. Camdessanche JP, Morel J, Pozzetto B, Paul S, Tholance Y, Botelho-Nevers E. COVID-19 may induce Guillain-Barré syndrome. *Rev Neurol (Paris)*. 2020;176(6):516-8. <https://doi.org/10.1016/j.neurol.2020.04.003>
22. Arnaud S, Budowski C, Tin S, Degos B. Post SARS-CoV-2 Guillain-Barré syndrome. *Clin Neurophysiol*. 2020;131(7):1652-4. <https://doi.org/10.1016/j.clinph.2020.05.003>
23. Bigaut K, Mallaret M, Baloglu S, Nemoz B, Morand P, Baicry F, et al. Guillain-Barré syndrome related to SARS-CoV-2 infection. *Neurol Neuroimmunol Neuroinflamm*. 2020;7(5):e785. <https://doi.org/10.1212/NXI.0000000000000785>
24. El Otmani H, El Moutawakil B, Rafai MA, El Benna N, El Kettani C, Soussi M, et al. Covid-19 and Guillain-Barré syndrome: more than a coincidence! *Rev Neurol (Paris)*. 2020;176(6):518-9. <https://doi.org/10.1016/j.neurol.2020.04.007>
25. Juliao Caamaño DS, Alonso Beato R. Facial diplegia, a possible atypical variant of Guillain-Barré syndrome as a rare neurological complication of SARS-CoV-2. *J Clin Neurosci*. 2020;77:230-2. <https://doi.org/10.1016/j.jocn.2020.05.016>
26. Galán AV, Del Saz Saucedo P, Postigo FP, Paniagua EB. Guillain-Barré Syndrome associated with SARS-CoV-2 infection. *Neurologia*. 2020;35(4):268-9. <https://doi.org/10.1016/j.nrl.2020.04.007>
27. Marta-Enguita J, Rubio-Baines I, Gastón-Zubimendi I. Fatal Guillain-Barre syndrome after infection with SARS-CoV-2. *Neurologia*. 2020;35(4):268-9. <https://doi.org/10.1016/j.nrl.2020.04.007>
28. Molina AE, Martínez MM, Chueca PS, López AC, Val IS, Sanjuan-Villarreal TA. Guillain-Barré syndrome associated with SARS-CoV-2 infection. *Med Intensiva*. 2020;44(8):513-4. <https://doi.org/10.1016/j.medin.2020.04.015>
29. Sancho-Saldaña A, Lambea-Gil A, Liesa JLC, Caballo MRB, Garay MH, Celada DR, et al. Guillain-Barré syndrome associated with leptomeningeal enhancement following SARS-CoV-2 infection. *Clin Med (Lond)*. 2020;20(4):e93-4. <https://doi.org/10.7861/clinmed.2020-0213>
30. Reyes-Bueno JA, García-Trujillo L, Urbaneja P, Ciano-Petersen NL, Postigo-Pozo MJ, Martínez-Tomás C, et al. Miller-Fisher syndrome after SARS-CoV-2 infection. *Eur J Neurol*. 2020;27(9):1759-61. <https://doi.org/10.1111/ene.14383>
31. Chan JL, Ebadi H, Sarna JR. Guillain-Barré syndrome with facial diplegia related to SARS-CoV-2 infection. *Can J Neurol Sci*. 2020;47(6):852-4. <https://doi.org/10.1017/cjn.2020.106>
32. Coen M, Jeanson G, Culebras Almeida LA, Hübers A, Stierlin F, Najjar I, et al. Guillain-Barré syndrome as a complication of SARS-CoV-2 infection. *Brain Behav Immun*. 2020;87:111-2. <https://doi.org/10.1016/j.bbi.2020.04.074>
33. Lascano AM, Epiney JB, Coen M, Serratrice J, Bernard-Valnet R, Lalive PH, et al. SARS-CoV-2 and Guillain-Barré syndrome: AIDP variant with a favourable outcome. *Eur J Neurol*. 2020;27(9):1751-3. <https://doi.org/10.1111/ene.14368>
34. Helbok R, Beer R, Löscher W, Boesch S, Reindl M, Hornung R, et al. Guillain-Barré syndrome in a patient with antibodies against SARS-COV-2. *Eur J Neurol*. 2020;27(9):1754-6. <https://doi.org/10.1111/ene.14388>
35. Kilinc D, van de Pasch S, Doets AY, Jacobs BC, van Vliet J, Garszen MPJ. Guillain-Barré syndrome after SARS-CoV-2 infection. *Eur J Neurol*. 2020;27(9):1757-8. <https://doi.org/10.1111/ene.14398>
36. Oguz-Akarsu E, Ozpar R, Mirzayev H, Acet-Ozturk NA, Hakyemez B, Ediger D, et al. Guillain-Barré syndrome in a patient with minimal symptoms of COVID-19 infection. *Muscle Nerve*. 2020;62(3):E54-7. <https://doi.org/10.1002/mus.26992>
37. Scheidl E, Canseco DD, Hadji-Naumov A, Bereznai B. Guillain-Barré syndrome during SARS-CoV-2 pandemic: a case report and review of recent literature. *J Peripher Nerv Syst*. 2020;25(2):204-7. <https://doi.org/10.1111/jns.12382>

