

Síndrome do aqueduto vestibular alargado: uma causa de disacusia neurosensorial*****

The large vestibular aqueduct syndrome: a cause of neurosensory dysacusia

Daniela Polo Camargo da Silva*
Jair Cortez Montovani**
Danielle Tavares Oliveira***
Marisa Portes Fioravanti****
Ivanira Ayako Tamashiro*****

*Fonoaudióloga. Mestranda do Programa de Bases Gerais da Cirurgia da Faculdade de Medicina de Botucatu. Fonoaudióloga do Hospital das Clínicas da Faculdade de Medicina de Botucatu - Universidade do Estado de São Paulo. Endereço para correspondência: Departamento de Oftalmologia e Otorrinolaringologia - Faculdade de Medicina de Botucatu - Distrito de Rubião Júnior s/n. - SP - CEP 18618-970. (daniela-polo@fmb.unesp.br)

**Médico Otorrinolaringologista. Professor Titular da Faculdade de Medicina de Botucatu - Universidade do Estado de São Paulo.

*** Fonoaudióloga. Mestranda do Programa de Bases Gerais da Cirurgia da Faculdade de Medicina de Botucatu. Voluntária do Hospital das Clínicas da Faculdade de Medicina de Botucatu - Universidade do Estado de São Paulo.

****Fonoaudióloga. Mestre - Faculdade de Medicina de Botucatu - Universidade do Estado de São Paulo.

*****Trabalho Realizado na Faculdade de Medicina de Botucatu - Universidade Estadual Paulista.

Abstract

Background: the large vestibular aqueduct syndrome (LVAS) is characterized by the enlargement of the vestibular aqueduct associated with sensorineural hearing loss. The level of hearing loss varies and may be fluctuant, progressive or sudden. Vestibular symptoms may be present. The diagnosis is reached by imaging methods. Aim: To report an LVAS case. Method: a female infant was submitted to a computerized tomography of the ears and to audiologic tests. Results: enlargement of the vestibular aqueduct of more than 1.5mm and sensorineural hearing loss in the right ear were observed. Conclusion: with an early hearing evaluation it is possible to diagnose hearing loss, even in children were this loss is unilateral. Although the literature indicates that the diagnosis of LVAS occurs at a later age, in this case the etiologic diagnosis was enabled by computerized tomography.

Key Words: Vestibular Aqueduct; Malformation; Hearing; Hearing loss.

Resumo

Tema: a síndrome do aqueduto vestibular alargado (SAVA) é caracterizada pelo alargamento do aqueduto vestibular associada a disacusia. O grau da perda auditiva é variável, podendo ser flutuante, progressiva ou súbita. Sintomas vestibulares podem estar presentes. O diagnóstico é realizado por exames de imagem. Objetivo: relatar um caso de SAVA. Método: lactente, gênero feminino, realizou tomografia computadorizada de ouvidos e exames de audição. Resultado: constatou-se alargamento do aqueduto vestibular maior que 1,5mm de diâmetro e perda auditiva neurosensorial à direita. Conclusão: com a avaliação auditiva precoce é possível o diagnóstico da disacusia, mesmo em crianças com disacusias unilaterais. Embora a literatura consultada mostre que o diagnóstico da SAVA ocorra tardiamente, no presente caso, o diagnóstico etiológico foi possibilitado pela tomografia computadorizada.

Palavras-Chave: Aqueduto Vestibular; Malformação; Audição; Deficiência Auditiva.

Artigo de Estudo de Caso

Artigo Submetido a Avaliação por Pares

Conflito de Interesse: não

Recebido em 19.04.2007.
Revisado em 10.07.2007; 25.03.2008;
17.04.2008; 13.05.2008.
Aceito para Publicação em 13.05.2008.

Referenciar este material como:



Silva DPC, Montovani JC, Oliveira DT, Fioravanti MP, Tamashiro IA. The large vestibular aqueduct syndrome: a cause of neurosensory dysacusia (original title: Síndrome do aqueduto vestibular alargado: uma causa de disacusia neurosensorial). Pró-Fono Revista de Atualização Científica. 2008 abr-jun;20(2):133-5.

Introduction

The large vestibular aqueduct syndrome (LVAS) was first described by Valvassori e Clemis¹ in 1978. The LVAS is characterized by an enlargement of the vestibular aqueduct (EVA) associated with neurosensory dysacusia. The syndrome might be manifested from birth and present possible genetic etiology².

Described in 14% of the children with progressive neurosensory dysacusia, it is more frequent in females, presenting descendent audiometric configuration and it is generally bilateral³. The hearing fluctuation can occur in the beginning, with occasional vestibular symptoms⁴.

The distinguishment of the diagnosis with other illnesses is carried through by means of image examination.

The treatment is clinical or surgical. Lin et al.⁵ observed significant auditory improvement in individuals treated with corticoid, after recurrent episodes of sudden deafness. However, Willing et al.⁶ demonstrated that the ELA surgery does not provide significant benefit. However, other authors reported benefits in patients with LVAS and deafness acquired after language development, submitted to cochlear implantation⁷. Another possibility is to adapt hearing aids.

Objective

The aim of the present study was to report the case of an infant with unilateral dysacusia and LVAS.

Method

This research was submitted to the Committee of Ethics in Research of the FMB - UNESP, protocol 03/10/05 and legal responsible of the subject read and signed a consent form, allowing the spreading of the present results.

The subject was an infant, one year of age, female, without familiar antecedents of hypoacusia. She was born full-term, 3380g, without any neonatal intercurrance. The mother presented diagnosis of Diabetes Mellitus type II. Serological tests were negative.

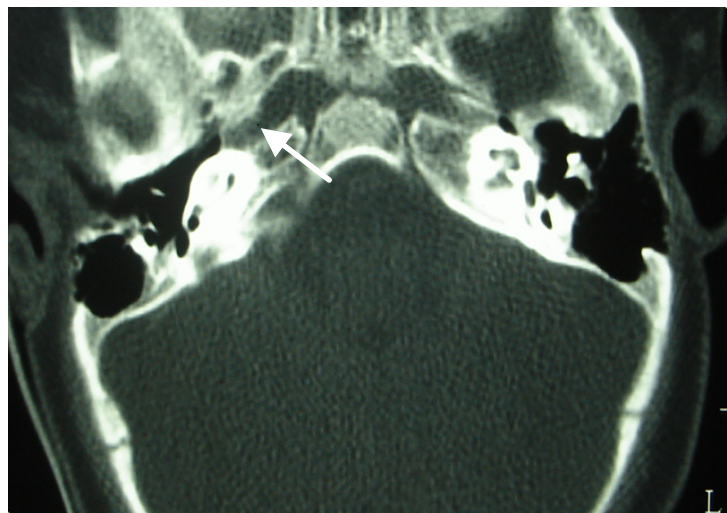
Results

Examinations of transient otoacoustic emissions (TOAE) and Auditory brainstem response (ABR) were carried through. At the first evaluation, the TOAE were present to the left and absent to the

right. At the second evaluation, the results were maintained, and a conductive alteration was discarded by the tympanometry. On the behavioral auditory evaluation, at seven months of age, response to sonorous localization to the left was evidenced even when the stimulation was to the right.

On the ABR, the electrophysiological threshold at 20 dBnHL to the left and the absence in 100 dBnHL to the right was observed. At one year of age, a computerized CAT scan (CT) of the temporal bone was carried through evidencing EVA only to the right, measuring 2,5mm (Figure 1).

FIGURE 1. CT of temporal bone showing EVA to the right.



Discussion

The vestibular aqueduct is an osseous canal that extends from the medial vestibule wall to an opening in the posterior surface of the squamous portion of the temporal bone. The duct and the endolymphatic sacs filled with endolympha course through this aqueduct. Some authors report that the EVA results from an abnormal development of the endolymphatic duct during the embryological period⁸.

The clinical findings of LVAS, mainly type and degree of the neurosensory dysacusia, are variable and for some even the correlation between the dysacusia and the size of EVA is discussible³. Sugiura et al.⁹ demonstrated with three-dimensional nuclear magnetic resonance that the deafness was caused by the reflux of the hyperosmolar fluid of the enlarged endolymphatic sac to the interior of the cochlea.

With regards to the etiology, some authors suggest autosomal recessive inheritance², explaining, as in our case, the lack of familial history for hypoacusia. Other authors had described mutation of gene SLC26A4 associating isolated deafness and LVAS¹⁰.

In the bilateral case the diagnosis is generally precocious given to the characteristics of the dysacusia, however, when the case is unilateral, such the dysacusia as the LVAS can remain without diagnosis as a result of the non-accomplishment of image examinations.

The treatment of this disorder consists of amplification, speech-language therapy and the prevention of cranium trauma. Occasionally, the cochlear implantation must be considered, mainly in the progressive cases.

Conclusion

Even so consulted literature reports that the diagnosis of LVAS is delayed in the majority of the cases, in the present case study, the etiological diagnosis was carried through precociously. The precocious diagnosis was made possible through the use of the CT in order to search for a unilateral dysacusia of unknown etiology.

References

1. Valvassori GE, Clemis JD. The large vestibular aqueduct syndrome. *Laryngoscope*. 1978;88:723-8.
2. Berrettini S, Forli F, Bogazzi F, Néri E, Salvatori L, Casani AP, Franceschini SS. Large vestibular aqueduct syndrome: audiological, radiological, clinical, and genetic features. *Am J Otolaryngol*. 2005;26:363-71.
3. Madden C, Halsted M, Benton C, Guinwald J, Choo D. Enlarged vestibular aqueduct syndrome in the pediatric population. *Otol Neurotol*. 2003;24:625-32.
4. Grimmer JF, Hedlund G. Vestibular symptoms in children with enlarged vestibular aqueduct anomaly. *Int J Pediatr Otorhinolaryngol*. 2007; 71: 275-82.
5. Lin CY, Lin SL, Kao CC, Wu JL. The remediation of hearing deterioration in children with large vestibular aqueduct syndrome. *Auris Nasus Larynx*. 2005;32:99-105.
6. Willing, DB, Martín MD, Miles BA, Oehler M, Schmalbrok P. Endolymphatic sac occlusion for the enlarged vestibular aqueduct syndrome. *Am J Otol*. 1998;19:145-51.
7. Loundon N, Rouillon I, Munier N, Marlin S, Roger G, Garabedian EN. Cochlear implantation in children with internal ear malformations. *Otol Neurotol*. 2005;26:668-73.
8. Ramirez-Camacho R, Ramón GBJ, Arellano B, Trinidad A. Familial isolated unilateral large vestibular aqueduct syndrome. *J Otorhinolaryngol Relat Spec*. 2003;65:45-8.
9. Sugiura M, Naganawa S, Sato E, Nakashima T. Visualization of a high protein concentration in the cochlea of a patient with a large endolymphatic duct and sac, using three-dimensional fluid-attenuated inversion recovery magnetic resonance imaging. *J Laryngol Otol*. 2006;120:1084-6.
10. Madden C, Halsted M, Meizen-Derr J, Bardo D, Boston M, Arjmand E, et al. The influence of mutations in the SLC26A4 gene on the temporal bone in a population with enlarged vestibular aqueduct. *Arch Otolaryngol Head Neck Surg*. 2007;133:162-8.