

Spitz nevus: a case report and the use of dermoscopy

Nevo de Spitz: relato de caso e dermatoscopia

Ana Maria Costa Pinheiro¹

Alessandro Guedes Amorim³

Horacio Friedman⁵

Gustavo Alonso Pereira²

Tatiana Cristina Nogueira Varella⁴

Resumo: O nevo de Spitz é uma lesão melanocítica benigna com características clínicas e histopatológicas semelhantes às do melanoma. Foi descrito em 1948, mas até hoje, ainda, existe grande controvérsia no seu diagnóstico e conduta. A utilização da dermatoscopia pode aumentar a sua acurácia diagnóstica. As características dermatoscópicas do nevo de Spitz incluem um padrão estelar (starburst), que é o mais frequente, seguido do padrão globular e do padrão atípico. O diagnóstico deve ser confirmado por exame histopatológico, principalmente, nos casos atípicos.

Palavras-chave: Dermatoscopia; Melanoma; Nevo de células epitelioides e fusiformes

Abstract: The Spitz nevus is a benign melanocytic lesion with clinical and histopathological features similar to those of melanoma. It was first described in 1948 but great controversy still remains today with respect to its diagnosis and management. The use of dermoscopy may increase diagnostic accuracy. In Spitz nevus, the most common dermoscopic finding is a starburst-like pattern, followed by globular and atypical patterns. Diagnosis must be confirmed by histopathology, particularly in atypical cases.

Keywords: Dermoscopy; Melanoma; Nevus, epithelioid and spindle cell

INTRODUCTION

The Spitz nevus is a benign melanocytic proliferation that was first described in 1948 by Sophie Spitz as a melanoma of childhood.¹ It was initially described as an erythematous papule or nodule of rapid growth, most commonly located on the extremities or on the face of children and adolescents. More recently, the Spitz nevus was found to present as a pigmented lesion in 71-92% of cases.^{2,3} This pigmentation, often intense and associated with the sudden appearance of the lesion, makes differential diagnosis with melanoma important. A diagnosis of Spitz nevus may be confirmed by dermoscopy, which shows three distinct patterns: a starburst pattern, a globular pattern and an atypical pattern.⁴ There is no consensus on the management of the Spitz nevus and removal of the lesion is often recommended in view of its clinical and dermoscopic similarity with melanoma.

Histopathologically, the Spitz nevus may be classified as junctional, intradermal and, in the majority of cases, compound. It is formed of large melanocytes, sometimes with nuclear atypia and abundant, rounded, oval, fusiform and polygonal cytoplasm with a fusiform and epithelioid appearance⁴, arranged in nests.^{5,6}

CASE REPORT

BISG, a two-year old girl with skin phototype 2, living in the Federal District of Brazil. According to her mother, the child had a "mark" that grew in size and bled spontaneously. Dermatological examination showed a brownish hyperchromic papule with blackened areas on the front of her right ankle (Figure 1). Dermoscopy showed a nonspecific global pattern with the presence of atypical striations associated with a

Received on 16.02.2010.

Approved by the Advisory Board and accepted for publication on 22.02.10.

* Study conducted at the Brasília Phototherapy and Dermoscopy Center, Brasília, DF, Brazil.

Conflict of interest: None / *Conflito de interesse: Nenhum*

Financial funding: None / *Suporte financeiro: Nenhum*

¹ Professor of Dermatology, University of Brasília. Coordinator of the Tumor Outpatient Clinic, Teaching Hospital, University of Brasília, Brasília, DF, Brazil.

² Dermatologist, São Paulo State Cancer Institute (ICESP), São Paulo, SP, Brazil.

³ Dermatologist, Dermatology Outpatient Clinic of Surgery and Tumors, Teaching Hospital, University of Brasília, Brasília, DF, Brazil.

⁴ Dermatologist, Outpatient Clinic of Phototherapy and Tumors, Teaching Hospital, University of Brasília, Brasília, DF, Brazil.

⁵ Professor, Head of the Pathology Department, Teaching Hospital, University of Brasília, Brasília, DF, Brazil.

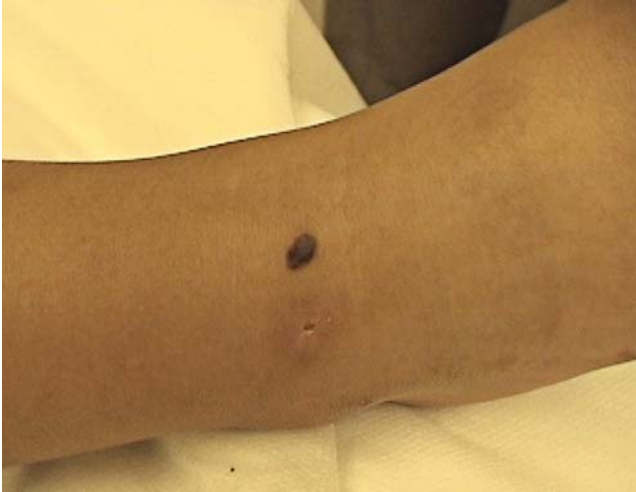

FIGURE 1: Clinical appearance. Hyperchromic papule of 8 mm in diameter

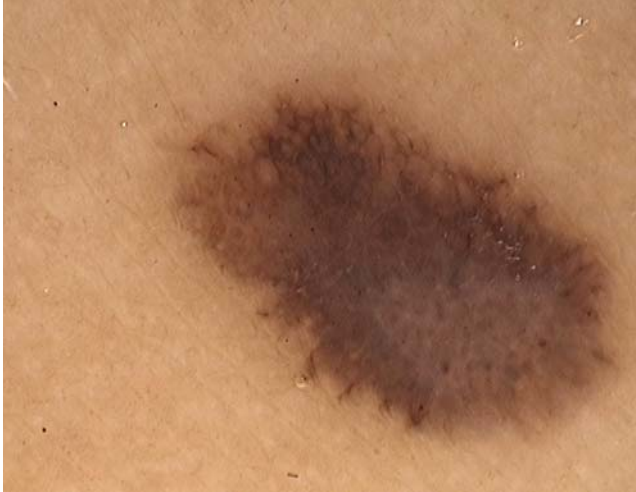

FIGURE 3: Dermoscopy, magnification 30x

negative pigment network at the center of the lesion and areas resembling a bluish-white veil (Figures 2 and 3). Histopathology showed nests of fusiform cells at the epidermal base and in the dermis (Figure 4).

DISCUSSION

The Spitz nevus is a rare, benign indolent lesion that is generally acquired and is brownish in color, flat or slightly raised and symmetrical.³ It is more commonly found in children or adolescents, rarely being found in elderly patients, a fact that suggests regression of the lesions with age.⁴ It often presents as a melanocytic lesion and the accuracy of its diagnosis may increase from 46% with the naked eye to 93% with the use of dermoscopy.⁷ Dermoscopy may reveal different patterns, the most common pattern specific to the Spitz nevus being a starburst-

like pattern, which occurs in 53% of cases. Its characteristics include the presence of multiple pigmented striations and/or large brown or black globules distributed symmetrically along the margins of the lesion, with a radiated appearance.⁴ The second most common pattern is the globular pattern, which occurs in 22% of cases and features the presence of regular, brownish or greyish central pigmentation and brownish globules along the margins. The third pattern described by Argenziano et al., which occurs in 25% of cases, is the atypical pattern, characterized by the irregular distribution of structures and colors, areas of diffuse, irregular pigmentation and a whitish-blue veil. It may also present radiated striations at the margins and a punctuated, vascular pattern.^{7,8}

Dermoscopy aids in the diagnosis of cases of Spitz nevus with a starburst or globular pattern; how-

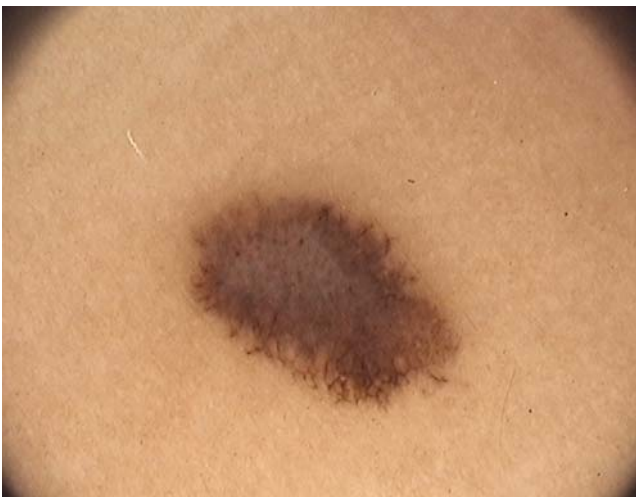

FIGURE 2: Dermoscopy, magnification 20x. Nonspecific global pattern with the presence of atypical striations (irregular distribution and dimensions), the presence of a negative pigment network at the center of the lesion and areas resembling a bluish-white veil

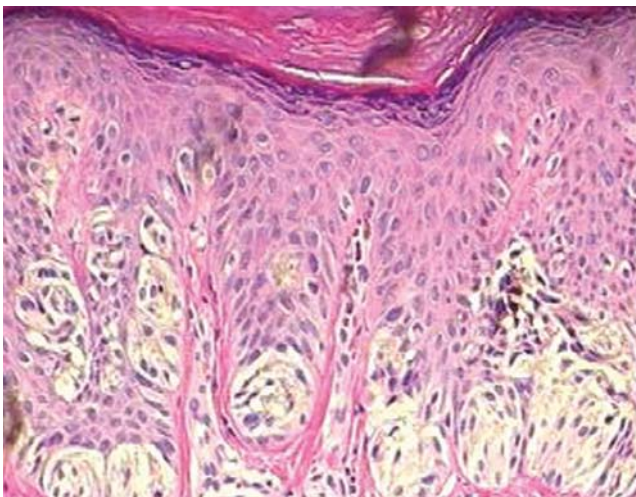


FIGURE 4: Histopathology. Nests of fusiform cells in the epidermal base and in the dermis (10x)

ever, in cases with the atypical pattern, diagnosis may be confused with melanoma.⁷ The dermoscopic patterns represent different morphological expressions that correspond to the phases of progression of the pigmented Spitz nevus. Follow-up studies of patients with Spitz nevus reveal different patterns at different

times in the progression of the condition, evolving from a starburst pattern to a reticular pattern.^{9,10}

Dermoscopy may result in a more precise diagnosis; however, a consensus on the management of the Spitz nevus can only be reached following more prolonged clinical and dermoscopic follow-up. □

REFERENCES

1. Spitz S. Melanomas of childhood. *Am J Pathol.* 1948;24:591-609.
2. Dal Pozzo V, Benelli C, Restano L. Clinical review of 247 case records of Spitz Nevus (epithelioid cell and/or spindle cell nevus). *Dermatology.* 1997;194:20-5.
3. Lyon V. The Spitz Nevus: review and update. *Clin Plast Surg.* 2010;37:21-33.
4. Argenziano G, Zalaudek I, Ferrara G, Hoffmann-Wellenhof R, Soyer H. Proposal of a new classification system for melanocytic naevi. *Brit J Dermatol.* 2007;157: 217-27.
5. Peris K, Ferrari A, Argenziano G, Soyer H, Chimenti, S. Dermoscopic Classification of Spitz/Reed Nevi *Clin in Dermatol.* 2002;20:259-62.
6. Requena C, Requena I, Kutzner H, Sanchez Yus E. Spitz nevus: a clinicalpathological study of 349 cases. *Am J Dermatopathol.* 2009;31:107-16.
7. Argenziano G, Scalvenzi M, Staibano S, Brunetti B, Piccolo D, Delfino M, et al. Dermoscopic pitfalls in differentiating pigmented Spitz naevi from cutaneous melanoma. *British J Dermatol.* 1999;141:788-91.
8. Rezze G, Sá B, Neves R. Atlas de dermatoscopia aplicada. São Paulo: Lemar; 2008.
9. Nino M, Brunetti B, Delfino S, Brunetti B, Panariello L, Russo D. Spitz Nevus: follow-Up Study of 8 cases of childhood Starburst type and proposal for Management. *Dermatology.* 2009;218:48-51.
10. Pizzicheta M, Argenziano G, Grandi G, Giacomi C, Trevisan G, Soyer H. Morphologic changes of a pigmented Spitz nevus assessed by dermoscopy. *J Am Acad Dermatol.* 2002;47:137-9.

MAILING ADDRESS / ENDEREÇO PARA CORRESPONDÊNCIA:
 Ana Maria Costa Pinheiro
 SQSW 300 - Bloco G - Ap. 606
 7067 3034 Brasília - DF, Brazil

How to cite this article/Como citar este artigo: Pinheiro AM, Pereira GA, Amorin AG, Varella TN, Friedman H. Spitz nevus: a case report and the use of dermoscopy. *An Bras Dermatol.* 2010;85(4):555-7.