

Hailey-Hailey disease treatment with Botulinum toxin type A *

Tratamento da doença de Hailey-Hailey com toxina botulínica tipo A

Giancarlo Rezende Bessa ¹
Ana Paula Manzoni ³
Renan Rangel Bonamigo ⁵

Thaís Corsetti Grazziotin ²
Magda Blessmann Weber ⁴

Abstract: Two sisters with recurrent lesions, one on axillae and other on the groin, and with limited response to classical treatments were treated with injections botulinum toxin type A. We observed marked improvement in the patient treated in the groin and complete remission in the patient treated in the axillae. It was possible to spare the use of systemic antibiotics and topical corticosteroids. The high cost is a restrictive factor to routine use and large studies are necessary to access efficacy and cost benefit profile. **Keywords:** Botulinum toxin type A; Combined modality therapy; Pemphigus, benign familial

Resumo: Duas irmãs com doença de Hailey-Hailey, com lesões recorrentes - uma em axilas e outra em região inguinal -, e resposta limitada aos tratamentos clássicos. Elas foram tratadas com aplicação de toxina botulínica tipo A.

Observamos que houve importante melhora na paciente tratada na região inguinal e remissão completa na paciente em cujas axilas sofreram tratamento. Além disso, foi possível poupar uso de antibióticos sistêmicos e corticoides tópicos. O alto custo é um fator restritivo para uso rotineiro e estudos maiores são necessários para definir eficácia e relação custo-benefício dessa intervenção.

Palavras-chave: Pênfigo familiar benigno; Terapia combinada; Toxina botulínica tipo A

INTRODUCTION

Hailey-Hailey disease (HHD) or familial chronic benign pemphigus, is a rare acantholytic disease, autosomal dominant clinically characterized by flaccid bullae and erosions on the intertriginous regions, mainly the axillary and inguinal. ¹ The rule is the occurrence of symmetrical bilateral eruption although there are reports of rare cases of mosaicism with unilateral lesions.² Mutations on the ATP2C1 gene that codifies a Ca²⁺ ATPase pump of the reticulum sarcoplasmatic leads to alterations in the intracellular signalling dependent on Ca²⁺, resulting in the loss of

cellular adhesion in the epidermis. To the loss of cohesion among the keratinocytes (acantholysis) it is added the effects of local factors such as friction, humidity, heat, microbic colonization and secondary infections, which are decisive in the induction of the appearing of lesions on the intertriginous regions. ¹ Diagnosis is clinical and histopathologic and has as its main differential diagnosis Darier disease. Currently the two illnesses are considered distinct entities, although there are reports of the occurrence of both disease (Darier and HHD) within the same family. ³

Received on 01.06.2009.

Approved by the Advisory Board and accepted for publication on 31.07.2009.

* Work carried out in the Dermatological service of the Federal University of Medical Sciences of Porto Alegre (UFCSPA) - Porto Alegre (RS), Brazil.

Conflict of interest: None / *Conflito de interesse: Nenhum*

Financial funding: None / *Suporte financeiro: Nenhum*

¹ Dermatologist. On going master course in Pathology run by the Federal University of Medical Sciences of Porto Alegre - Porto Alegre (RS), Brazil.

² Dermatologist. On going master course in Pathology run by the Federal University of Medical Sciences of Porto Alegre - Porto Alegre (RS), Brazil.

³ On going doctorate course in Pediatrics of the Federal University of Rio Grande do Sul. Invited professor in the specialization course of Dermatology of the Federal University of Medical Sciences of Porto Alegre - Porto Alegre (RS), Brazil.

⁴ Doctorate degree in Medical Sciences - Pediatrics from the Federal University of Rio Grande do Sul. Associate professor of Dermatology of the Federal University of Medical Sciences of Porto Alegre - Porto Alegre (RS), Brazil.

⁵ Doctorate degree in Medical Sciences from the Federal University of Rio Grande do Sul. Associate professor and head of the Dermatological Service of the Federal University of Medical Sciences of Porto Alegre - Porto Alegre (RS), Brazil.

HHD is traditionally treated with corticosteroids and topic and systemic antibiotics.⁴ The use of topic corticosteroids on the intertriginous areas, even for short periods, is associated to the risk of the occurrence of atrophy, streaks, and telangiectasias. Oral antibiotics are efficient because the infections potentiate the acantholysis and have important role in the exacerbation and persistence of the disease.¹ They might, however, lead to the appearing of bacterial resistance.⁵ More recently there have been described surgical methods such as the excision of the affected area and healing of the site by second intention, excision with graft⁶, dermoabrasion⁷ and ablation with CO₂⁸ or erbium:YAG⁹ laser. However, these treatments need post operative care for variable periods and might not be feasible with patients with dif-fused disease.

Botulinum toxin type A (BTA) is a protein that produces chemodenervation when it blocks the liberation of acetylcholine in nerve terminations. Originally it was used in the treatment of neurologic, ophthalmologic and cosmetic diseases for its action in the motor plaque with production of muscularis weakness. Currently, new uses for BTA have been proposed for its blocking action to the cholinergic stimulus in the post ganglial symphathetic innervation and reduction of the production of sweat by the eccrine glands. As such it has also been used for the treatment of palmar and axillary hyperhidrosis^{10,11} Heat and sweat are factors known to worsen the condition of patients suffering from HHD and frequently exacerbation occurs throughout the months of summer.

There are few reported cases about the use of BTA in the treatment of HHD in the international medical literature. It is generally used in association

with other therapeutic modalities in patients with severe disease or resistant to conventional treatment.^{12,13} It was reported, recently, an improvement in the disease with the isolated application of BTA comparable with its associated use of dermoabrasion and erbium:YAG laser.¹⁴

In the present report it is shown the use of BTA as an adjuvant therapy in two sisters HHD carriers with limited response to classical treatment

CASE REPORTS

Patient 1: 48 year-old woman with HHD confirmed histopathologically, undergoing topic and systemic treatment with corticoids and antibiotics for four years. Recurrent periods of exacerbation of the disease were reported especially throughout the summer. Clinical examination showed erythematous and pultaceous plaques, parallel rhagades, flaccid vesicles and bromhidrosis on the axillae, inframammary region and bilateral groin region (Picture 1). Throughout the first monitoring year, the patient presented temporary improvement with the systemic use of antibiotics such as trimethoprim/sulfamethoxazole and erythromycin and topic use of corticoids and clindamycin, as well as solutions and anti-septic soaps. The patient developed gastrointestinal intolerance to tetracycline and did not respond to limecycline (300mg/day for 60 days).

Patient 2: Woman, aged 65 years of age, described lesions in the intertriginous areas with pruritus and burning for more than 30 years. She had a histopathological report done 4 years before diagnosing HHD. It was reported the frequent use of betamethasone and gentamicin cream, without regular medical checking. The clinical examination

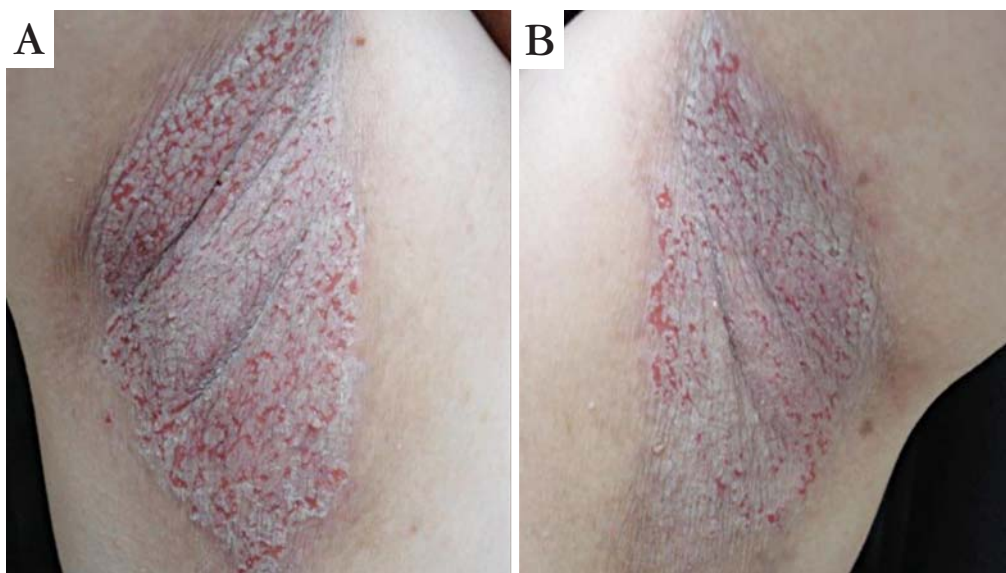


FIGURE 1: Recurrent lesions on the axillae of patient 1

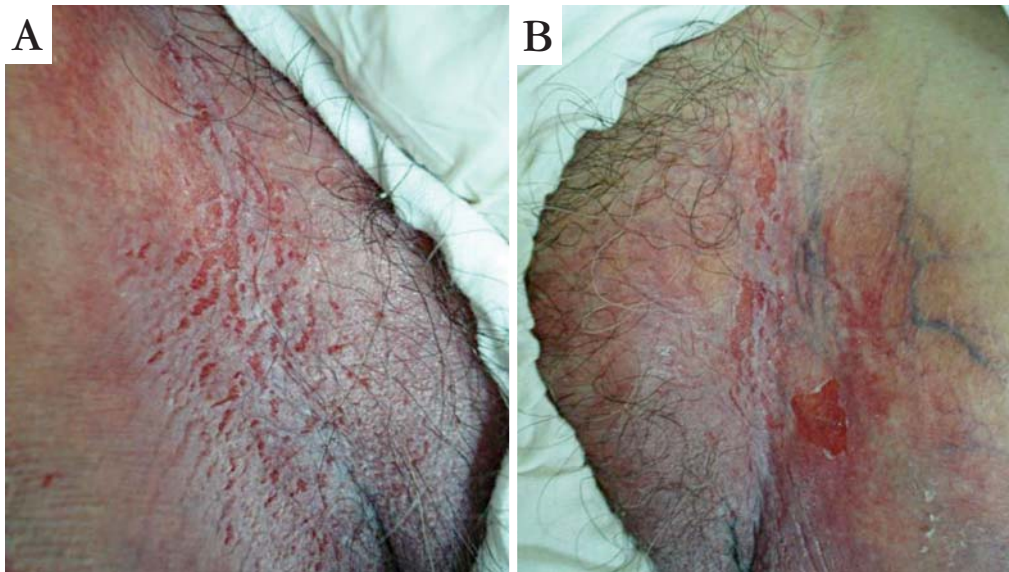


FIGURE 2: Persistent lesions on the groin region of patient 2

showed severe cutaneous atrophy in the inframammary region and bilateral axillary, erythematous and pultaceous plaques with rhagades on the groin regions (Picture 2). The patient was recommended to stop the use of topic corticosteroids and it was started a treatment using oral trimethoprim/sulfamethoxazole, antiperspiring and topic anti-septic. After three months, it was attempted the suspension of the oral antibiotic but the patient presented recidivation of the lesions and gastrointestinal intolerance to the use of tetracycline. It was decided to reintroduce trimethoprim/sulfamethoxazole. Due to the absence of a satisfactory response to the treatments, it was decided to proceed with the application (Picture 3) of 125U of BTA (bottle of 500U) in the right axilla of patient 1 and in the right groin region of patient 2 (50 marks of injection

with distance of 1 cm, application of 2,5U in each mark). After two weeks, the left axilla of patient 1 was treated and also the left groin region of patient 2 with the same dose of BTA (Picture 4). In a medical consultation 30 days after the second application, we observed an important improvement in the patient who had treated the groin region and complete remission in the patient who had treated the axillae. All medication, either topic or systemic, was interrupted. One month later, patient 1 was examined and reported the occurrence of lesions on the groin region, without occurrence on the axillae (Picture 5) and patient 2 presented axillary lesions and discreet residual erythematous area minimally pultaceous on the groin regions (Picture 6). It was prescribed topic clindamycin and local measures.

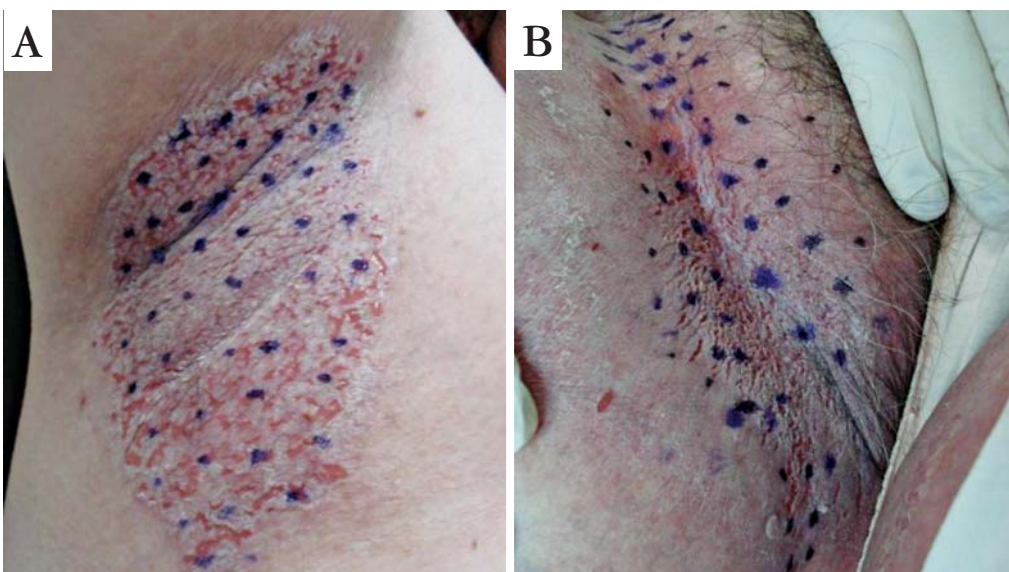


FIGURE 3: Marking for treatment with TBA on the right side lesions of both patients

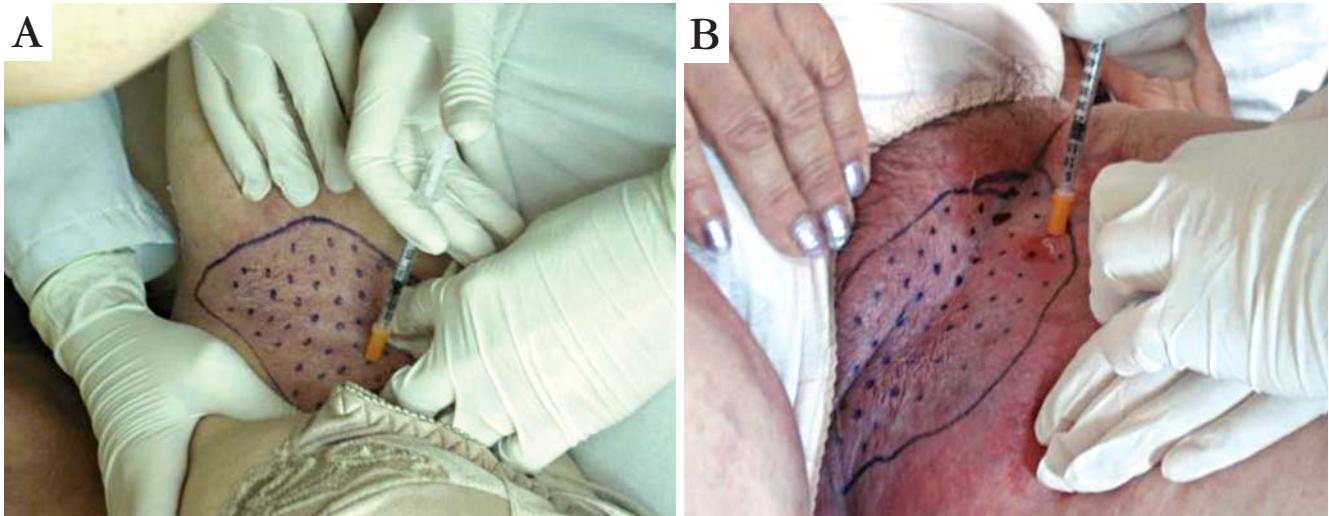


FIGURE 4: Application of TBA on the left side lesions of both patients

DISCUSSION

HHD lesions usually occur immediately after puberty, affecting mainly the active years of life of patients¹⁵ The painful sensation or pruritus on the intertriginous regions of erosion and the fetid smell of the HHD lesions affect enormously the quality of life of the patients. For this reason, it is recommended an intensive treatment including those patients with few lesions.¹⁶ Lapiere *et al.* reported the case of a patient who had had an applications of 50U of BTA in each axilla, having had complete remission of the lesions in these areas,¹² similarly to patient 1 who, during the summer, developed lesions on the groin region, site not treated with BTA, while it remained asymptomatic on the axillae.

Kang *et al.* reported the use of BTA on the groin region of a 48-year-old woman with severe disease, that was being treated with high doses of oral corticosteroid. In this case, it was used the initial dose of 100U of BTA on the right side with posterior complementation on the left side. The corticosteroid dose was reduced although it was not possible to stop completely with the medication showing the adjuvant role of BTA in patients with severe disease.¹³ As for patient 2 of the present report it was used a smaller dose which might have contributed for the non complete remission of the lesions. However, the patient presented discreet lesions, in spite of the intense heat and humidity of our climate, at that time.

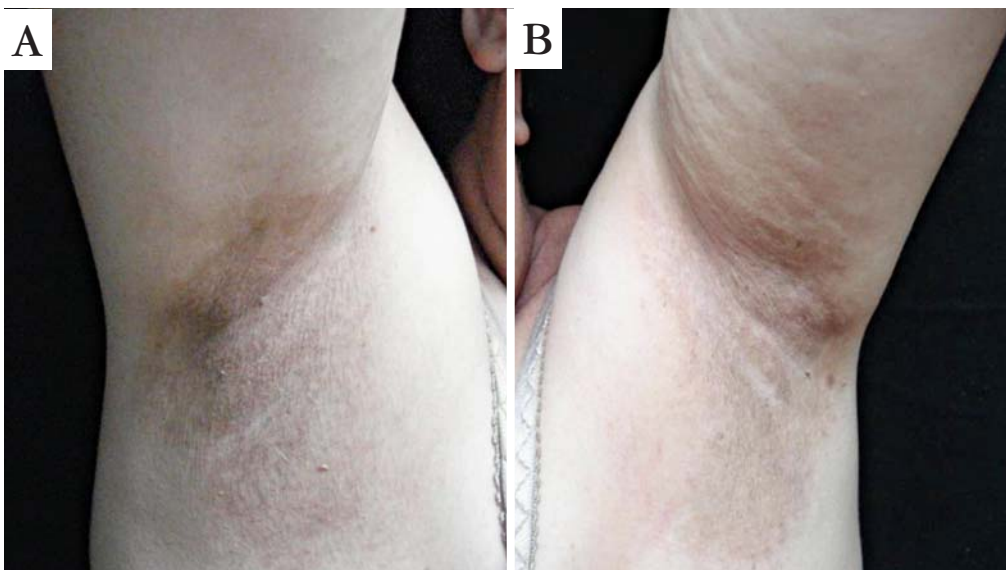

FIGURE 5: Residual hyperchromia in the patient who treated the axillae, two months after the application of TBA

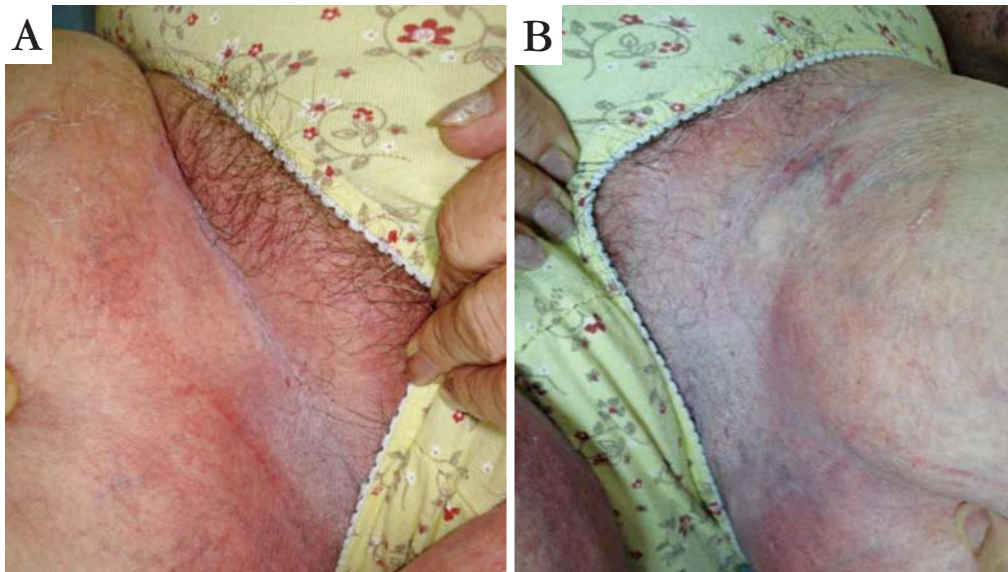


FIGURE 6: Minimal lesions of patient who treated the groin region, two months after the application of TBA

The postulate mechanism to explain the response to BTA in HHD is the reduction of sudoresis in response to the heat. The reduction of humidity probably acts in the reduction of the colonization by microorganisms (fungous and bacterial) involved in the exacerbations. It would also lead to less irritation stimulated by the natural rub in the areas of folds.¹²

We presented here two cases in which the BTA proved to be a good adjuvant in patients with recurrent disease and limited response to classical treat-

ment. Its use made it possible to save the use of systemic antibiotics and topic corticosteroids, which was particularly important for a patient that already presented advanced signs of cutaneous atrophy in the fold areas.

BTA is a therapy of easy application and good tolerance. The high cost is a limiting factor for its routine use and broader studies are necessary to define the efficacy of the treatment and its cost-benefit. □

ACKNOWLEDGEMENTS

We thank Galderma Laboratory for the donation of a bottle of Botulinum toxin used for treating the patients of this current study.

REFERENCES

1. Hohl D, Mauro T. Darier Disease and Hailey-Hailey Disease. In: Bologna JL, Jorizzo JL, Rapini RP, editors. *Dermatology*. 2nd ed. New Haven: 2008. Mosby; p. 791-800.
2. Silveira KS, Zac RI, Oliveira PJV, Neves DR, Barbosa VG, Café MEM. Caso para Diagnóstico. Mosaicismo na Doença de Hailey-Hailey. *An Bras Dermatol*. 2009;84:680-1.
3. Oliveira MP. Ocorrência familiar da doença de Darier e doença de Hailey-Hailey. *An Bras Dermatol*. 1980; 55:203-6.
4. Burge SM. Hailey-Hailey disease: the clinical features, response to treatment and prognosis. *Br J Dermatol*. 1992; 126:275-82.
5. Rossolini GM, Mantengoli E. Antimicrobial resistance in Europe and its potential impact on empirical therapy. *Clin Microbiol Infect*. 2008;14 Suppl 6:2-8.
6. Shons AR. Wide excision of perineal Hailey-Hailey disease with healing by secondary intention. *Br J Plast Surg*. 1989; 42:230-32.
7. Hamm H, Metze D, Brocker EB. Hailey-Hailey disease. Eradication by dermabrasion. *Arch Dermatol*. 1994; 130:1143-9.
8. Touma DJ, Krauss M, Feingold DS, Kaminer MS. Benign familial pemphigus (Hailey-Hailey disease). Treatment with the pulsed carbon dioxide laser. *Dermatol Surg*. 1998; 24:1411-4.
9. Beier C, Kaufmann R. Efficacy of erbium: YAG laser ablation in Darier disease and Hailey-Hailey disease. *Arch Dermatol*. 1999; 135:423-7.
10. Lowe NJ, Yamauchi PS, Lask GP, Patnaik R, Iyer S. Efficacy and safety of Botulinum toxin type A in the treatment of palmar hyperhidrosis: a double-blind, randomized, placebo-controlled study. *Dermatol Surg*. 2002;28:822-7.
11. Lowe PL, Cerdan-Sanz S, Lowe NJ. Botulinum toxin type A in the treatment of bilateral primary axillary hyperhidrosis: efficacy and duration with repeated treatments. *Dermatol Surg*. 2003;29:545-8.
12. Lapiere JC, Hirsh A, Gordon KB, Cook B, Montalvo A. Botulinum toxin type A for the treatment of axillary Hailey-Hailey disease. *Dermatol Surg*. 2000;26:371-4.
13. Kang NG, Yoon TJ, Kim TH. Botulinum toxin type A as an effective adjuvant therapy for Hailey-Hailey disease. *Dermatol Surg*. 2002;28:543.
14. Konrad H, Karamfilov T, Wöllina U. Intracutaneous botulinum toxin A versus ablative therapy of Hailey-Hailey disease--a case report. *J Cosmet Laser Ther*. 2001;3:181-4.
15. Fonseca APM, Fonseca WSM, Araújo RC. Bulose Crônica Benigna Familiar: a propósito de um caso. *An Bras Dermatol*. 1993;68:57-60.
16. Gisondi P, Sampogna F, Annessi G, Girolomoni G, Abeni D. Severe impairment of quality of life in Hailey-Hailey disease. *Acta Derm Venereol*. 2005;85:132-5.

MAILING ADDRESS / ENDEREÇO PARA CORRESPONDÊNCIA:

Giancarlo Rezende Bessa

Universidade Federal de Ciências da Saúde de Porto Alegre (UFCSPA).

Rua: Sarmiento Leite, 245. Centro.

90050-170 Porto Alegre - RS, Brazil.

Phone/Fax: 51 33039000 / 51 33038810

E-mail: gianmed@yahoo.com

How to cite this article/Como citar este artigo: Bessa GR, Grazziotin TC, Manzoni AP, Weber MB, Bonamigo RR. Treatment of Hailey-Hailey disease with Botulinum toxin type A. *An Bras Dermatol*. 2010;85(5):717-22.