

## Cerebriform sebaceous nevus: a rare presentation\*

Roberto Rheingantz da Cunha Filho<sup>1</sup>  
Nádia Aparecida Lorencette<sup>1</sup>

Aline Peluso Fezer<sup>1</sup>

DOI: <http://dx.doi.org/10.1590/abd1806-4841.20153433>

**Abstract:** A 13-year-old boy presented congenital, raised, yellowish colored plaques with fibroelastic consistency, which were velvety in appearance, alopecic, with clearly defined limits and sulci or well-marked meandering invaginations, a cerebriform appearance on the upper part of the right ear, accompanied by alopecia in the temporo-mandibular region-parietal. The lesion was asymptomatic. Histopathologic examination revealed acanthosis, hyperkeratosis, papillomatosis and follicular plugging in the epidermis. The upper dermis showed underdeveloped hair follicles with sebaceous glands, consistent with sebaceous nevus. There were no skeletal, cardiological, ophthalmological or neuropsychomotor changes; nor were there any records of relevant pathologies in the family history. The patient complained of his appearance, experiencing aesthetic and social issues. Following a diagnosis of cerebriform nevus sebaceous, complete excision was performed with excellent aesthetic results.

**Keywords:** Congenital abnormalities; Hamartoma; Nevus; Nevus, Sebaceous of Jadassohn; Scalp

### INTRODUCTION

Sebaceous nevus (SN) is an uncommon hamartoma that is often present at birth, affecting the head or neck, though usually the scalp. It is considered an epidermal nevus composed of sebaceous glands. The lesion presents as a yellow plaque with alopecia. The cerebriform variant is extremely rare and only 12 cases have been reported.<sup>1,2</sup> Furthermore, there have been no recorded instances in South America, thus justifying this case report. We describe a new case of lesions present in the parieto-temporal region.

### CASE REPORT

A 13-year-old boy presented raised, yellowish colored plaques with fibroelastic consistency, which were velvety in appearance, alopecic, with clearly defined limits and sulci or well-marked meandering invaginations and a cerebriform appearance on the upper part of the right ear (Figure 1). The lesions were asymptomatic congenital. There were no skeletal, cardiac or ophthalmic changes. *Neuropsychomotor development* was normal and CT of the skull revealed no abnormalities. Family history revealed no diseases that warranted attention.

The histopathologic examination revealed acanthosis, hyperkeratosis, papillomatosis and follicular plugging in the epidermis. Meanwhile, the upper dermis showed underdeveloped hair follicles with seba-

ceous glands, consistent with SN (Figure 2).

The patient complained of cosmetic disfigurement and wore long hair to disguise the lesion. He was willing to undergo a surgical excision. A complete excision surgery was performed with fairly favorable cosmetic results.

### DISCUSSION

Cerebriform skin lesions are unusual and can manifest as intradermal nevus, *cutis verticis gyrata*, *lipomatous nevus*, collagenoma, Proteus Syndrome, epidermal and sebaceous nevus. Most reports on cerebriform lesions include melanocytic nevus and Proteus Syndrome.<sup>1-3</sup> For accurate diagnosis and management, a biopsy followed by an anatomopathological examination is required. Our patient was diagnosed with SN, characterized by a very rare cerebriform appearance, macroscopically similar to a human brain due to the *numerous sulci and gyri*.

SN is also called organoid nevus as it presents similar structures to normal tissue without atypia or neoplastic behavior. Its etiology is still unknown. The most accepted theory involves mosaicism, which is formed by pluripotent stem cells between the 7th and 8th months of pregnancy. It remains unclear as to why the hamartoma assumes the cerebriform characteristic.<sup>1,3,4</sup>

Received on 06.02.2014

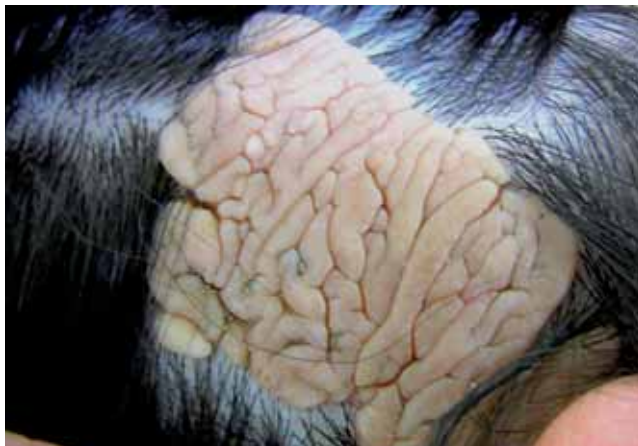Approved by the Advisory Board and accepted for publication on 24.02.2014

\* Work performed at the Universidade do Oeste de Santa Catarina (UNOESC) – Joaçaba (SC), Brazil.

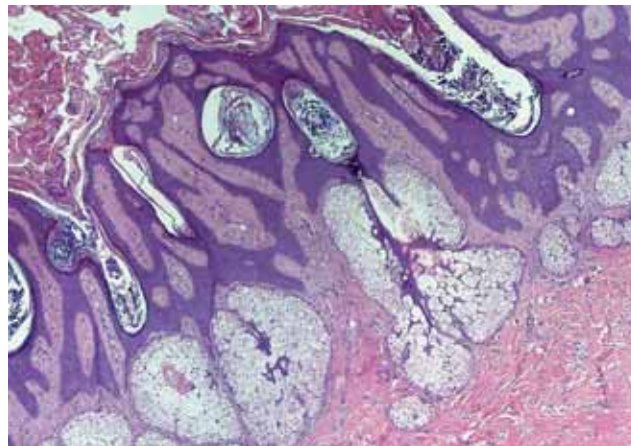
Financial Support: None.

Conflict of Interest: None.

<sup>1</sup> Universidade do Oeste de Santa Catarina (UNOESC) – Joaçaba (SC), Brazil.



**FIGURE 1:** Beige colour plaque with fibroelastic consistency, velvety in appearance, alopecic, with clearly defined limits and sulci or well-marked meandering invaginations and a cerebriform appearance on the upper part of the right ear



**FIGURE 2:** Acanthosis, hyperkeratosis, papillomatosis, follicular plugging in the epidermis. The upper dermis showed underdeveloped hair follicles with sebaceous glands. HE, 100x

The histology of SN may vary according to age. In the early years of life, the sebaceous glands are underdeveloped, which can make diagnosis difficult. There are hairy, incompletely differentiated structures. The second stage starts during puberty, when mature or nearly mature sebaceous glands and papillous hyperplasia appear.<sup>4,5</sup> The third stage occurs in adulthood and is characterized by the occurrence of appendage tumors, the most commonly found of which is syringocystadenoma *papilliferum* (8-19% of SN).

The risk of malignancy is probably less than 1%. Malignant tumors can include basal cell carcinoma, sebaceous or apocrine carcinoma, malignant eccrine poroma and, in rare cases, squamous cell carcinoma. Neurocutaneous syndrome may also occur, especially in extensive nevi, with changes such as epilepsy, mental retardation, or other neurological and skeletal abnormalities.<sup>4,5</sup>

Treatment should be indicated taking into account the cosmetic, psychological, and social impact,

as well as the possibility of malignancy. Generally, facial lesions should be excised at an early age before the development of verrucous and unsightly scars. Equally, SN on the scalp needs to be treated before adolescence, when there is an increased risk of developing secondary neoplasms.

In the present case, the lesion was extensive, entailing substantial cosmetic and social detriment. Hence, a complete excision was performed with excellent aesthetic results. If excision is discarded, regular clinical follow-up will be necessary as there is a risk of malignancy. □

#### Erratum

The title published in v.90 n.3 supl.1 was in Portuguese; the correct would be in English: Cerebriform sebaceous nevus: a rare presentation.

#### REFERENCES

1. Mahajan R, Dogra S, Kanwar AJ, Saikia UN, Agrawal S. Extensive cerebriform nevus sebaceus: An unusual presentation. *Dermatol Online J.* 2012;18:9.
2. Bomsztyk ED, Garzon MC, Ascherman JA. Postauricular cerebriform sebaceous nevus: case report and literature review. *Ann Plast Surg.* 2008;61:637-9.
3. Almeida Jr HL, Gonçalves NEL. Importância das lesões cutâneas no diagnóstico da síndrome de Proteus. *An Bras Dermatol.* 1999;74:597-9.
4. Ahmed TSS, Priore JD, Seykora. Tumores dos Apêndices Epidérmicos. In: Elder DE, Elenisitas R, Johnson Jr BL, Murphy GF and Xu X, editores. *Lever: Histopatologia da Pele.* Rio de Janeiro: Guanabara Koogan; 2009. p. 825-827.
5. McCalmont TH. Adnexal Neoplasms. In: Bologna JL, Jorizzo JL, Schaffer JV, editors. *Dermatology.* New Haven: Elsevier Saunders; 2012. p.1830-31.

#### MAILING ADDRESS:

Roberto Rheingantz da Cunha Filho  
Av Santa Terezinha 243, sala 302  
Edifício Centro Profissional  
Centro de Joaçaba  
89.600.000 - Joaçaba - SC  
Brazil  
E-mail: robertodermatologista@yahoo.com.br

**How to cite this article:** da Cunha Filho RR, Fezer AP, Lorencette NA. Cerebriform sebaceous nevus: a rare presentation. *An Bras Dermatol.* 2015;90 (3 Suppl 1):160-1.