

Ozay Gokoz: Data collection, analysis and interpretation; Approval of the final version of the manuscript.

Ibrahim Vargel: Data collection, analysis and interpretation; Approval of the final version of the manuscript.

Conflicts of interest





None declared.

References

1. Baliyan A, Dhingra H, Kumar M. Spiradenocylindroma of skin: a hybrid tumor. *Indian J Dermatopathol Diagn Dermatol*. 2018;5:66–8.
2. Michal M, Lamovec J, Mukensnabl P, Pizinger K. Spiradenocylindromas of the skin: tumors with morphological features of spiradenoma and cylindroma in the same lesion: report of 12 cases. *Pathol Int*. 1999;49:419–25.
3. Senarega A, Flores L, Innocenti AC, Parra V. Dermoscopic Features of Spiradenocylindroma. *Actas Dermosifiliogr*. 2019;110:604–6.
4. Lozano-Masdemont B, Polimón-Olabarrieta I, Marinero-Escobedo S, Gutiérrez-Pecharrómán A, Rodríguez-Lomba E. Rosettes in actinic keratosis and squamous cell carcinoma: distribution, asso-

ciation to other dermoscopic signs and description of the rosette pattern. *J Eur Acad Dermatol Venereol*. 2018;32:48–52.

5. Liebman TN, Rabinovitz HS, Dusza SW, Marghoob AA. White shiny structures: dermoscopic features revealed under polarized light. *J Eur Acad Dermatol Venereol*. 2012;26:1493–7.

Ecem Bostan ^{a,*}, Etkin Boynuyogun ^b,
Ozay Gokoz ^c, Ibrahim Vargel ^b

^a Cihanbeyli Public Hospital, Konya, Turkey

^b Department of Plastic and Reconstructive Surgery, Hacettepe University, Faculty of Medicine, Ankara, Turkey

^c Department of Pathology, Hacettepe University, Faculty of Medicine, Ankara, Turkey

* Corresponding author.

E-mail: bostanecem@gmail.com (E. Bostan).

Received 4 June 2021; accepted 4 July 2021;

Available online 2 January 2023

<https://doi.org/10.1016/j.abd.2021.07.011>

0365-0596/ © 2022 Sociedade Brasileira de Dermatologia.

Published by Elsevier España, S.L.U. This is an open access article under the CC BY license (<http://creativecommons.org/licenses/by/4.0/>).

Case for diagnosis. Vascular malformations, hemihypertrophy and macrodactyly: Proteus syndrome[☆]



Dear Editor,

A one-year-old boy had erythematous-violaceous macules on the left lower limb and trunk since birth (Fig. 1), associated with feet and chest deformities (Figs. 2 and 3), arteriovenous fistulas, and hypospadias. His personal and family history showed normal delivery at term, with no complications and non-consanguineous parents, with no reports of similar cases in the family, or hereditary diseases.

The investigation showed a normocephalic child, cervicothoracic scoliosis, posteriorly rotated ears, straight palpebral fissures, enlarged nasal base, retrognathia, flattened nasal philtrum, high palate, downturned oral commissures, and a palpable mass in the right epigastric region. He also had hemihypertrophy of limbs, enlarged hands and toes (symmetrically), and increased feet volume (left foot larger than the right one) with syndactyly between the second and the third and between the fourth and the fifth toes on the right. Vascular malformations were observed in the left lower limb, dorsum, thorax and genital region, besides linear epidermal nevus on the thorax. He had adequate neuropsychomotor development, without ocular alterations.

The genetic analysis disclosed a male karyotype (46, XY), with no qualitative or structural alterations.

What is your diagnosis?

- a Proteus syndrome
- b Maffucci Syndrome
- c Klippel-Trenaunay-Weber syndrome
- d Milroy Disease

Discussion

Named in 1983 by Wiedmann et al.,¹ Proteus syndrome is characterized by its polymorphism, variable phenotypic presentations, and mosaic distribution of lesions.² It presents immediately at birth and can affect any organ or system, commonly manifesting with skeletal malformations, overgrowth of connective and muscular tissues, nevi and vascular malformations. Neuropsychological development is usually preserved.³

The clinical manifestations are variable, with cases ranging from focal changes (isolated macrodactyly),⁴ to extensive dysmorphism that undergoes changes over time, making the diagnosis and therapeutic approach difficult.⁵ It is considered a rare condition, with an average incidence of 1/10,000,000 births, and less than 150 cases reported worldwide.⁶ It results from a mosaic mutation with somatic activation of the AKT1 oncogene (14q32.3), which is involved in cell-growth signaling pathways,⁷ in addition to being associated with a greater predisposition to neoplasms, deep vein thrombosis, and pulmonary embolism, with a risk of early death.⁸

[☆] Study conducted at the Department of Infectology, Dermatology, Diagnostic Imaging and Radiotherapy, Faculty of Medicine, Universidade Estadual Paulista, Botucatu, SP, Brazil.

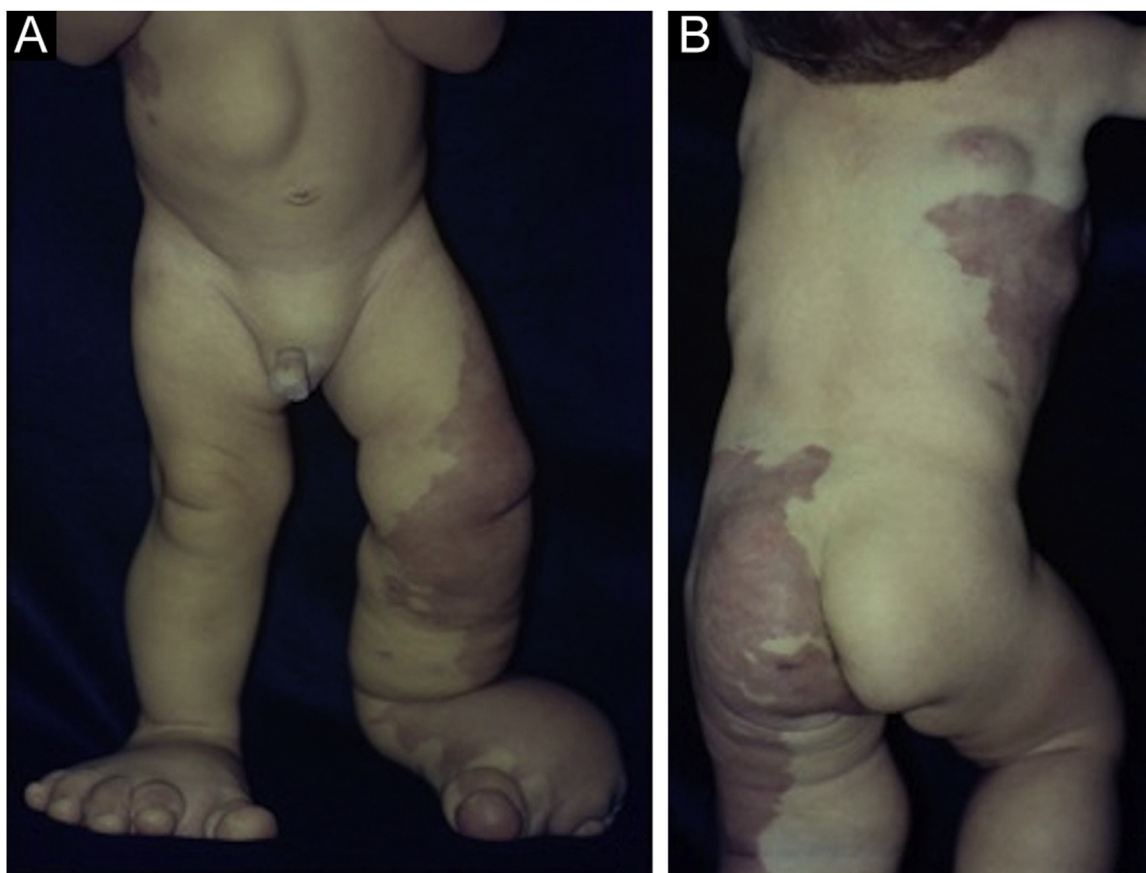


Figure 1 (A) Vascular malformations in the left lower limb. Leg and foot deformities and abdominal tumor. (B) Extensive vascular malformations in the thorax, hip and thighs with mosaic distribution.

Table 1 Main clinical characteristics of Proteus syndrome and its differential diagnoses

Diagnosis	Main clinical characteristics
Proteus Syndrome	<ul style="list-style-type: none"> [●]Asymmetrical growth of one or more limbs, pigmented nevi, cerebriform connective tissue nevi, vascular malformations, subcutaneous tumors, macrocephaly and visceromegaly ● Progressive evolution ● Facial alterations: dolichocephaly, elongated face, oblique palpebral fissures and/or ptosis, depressed nasal bridge, narrow or wide nostrils, open mouth at rest
Maffucci syndrome	[●]Cutaneous venous malformations, dyschondroplasia, enchondromas, lymphangiomas, <i>café au lait</i> spots
Klippel Trenaunay-Weber Syndrome	[●]Port-wine stains, vascular malformations, arteriovenous fistulas, hypertrophy of the affected limb (bone and/or tissue)
Milroy Disease	[●]Lymphedema since birth in lower limbs, varicose veins, limb hypertrophy

The diagnosis of Proteus syndrome is based on clinical criteria, making it necessary to differentiate from other hamartoses, such as Klippel-Trenaunay-Weber and Maffucci syndromes (Table 1).²

Treatment is individualized and multidisciplinary, requiring a psychological and psychomotor evaluation when orthopedic and vascular surgical approaches are indicated.

Oral inhibitors of the mTOR pathway (sirolimus 0.1 mg/kg/d) have been reported to be effective in preventing the growth of connective tissue hamartomas.⁹ The use of sirolimus has promising results in controlling symptoms related to limb overgrowth and tumors and should be started early to prevent disease progression.¹⁰ However, the use of this med-

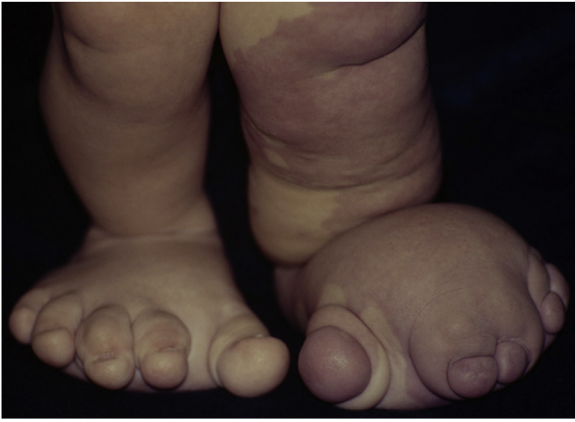

Figure 2 Details of foot deformities with asymmetric gigantism and syndactyly.

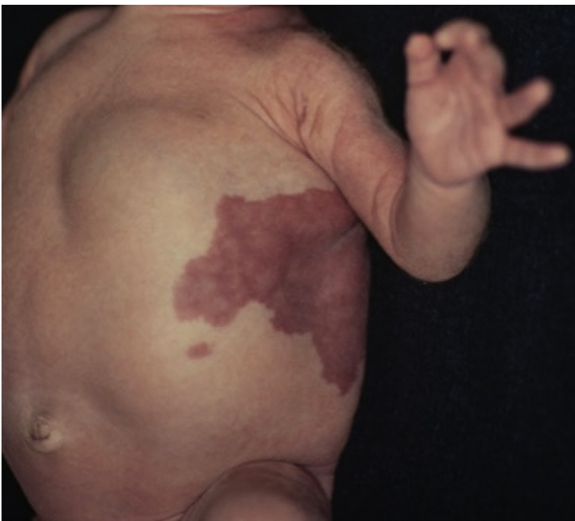

Figure 3 Detail of the vascular malformation in the thorax and thoracoabdominal tumor.

ication was not available at the time the present patient was evaluated.

This child was followed by the dermatology, pediatrics, psychology, vascular surgery and orthopedics teams for 12 years. At the age of ten, he experienced a worsening of the gigantism of the lower limbs, leading to difficulty in walking and weight loss. The multidisciplinary team decided for a transtibial amputation of the right lower limb and a transfemoral amputation of the left lower limb.

Financial support

None declared.

Authors' contributions

Bárbara Elias do Carmo Barbosa: Drafting of the manuscript; effective participation in research orientation; effective participation in propaedeutics; critical review of the literature; critical review of the manuscript; approval of the final version of the manuscript.

Melissa Almeida Corrêa Alfredo: Drafting of the manuscript; effective participation in research orientation; effective participation in propaedeutics; critical review of

the literature; critical review of the manuscript; approval of the final version of the manuscript.

Luciana Patrícia Fernandes Abbade: Drafting of the manuscript; effective participation in research orientation; effective participation in propaedeutics; critical review of the literature; critical review of the manuscript; approval of the final version of the manuscript.





Hélio Amante Miot: Drafting of the manuscript; effective participation in research orientation; effective participation in propaedeutics; critical review of the literature; critical review of the manuscript; approval of the final version of the manuscript.

Conflicts of interest

None declared.

References

1. Wiedemann HR, Burgio GR, Aldenhoff P, Kunze J, Kaufmann HJ, Schirg E. The proteus syndrome. *Eur J Pediatr.* 1983;140:5–12.
2. Capelato Rocha RC, Estrella MPS, do Amaral DM, Barbosa AM, Morgado de Abreu MAM. Proteus syndrome. *An Bras Dermatol.* 2017;92:717–20.
3. Biesecker L. The challenges of Proteus syndrome: Diagnosis and management. *Eur J Hum Genet.* 2006;14:1151–7.
4. de Almeida HL, Fiss RC, Happle R. Macroductyly with skin hypertrophy: a minimal form of the Proteus syndrome. *An Bras Dermatol.* 2011;86:557–9.
5. Pithadia DJ, Roman JW, Sapp JC, Biesecker LG, Darling TN. Hypertrichotic patches as a mosaic manifestation of Proteus syndrome. *J Am Acad Dermatol.* 2021;84:415–24.
6. Sapp JC, Hu L, Zhao J, Gruber A, Schwartz B, Ferrari D, et al. Quantifying survival in patients with Proteus syndrome. *Genet Med.* 2017;19:1376–9.
7. Lindhurst MJ, Sapp JC, Teer JK, Johnston JJ, Finn EM, Peters K, et al. A Mosaic Activating Mutation in AKT1 Associated with the Proteus Syndrome. *N Engl J Med.* 2011;365:611–9.
8. Zeng X, Wen X, Liang X, Wang L, Xu L. A case report of proteus syndrome (ps). *BMC Med Genet.* 2020;21:15.
9. Marsh DJ, Trahair TN, Martin JL, Chee WY, Walker J, Kirk EP, et al. Rapamycin treatment for a child with germline PTEN mutation. *Nat Clin Pract Oncol.* 2008;5:357–61.
10. Weibel L, Theiler M, Gnandt R, Neuhaus K, Han JS, Huber H, et al. Reduction of Disease Burden with Early Sirolimus Treatment in a Child with Proteus Syndrome. *JAMA Dermatol.* 2021;157:1514–6.

Bárbara Elias do Carmo Barbosa ,
Melissa de Almeida Corrêa Alfredo ,
Luciana Patrícia Fernandes Abbade ,
Hélio Amante Miot *

Department of Infectology, Dermatology, Diagnostic Imaging and Radiotherapy, Faculty of Medicine, Universidade Estadual Paulista, Botucatu, SP, Brazil

* Corresponding author.

E-mail: heliomiot@gmail.com (H.A. Miot).

Received 3 October 2021; accepted 8 November 2021;
Available online 6 February 2023

<https://doi.org/10.1016/j.abd.2021.11.012>

0365-0596/ © 2023 Sociedade Brasileira de Dermatologia.

Published by Elsevier España, S.L.U. This is an open access article under the CC BY license (<http://creativecommons.org/licenses/by/4.0/>).