



Complete resolution of generalized annular elastolytic giant cell granuloma with doxycycline[☆]

Dear Editor,

Annular Elastolytic Giant Cell Granuloma (AEGCG) is a rare granulomatous dermatosis with unclear etiology and physiopathology. Histopathological hallmarks are elastolysis and elastophagocytosis. The definitive mechanism that leads to damage of the elastic fibers has not yet been elucidated. Treatment is still challenging and the use of tetracyclines is controversial due to their potential phototoxicity. Herein, we present a case of generalized AEGCG that achieved a complete resolution after daily doxycycline and review the previous cases treated with tetracyclines.

An 88-year-old man with mild hypertension under treatment with lisinopril, visited our dermatology department presenting multiple erythematous and mild pruritic annular plaques with atrophic center located on the back, shoulders, posterior neck, and upper chest that had appeared over the last month (Fig. 1A). Initial differential diagnosis included subacute cutaneous lupus erythematosus, generalized granuloma annulare and annular psoriasis. A punch biopsy taken from an erythematous border showed a scattered dermal granulomatous infiltrate of multinucleated giant cells with elastophagocytosis consistent with the diagnosis of AEGCG (Fig. 2). Laboratory studies including complete blood cell

count, glucose levels, liver and renal function, and antinuclear antibodies were normal. Considering that the lesions were not photo-distributed, the little sun exposure by the patient, and the previously reported cases of AEGCG treated with tetracyclines, doxycycline 100 mg daily was initiated. After five months, complete resolution of the lesions and pruritus were observed (Fig. 1B). Nevertheless, the lesions rapidly recurred when doxycycline was discontinued but after its reintroduction, the patient experienced marked improvement during the following 12 months.

AEGCG was first described as actinic granuloma by O'Brien in 1975 to indicate the causal role of actinic damage triggering elastolysis and elastophagocytosis. However, photoaged skin with degenerative elastin changes is rarely associated with elastophagocytosis. Lesions of AEGCG are often located on nonexposed skin so other factors aside from heat and ultraviolet radiation should be considered. Several events may damage the elastic fibers and trigger the inflammatory response that leads to its phagocytosis. One of these triggers may be hyperglycemia in diabetes mellitus, as it has been frequently reported as a concomitant disease. Many other associations such as malignancies and inflammatory diseases have been described but probably the most common presentation is idiopathic.¹ Despite its benign course, AEGCG can take up to several years to resolve, lesions are usually extensive and may require different treatment modalities to prevent its progression. Anti-inflammatory and anti-granulomatous effects of tetracyclines are well known but they are not regarded as a convenient treatment due to their phototoxicity and the

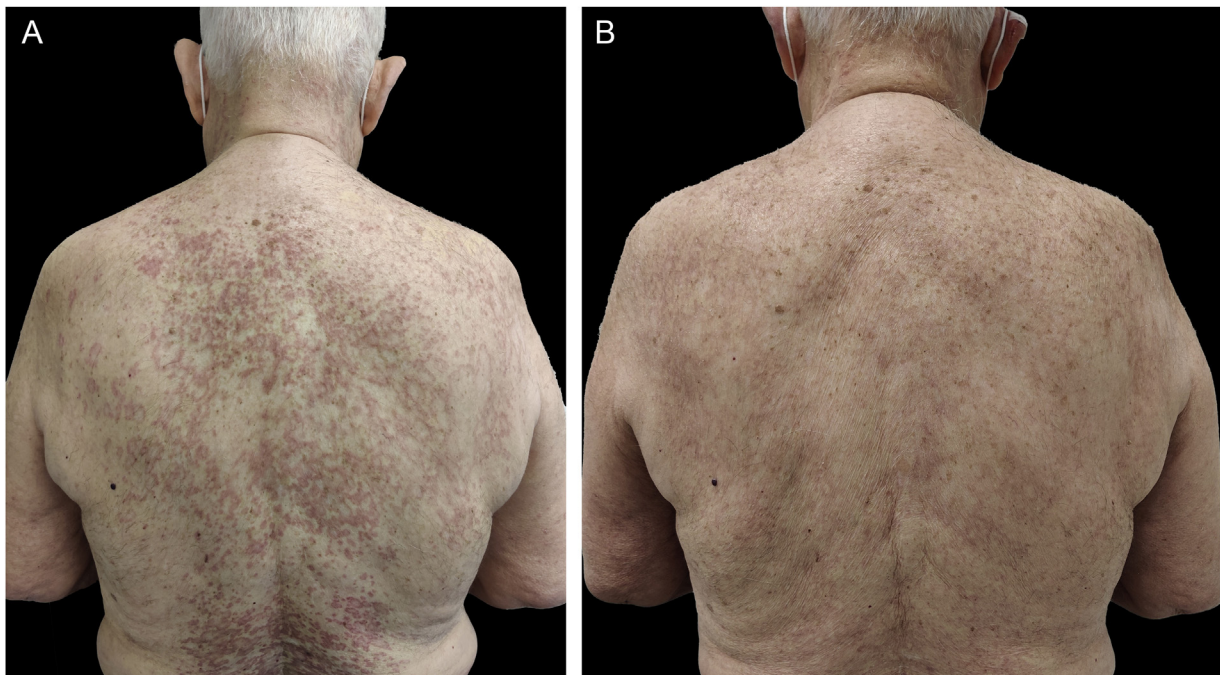


Figure 1 (A) Multiple erythematous annular plaques on the back and posterior neck at the initial visit. (B) Complete resolution of the lesions after 5 months under treatment with doxycycline 100 mg/day

[☆] Study conducted at the Hospital Universitari Sagrat Cor, Barcelona, Spain.

Table 1 Overview of published cases of AEGCG treated with tetracyclines

Article	Cases	Age	Sex	Comorbidities	Pattern and location	Previous treatments	Tetracycline and dose	Outcome
Nanbu et al. (2015) ³	1	46	Male	None	Solitary annular plaque on the temple	Topical corticosteroid	Minocycline 200 mg/day and 100 mg/day	Resolution after 11 weeks
Kabuto et al. (2017) ⁵	1	80	Male	Diabetes mellitus	Annular plaques on the posterior neck, back, chest, upper arms, wrists, dorsum of hands and thighs	Topical tacrolimus, topical corticosteroid and oral tranilast	Minocycline 200 mg/day and 100 mg/day	Resolution after 6 months
Jeha et al. (2020) ⁴	1	67	Male	Chronic kidney disease, diabetes mellitus and coronary artery disease	Annular plaques on ventral forearms and proximal thighs	Topical and intralesional corticosteroids	Doxycycline 200 mg/day	Resolution after 6 months
Current case	1	88	Male	Hypertension	Annular plaques on the whole back, shoulders, posterior neck, and upper chest	None	Doxycycline 100 mg/day	Resolution after 5 months

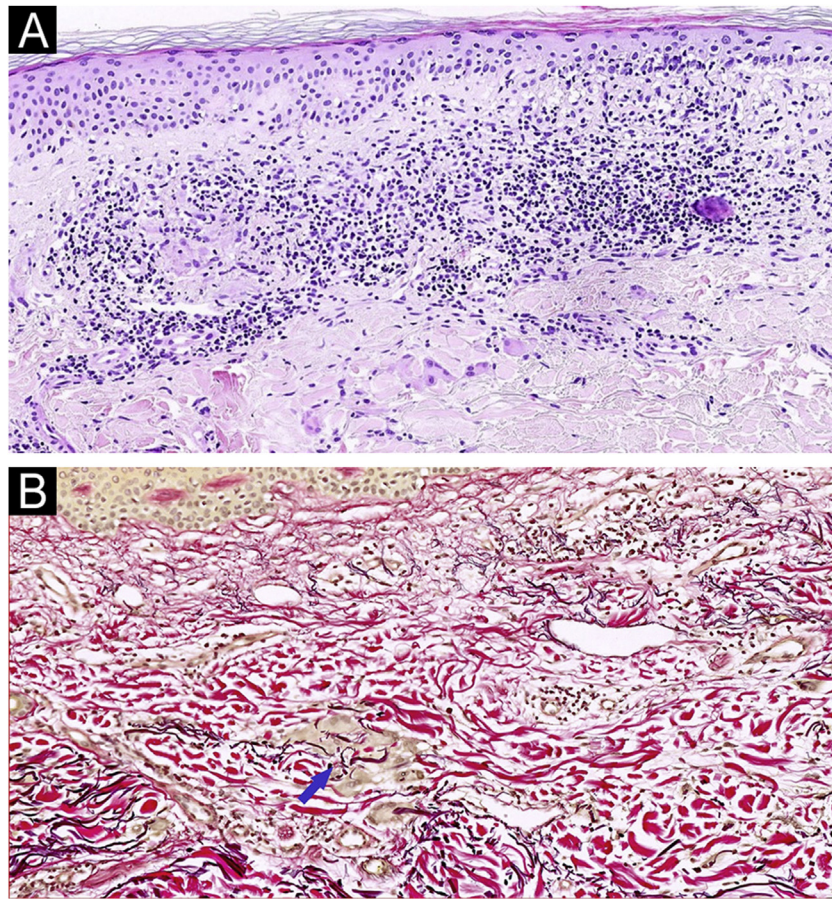


Figure 2 (A) Skin biopsy specimen showing a scattered dermal granulomatous infiltrate with phagocytosis of elastic fibers by multinucleated giant cells. (Hematoxylin & eosin, $\times 100$). (B) Elastophagocytosis by multinucleated giant cells demonstrated by elastic fibers stain. The blue arrow indicates the elastophagocytosis. (Verhoeff-Van Gieson; $\times 100$)

seldom reported risk to trigger AEGCG.² Nevertheless, tetracyclines have shown excellent outcomes with complete responses in both limited^{3,4} and generalized⁵ forms involving sun-exposed and nonexposed skin with no side effects. Table 1³⁻⁵ summarizes the main features of our patient and the three previously published cases of AEGCG treated with tetracyclines.

In conclusion, tetracyclines should be considered a safe first-line treatment for patients with extensive or generalized AEGCG or a second-line option for localized forms that do not respond to conventional topical treatments.

Financial support

None declared.

Authors' contributions

Marín-Piñero D: Approval of the final version of the manuscript; design and planning of the study; drafting and editing of the manuscript; collection, analysis, and interpretation of data; effective participation in research orientation; intellectual participation in the propaedeutic

and/or therapeutic conduct of the studied cases; critical review of the literature; critical review of the manuscript.

Sola-Casas MA: Approval of the final version of the manuscript; design and planning of the study; drafting and editing of the manuscript; effective participation in research orientation; intellectual participation in the propaedeutic and/or therapeutic conduct of the studied cases; critical review of the literature; critical review of the manuscript

Perez-Muñoz N: Approval of the final version of the manuscript; design and planning of the study; drafting and editing of the manuscript; effective participation in research orientation; intellectual participation in the propaedeutic and/or therapeutic conduct of the studied cases; critical review of the literature; critical review of the manuscript




Conflicts of interest

None declared.

References

1. Gutiérrez-González E, Pereiro M Jr, Toribio J. Elastolytic actinic giant cell granuloma. *Dermatol Clin.* 2015;33:331-41.

2. Lim DS, Triscott J. O'Brien's actinic granuloma in association with prolonged doxycycline phototoxicity. *Australas J Dermatol.* 2003;44:67–70.
3. Nanbu A, Sugiura K, Kono M, Muro Y, Akiyama M. Annular elastolytic giant cell granuloma successfully treated with minocycline hydrochloride. *Acta Derm Venereol.* 2015;95:756–7.
4. Jeha GM, Luckett KO, Kole L. Actinic granuloma responding to doxycycline. *JAAD Case Rep.* 2020;6:1132–4.
5. Kabuto M, Fujimoto N, Tanaka T. Generalized annular elastolytic giant cell granuloma successfully treated with the long-term use of minocycline hydrochloride. *Eur J Dermatol.* 2017;27:178–9.

Dídac Marín-Piñero ^{a,*}, M. Ángeles Sola-Casas ^a,
Noelia Perez-Muñoz ^b

^a Department of Dermatology, Hospital Universitari Sagrat Cor, Grupo Quirónsalud, Barcelona, Spain

^b Department of Pathology, Hospital Universitari General de Catalunya, Grupo Quirónsalud, Universitat internacional de Catalunya, Sant Cugat del Vallès, Barcelona, Spain

* Corresponding author.

E-mail: marindidac@gmail.com (D. Marín-Piñero).

Received 9 March 2022; accepted 1 May 2022

Available online 22 September 2023

<https://doi.org/10.1016/j.abd.2022.05.011>

0365-0596/ © 2023 Sociedade Brasileira de Dermatologia.

Published by Elsevier España, S.L.U. This is an open access article under the CC BY license (<http://creativecommons.org/licenses/by/4.0/>).

Pustular psoriasis triggered by therapy with atezolizumab and bevacizumab[☆]



Dear Editor,

Atezolizumab (ATZ) and Bevacizumab (BVZ) are used in the immunotherapy of some advanced tumors.^{1,2} ATZ is an immune checkpoint inhibitor, an antagonist of PDL1, expressed in tumor cells, which allows both the evasion of these cells from the immune system, as well as a reduction in T-cell proliferation.¹ This class of drugs can cause a variety of cutaneous adverse effects, mainly immune-mediated, such as neutrophilic, bullous dermatoses, and vitiligo.¹ BVZ is an anti-VEGF, therefore with anti-angiogenic action,² and cutaneous side effects such as exanthema and impaired tissue healing have also been described.³

The authors present a rare cutaneous adverse event, pustular psoriasis, after the start of the aforementioned therapeutic combination.

A 55-year-old male patient with a history of mild psoriasis controlled only with topical treatment, presented with erythematous, desquamative plaques with pustules on the dorsum of the hands, elbows, legs, and feet after starting ATZ + BVZ therapy for hepatocellular carcinoma. These medications were administered every 21 days and were infused on the same day. During follow-up, the infusion was withdrawn due to hospitalization because of clinical complications. At the time, there was rapid improvement of the lesions, in four weeks (Fig. 1A). After this period, the infusions were resumed, and psoriasis recurred (Fig. 1B), reinforcing the association between the skin condition and drug administration. The clinical presentation, in the form of erythematous-desquamative plaques with pustules (Figs. 2A and 2B) and pustule generalization to the trunk (Fig. 3A), associated with the anatomopathological examination (Fig. 3B) with intraepidermal pustules and psoriasiform infiltrate, allowed the diagnosis of psoriatic

exacerbation, in the form of pustular psoriasis, triggered by antineoplastic immunotherapy. The case constituted a therapeutic challenge since the patient had an hepatocellular carcinoma developed in cirrhosis due to chronic hepatitis C. Therefore, there was contraindication to the use of drugs such as acitretin and methotrexate, due to the risk of severe liver toxicity (including liver failure), and to the use of anti-TNF, considering the diagnosis of hepatitis C. Moreover, the patient developed arthritis in the interphalangeal joints, reinforcing the choice of systemic therapy. Considering these limitations, the authors chose an interleukin (IL-) inhibitor, ustekinumab (anti-IL 12/23).

Interestingly, there have been reports of psoriasis improvement with the use of BVZ.^{4,5} Vascular proliferation in the papillary dermis is known to play an important role in the pathophysiology of psoriasis.² Moreover, it was found that VEGF levels are higher in psoriatic lesions when compared to healthy skin. Plasma factor levels have also been observed to be higher in patients with psoriasis than in healthy ones.²

On the other hand, ATZ seems to induce a pro-inflammatory state, with a change in the cytokine profile, with an increase in TNF- α and IL-17 levels, which would explain psoriasis onset or worsening.¹ Skin changes due to ATZ usually occur within five to nine weeks after beginning therapy.¹ In the present case, psoriasis worsening occurred nine weeks after starting therapy, in agreement with the literature. Guttate, inverse, and palmoplantar presentations of psoriasis exacerbations have been described with the use of ATZ.¹ Therefore, the case highlights the combination related to the eruption, and also the unusual pustular presentation.

Financial support

None declared.

Authors' contributions

Mariani Magnus Andrade: Collection, analysis and interpretation of data; drafting and editing of the manuscript or critical review of important intellectual content; critical review of the literature.

[☆] Study conducted at the Hospital de Clínicas de Porto Alegre, Porto Alegre, RS, Brazil.