

# COMPARATIVE, PROSPECTIVE AND RANDOMIZED STUDY OF HUMERAL SHAFT FRACTURES REQUIRING SURGICAL TREATMENT: BRIDGING PLATE VERSUS LOCKED INTRAMEDULLARY NAIL (PRELIMINARY ANALYSIS)

EDUARDO BENEGAS<sup>1</sup>, DANIEL TASSETO AMÓDIO<sup>2</sup>, LUIZ FILIPE MARQUES CORREIA<sup>2</sup>, EDUARDO ANGELI MALAVOLTA<sup>2</sup>, LUCAS BUSNARDO RAMADAN<sup>2</sup>, ARNALDO AMADO FERREIRA NETO<sup>3</sup>, ARNALDO VALDIR ZUMIOTTI<sup>4</sup>.

## SUMMARY

The treatment of the great majority of humeral shaft fractures is conservative. Absolute indications (i.e., vascular injury) and relative indications (i.e., primary nervous palsy) for surgical treatment are well established by literature. The two most used methods for that purpose - the self-compression plate and the locked intramedullary nail - have already been com-

paratively studied. However, there are no studies comparing intramedullary nails to the bridging plate, therefore, this is the objective of the present study.

**Keywords:** Humeral fractures/ surgery; Bone plates; Bone nails; Comparative study.

**Citation:** Benegas E, Malavolta EA, Ramadan LB, Correia LFM, Amodio DT, Ferreira Neto AA et al. Comparative and randomized study of humeral shaft fractures requiring surgical treatment: bridging plate versus antegrade locked intramedullary nail. *Acta Ortop Bras.* [serial on the Internet]. 2007; 15(2):87-92. Available from URL: <http://www.scielo.br/aob>.

## INTRODUCTION

Humeral shaft fractures are, in most cases, treated conservatively<sup>(1-3)</sup>. However, there are absolute indications (multiple trauma, open fractures, pathological fractures, floating elbow, vascular injury, radial nerve palsy after closed reduction, pseudoarthrosis)<sup>(4-6)</sup> and relative indications (long spiral fractures, transverse fractures, brachial plexus injuries, primary nervous palsy, lack of ability to maintain reduction, neurological deficits such as Parkinson's disease, obesity and lack of cooperation due to alcohol and drugs abuse) for the surgical treatment of such fractures, and much has been discussed about the most suitable surgical alternative.

Among the most frequently used ones, the following are included: bridging plates (BP), self-compression plates, antegrade and retrograde intramedullary nails, either locked or not, and external fixators.

External fixators have mostly been used for shaft fractures with extensive soft parts injuries, bone loss or infection<sup>(7,8)</sup>.

Compression or self-compression plates, inserted by means of bloody reduction through wide access ports, are regarded as a good treatment approach; they enable a good fracture reduction and the use of absolute stability shows good results according to literature<sup>(9,10)</sup>.

However, complications resulting from this kind of treatment (pseudoarthrosis, infection), usually difficult to solve, have motivated a growing trend on orthopaedic surgery in general, which is to avoid any significant harm to fracture core, preserving its hematoma. Therefore, the use of the relative stability technique with locked intramedullary nails (LIN), both antegrade and retrograde<sup>(11)</sup>, has become increasingly frequent

when handling those fractures.

Retrograde nails have the advantage of not hurting the rotator cuff during its insertion; on the other hand, they impose a risk of intercondylar fracture of the distal humerus. There are studies comparing plates with absolute stability (compression) with locked intramedullary nails<sup>(12)</sup>, of relative stability, and the conclusions report that both are good methods for surgical treatment of humeral shaft fractures. Although no consensus exists concerning the benefit of nails to surgical time and bleeding, nails should also have the advantages of not hurting fracture core, less soft parts dissection, lower risk of radial nerve injury, but they would deliver a higher rate of postoperative shoulder pain (antegrade nails).

An additional treatment approach, which, similarly to external fixators and nails, also provides relative stability, is the bridging plate. Its surgical technique builds on proven surgical ports (Thompson and Henry), avoids radial nerve, and enables a good reduction and stabilization, in addition to avoid a large dissection near fracture core<sup>(13)</sup>.

Currently, there are no studies in literature comparing these two fixation methods with relative stability for humeral shaft fractures (LIN vs. BP), so this is the objective of this study.

## OVERALL OBJECTIVE

To compare patients submitted to surgical treatment using a bridging plate (Plate group) or locked intramedullary nail (Nail group) regarding the following variables of interest:

- Surgery time (in minutes);
- Time until bone union (in weeks);

Study developed at the Orthopaedics and Traumatology Institute, IOT/HC/FMUSP

Correspondences to: Eduardo Benegas - Rua: Dr. Ovídio Pires de Campos, 333 - 3o Andar, Fone/Fax: 11 3069-6655 - Email: [e.benegas@terra.com.br](mailto:e.benegas@terra.com.br)

1 - Assistant doctor, Shoulder and Elbow Group, Orthopaedics and Traumatology Institute HC/FMUSP (IOT/HC/FMUSP)

2 - Resident doctor, Shoulder and Elbow Group, IOT/HC/FMUSP

3 - Head of the Shoulder and Elbow Group, IOT/HC/FMUSP

4 - Chairman of the Department of Orthopaedics and Traumatology, HC/FMUSP

Received in: 09/20/06; approved in: 09/25/06

- Image enhancer use time (in seconds);
- Functional outcome 6 months after surgery: fair, good, or excellent, and;
- Functional outcome 1 year after surgery: fair, good, or excellent.

Additionally, we were interested in studying a potential influence of the fracture kind and patient's age on the relationship between study groups and surgery time and time for bone union. For image enhancer use time, we are interested in studying the influence of the fracture kind.

## MATERIALS AND METHODS

In total, 25 patients were assessed, and all considered cases were addressed and operated by the same team (75% of the cases by the leading surgeon) within a period comprehending January 2003 to June 2005.

The mean follow-up time was 21 months, ranging from 12 to 42 months.

Inclusion cases were humeral shaft fractures located at least 3.0 centimeters distal to humeral surgical neck and at least 5.0 centimeters proximal to olecranon. Inclusion criteria for surgery were: multiple trauma, humeral bilateral fracture, inability to keep an adequate reduction under conservative methods, and floating elbow. Exclusion criteria were: skeletal immaturity, pathological fractures secondary to neoplasia, history of previous humeral fracture, osteometabolic diseases, pregnancy, Gustillo open fractures 3B or 3C, concurrent spinal cord injury, injury associated to brachial plexus, radial nerve palsies, and refusal to take part of the randomized study.

From the 25 patients in the study, 12 suffered car or motorcycle accidents, 4 were trampling victims, 1 was a victim of aggression, and 1 was suffered a gun shot injury (GSI); 15 fractured the right humerus, 10 fractured the left one; 5 were smokers, and 6 were carriers of diseases at baseline, with 5 of these cases presenting systemic blood hypertension and 1 with asthma. No patient presented with diabetes mellitus or any other clinical co-morbidity except those they have reported at baseline.

Regarding associated injuries, we had 1 case of abdominal GSI (the same patient victim of GSI on humerus), 1 with a closed contralateral distal radius fracture, 1 closed ipsilateral ankle fracture, 1 contralateral glenohumeral dislocation, and 7 cases with multiple fractures, from which 2 presented with at least 1 fracture with open core. The remaining 13 did not present any further injuries.

The kind of implant was determined by means of random assignment, performed by an individual not belonging to the surgical team involved, totaling 14 bridging plates and 11 locked anterograde nails.

### The surgical technique employed for locating locked nails was the following:

Selection of the nail size by means of X-ray image of the contralateral humerus.

The patient is positioned in dorsal horizontal decubitus with a 10-cm diameter cushion under the medial parascapular region with the upper limb lying out of the table, and controlled by an assistant. A small anterolateral incision is performed by saber strike on the juxta-upper region to the larger humeral tuberosity, and dissection by planes until it is found.

The initial guide is passed through towards humeral shaft, with clinical control and by means of image enhancer. The non-milled nail is then introduced until it reaches fracture core and a bloodless reduction is made by traction and manipulation. The nail is introduced until humeral distal third is reached after correcting any occasional displacement. Blockage of an anteroposterior distal screw with free hand with the aid of an image enhancer, taking special care to avoid angular displacements and proximal blockage only for the steady screw with a proper guide<sup>(14)</sup>.

For the bridging plate technique, a 4.5-mm narrow DCP plate was employed, with preoperative planning made on vegetable paper. The patient is positioned in dorsal horizontal decubitus with a 10-cm diameter cushion under medial scapula edge. Similarly to the previous technique, the patient remains with free upper limb and helped by an assistant.

Initially, an anterolateral distal access port is performed. Dissection between brachial biceps and brachial muscles<sup>(5,15)</sup>. Divulsion between brachial muscles fibers. Identification of the anterior surface of the humeral shaft. An anterolateral proximal access port is achieved between major pectoral and deltoid muscles' insertion, with dissection up to humeral shaft. The plate is located and slid, which was previously measured on a contralateral X-ray image, from proximal to distal, with indirect reduction at fracture core aided by image enhancer. Correction of eventual displacements and fixation of the plate with screws, involving six proximal and six distal corticals.

No bone graft was used in none of the cases or in open fracture cases. Those fractures were properly washed and submitted to debridement according to service protocol.

All patients were submitted to a prophylactic antibiotic therapy (Kefazol) for 24 hours, except those 2 presenting with combined open fractures and the patient with humeral open fracture resulting from GSI, which followed a distinct protocol (Clindamicin + Gentamicin).

The patients were registered in our service and followed up according with the following protocol:

First postoperative day: hospital discharge with Velpeau-type immobilization and medication for postoperative pain control (should the patient experienced severe pain, leakage on surgical wound, wound dehiscence, fever, other surgical or clinical complications, or in case of any other contraindication for hospital discharge, such as endovenous antibiotic therapy due to open fractures, this time was extended until the patient was able to be discharged, and the standard protocol was followed with the patient hospitalized in our infirmary).

Seventh postoperative day: surgical wound assessment, immobilization removed, pain measured, and physical therapy started with passive movements intending to improve shoulder and elbow range of motion, and X-ray analysis of the humerus intending to check if any reduction loss or material failure occurred.

Fourteenth postoperative day: surgical wound assessment, stitches removed, pain and shoulder/ elbow range of motion measurement, and X-ray analysis of the humerus intending to check if any reduction loss or material failure occurred.

First postoperative month: surgical wound assessment, pain and shoulder/ elbow range of motion measurement, X-ray analysis of the humerus, and introduction of shoulder and elbow active movements.

Third postoperative month: Surgical wound assessment, pain

and shoulder/ elbow range of motion measurement, and X-ray analysis of the humerus.

Sixth postoperative month: pain and shoulder/ elbow range of motion and strength measurement, X-ray analysis of the humerus, and application of the assessment scale developed by UCLA (Annex 1).

Twelfth postoperative month: pain and shoulder/ elbow range of motion and strength measurement, X-ray analysis of the humerus, and application of the assessment scale developed by UCLA (Annex 1).

Twenty-fourth postoperative month: pain and shoulder/ elbow range of motion and strength measurement, X-ray analysis of the humerus, and application of the assessment scale developed by UCLA (Annex 1).

Thirty-sixth postoperative month: pain and shoulder/ elbow range of motion and strength measurement, X-ray analysis of the humerus, and application of the assessment scale developed by UCLA (Annex 1).

Surgical complications surveyed were: infection, reduction loss, and nervous injury. Union delay was considered as a union failure after 4 months of fracture. Pseudoarthrosis was considered as non-union after 6 months of the fracture.

For results analysis, the following factors were taken into account: surgery time, intraoperative image enhancer use time, number of hospital days postoperatively, perioperative or late postoperative complications occurrence or not, and union time or synthesis material failure. Range of motion, pain, functional capacity, strength, and patients' level of satisfaction were as-

essed according to the criteria described on UCLA protocol at 6, 12, 24, and 36 months postoperatively.

### Statistical analysis

The averages for surgery time, bone union time, and scopy use time for Nail and Plate groups were compared by means of the Student's t test. The test result was adjusted in cases of uneven variances between groups.

The associations between study groups and the variables fracture kind and functional outcome were assessed by using the Fisher's exact test.

It is worthy to highlight that, due to the small sample size, it was impossible to assess the influence of fracture kinds and patients' ages concurrently with the kind of material employed. Thus, the results presented in this paper should be considered as preliminary.

### RESULTS

In this study, measurements reported for 25 patients have been considered, with 14 belonging to the Nail group, and 11 to the Plate group. The Nail group is constituted of 90.9% of all male patients, but in the Plate group, this percentage is 64.3%.

The results were collected in our service, by means of interviews, physical tests and X-ray evaluation, as well as perioperative data noted on medical files.

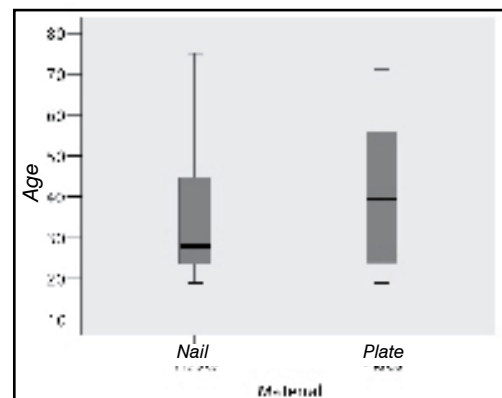
Humeral shaft fractures have been categorized according to the alphanumeric classification adopted by the AO Group, and, at X-ray evaluation, initial signs of fracture union, loosening, or synthesis material failure were observed.

Overall, the two groups presented similar percentages of type A, B or C fractures (Table 1) and the averages for age did not show significant differences (Table 2). Still regarding ages, the mean age for patients from Nail group was 36.4 years, ranging from 19 to 75 years. In the Plate group, that average was 42.2 years, ranging from 19 to 71 years. Figure 1 shows a boxplot-type graph for patients' ages according to the study group.

Group	Kind of Trauma			Total
	A	B	C	
Nail	5	5	1	11
	45,5%	45,5%	9,1%	100%
Plate	7	5	2	14
	50,0%	35,7%	14,3%	100%

Fisher's exact test:  $p > 0.99$

**Table 1** - Distribution of kind of trauma according to study group.



**Figure 1** - - Boxplot showing patients' ages according to study group.

ANNEX 1 UCLA evaluation criteria	
<b>1) Pain (1-10)</b>	<ul style="list-style-type: none"> <li>- no pain = 10 points</li> <li>- occasional and mild = 8 points</li> <li>- at heavy efforts = 6 points</li> <li>- at light efforts = 4 points</li> <li>- at rest, sporadic analgesic drugs use = 2 points</li> <li>- disabling, frequent analgesic drugs use = 1 point</li> </ul>
<b>2) Function (1-10)</b>	<ul style="list-style-type: none"> <li>- normal = 10 points</li> <li>- mild restriction, work above shoulder level = 8 points</li> <li>- home-related activities, drive, comb hair, dress = 6 points</li> <li>- mild home-related activities = 4 points</li> <li>- mild daily living activities = 2 points</li> <li>- disabled = 1 point</li> </ul>
<b>3) Range of flexion (0-5)</b>	<ul style="list-style-type: none"> <li>- 150 degrees or more = 5 points</li> <li>- 120 - 150 degrees = 4 points</li> <li>- 90 - 120 degrees = 3 points</li> <li>- 45 - 90 degrees = 2 points</li> <li>- 30 - 45 degrees = 1 point</li> <li>- less than 30 degrees = 0 point</li> </ul>
<b>4) Flexion strength (0-5)</b>	<ul style="list-style-type: none"> <li>- normal = 5 points</li> <li>- slightly = 4 points</li> <li>- overcomes gravity = 3 points</li> <li>- outlines some movements = 2 points</li> <li>- absence of strength = 0 point</li> </ul>
<b>5) Satisfaction (0-5)</b>	<ul style="list-style-type: none"> <li>- satisfied = 5 points</li> <li>- dissatisfied = 0 point</li> </ul>
<b>6) Ellman's Criteria :</b>	<ul style="list-style-type: none"> <li>a) 34 or 35 points = excellent</li> <li>b) 28 - 33 points = good</li> <li>c) 21 - 27 points = fair</li> <li>d) 0 - 20 points = poor</li> </ul>

	Group	Average	Stand. Deviation	Median	Minimum	Maximum	p value
Patients' ages (years)	Nail	36,4	18,0	28,0	19,0	75,0	0,422
	Plate	42,2	17,6	39,5	19,0	71,0	
Surgery time (minutes)	Nail	110,9	18,1	110,0	90,0	150,0	0,154
	Plate	101,4	14,1	100,0	80,0	120,0	
Union time (weeks)	Nail	9,6	2,8	12,0	6,0	12,0	0,879
	Plate	9,9	4,0	8,0	6,0	16,0	
Enhancer use time (seconds)	Nail	252,0	44,2	253,0	194,0	316,0	<0,001a
	Plate	96,0	15,7	93,0	74,0	125,0	

\* p value adjusted due to variance unevenness.

**Table 2** - Descriptive measurements for variables of interest according to study groups.

According to that graph and to the data listed on Table 2, we can notice that 50% of the patients are older than 28 years in the Nail group, and older than 40 in the Plate group.

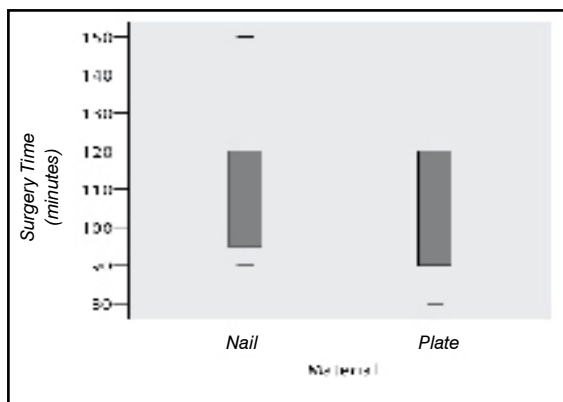
The mean surgery time was 101.4 minutes for patients submitted to plate insertion surgery, and 110.9 minutes for those submitted to nail insertion surgery. The analysis found no significant difference among these averages, with  $p=0.154$ .

On X-ray analysis, fracture union, synthesis material loosening or failure, and reduction loss were observed. The average times for the first bone union signs to be identified in Plate and Nail groups were very close, being, respectively, equal to 9.9 and 9.6 weeks. The analysis found no significant difference between these averages, with  $p=0.879$ . No implants loosening or failure were seen, as well as reduction loss.

Regarding image enhancer use time, we found that the patients from Plate group presented with the same values, ranging from 74 to 125 seconds, while in Nail group, these ranged from 194 to 316 seconds. The analysis suggested that the average image enhancer use time for the group submitted to plate insertion surgery (96 seconds) was significantly lower as compared to the group submitted to nail insertion surgery (252 seconds), with  $p<0.001$ .

Figures 2, 3 and 4 show boxplot-type graphs for surgery times, union times, and image enhancer use times, respectively, according to the study group. Those graphs help on visualizing the distribution of data.

The patients remained in hospital during 01 - 30 days, with the latter presenting with multiple bone fractures, including 2 open fractures requiring antibiotic therapy for an extended time, and the mean hospitalization time was 4.9 days. By as-



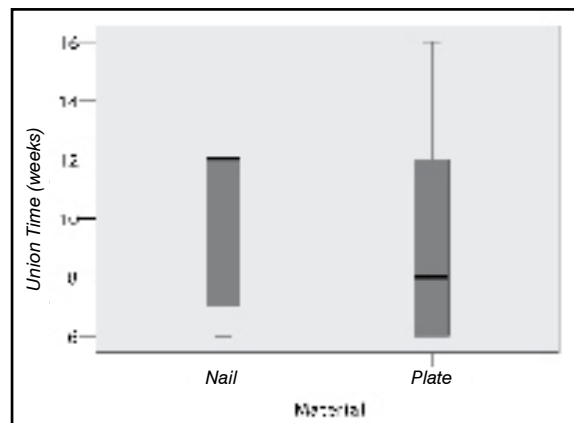
**Figure 2** - Boxplot showing measurements for surgery time according to study group.

sessing only patients presenting with no related injuries, the mean hospitalization time was 1.3 days. When comparing both groups, the plate group showed an average of 6.92 days against 2.36 for the nail group.

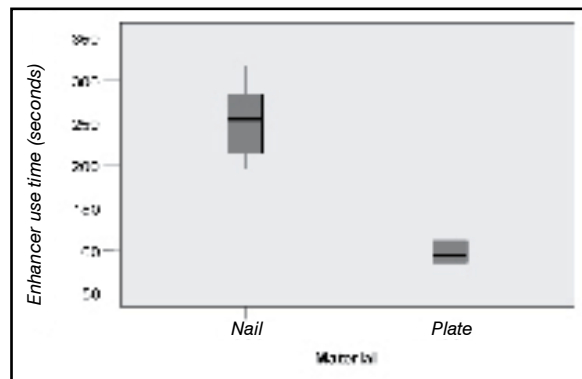
During the early evaluation in the first 7 days, no case showed surgical wound leakage or dehiscence. During the late postoperative period, none of the cases showed infection at surgical site. No postoperative complication case was found in both groups.

The analysis of the functional outcome after 6 months of surgery showed that the percentages for excellent, good or fair outcomes were similar between Nail and Plate groups ( $p>0.99$ ), as shown on Table 3.

The evaluation after 12 months of surgery shows no fair outcomes in the nail group, which demonstrates an improvement with time, and the percentage of excellent and good outcomes was similar for both groups (Table 4).



**Figure 3** - Boxplot showing measurements for union time according to study group.



**Figure 4** - Boxplot showing measurements for enhancer use time according to study group.

Group	Functional outcome after 6 months			Total
	Excellent	Good	Fair	
Nail	3 27,3%	7 63,6%	1 9,1%	11 100,0%
Plate	4 28,6%	8 57,1%	2 14,3%	14 100,0%

Fisher's exact test:  $p>0.99$ .

**Table 3** - Distribution of the functional outcome after 6 months of surgery according to the material employed.

Group	Functional outcome after 1 year			Total
	Excellent	Good	Fair	
Nail	4 36,4%	7 63,6%	0 0,0%	11 100,0%
Plate	5 35,7%	8 57,1%	1 7,2%	14 100,0%

Fisher's exact test:  $p > 0.99$ .

**Table 4** - Distribution of the functional outcome after 1 year of surgery according to the material employed.

## DISCUSSION

No union delay or pseudoarthrosis cases were seen in this study, however, there seems to be a correlation between fracture severity and union time.

Overall, table 5 shows that the average bone union time was longer for fractures kind A, B and C, in this order.

Moreover, by assessing the union time according to the kind of fracture and study group (Table 5 and Figure 5), we can notice that, for type-A fractures, both the patients submitted to nail insertion surgery and those submitted to plate insertion surgery showed bone union within 8 weeks in average. Nevertheless, for type-B fractures, the difference between groups' averages was 1 week and, for type-C fractures, this average difference was 4 weeks. Those results suggest that the time for bone union depends on the combination between fracture type and kind of material employed in the surgery. Due to the small sample size, it was not possible to statistically evaluate the effects of this combination in this study.

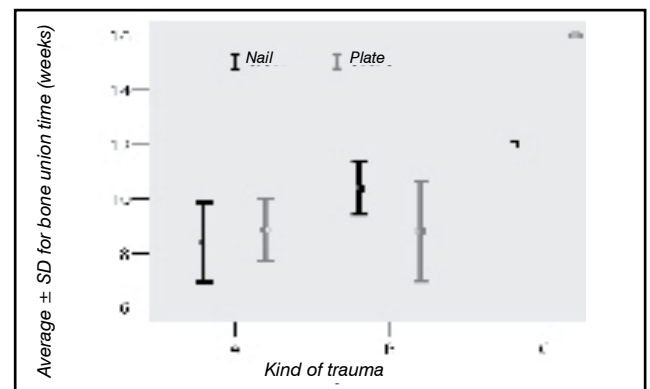
Nonetheless, the difference seen in union time between both groups showed no statistical significance, a result similar to some studies comparing the plate with the intramedullary nail<sup>(16)</sup>.

Regarding surgical procedure time, the major factor causing the average for plates to be slightly lower than in nails, in our opinion, was the longer time for performing distal blockage of the nail, this being the most difficult and time-consuming step. This fact is also reflected on a higher average for total image enhancer use time in the nails group, this being the only variable found in our study, with a significant difference between the groups.<sup>(12,14)</sup>

Regarding hospitalization time, the plate group was consti-

Kind of trauma	Average	N	Mean	Deviation	Standard	
					Minimum	Maximum
A	Nail	5	8,4	3,3	6	12
	Plate	7	8,9	3,0	6	12
	Total	12	8,7	3,0	6	12
B	Nail	5	10,4	2,2	8	12
	Plate	5	8,8	4,1	6	16
	Total	10	9,6	3,2	6	16
C	Nail	1	12,0	-	12	12
	Plate	2	16,0	0,0	16	16
	Total	3	14,7	2,3	12	16
Total	Nail	11	9,6	2,8	6	12
	Plate	14	9,9	4,0	6	16
	Total	25	9,8	3,5	6	16

**Table 5** - Descriptive measurements for union time (weeks) according to the kind of trauma and material employed.



**Figure 5** - Average  $\pm$  standard deviation for bone union times, according to study group and kind of trauma.

tuted of 4 patients presenting related injuries, which required 9, 12, 15 and 30 days in hospital, with no similarly matching case in the other group. Thus, it was not possible to perform a statistical analysis of such variable, once the groups were not homogeneous in this aspect.

An important data found in this study was that, at the end of 6 postoperative months, functional outcomes were similar for both groups. It is also worthy to remind that among the cases presenting a fair outcome according to UCLA classification, 2 presented with a strong emotional component accompanied by job-related problems, having scored negatively largely because of their dissatisfaction (both patients were able to raise arms above shoulders, were pain-free, and with normal strength); the remaining patient discontinued follow-up, and was back to rehabilitation protocol 4 months after surgery presenting a good outcome as early as 12 months.

At 12 months, functional outcomes remained similar to those seen 6 months before. Some patients showed functional improvement, but such variation was not significant. It is important to highlight that this is a preliminary analysis, and we believe that we can potentially see those changes with a higher level of fidelity in the future.

According to specific literature, the major complications in the surgical treatment of humeral shaft fractures are: infection, pseudoarthrosis/ union delay, radial nerve injury and vicious union, as well as pain and reduced range of motion of the shoulder resulting from rotator cuff injuries with anterograde locked intramedullary nails, and elbow stiffness with bridging plates. No postoperative complication case was found in both groups.

## CONCLUSION

In our study, we have been able to compare these two techniques, and the outcomes showed that there is no significant difference between them, except for intraoperative image enhancer use, with similarities regarding surgery time, union time, functional result and postoperative complication.

Thus, we can conclude that both are excellent methods for treating this kind of fracture, showing a short surgical procedure time, small incisions, brief hospitalization time, early limb motility, low complications rate, and great functional outcomes, suggesting that these techniques should be employed whenever indicated, leaving the selection of the method at surgeon's discretion, according to each individual's availability and familiarity.

---

## REFERENCES

1. Rüedi TP, Murphy WM. Principios AO do tratamento de fraturas. São Paulo: Artmed; 2002. p. 291-305.
2. Sarmiento A, Kinman PB, Galvin EG, Schmitt RH, Phillips JG. Functional bracing of fractures of the shaft of the humerus. *J Bone Joint Surg Am.* 1977; 59:596-601.
3. Sarmiento A, Latta L. Tratamento funcional incruento de las fracturas. Buenos Aires: Panamericana; 1987. p. 498-548.
4. Poigenfurst J. [Diaphyseal upper arm fractures]. *Zentralbl Chir.* 1972; 97:1643-50.
5. Ruedi T, Moshfegh A, Pfeiffer KM, Allgower M. Fresh fractures of the shaft of the humerus. Conservative or operative treatment? *Reconstr Surg Traumatol.* 1974; 14:65-74.
6. Holstein A, Lewis GB. Fractures of the humerus with radial nerve paralysis. *J Bone Joint Surg Am.* 1963; 45:1382-8.
7. Smith DK, Cooney WP. Extremal fixation of high-energy upper extremity injuries. *J Orthop Trauma.* 1990; 4:7-18.
8. Zinman C, Norman D, Hamoud K, Reis ND. External fixation for severe open fractures of the humerus caused by missiles. *J Orthop Trauma.* 1997; 11:536-9.
9. Chen AL, Joseph TN, Wolinsky PR, Tejwani NC, Kummer FJ, Egol KA et al. Fixation stability of comminuted humeral shaft fractures: locked intramedullary nailing versus plate fixation. *J Trauma.* 2002; 53:733-7.
10. Modabber MR, Jupiter JB. Operative management of diaphyseal fractures of the humerus. Plate versus nail. *Clin Orthop Relat Res.* 1998; (347):93-104.
11. Rommens PM, Verbroggen J, Broos PL. Retrograde locked nail of humeral shaft fractures. A review of 39 patients. *J Bone Joint Surg Br.* 1995; 77:84-9.
12. McCormack RG, Brien D, Buckley RE, Powell J, Schemitsch EH. Fixation of fractures of the humerus by dynamic compression plate or intramedullary nail. *J Bone Joint Surg Br.* 2000; 82:336-9.
13. Livani B, Belangero WD. Bridging plate osteosynthesis of humeral shaft fractures. *Injury* 2004; 35:587-95.
14. Rommens PM, Blum J. Internal fixation by nailing of humeral shaft fractures. In: *Surgical techniques in orthopaedics and traumatology.* Paris: Elsevier SAS; 2000.
15. Hoppenfeld S, deBoer P. *Vias de acesso anatômico.* São Paulo: Manole; 1990. p.47-75.
16. Chapman JR, Henley MB, Agel J, Benca PJ. Randomized prospective study of humeral shaft fracture fixation: intramedullary nails versus plates. *J Orthop Trauma.* 2000; 14:162-6