

ISOLATED LESIONS OF THE SUBSCAPULARIS TENDON

SERGIO LUIZ CHECCHIA, ALBERTO NAOKI MIYAZAKI, MARCELO FREGONEZE, PEDRO DONEUX DOS SANTOS, LUCIANA ANDRADE SILVA, RODRIGO TORMIN ORTIZ, FERNANDO IGE KUSABARA, TATIANA BATALHA CUNHA DOS SANTOS

ABSTRACT

Objectives: To evaluate the results of surgically treated patients with isolated subscapularis tendon injuries. **Patients and Methods:** Twelve patients with isolated tears of the subscapularis muscle tendon surgically treated between June 1987 and April 2005 were evaluated. Ten patients had traumatic injuries. Eight patients were males and four females. The duration of preoperative pain ranged from three days to 72 months. Seven patients were submitted to arthroscopic procedures and five to open surgical ones. Seven had complete tendon tears while five showed partial injuries. **Results:** The mean range of motion of the patients has improved from pre-

operative to final evaluation from 135° to 150° of forward lifting, from 60° to 50° of lateral rotation, and from T12 to T9 for medial rotation. Six patients returned to their pre-injury level of sports activity. Using the UCLA score, 11 patients showed excellent or good results. 33.3% of the cases were associated to injuries of the long head of the brachial biceps. **Conclusion:** Isolated tears of the subscapularis tendon addressed with surgery lead to good outcomes and patient satisfaction.

Keywords: Shoulder. Range of articular joint motion. Tendon injuries. Surgery.

Citation: Sergio Luiz Checchia, Alberto Naoki Miyazaki, Marcelo Fregoneze, Pedro Doneux dos Santos, Luciana Andrade Silva, Rodrigo Tormin Ortiz, Fernando Ige Kusabara, Tatiana Batalha Cunha dos Santos. *Isolated lesions of the subscapularis tendon. Acta Ortop Bras. [online]. 2009; 17(1):26-30. Available from URL: <http://www.scielo.br/aoob>.*

INTRODUCTION

Rotator cuff contributes to shoulder stabilization through mechanisms such as: passive muscle tension, joint forces reactive to compression, upper limb proprioception, and forces between paired muscle groups. In this role, the subscapularis muscle is very important as a both dynamic and passive stabilizer of the shoulder.¹

Ruptures involving the subscapularis muscle tendon alone are regarded as relatively uncommon and seldom diagnosed.^{2,3} This kind of injury is usually associated to other shoulder conditions, such as the instability of the tendon of the brachial biceps muscle's long head, tubercle fractures, shoulder dislocations, extensive injuries on the rotator cuff and rotator cuff arthropathy.³ Typical, partial or full injuries of the subscapularis muscle tendon have been attributed to complications of the shoulder traumatic lesion, differently from more common injuries compromising tendons of supra- and infra-spinal muscles, which are associated to a degenerative process on tendons and to the subacromial impact present in patients older than 40 years.^{2,4}

Diagnosing an isolated injury of subscapularis muscle tendon may be difficult and left unnoticed during physical examination. Rupture has been associated to pain, increased passive lateral rotation, reduced strength for medial rotation, inability to drive

hand away from the chest with the upper limb extended and medially rotated, subdislocation and recurrent dislocation of the shoulder.¹ Magnetic resonance, particularly when performed with intra-joint magnetic contrast, may be used for diagnostic screening, with 91% sensitivity.⁵ (Figure 1) Arthroscopy would be the definitive method for diagnosing these injuries, however, not always the full extension of subscapularis muscle tendon can be visualized with shoulder joint standard arthroscopy.³ When an injury is not specifically screened, a surgeon cannot diagnose it.⁵

In a physical examination, the lift-off test can be applied, as described by Gerber and Krushell⁶, which consists of passively bringing the upper limb to dorsal region at maximum medial rotation, with the result being regarded as normal when the patient is able to keep maximum medial rotation after the examiner releases the limb. (Figure 2) Another test described for assessing the integrity of subscapularis muscle is the "belly-press", in which the patient presses the abdomen with an open hand and tries to keep the upper limb at maximum medial rotation with the elbow anterior to the trunk. If medial rotation is normal, the elbow will not move posteriorly. In the presence of subscapularis muscle injury, maximum medial rotation cannot be kept when moving the elbow posteriorly to the trunk.⁶ (Figure 3)

All authors state no potential conflict of interest concerning this article

Study conducted at Santa Casa de São Paulo Medical Sciences School "Pavilhão Fernandinho Simonsen", Department of Orthopaedics and Traumatology – Shoulder and Elbow Group (DOT – FCMSCSP).

Correspondences to: Santa Casa de Misericórdia de São Paulo, Departamento de Ortopedia e Traumatologia, "Pavilhão Fernandinho Simonsen", Rua Dr. Cesário Mota Júnior, 112-Vila Buarque, São Paulo – SP – Brasil. CEP 01220-020. Email: ombro@ombro.med.br

Received in 06/27/07 approved in 07/15/08

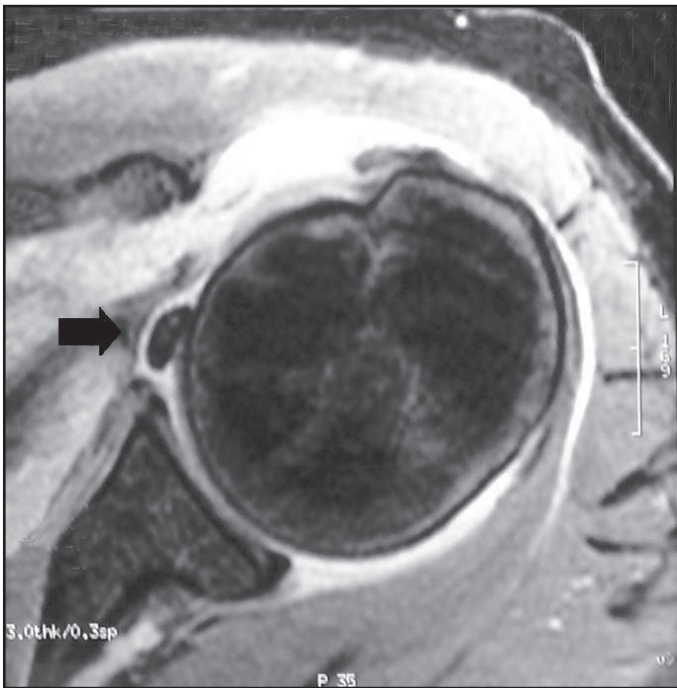


Figure 1 – Magnetic resonance image. The arrow shows a dislocated tendon of biceps long head, as well as a subscapularis rupture.

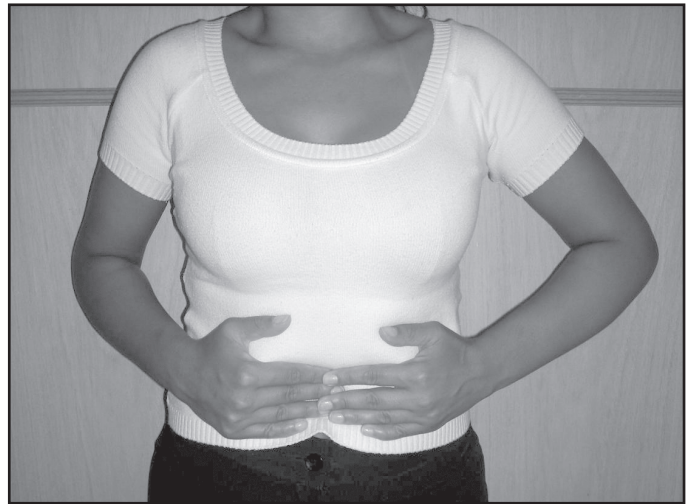


Figure 3 – Belly-press maneuver, which consists of a patient pressing the abdomen with an open hand trying to keep maximum medial rotation of the upper limb with the elbow at an anterior position to the trunk. If medial rotation is normal, the elbow will not move posteriorly, as on the left side of the patient on the photo. In the presence of subscapularis muscle injury, maximum medial rotation cannot be kept moving the elbow posteriorly to the trunk, as seen on this patient's right side.

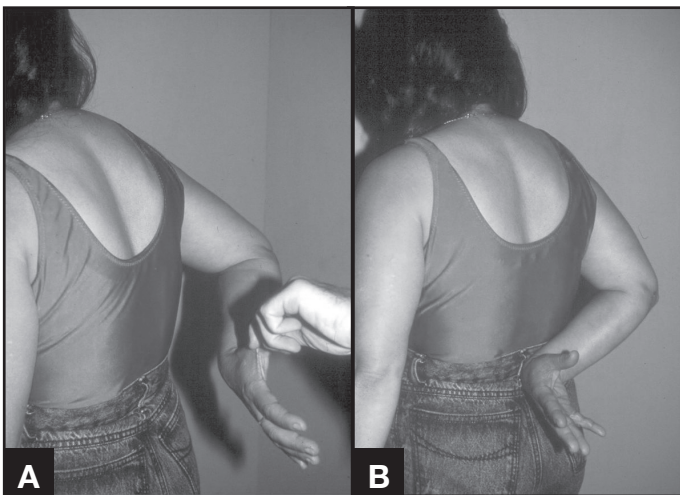


Figure 2 A – Lift-off maneuver, which consists of passively bringing the upper limb to dorsal region at maximum medial rotation, with the results being regarded as normal when the patient is able to keep maximum medial rotation when the investigator releases the examined limb.

Figure 2 B – Positive lift-off maneuver consisting of patient's inability to keep maximum medial rotation when the investigator releases the examined limb.

Subscapularis muscle tendon ruptures have received a lot of attention in orthopaedic literature, but the treatment of an isolated injury is described on few studies, always with a limited number of patients.⁴⁻⁶ Rotator cuff injury repair by arthroscopy has been increasingly performed by orthopaedic surgeons as their experience and trust on this technique also increase. Similarly, suture of the isolated injury of subscapularis muscle tendon is increasingly performed.⁷

The objective of this study is to review the results of surgical treatment on patients with isolated rupture of the subscapularis muscle tendon.

PATIENTS AND METHODS

From June 1987 to April 2005, 12 patients with isolated injuries of subscapularis muscle tendon were submitted to surgical treatment.

Ten patients were injured as a result of trauma. There were 8 males and 4 females. Mean age was 52 years, ranging from 31 to 67. Preoperative pain duration ranged from three days to 72 months. (Table 1)

Preoperative mobility may be assessed on Table 2.

At physical examination, eight patients were positive to the lift off test. Only in one patient (Case 1) the maneuver was not assessed, because the patient had been treated before baseline. Four had pain on the acromion- clavicular joint. Six patients practiced sports previously to injury. (Table 1)

Seven patients had full injuries of subscapularis muscle tendon and five partial injuries diagnosed during surgical procedure. One of the patients with full injury of the subscapularis muscle tendon had an associated fracture of the coracoid process (Case 1). Four patients had instability of the long head of the brachial biceps muscle tendon. (Table 1)

Seven patients were submitted to treatment by the arthroscopic technique and five by deltopectoralis open approach. Of the seven patients submitted to arthroscopic surgery, tendonesis of the long head of brachial biceps muscle was associated in three, due to instability. Three patients were also submitted to acromioplasty via arthroscopy and to resection of the distal clavicular end. Coracoplasty was performed in only one patient in conjunction with arthroscopic acromioplasty and to the resection of distal clavicular end. (Table 1)

Of the patients submitted to open surgery, tendonesis of brachial biceps muscle long head was associated in one patient, while acromioplasty was associated in three, and one patient had resection of distal clavicular end associated. Coracoid process fracture present in Case 1, was fixated during the same procedure.

Table 1 – Patients' data

	GENDER	AGE	DOM	TRAUMA	MOT PRE	LIFT-OFF	APP	INJ.T	BIC T.	ASSOC. PROCED.	MOT POST	UCLA	F.UP	COMPLICATIONS
1	M	67		Y	100/50/T10	#	OP	FULL			170/40/45	35	227	
2	F	61	Y	Y	170/45/GLU	Y	OP	PART		ACR	160/40/L3	34	122	
3	F	55	Y	Y	150/50/T12	Y	OP	FULL	Y	ACR+MU	160/45/T7	31	107	AC PAIN
4	M	43	Y	Y	90/40/T11	Y	OP	FULL		ACR	120/45/L2	25	78	PAIN/ STRENGTH DEFICIT
5	M	63	Y	Y	90/40/L1	Y	OP	FULL			150/45/T7	35	50	
6	F	55	Y		160/70/L2		ART	PART	Y	ACR+MU	160/60/L4	35	41	
7	M	42	Y	Y	140/80/L3	Y	ART	PART	Y		140/60/L5	35	25	
8	M	59	Y	Y	150/60/T12	Y	ART	FULL		ACR+MU+CP	150/60/T5	35	20	
9	M	52	Y	Y	140/90/T10	Y	ART	FULL			140/45/T4	35	18	
10	M	42	Y	Y	150/45/T8		ART	PART		MU	140/45/T8	33	18	
11	M	31	Y		150/60/T8		ART	PART		ACR	150/60/T7	34	13	
12	F	56		Y	130/90/L5	Y	ART	FULL	Y		160/60/T7	33	12	

SOURCE: SAME-DOT-ISCMS - M - male / F - female / age in years / DOM - dominance / Y - yes / MOT. PRE – preoperative motility / LIFT-OFF – lift-off test / APP – surgical approach / OP - open / ART - arthroscopic
 INJ. T – Injury type/ PAR – partial/ FULL- full/ BIC T. biceps tenodesis/ ASSOC. PROCED. – Associated procedure/ACR - acromioplasty/ MU - Mumford / CP - coracoplasty
 MOT. PNST – postoperative motility / F.UP – follow-up in months / AC PAIN – pain at acromioclavicular joint - # - not surveyed, because the injury occurred in 1987, previously to teste description in 1991.

Table 2 – Joint motion (mean)

	PREOPERATIVE	POSTOPERATIVE
Lift	90° - 170° (135°)	120° - 170° (150°)
Lateral rotation	40° - 90° (60°)	45° - 60° (50°)
Medial rotation	gluteus – T7 (T12)	L5 - T4 (T9)

SOURCE - SAME DOT-ISCMS

Medial rotation assessed by the vertebral level reached by patient with thumb
 Lateral lifting and rotation assessed in degrees.

On the seven patients submitted to arthroscopic treatment, tendon repair was provided by means of anchors (Figure 4), while the repair on those submitted to open surgery was provided with trans-bone stitches (Figure 5) in four patients and, in one, anchors were used.

The number of stitches ranged from one to six, in an average of 3.3 stitches. The mean postoperative immobilization time with slings was five weeks, ranging from four to six weeks.

During postoperative follow up, the patients were clinically reassessed by the method described by University of California at Los Angeles – UCLA⁸, and joint motion was assessed by the parameters described by Hawkins and Boko⁹. For assessing fat degeneration of subscapularis muscle, the classification by Mellado et al¹⁰ was employed, based on magnetic resonance imaging.

RESULTS

Pre-and postoperative joint motion can be reviewed on Table 2. The six patients who practiced sports previously to injury returned to the same level of activity.

By assessing the results by UCLA method, we found eight excellent results, three good results, and one poor result, in an average of 33, ranging from 25 to 35. (Table 1)

As complications, we had one patient with complaints of residual pain on acromion-clavicular joint, and another still suffering reduced global shoulder strength and joint motion. (Table 1)

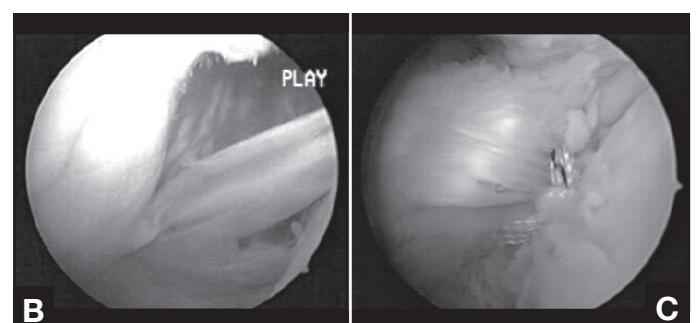
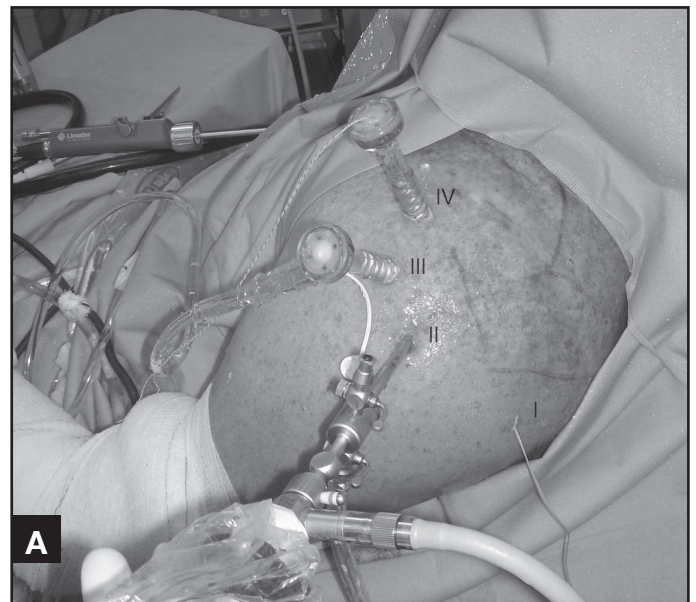


Figure 4 A – Perioperative image showing the positioning of ports for arthroscopic surgery: I – posterior port; II – lateral port; III – anterolateral port; IV – anterior port.

Figure 4 B – Perioperative image of arthroscopic procedure showing medial dislocation of the tendon of brachial biceps muscle's long head.

Figure 4 C – Perioperative image of arthroscopis surgery showing suture of the subscapularis injury.

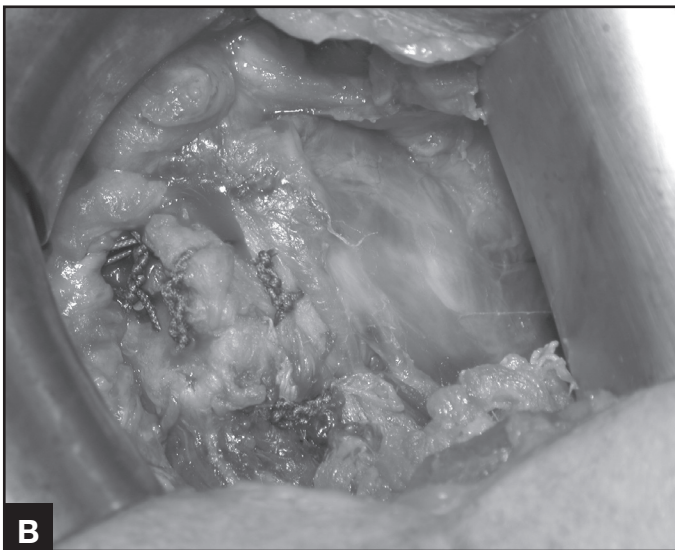
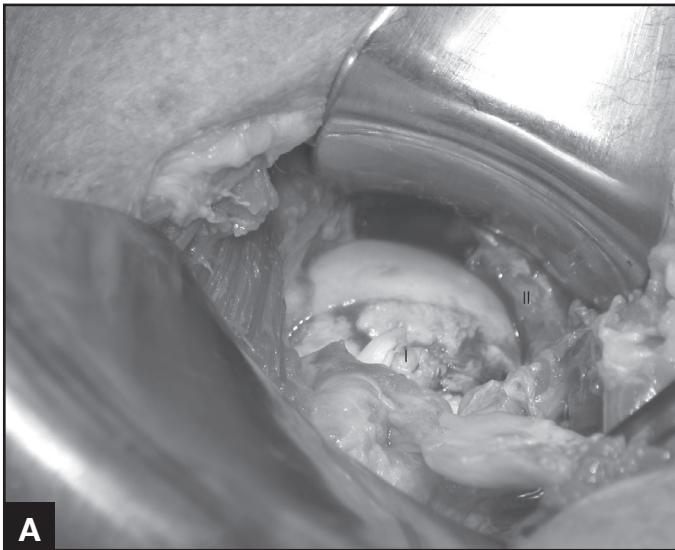


Figure 5 A – Peroperative image of open procedure showing: I – minor tubercle; II – Retracted subscapularis tendon.

Figure 5 B – Peroperative image of open procedure showing suture of the subscapularis injury.

DISCUSSION

There are few studies in literature about the surgical treatment of isolated injuries of subscapularis muscle tendon, with the first description provided in 1991 by Gerber and Krushell.⁶ Most authors published studies with small samples.^{1,2,4,6,7} Edwards et al.¹¹ have the largest series described about this injury, presenting the results of the surgical treatment on 81 patients (84 shoulders) with isolated injury of subscapularis muscle tendon. In this study, the Constant index improved from 55 points in average preoperatively to 79.5 points postoperatively.

In our study, the mean age of affected patients was 52 years, which is close to the reported average, which ranged from 39 to 67 years. The proportion of male and female patients, duration of pain and injury on dominant side were also consistent with literature.^{1,2,4,7,11}

Usually, subscapularis muscle tendon injuries occur as a result of trauma. Edwards et al.¹¹ identified trauma as the mechanism of injury in 67% of the cases. In our study, 83% of the patients had trauma-related injuries.

The lift-off test positivity in our study was singular to that demonstrated in the study where the maneuver was originally described.⁶ All patients with full injury of subscapularis muscle tendon showed a positive lift-off test on preoperative assessment, as well as two patients with partial injuries.

Surgical treatment can be performed both by open and arthroscopic ways. Gerber and Krushell⁶, were the first to describe open surgery using a superolateral access. Edwards et al.¹¹ described a series of patients submitted to open surgery, with 58 patients through deltopectoralis way and 26 through anterior trans-deltoid way, the latter was selected when associated supra-spinal tendon injury was suspected. Burkhart et al.⁷, provided the first description of an arthroscopic treatment for isolated injuries of subscapularis muscle tendon, using anchor positioning – one anterolateral for mobilizing the tendon and one ancillary anterolateral for traction points on the tendon. (Figure 4)

In association with subscapularis muscle tendon injury, the long head tendon injury of brachial biceps muscle may be present, requiring tenodesis. We found 33.3% of associated injuries of the long head tendon of brachial biceps muscle. In literature, this association is described in 50-78% of the cases.^{2,6,11}

Our rate of 91.7% excellent and good results after surgical repair of the isolated injury of subscapularis tendon is consistent with literature, with rates around 90%. Of the five patients submitted to open surgery, we found four excellent and good results (80%), which are similar to those found by Gerber et al.⁴ (81%) and Edwards et al.¹¹ (84%). Burkhart and Tehrani⁷, had 92% of excellent and good results with arthroscopic treatment. In our study, the percentage of excellent and good results with arthroscopy was 100%.

In our opinion, arthroscopic surgery is a technical challenge, requiring a learning curve and higher costs, but it is a less invasive procedure, allowing investigating and treating other injuries that may be associated.

The patient who evolved to a poor result after open surgery (Case 4), remained feeling pain and did not recover the strength on the operated upper limb. In 2003, he was submitted to a magnetic resonance test evidencing severe fat degeneration on subscapularis muscle, at stage 4 of the classification by Mellado et al.¹⁰, but with no sign of new rupture. Currently, this patient is negative to the lift-off test and is included on a physical therapy program for muscular strengthening.

In one patient, arthroscopic coracoplasty was performed conjunctively to tendinous injury repair, as provided by Gerber et al.⁴ in 1996.

CONCLUSIONS

The surgical treatment of patients with isolated injuries of subscapularis muscle tendon provides good and excellent results in 91.7% of the cases and patient satisfaction both with open and arthroscopic surgery. The associated injury of the long head tendon of brachial biceps muscle was found in 33.3% of the patients.

REFERENCES

1. Wirth MA, Rockwood CA Jr. Operative treatment of irreparable rupture of subscapularis. *J Bone Joint Surg Am.* 1997;79:722-31.
2. Deutsch A, Altchek DW, Veltri DM, Potter HG, Warren RF. Traumatic tears of subscapularis tendon. *Am J Sports Med.* 1997;25:13-22.
3. Wright JM, Heavrin B, Hawkins RJ, Noonan T. Arthroscopic visualization of subscapularis tendon. *Arthroscopy.* 2001;17:677-84.
4. Gerber C, Hersche O, Farron A. Isolated rupture of subscapularis tendon. *J Bone Joint Surg Am.* 1996;78:1015-23.
5. Pfirrmann CWA, Zanetti M, Weishaupt D, Gerber C, Hodler J. Subscapularis tendon tears: detection and grading at MR arthrography. *Radiology.* 1999;213: 709-14.
6. Gerber C, Krushell RJ. Isolated ruptures of the tendon of the subscapularis muscle. *J Bone Joint Surg Br.* 1991;73:389-94.
7. Burkhart SS, Tehrany AM. Arthroscopic subscapularis tendon repair: technique and preliminary results. *Arthroscopy.* 2002;18:454-63.
8. Ellman H, Kay SP. Arthroscopic subacromial decompression for chronic impingement – two to five years results. *J Bone Joint Surg Br.* 1991;73:395-8.
9. Hawkins RJ, Botos DJ. Clinical evaluation of shoulder problems. In: Rockwood CA Jr, Matsen FA III. *The Shoulder.* 2nd ed. Philadelphia: WB Saunders; 1998. p.175-80.
10. Mellado JM, Calmet J, Olona M, Esteve C, Camins A, Palomar LP et al. Surgically repaired massive rotator cuff tears: MRI of tendon integrity, muscle fatty degeneration, and muscle atrophy correlated with intraoperative and clinical findings. *Am J Roentgenol.* 2005;184:1465-3.
11. Edwards TB, Walch G, Sirveaux F, Molé D, Nové-Josserand L, Boulahia A et al. Repair of tears of the subscapularis. *J Bone Joint Surg Am.* 2005; 87:725-30.