

Acute Disseminated Paracoccidioidomycosis in a 3 Year-Old Child

Daciene de Arruda Grossklauss¹, Tomoko Tadano², Sandra Assis Breder² and Rosane Christine Hahn^{1,2}

¹Science Medical School, Federal University of Mato Grosso; ²Julio Muller University Hospital; Cuiabá, MT, Brazil

Clinical cases involving paracoccidioidomycosis in children, diagnosed in Mato Grosso State, in the central western region of Brazil, are rare despite the state being classified with a moderate to high incidence. We describe a clinical case of infant acute disseminated Paracoccidioidomycosis in Mato Grosso State, Brazil, highlighting the importance of early differential diagnosis from other severe pathologies, thus contributing to the survival of compromised patients. A 3 year-old male child, weighing 12.8 Kg, originating from Vila Rica, MT, Brazil. The patient presented intermittent 40°C fever evolving over 40 days, dry cough and painless bilateral cervical adenomegaly, showing no signs of inflammation. This was associated with diarrhea, distension and important abdominal pain and weight loss. Diagnosis was achieved by visualization of *Paracoccidioides brasiliensis* yeasts in a direct mycological exam and posterior fungus isolation in culture medium. The patient evolved presenting good clinical response to antifungal treatment and progressive reduction of abdominal and cervical ganglions. To improve the prognosis of compromised patients it is essential that professionals realize a full clinical-laboratorial evaluation, including differential diagnoses for other severe pathologies, as early as possible. The degree and intensity of paracoccidioidomycosis compromise are determining factors for defining the most efficient treatment.

Key-Words: Acute paracoccidioidomycosis, children, antifungal.

The thermomorphous fungus *Paracoccidioides brasiliensis* is the etiological agent for paracoccidioidomycosis (PCM), a human systemic disease restricted to Latin America, with endemic areas found from Argentina to Central America, and constitutes one of the most important mycoses in this region [1]. Brazil possesses important endemic areas of this disease, which is considered a public health issue in the country, especially concerning rural workers, with highly deficient access to and support from the health services network, which favors delayed diagnosis [2,3].

Mato Grosso is a state in the central western region of Brazil that presents a significant and growing number of PCM cases, as observed in clinical epidemiological surveys [4]. Over the last few decades, notable alterations have been observed in PCM frequency, the demographic characteristics of the population affected and in its geographical distribution. Although not all the causes of these alterations are known, it is assumed that increased urbanization and diagnostic improvements should be highlighted as major contributing factors. Environmental factors resulting from the opening of new agricultural frontiers, involving the logging of forests, principally in the central western and northern regions, especially affecting the Amazon forest, have also contributed to the current panorama of this mycosis [2].

PCM is acquired by the inhalation of propagules from the mycelial phase of the fungus, which initially develop in the respiratory airways and can disseminate by hematogenic and/or lymphatic vias to other organs in the organism. Many infected individuals develop asymptomatic pulmonary infection and

only some patients present clinical manifestations that are classified as acute, subacute or chronic [5].

The most frequent clinical presentation of PCM is the chronic form, involving pulmonary compromise; the acute form occurs in only 3% to 5% of cases and presents as a lymphoproliferative syndrome involving fever with severe evolution, which has been diagnosed in children and adolescents. In this form, a low differential exists between the proportion of males and females, compared to reports of the chronic mycosis form, where greater prevalence is observed among males. PCM remains relatively unknown among pediatricians and general clinicians and is considered a rare pathology in infancy, a fact that contributes to its delayed diagnosis, treatment and impaired prognosis [5-8].

The Júlio Muller University Hospital (*Hospital Universitário Júlio Muller*, HJUM) and the Investigation Laboratory of the Faculty of Medical Sciences at the Federal University of Mato Grosso (UFMT), located in the state capital, act in concert as reference services in the state regarding the clinical-laboratorial diagnosis and treatment of PCM and are responsible for cases both within the state and in the city of Cuiabá, as well as aiding neighboring states. The study objective was to present a case of the acute (infant) form of PCM, describing the clinical aspects of its presentation, evolution and treatment.

Case Report

Patient

When first attended, MHCS was a 3 year-old male child, weighing 12.8 Kg, born and raised in Vila Rica, MT, Brazil.

HDA

The patient presented history of intermittent 40°C fever that evolved over 40 days, dry cough and painless bilateral cervical adenomegaly, showing no signs of inflammation. Treated for pneumonia with amoxicillin for 14 days, his clinical condition worsened, presenting dyspnea followed by cyanosis. He was then transferred to an ITU in Cuiabá

Received on 15 January 2009; revised 13 April 2009.

Address for correspondence: Dr. Rosane Christine Hahn. Universidade Federal de Mato Grosso, Faculdade de Ciências Médicas, Laboratório d'Investigação. Av. Fernando Correa da Costa, s/n, Coxipó - Cuiabá -MT Zip code: 78000-000. Brazil.

presenting respiratory failure, where he remained for 15 days, followed by a further 45 days in the infirmary. After being discharged he relapsed, presenting fever episodes and increased cervical adenomegaly and was readmitted to the oncology unit following suspicion of lymphoma. After being submitted to cervical ganglion biopsy, this hypothesis was discarded. Following associations with diarrhea, distension and important abdominal pain and weight loss, he was eventually referred to our service for diagnostic clarification.

Physical Exam

He presented visible weight loss, weighing only 13 Kg, with diminished panniculus adiposus, principally in the limbs, pale cutaneous mucosa of 2+/4, and was anicteric, exhausted and prostrate. Left and right anterior cervical adenomegaly were present, the largest measuring 5 cm in diameter, with no signs of inflammation or fistulae, of elastic consistency that were mobile and painless. Axillary and inguinal nodes of 0.5 to 1 cm were present. His abdomen was rounded, tense and painful to palpation. The liver presented 4 cm from the right costal edge, with blunt edges, fibroelastic and without nodules and hepatometry measured 10 cm. A mass of imprecise limits and firm consistency was found in the mesogastric region, projecting to the left, confounding the limits of the spleen. Traube's space was occupied. The left iliac fossa was filled by a hardened mass presenting an irregular outline. No alterations were found during examination of the remaining organs.

Laboratorial and Complementary Exams

A diagnostic puncture of the largest cervical node was realized, in which the presence of a large number of yeast form cells typical of *P. brasiliensis* were observed. Later, the fungus was grown in culture medium. An ultrasound exam of the abdomen revealed large adenomegaly of the hepatic hilum, paraaortic and peritoneal nodes. Exams revealed discrete hepatomegaly; hemogram presenting moderated hypochromic microcytic anemia and thrombocytosis (819,000 cells/mm³), leukocytosis (19,000 cells/mm³) with neutrophilia (75%), relative lymphopenia (15%) and monocytosis (6%); normal kidney and liver function; discrete hypoalbuminemia (3.2 g/dL); globulinemia (3.2 g/dL); and normal LDH and C-reactive protein levels.

Evolution

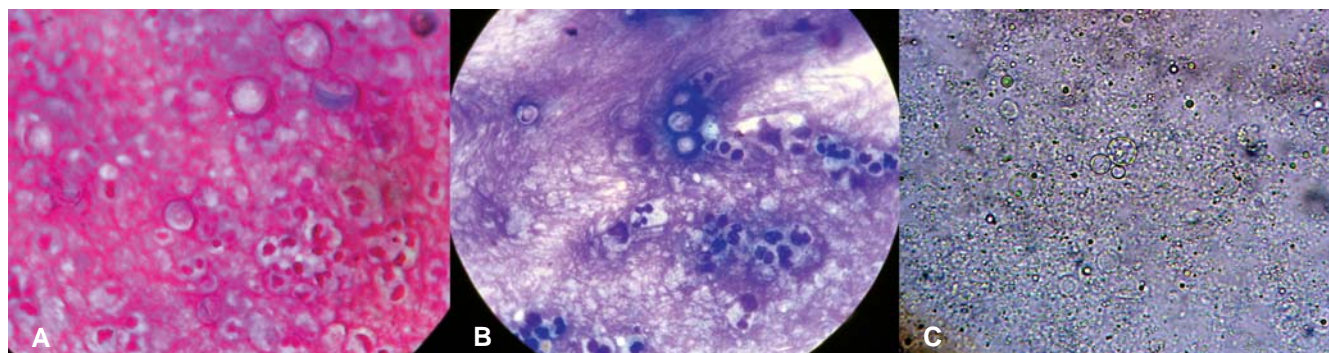
Treatment with amphotericin B (0.8 mg/kg/day) and prednisone (0.5 mg/kg/day) was initiated. Fever remission occurred on day 3 of treatment, with discrete improvement in the boy's general condition. On day 9 of admittance, he complained of thoracic pain, without fever. Pneumonia with pleural effusion was diagnosed and treatment with cefepime was initiated. Thorax drainage was realized by drain placement. Examination of the pleural fluid was characteristic of exudate (Figure 1). No further bacterial growth in pleural fluid culture or hemoculture was observed.

The patient evolved, presenting good clinical response to the antibiotic treatment and progressive reduction of the abdominal and cervical nodes. The spleen and liver were

palpable 4 cm from the left and right costal edges, respectively. Treatment with amphotericin B was continued for 28 days and prednisone for 12 days. The patient was discharged on day 30 of admittance and prescribed itraconazole (100 mg/day) and ferrous sulfate. Throughout the entire treatment he presented no signs of renal toxicity due to the amphotericin B, as confirmed by the stable kidney function tests. Outpatient follow-up occurred two months after discharge and the correct use of itraconazole, the patient weighed 15.8 kg and presented complete regression of hepatosplenomegaly and cervical and abdominal adenomegaly. The follow-up treatment proposed was a further two months of itraconazole, followed by two years of sulfamethoxazole-trimethoprim.

The case refers to a male infant, born and resident in Vila Rica, a municipality located in western Mato Grosso State, close to the border with Bolivia. The initial clinical manifestations showed painless bilateral cervical adenomegaly, showing no signs of inflammation, intermittent fever up to 40°C and frequent dry cough. The Vila Rica medical service used amoxicillin and penicillin for 20 days, believing that the symptoms indicated pneumonia. The child's clinical status worsened, evolving to intense dyspnea followed by cyanosis. The patient was then referred to the Santa Casa de Misericórdia in Cuiabá, where he was treated and after 50 days admittance, was discharged. The patient returned home to the countryside; however he presented further fever episodes, followed by diarrhea and intense abdominal pain. Suspicion of neoplasia was hypothesized and the patient was referred to the Mato Grosso Cancer Hospital (*Hospital do Câncer de Mato Grosso*, HCMT), where a biopsy was performed on the left cervical node chain; however, no neoplastic alterations were detected. Finally referred to our service, mycosis diagnosis was easily obtained by direct examination and *in vitro* isolation of the fungus using node aspirate. When the paracoccidioidomycosis diagnosis was finally determined, antifungal therapy was instituted. An interesting fact in the unfolding story was the appearance of nosocomial pneumonia, confirmed after thoracentesis drainage and treated using 50 mg of cefepime every 8 h, extravenous injection, for 6 days, which permitted the regression of the disease. The antifungal therapy presented satisfactory results that stabilized the child's clinical condition and significant improvement in the abdominal lymph nodes was demonstrated by ultrasound, leading to patient discharge. The patient continued under the follow-up treatment prescribed, 100mg/day of itraconazole, and subsequent consultations demonstrated recovery and visceromegaly regression. The Mato Grosso State reference service at the HJUM managed to institute an efficient therapy that permitted regression of the lymph nodes and improvement of the clinical condition. This presentation illustrates the presence of PCM cases presenting the infant acute clinical form in Mato Grosso, especially in cities that are in full agricultural development, which consequently involves extensive areas of logged forest and soils plowed in preparation for plantation [8].

Figure 1. Culture indicating paracoccidioidomycosis positive. A) Gram; B) Giemsa; C) KOH 20% with glycerol.



Discussion

Mato Grosso State is strongly agrobusiness oriented and is located in a region endemic for PCM. The acute form of PCM, prevalent in infancy, is important for indicating probable PCM reserve areas, since children are active in limited areas and families tend not to migrate frequently; thus determining probable areas where the infection was acquired [6, 9]. The child was born and raised in a rural area of Vila Rica and had never traveled to other locations, according to his mother's report; a fact that could be indicative of the presence of the fungus in this municipality in some specific niche. Factors that probably contributed to his infection were residency in a rural area close to forests; exposure to logging of extensive forest areas, especially for agricultural purposes; low immunity and/or chronic malnutrition common to children in these populations, who are exposed to the difficulties of subsistence living in such regions [8].

The primary paracoccidioid complex in children was first described in 1992 [10], however, in this case it was not possible to detect these findings, possibly because the patient had presented pulmonary symptoms and, for this reason, received treatment for pneumonia.

Laboratorial data concerning leukocytosis (19,000 cells/mm³) were similar to those described by Nogueira et al. (2006) [11] who analyzed laboratorial data from 38 children presenting PCM and found values between 4,400 and 36,000 cells/mm³.

Colombo et al. [12] described icterus as an initial PCM manifestation in children; whereas Paniago et al. [13], described the following symptoms as more prevalent in the acute form: lymphadenopathy (95.4%), hepatomegaly (40%) and splenomegaly (23.1%). All these symptoms were present in the case reported here.

In synthesis, an accurate clinical-laboratorial diagnosis must be realized as early as possible. This action permits the institution of adequate therapeutic management; thus leading to an increase in patient survival. Clinical signs and symptoms should be clearly investigated, and resolved using classic manifestations (pneumonias, neoplasias); moreover, this

should include the exclusion of serious and less common diseases, such as PCM in children.

References

- Restrepo A. The ecology of *Paracoccidioides brasiliensis*: a puzzle still unsolved. *Sabouraudia* **1985**;23:323-334.
- Shikanai-Yasuda M.A., Telles F.F.Q., Mendes R.P., Colombo A.L., Moretti M.L. Guidelines in paracoccidioidomycosis. *Rev Soc Bras Med Trop* **2006**;39:297-310.
- Coutinho Z.F., Silva D., Lazera M. et al. Paracoccidioidomycosis mortality in Brazil (1980-1995). In: *Cadernos de saúde pública: Ministério da Saúde, Fundação Oswaldo Cruz: Escola Nacional de Saúde Pública* **2002**;18:1441-1454.
- Assis D.R., Carvalho J., Rezende S.B. et al. Paracoccidioidomycose em Mato Grosso: Revisão clínico-laboratorial da demanda do Hospital Universitário da UFMT. *Rev Soc Bras Med Trop* **2007**;40:94.
- de Camargo Z.P., de Franco M.F. Current knowledge on pathogenesis and immunodiagnosis of paracoccidioidomycosis. *Rev Iberoam Micol* **2000**;17:41-48.
- Gonçalves A.J., Londero A.T., Terra G.M. et al. Paracoccidioidomycosis in children in the state of Rio de Janeiro (Brazil). Geographic distribution and the study of a "reservarea". *Rev Inst Med Trop Sao Paulo* **1998**;40:11-13.
- Franco M., Peracoli M.T., Soares A. et al. Host-parasite relationship in paracoccidioidomycosis. *Current topics in medical mycology* **1993**;5:115-149.
- Gonçalves A.J. R., Terra G.M., Passoni L.F. et al. Paracoccidioidomycose infanto-juvenil. Relato de dez pacientes recentemente observados na cidade do Rio de Janeiro. *Revista Médica* vol. 1.
- Fonseca E.R., Pardal P.P., Severo L.C. Paracoccidioidomycosis in children in Belem, Pará. *Rev Soc Bras Med Trop* **1999**;32:31-33.
- de Campos E.P., Bertoli C.J., Barbosa K.S. Pulmonary lymph node in acute juvenile paracoccidioidomycosis (a case report). *Rev Soc Bras Med Trop* **1992**;25:195-200.
- Nogueira M.G., Andrade G.M., Tonelli E. et al. Laboratory evolutive aspects of children under paracoccidioidomycosis treatment. *Rev Soc Bras Med Trop* **2006**;39:478-483.
- Colombo A.I., Hadad D.J., Camargo Z.P. et al. Icterícia obstrutiva como apresentação de paracoccidioidomycose. *Arq Bras Ped* **1994**;1:100-110.
- Paniago A.M., Aguiar J.I., Aguiar E.S. et al. Paracoccidioidomycosis: a clinical and epidemiological study of 422 cases observed in Mato Grosso do Sul. *Rev Soc Bras Med Trop* **2003**;36:455-459.