



The Brazilian Journal of INFECTIOUS DISEASES

www.elsevier.com/locate/bjid



Case report

Severe shoulder tendinopathy associated with levofloxacin

Walter de Araujo Eyer-Silva^{a,*}, Henrique de Barros Pinto Netto^b,
Jorge Francisco da Cunha Pinto^a, Fernando Raphael de Almeida Ferry^a,
Rogério Neves-Motta^a

^a Hospital Universitário Gaffrée e Guinle, Universidade Federal do Estado do Rio de Janeiro (UNI-RIO), Rio de Janeiro, Brazil

^b Hand Surgery Unit, Hospital da Lagoa, Rio de Janeiro, Brazil

ARTICLE INFO

Article history:

Received 31 January 2012

Accepted 26 March 2012

Keywords:

Fluoroquinolone

Levofloxacin

Tendinitis

Tendinopathy

ABSTRACT

Fluoroquinolone (FQ)-associated tendinopathy and myopathy are uncommon but well recognized complications of the use of this class of antibacterial agents. The case of a 63-year-old previously asymptomatic female patient who developed severe left shoulder tendinopathy after surreptitiously doubling the prescribed dose of levofloxacin for the treatment of community-acquired pneumonia is reported here. Surgical stabilization with suture anchors and subacromial decompression were needed.

© 2012 Elsevier Editora Ltda. All rights reserved.

Introduction

Fluoroquinolone (FQ)-associated tendinopathy, including tendon rupture, myopathy, and arthropathy, is an uncommon but potentially devastating complication of this class of antibacterial agents. It has been described with most representatives of the class, but ofloxacin and ciprofloxacin seem to be the most common agents. Symptoms of tendon injury are reported after a median of eight days of initiation of treatment, but they may appear as early as two hours after the first dose and as late as six months after treatment.¹ The first published case report was of a 56-year-old renal transplant patient from New Zealand, in 1983, who developed Achilles tendinopathy after being treated with norfloxacin for urinary tract infection and septicemia.² The Achilles tendon is the most commonly affected, but any tendon appears to be vulnerable, including tendinitis of extraocular muscles leading to diplopia.³

The case of a female patient who developed severe shoulder tendinopathy after surreptitiously doubling the prescribed dose of a FQ agent for the treatment of community-acquired pneumonia is reported here.

Case presentation

A previously asymptomatic 63-year-old female patient from the city of Rio de Janeiro presented with fever, malaise, rigors, and a productive cough of one-week duration. She reported that these signs and symptoms developed soon after returning from a weekend trip to a rural area in the highlands of the state of Rio de Janeiro, where she was exposed to cold weather during outdoor activities. Physical examination showed an acutely ill febrile patient (38.5 °C) with coarse crackles on auscultation of the left hemithorax. She was an otherwise healthy elderly patient who reported being physically active through

* Corresponding author at: 10^º Enfermaria, Hospital Universitário Gaffrée e Guinle, Rua Mariz e Barros, 775, Rio de Janeiro, RJ, 20270-004, Brazil.

E-mail address: walter.eyer@ig.com.br (W. de Araujo Eyer-Silva).
1413-8670/\$ – see front matter © 2012 Elsevier Editora Ltda. All rights reserved.
<http://dx.doi.org/10.1016/j.bjid.2012.06.015>

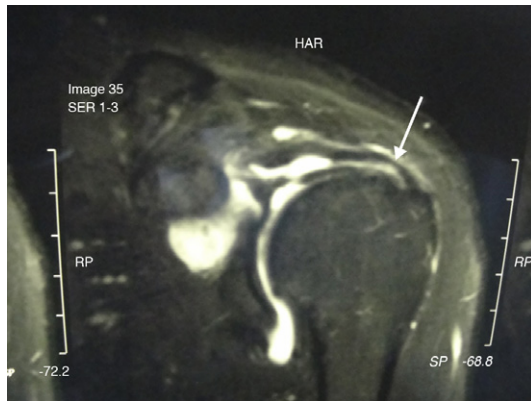


Fig. 1 – T2-weighted MRI study of the left shoulder performed three months after levofloxacin exposure shows a supraspinatus tendon tear (arrow), corresponding to a 40%–50% thinning, near its insertion on the greater tuberosity of the humerus.

daily regular aerobic and anaerobic activity at a gym. A chest x-ray study showed ill-defined patchy airspace infiltrates in the lingular portion of the left upper lobe, consistent with the diagnosis of acute lower respiratory tract infection. A decision was made to empirically initiate an outpatient treatment with levofloxacin 500 mg orally once a day for 10 days.

Two weeks later the patient presented with abrupt onset of diffuse myalgia and severe left shoulder pain. She also complained of pain in the right shoulder, biceps brachii, elbow, bilateral patellar tendon, and hip. Left shoulder swelling and pain on palpation were evident on examination. She informed that the prescribed dose of levofloxacin had been surreptitiously doubled to 500 mg bid due to the persistence of fever as of the second treatment day. Laboratory evaluation was remarkable for increased creatine phosphokinase (488 U/L; normal value < 167 U/L). A magnetic resonance imaging (MRI) study of the left shoulder rotator cuff performed one week later showed areas of increased T2 signal intensity on subscapular and supraspinatus tendons and a large gleno-umeral joint effusion with distension of the articular bursa.

The patient was treated with strict physical rest, nonsteroidal anti-inflammatory agents, shoulder splinting for joint stabilization, and physiotherapy. She gradually improved over the ensuing weeks, except for the left shoulder pain. An MRI study performed three months later showed a partial tear (40%–50% thinning) of the left supraspinatus tendon (Fig. 1). Surgical intervention was then indicated. Arthroscopy exploration revealed a rotator cuff injury with subacromial impingement. Arthroscopic stabilization with suture anchors and subacromial decompression was performed successfully. The patient remains well six months after surgical intervention.

Discussion

In spite of the FDA warning alert released in August 2008,⁴ FQ-associated tendinopathy and tendon rupture seem not to be widely known among health care professionals. Proposed

pathogenic mechanisms include a direct toxic effect⁵ and ischemic injury.⁶ FQ toxicity also includes damage to cartilage, muscle, and bone tissue.⁷ It has also been associated with acute severe myalgia requiring emergency care treatment.⁸ In children and pregnant women, the use of FQs is avoided since these agents can cause lesions of articular-epiphyseal cartilage complexes in several species of juvenile animals.⁹

Major risk factors for FQ-induced tendinopathy include age over 60, concurrent corticosteroid use, high FQ dose, previous musculoskeletal disease, renal failure, and diabetes mellitus. Immediate discontinuation of FQ is warranted, but lack of knowledge on this syndrome has led to inappropriate advice to complete the antibacterial course.¹⁰ Van der Linden et al.¹¹ have found that approximately 2% to 6% of all Achilles tendon ruptures in people older than 60 years can be attributed to FQ use. Imaging studies such as ultrasound and MRI are useful in identifying tendon tears.

The present case report highlights the importance of judicious use of FQ agents among those with risk factors for FQ-related tendinopathy, especially older patients. The potential benefits and risks of prescribing a FQ agent should be weighed individually. Patients receiving a FQ agent should be advised to seek medical attention as soon as any sign or symptom of tendinopathy or myopathy develops. The offending drug should be immediately withdrawn and measures of joint rest and expert orthopedic advice instituted. It is also important to avoid corticosteroids since these drugs may worsen the tendinopathy.

Conflict of interest

All authors declare to have no conflict of interest.

REFERENCES

1. Khaliq Y, Zhanel GG. Fluoroquinolone-associated tendinopathy: a critical review of the literature. *Clin Infect Dis.* 2003;36:1404–10.
2. Bailey RR, Kirk JA, Peddie BA. Norfloxacin-induced rheumatic disease. *N Z Med J.* 1983;96:590.
3. Fraunfelder FW, Fraunfelder FT. Diplopia and fluoroquinolones. *Ophthalmology.* 2009;116:1814–7.
4. FDA. Information for healthcare professionals: fluoroquinolone antimicrobial drugs [ciprofloxacin (marketed as Cipro and generic ciprofloxacin), ciprofloxacin extended-release (marketed as Cipro XR and Proquin XR), gemifloxacin (marketed as Factive), levofloxacin (marketed as Levaquin), moxifloxacin (marketed as Avelox), norfloxacin (marketed as Noroxin), and ofloxacin (marketed as Floxin)], 2008.
5. Simonin MA, Gegout-Pottie P, Minn A, Gillet P, Netter P, Terlain B. Pefloxacin-induced achilles tendon toxicity in rodents: biochemical changes in proteoglycan synthesis and oxidative damage to collagen. *Antimicrob Agents Chemother.* 2000;44:867–72.
6. Waterston SW, Maffulli N, Ewen SW. Subcutaneous rupture of the Achilles tendon: basic science and some aspects of clinical practice. *Br J Sports Med.* 1997;31:285–98.
7. Hall MM, Finnoff JT, Smith J. Musculoskeletal complications of fluoroquinolones: guidelines and precautions for usage in the athletic population. *PM R.* 2011;3:132–42.

8. Eisele S, Garbe E, Zeitz M, Schneider T, Somasundaram R. Ciprofloxacin-related acute severe myalgia necessitating emergency care treatment: a case report and review of the literature. *Int J Clin Pharmacol Ther.* 2009;47:165-8.
9. Burkhardt JE, Hill MA, Carlton WW, Kesterson JW. Histologic and histochemical changes in articular cartilages of immature beagle dogs dosed with difloxacin, a fluoroquinolone. *Vet Pathol.* 1990;27:162-70.
10. Ng WF, Naughton M. Fluoroquinolone-associated tendinopathy: a case report. *J Med Case Reports.* 2007; 1:55.
11. van der Linden PD, Sturkenboom MC, Herings RM, Leufkens HM, Rowlands S, Stricker BH. Increased risk of achilles tendon rupture with quinolone antibacterial use, especially in elderly patients taking oral corticosteroids. *Arch Intern Med.* 2003;163:1801-7.