

Case reports

Hipoplasia condylar of probable otologic origin

Hipoplasia condilar de provável origem otológica

Danieli de Souza Gomes Horn⁽¹⁾

Olívia dos Santos Silveira⁽²⁾

Carolina Drumond de Barros e Azevedo⁽²⁾

Laíze Rosa Pires⁽²⁾

Cristina Maria Fraga Moraes⁽²⁾

Paulo Isaias Seraidarian⁽²⁾

Flávio Ricardo Manzi⁽²⁾

⁽¹⁾ Universidade Tuiuti do Paraná, Curitiba, PR, Brasil.

⁽²⁾ Pontifícia Universidade Católica de Minas Gerais, Belo Horizonte, MG, Brasil.

Conflict of interest: non-existent

Received on: December 03, 2015

Accepted on: February 02, 2016

Mailing address:

Flávio Ricardo Manzi

Av. Dom José Gaspar, Prédio 45 –

Clínica de Radiologia Coração Eucarístico

Belo Horizonte – MG – Brasil

CEP: 30535-901

E-mail: manzi@pucminas.br

ABSTRACT

The temporomandibular joint is one of the most complex of the human body and the condylar process is responsible for the expression of mandibular growth. The condylar hypoplasia is characterized by a defective formation of the condylar process. The acute otitis media is an inflammatory process, triggered from infections of the nasal cavity, paranasal sinuses and, nasopharynx, propagated through the Eustachian tube. In the presented case, the patient had facial asymmetry since the first year of life, and recurring cases of otitis just in the early stages of closing the temporotimpânica suture and in the foramen of Huschke, which would facilitate the dissemination of this ear infection which would undermine the development of condyle resulting in hypoplasia identified, only in the right side. Thus, professionals who work in temporomandibular joint and ear regions must have knowledge of the existence and clinical implications of the foramen of Huschke for early diagnosis and prevent the development of facial asymmetry where this association presents with clinical signs of infection of the affected areas, restoring function, aesthetic and, psychological state of the patient.

Keywords: Temporomandibular Joint; Facial Asymmetry; Otitis Media

RESUMO

A articulação temporomandibular é uma das mais complexas do corpo humano sendo o processo condilar responsável pela expressão do crescimento mandibular. A hipoplasia condilar é caracterizada por uma formação defeituosa do processo condilar. A otite média aguda é um processo inflamatório, desencadeada a partir de infecções das fossas nasais, cavidades paranasais e rinofaringe, propagadas por meio da tuba auditiva. No caso apresentado, a paciente apresentava assimetria facial desde o primeiro ano de vida, além de recorrentes casos de otite justamente nos estágios iniciais do fechamento da sutura temporotimpânica e do forame de Huschke o que facilitaria a disseminação dessa infecção otológica o que comprometeria o desenvolvimento do côndilo resultando na hipoplasia identificada, somente do lado direito. Assim, os profissionais que atuam na região da articulação temporomandibular e ouvido devem ter o conhecimento da existência e das implicações clínicas do forame de Huschke para um diagnóstico precoce e evitar o desenvolvimento das assimetrias faciais nos casos em que esta apresenta associação com sinais clínicos de infecção das áreas afetadas, restabelecendo função, estética e o estado psicológico do paciente.

Descritores: Articulação Temporomandibular; Assimetria Facial; Otite Média

INTRODUCTION

The temporomandibular joint is one of the most complex joints in the human body. It is made up of the condyle and the articular eminence of the temporal bone. Its development starts still the 8th week of intrauterine life, where there are already two areas widely separated by mesenchymal cells in the head of the mandible and glenoid cavity. At birth, the joint surfaces are covered with fibrous connective tissue, and slowly it is converted into fibrocartilage and occurs the deepening the articular fossa. It differs from the other body joints in its appearance and in its evolution because at birth it is very underdeveloped. The head of the mandible develops an important role in the joint because it is responsible for the expression of the mandibular growth¹.

The condylar hypoplasia is characterized by a defective formation of the mandibular condyle, which may be congenital or acquired origin, the first of which is already established since the birth and the second may result from trauma, infection, radiation, endocrine disorders, degenerative joint disease or even systemic arthropathy^{2,4}. In the genetic changes group, it can mention the Microsomy Facial Congenital, Micrognathia, Treacher Collins Syndrome, Pierre Robin Syndrome, Crouzon Syndrome, and Cleft Lip and Palate. In such cases, early tissue differentiation and development processes are affected, that is, the pattern of growth of the posterior region is impaired as a result of this development of abnormality².

In cases where condylar hypoplasia is acquired, trauma and infections are considered the main reasons for the appearance of this abnormality, among them mechanical injury before two years of age (active growth phase of the condyle), the infections of joint itself or middle ear during childhood, rheumatoid arthritis, radiation therapy, parathyroid disabilities are the most which could affect the formation and differentiation of chondrocytes and consequently impair bone formation^{1,2}.

Anatomically, there is proximity between the external ear canal and TMJ, with the joint capsule attached to scamotympanic fissure. Thus, the congenital dehiscence of the cartilaginous canal and scamotympanic fissure or persistence of the foramen of Huschke can contribute to the spread of infection to the joint⁵. The merger of the tympanic ring is initially incomplete in its anterior and inferior portion resulting in an opening (foramen of Huschke) present to the fourth or fifth year of life of the individual. This merger separates the

external ear canal superiorly and inferiorly the foramen of Huschke, that is, this foramen represents non ossification of the anterior inferior portion of the tympanic plate, which is intramembranous origin. However, this foramen may persist for all the individual life. When it occurs, the retrodiscal region of the temporomandibular joint and the medial portion of the external auditory canal are separated only by soft tissue, which would facilitate the spread of infectious processes in the region^{5,6}.

The hyperplasia may develop after the loss of one or both condylar growth centers in the early stages of development and may also be accompanied by ankyloses, from bleeding and inflammation to adjacent structures causing fibrosis in the articular capsule^{2,7}. Its severity is related to the growth phase of the condyle (before birth up to 25 years approximately). The condylar growth is most active during the early years and disturbances during this phase can accentuate condylar hypoplasia³. Results in skeletal and dental facial deformation, also leading to a shortening of the mandibular branch⁴.

When diagnosed in young patients, it may be indicated as a treatment to orthopedic therapy. In cases of late diagnosis in patients already in adulthood, treatment involves orthognathic surgery to correct the skeletal deformity⁴.

CASE PRESENTATION

For realization of this case report there was an approval by the Ethics Committee of the Pontifical Catholic University of Minas Gerais (CAAE: 43979415.8.0000.5137) and free informed consent form signed by the responsible of the patient.

The presented case began when a female 15-year-old patient searched a dentist, a specialist in functional orthopedics of the jaws, complaining of large skeletal asymmetry. In the medical history, the patient and her companion (mother) said that such asymmetry existed since the first year of life, and over the years it has become increasingly pronounced, and being cause of comments on the adolescent living. The mother reported that her daughter suffers *bullying*, resulting in social isolation. A relevant data in the past history was that the patient had multiple cases of purulent otitis media from the fifth to the ninth month of life.

Thus, an extra oral examination was carried out where it was found facial asymmetry, limited mouth opening besides deflection in the opening movement.

For better evaluation of TMJ, a CT was requested. In this test it was found condylar hypoplasia of the right side. It was also found that the joint bone surfaces of this side (condyle, articular eminence and glenoid fossa) presented flattened, besides the ascending

limb shortening of the affected side jaw and the consequent developmental defect of the mandibular body. However, on the left side, all articular bone components were within the normal aspect (Figures 1 to 3).

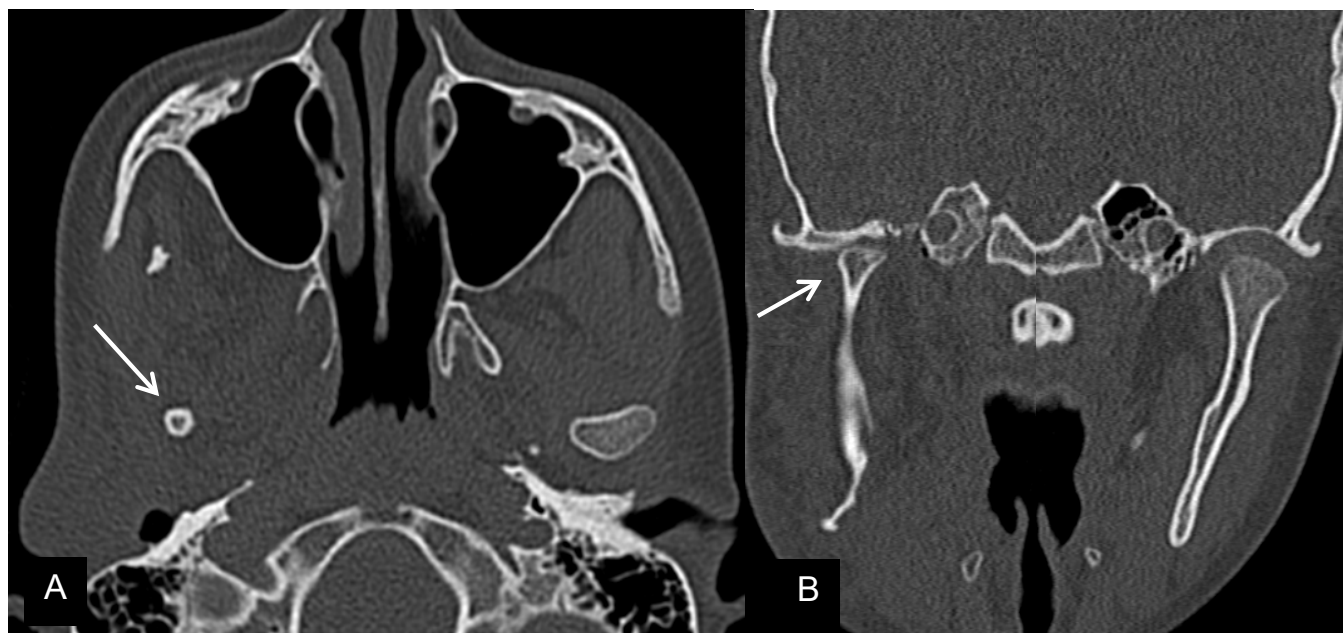

Figure 1. Computerized Tomography showing the condylar hypoplasia of the right side (indicated by arrows). Note the appearance of normality of the left condylar process; A- Axial cut and B- Coronal cut.

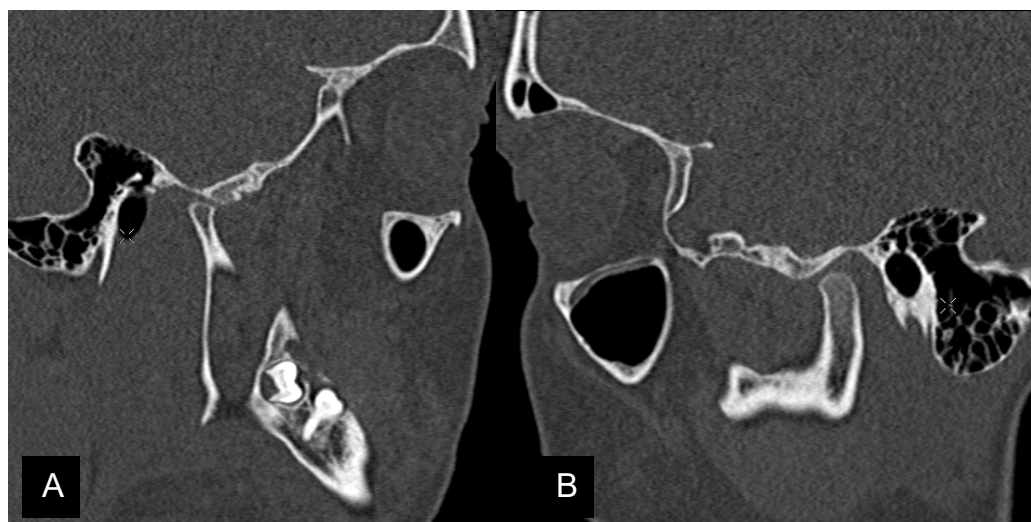

Figure 2. Computed tomography showing the condylar hypoplasia of the right side. Both condylar processes are presented previously the mandibular fossa. There is also flattening of the condyle, glenoid fossa and articular eminence of the affected side; A- Sagittal cut of the right side and B-Sagittal cut of the left.

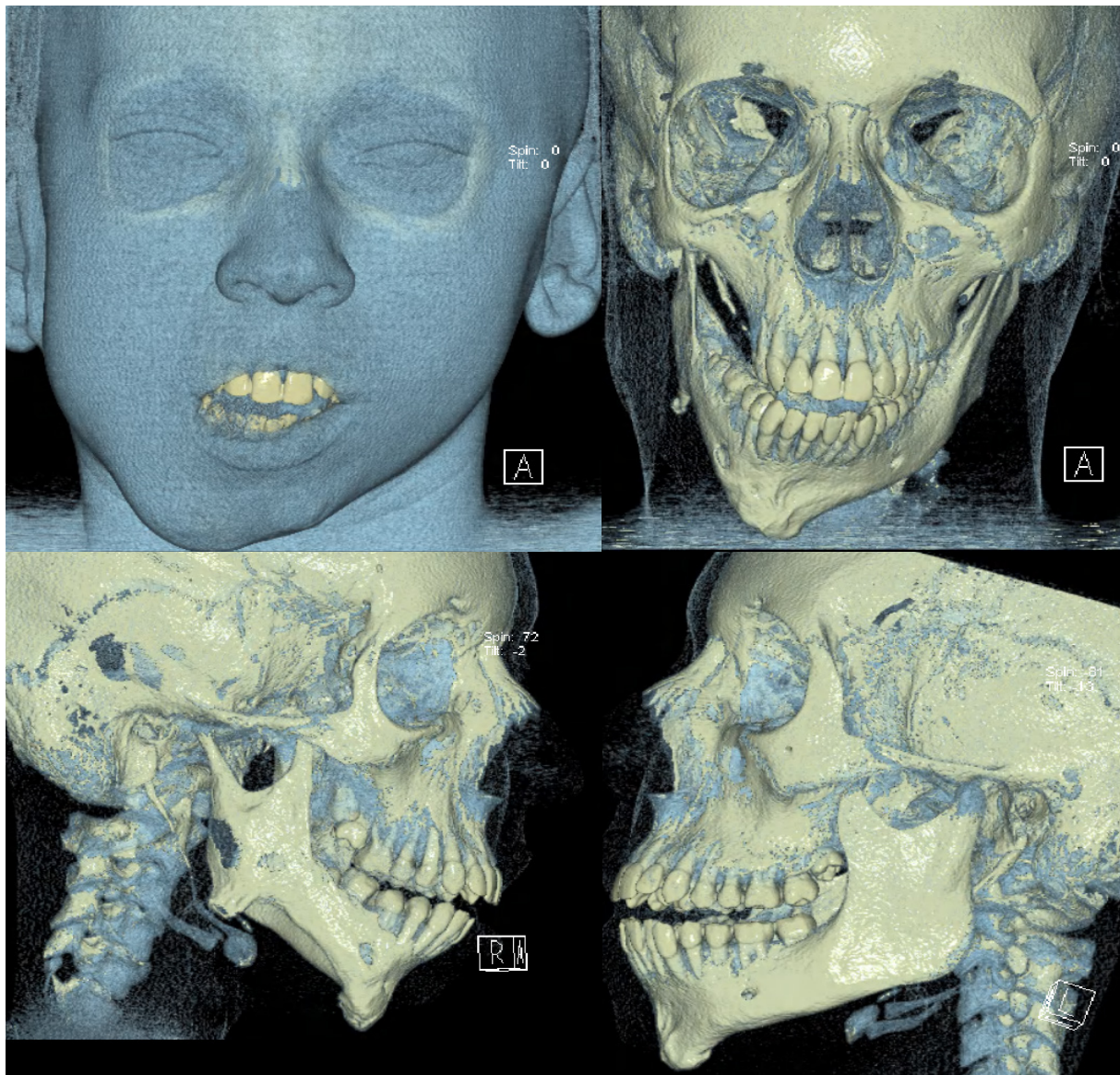


Figure 3. Computed tomography showing the condylar hypoplasia of the right side. There is also ascending limb shortening of the jaw and consequent body development defect of the affected side jaw; Three-dimensional reconstructions with A- soft tissue and B, C and D window of bone issue in various views.

RESULTS

As treatment, the patient is in orthopedic accompaniment to minimize facial asymmetry with likely future need for orthognathic surgery, after complete maturation of the patient.

DISCUSSION

Acute otitis media is an acute inflammation of the middle ear, which is triggered from infections of the nasal cavity, paranasal sinuses and nasopharynx, propagated through the Eustachian tube. The tympanic membrane becomes convex, opaque and erythematous and pneumatic otoscopy presents with limited

or no mobility, having fluid accumulation signals in the middle ear and can also be viewed with a perforation and purulent secretion. It may have otologic complications - mastoiditis, petrositis, facial paralysis and vestibular and intracranial symptoms - epidural abscess, lateral sinus thrombophlebitis, subdural abscess, brain abscess and hydrocephalus otic⁸.

There is a close relation between the middle ear and mastoid process, glenoid cavity and the temporomandibular joint. The TMJ is one of the places where the inflammatory diseases of the ear and mastoid process spread. The bony walls of pneumatized spaces of the mastoid process are important barrier against the spread of infection, but the destruction of these bone

barriers and in the presence of open sutures in the glenoid fossa and further delayed tympanic plate ossification may cause the spread of infections such as otitis acute middle, acute and chronic mastoiditis directly to TMJ^{9,10}

In children, the bone dense barriers may not yet have developed to the point where this prevention occurs. Young people are at higher risk for ear infections due to the immaturity of the Eustachian tube and still not have a complete bone development of the temporal bone, glenoid cavity and TMJ. This combination of factors places this age group at high risk of spread of infection between these two different anatomical regions¹⁰. The introduction of antibiotics drastically reduced the incidence of otitis and mastoiditis infections, as well as septic arthritis in the last years, and consequently the spread of such infections to the TMJ have been rarely found. Among the possible reasons for this to occur, you can mention the spread of inflammatory fluids through anatomical channels that enable communication of these structures¹⁰

When studying the anatomy and embryology of the temporal bone notices the existence of a “defect” bone in the medial wall of the external acoustic meatus (posterior wall of the articular fossa). This condition remains until about the four years of the individual's life. However, approximately 20% of adults may have traces of this “defect”⁵ which could serve as a means of communication of infections of external and middle ear for the TMJ tissues or vice versa. The presence of Huschke foramen would be a likely cause of the weakening of the bone structure of the external ear canal with possible tendency to fracture even in cases of trauma and infections⁵

In the reported case in this paper, there is the information of the clinical history past that the patient had recurrent cases of purulent otitis during early childhood, more precisely between the 5th and 9th month old, exactly in the early stages of the closure of temporotympanic suture and closure of the foramen of Huschke. At that stage still exists also an immaturity of bone structures surrounding the area of the ear and TMJ which would facilitate the dissemination of this ear infection and would jeopardize the development of the mandibular condyle resulting in condylar hypoplasia identified in the patient.

Another factor that may be relevant to a diagnosis of condylar hypoplasia in this case is that hypoplasia is present only on the right side, precisely on the

side pointing with recurrent otitis media in the early childhood, while the left side is in the normal range.

Another important fact is that the asymmetry is present from the first year of the patient according to the mothers' reports, that is, at birth showed no irregularities in the face, which still leads us to believe that this condition was acquired during growth.

FINAL CONSIDERATIONS

Based on the case previously reported in the tomographic image analysis and literature review is possible to state that the etiology of condylar hypoplasia is diverse, demanding a detailed clinical examination to investigate its probable origin. The condylar hypoplasia affects development and maxillo-mandibular growth, leading the patient to suffer facial asymmetries.

The diagnosis of hypoplasia should be early being fundamental requirement to restore function, aesthetic and psychological state of the patient. It is vital that professionals working in the TMJ region and ear have knowledge of the existence and the clinical implications resulting from the existence of the foramen of Huschke for early diagnosis and still prevent the development of facial asymmetry where this presents association with clinical signs of infection of the affected areas. The patient's medical history analysis makes us suppose that the condylar hypoplasia condition of the patient would have acquired cause, or due to recurrent purulent otitis suffered by her during early childhood.

REFERENCES

1. Shivhare P, Shankarnarayan L, Usha, Kumar M, Sowbhagya M B. Condylar Aplasia and Hypoplasia: A Rare Case. *Case Rep Dent.* 2013; doi: 10.1155/2013/745602
2. Meazzini M C, Brusati R, Caprioglio A, Diner P, Garattini G, Giann E et al. True hemifacial microsomia and hemimandibular hypoplasia with condylar-coronoid collapse: Diagnostic and prognostic differences. *AJO-DO.* 2011;139(5):435-47.
3. Moze K, Hoyte T, Bissoon AK. Cone Beam Computed Tomography in the Diagnosis of Unilateral Condylar Hypoplasia: Report of a Case. *West Indian Med J.* 2012;61(7):739-42.
4. Jacobson N, Starr C. Implant-Supported Rehabilitation of Severe Malocclusion Due to Unilateral condylar Hypoplasia: Case Report. *J Oral Implantol.* 2008;34(2):90-6.

5. Ajduka J, Riesa M, Vagica D, Batos-Tripalo A. Temporomandibular joint fistula into the external ear canal. *JLO*. 2012;126(8):837-9.
6. Vidigal BCL, Seraidarian PI, Rodrigues EP, Manzi FR. Avaliação anatomo-radiográfico do Forame de Huschke. *Rev ABO Nac*. 2008;15(6):372-4.
7. Agrawal S, Singh S, Agrawal M, Singh S. Unilateral Hipoplasia of the Mandibular Condyle or Displasia-An Usual Case Report. *Int J Contemp*. 2011;2(6):122-5.
8. Miranda SL, Antonini RA. Anquilose da Articulação Temporo - Mandibular Pós - Otite Média Aguda. *Rev Bras Otorrinolaringol*. 2013;60(3):240-2.
9. Orhan K, Nishiyama H, Tadashi S, Shumei M, Furukawa S. MR of 2270 TMJs: prevalence of radiographic presence of otomastoiditis in temporomandibular joint disorders. *Eur J Radiol*. 2005;55(1):102-7.
10. Rana R S, Moonis G. Head and Neck Infection and Inflammation. *Radiol Clin N Am*. 2011;49:165-82. doi:101016