

Francisco Veríssimo de Mello-Filho
Rui Celso Martins Mamede
Adilon Passinho Koury

Use of a platysma myocutaneous flap for the reimplantation of a severed ear: experience with five cases

Department of Surgery, Orthopedics and Traumatology,
Faculdade de Medicina de Ribeirão Preto, University of São Paulo, São Paulo, Brazil

ABSTRACT

INTRODUCTION

Context: The traumatic loss of an ear greatly affects the patient because of the severe aesthetic deformity it entails. The characteristic format of the ear, with a fine skin covering a thin and elastic cartilage, is not found anywhere else in the human body. Thus, to reconstruct an ear, the surgeon may try to imitate it by sculpting cartilage and covering it with skin.

Objective: To use a platysma myocutaneous flap for the reimplantation of a severed ear in humans.

Design: Case report.

Setting: Emergency unit of the university hospital, Faculty of Medicine, Ribeirão Preto - USP.

Case Report: Five cases are reported, with whole ear reimplantation in 3 of them and only segments in 2 cases. The surgical technique used was original and was based on the principle of auricular cartilage revascularization using the platysma muscle. We implanted traumatically severed auricular cartilage into the platysma muscle. The prefabricated ear was later transferred to its original site in the form of a myocutaneous-cartilaginous flap. Of the 5 cases treated using this technique, 4 were successful. In these 4 cases the reimplanted ears showed no short- or long-term problems, with an aesthetic result quite close to natural appearance. In one case there was necrosis of the entire flap, with total loss of the ear. The surgical technique described is simple and utilizes the severed ear of the patient. Its application is excellent for skin losses in the auricular region or for the ear itself, thus obviating the need for microsurgery or the use of prostheses or grafts.

Key-words: Platysma flap. Myocutaneous flap. Severed ear

The traumatic loss of an ear greatly affects the patient because of the severe aesthetic deformity it entails. The characteristic format of the ear, with a fine skin covering a thin and elastic cartilage, is not found anywhere else in the human body. Thus, to reconstruct an ear, the surgeon may try to imitate it by sculpting cartilage and covering it with skin. With a few honorable exceptions, the results are usually unsatisfactory. On this basis, the most logical procedure would be to preserve the severed ear and reimplant it. However, the surgical salvage of a severed ear is quite difficult, as confirmed by the frequent unsatisfactory results reported. The simple implantation of the ear at its original site as a compound graft usually leads to necrosis, with a total loss of the organ. Furthermore, loss of skin of the auricular region commonly occurs in these accidents, together with local contamination, a fact that ends up discouraging any attempt at immediate reconstruction. The severed ear may also suffer severe skin losses and deforming lesions of the cartilage, leading the surgeon to opt for discarding the organ.

We propose here the use of a platysma

myocutaneous flap for the reimplantation of a severed ear in two surgical steps.

CASES REPORT

Patients. Five patients who had suffered partial or total traumatic avulsion of an ear were seen at the emergency unit of the university hospital of the Faculty of Medicine of Ribeirão Preto, University of Sao Paulo. The characteristics of the patients are listed in Table 1. After the initial care provided for all polytraumatized patients, specific treatment was started for the preservation of auricular cartilage (AC).

Surgical technique. During the first operative phase, the severed ear was washed with 0.9% sodium chloride and disinfected with 10% polyvinylpyrrolidone iodine. The entire skin cover was then dissected and the ear was removed, with skeletonization of AC. When fractures or lesions of AC were present, they were corrected using colorless mononylon 5-0 sutures, thus establishing the original architecture of the organ. Exhaustive irrigation of the entire AC with 0.9% sodium chloride was then performed under pressure. After this preparation, the procedure of AC implantation in the supraclavicular fossa was started on the same side as the lesion.

An incision of approximately 8 cm was made in the supraclavicular fossa parallel to the clavicle and the platysma muscle was identified (Fig. 1, incision A). The skin of the region was detached from the muscle by blunt dissection until a pocket was created that could accommodate the AC, at a distance of at least 3 cm above the incision made in the skin. The AC was introduced so that its lateral surface faced the skin, hemostasis was revised, the skin was sutured with

simple stitches, a slightly compressive dressing was applied, and the procedure was terminated (Fig. 1).

The second surgical step was started after full patient recovery and full healing of the auricular region. The patient was then prepared for ear reimplantation.

The skin and platysma were sectioned along the entire length of the muscle by an incision on the supraclavicular scar of the first surgery (Fig. 1, incision A). Subplatysmal undermining was then performed along the covering fascia of the muscle until the lower margin of the mandible was reached. Another incision, only in the cervical skin immediately above the site of AC implantation, was then performed to create a skin ellipse at the site (Fig. 2, incision B). Using blunt dissection, the platysma skin was detached from incision B to the lower margin of the mandible. Incision A was then sutured to incision B with mononylon 5-0 sutures. Thus, the AC was enveloped by the skin in a pedicled island in the platysma muscle, with the construction of a compound platysma cartilage-muscle-skin flap (PCMSF) (Fig. 2). Another 8 cm incision (Fig. 3, incision C) was then performed at the site where the ear would be implanted, and the skin was detached from the auricular region to the previously undermined cervical region, forming an ample communication between areas.

The PCMSF was rotated 180° under the cervical skin and transported to the region of ear implantation (Fig. 3), where it was fixed with simple mononylon 5-0 sutures. The donor area was primarily closed with simple mononylon 5-0 sutures and a drain with continuous aspiration was introduced (Figure 4A).

Table 1 - Patient number, age, side of severed ear, date of accident, cause of avulsion and type of avulsion

Patient	Age	Side	Cause	Type
1	9 years	Right	Automobile accident	Total
2	11 years	Right	Dog bite	Partial (upper half)
3	24 years	Right	Automobile accident	Total
4	20 years	Right	Automobile accident	Total
5	19 years	Right	Automobile accident	Partial (upper two-thirds)

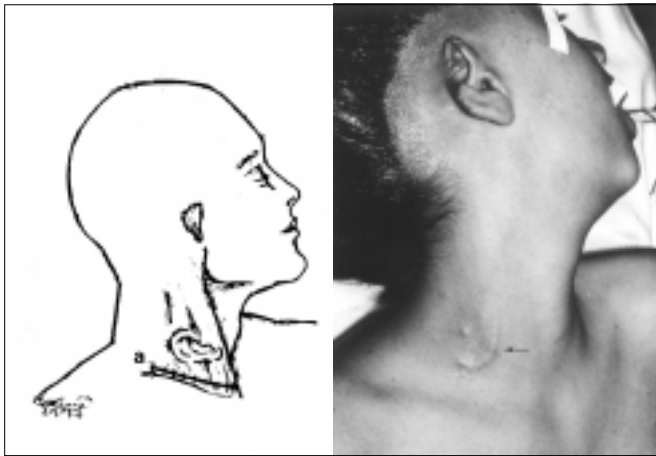


Fig. 1 - Preoperative stage of the second surgical step. Note the absence of the upper half of the patient's right ear, which is located in the supraclavicular fossa. 1-A: Schematic illustration of the incision used to introduce the auricular cartilage into the supraclavicular fossa. 1-B: Photograph of the auricular cartilage (arrow) under the cervical skin.

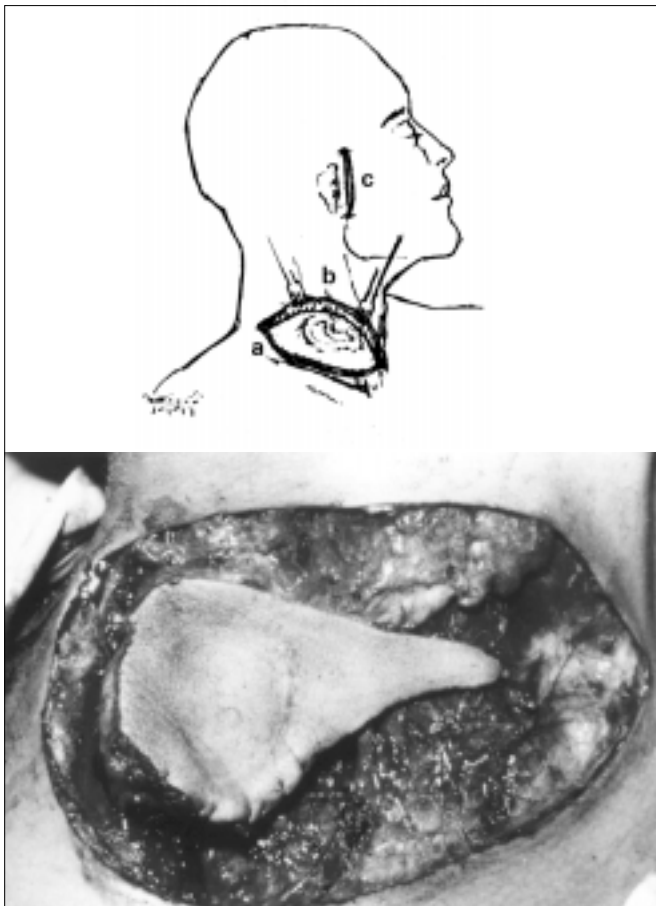


Fig. 2 - Intraoperative stage of the second surgical step. 2-A: Schematic illustration of the incisions (a, b and c) performed for PCMSF transfer from the supraclavicular region to the original site of the ear. 2-B: Close-up of the PCMSF before transfer.

Figure 4B show the results obtained after reimplantation of a totally severed and partially severed ear, respectively, using a PCMSF. The results are summarized in Table 2.

DISCUSSION

Several treatment modalities for fully or partially severed ears are currently being used. However, none of them appears to have solved the problem in a definitive manner. Successful simple repositioning of severed portions has been reported both in cases of partial^{1,2} and total³ losses. However, in clinical practice, success is rarely obtained with this procedure unless the severed segment has a reasonable skin pedicle. Of the five cases in which we used PCMSF, only one presented total necrosis after reimplantation (Table 2). This lack of success was attributed to a possible lesion of the dominant vascular pedicle of the platysma, consisting of the submental artery, a branch of the facial artery.⁴

Microsurgical ear reimplantation was first performed on a human being in 1980.⁵ Despite the excellent results reported and the natural aspect of a microsurgically reimplanted ear, the small caliber of auricular vessels implies great technical difficulties, which limit the method to specialized centers and selected cases. In an attempt to overcome the technical limitations of microsurgical anastomosis in the very fine vessels of the ear, Sucur et al⁶ proposed the implantation of deepithelialized AC into a subcutaneous pocket on the forearm, which has vessels of larger caliber, in order to facilitate the procedure of microsurgical transfer. With the use of a PCMSF we eliminated all the technical difficulties of

Table 2 - Patient number, time until flap transfer and final result

Patient	Time(months)	Final result
1	14	Reimplanted ear without complications
2	2	Reimplanted ear without complications
3	4	Reimplanted ear without complications
4	4	Total loss due to flap necrosis
5	4	Reimplanted ear without complications

microsurgery, thus permitting reimplantation of fully or partially severed ears in a procedure that can be executed in any emergency unit. Furthermore, the skin of the supraclavicular region is practically identical to that of the ear in terms of color, thickness and absence of hair, thus providing the natural aspect of the original shape by closely adapting to the varying relief of the AC.

The use of an external prosthesis should be limited to selected cases because of the inconvenience of fixation and exchange. Even bone-integrated prostheses should be limited to poorly cooperating patients who have no possibility of using their own cartilage, since the greatest disadvantage of the method is not using the tissue of the patient himself.⁷ With the PCMSF, only the patient's own tissue is used and in a definitive manner, with minimal sequels in the donor area, represented by a cervical scar.

The idea of saving a severed ear by keeping the cartilage skeleton for later positioning goes back quite a long time. The cartilage may be skeletonized and implanted into a skin pocket in the auricular region itself, or the variation proposed by Mladick et al.⁸ may be used, whereby the cartilage portion is buried without skeletonization but after dermabrasion. The problem with these techniques is that their execution requires the presence of intact skin in the ear region for implantation, or that the ear itself be covered with tegument. With the PCMSF, only the AC is used, being implanted into a pocket under the skin of the supraclavicular fossa. Thus, a skin loss in the ear region due to mechanical, thermal or chemical trauma or even due to severe local contamination does not prevent the use of this technique. Another disadvantage of burying the severed ear in the auricular region is its later repositioning. It is necessary to use skin grafts or flaps to cover the median surface of the AC, a fact that may cause distortions of the cartilage itself or scarring retractions that modify its positioning. Since the PCMSF has a long muscle pedicle, it can be easily implanted without tension. The skin of the supraclavicular region offers ample coverage of

the entire AC, covering its anterior surface only with a fine skin that perfectly fits the complicated folds of the AC, with no need for additional grafts

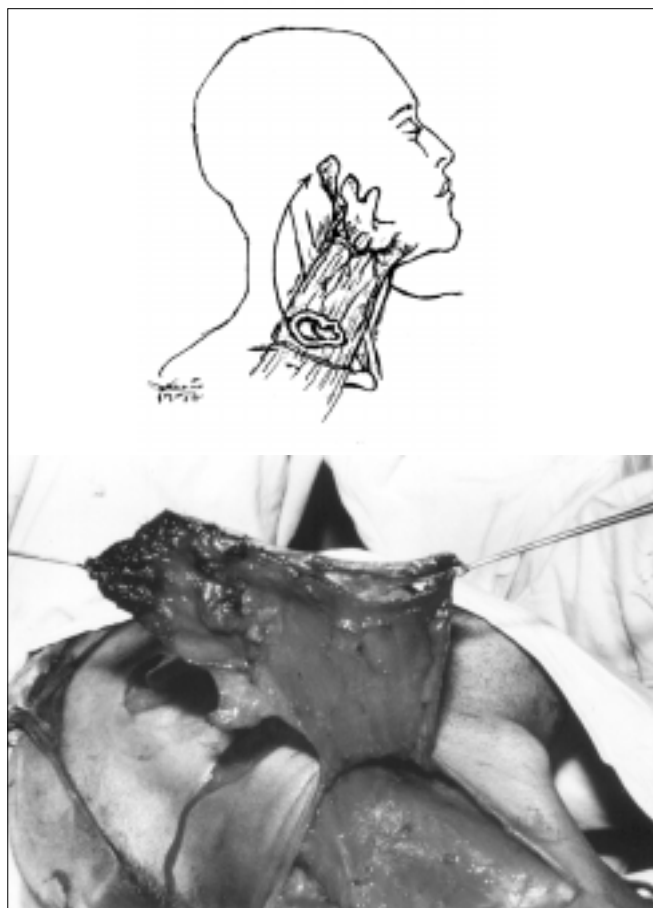


Fig. 3. Intraoperative stage of the second surgical step. 3-A: Schematic illustration of the 180° rotation performed with the PCMSF under the cervical skin. 3-B: Photograph of the PCMSF attached only to the mandible and ready for transfer.

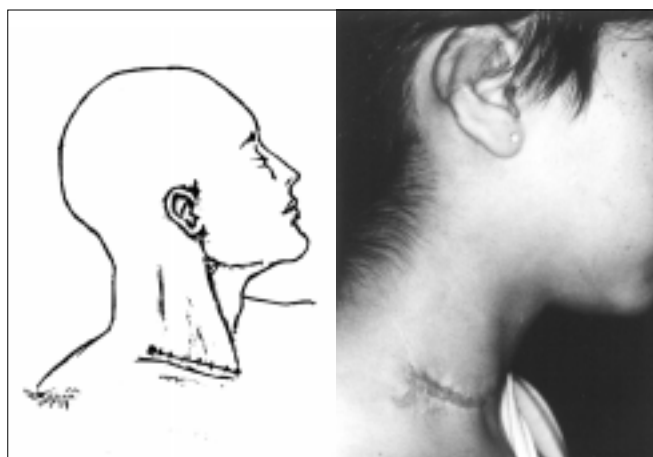


Fig. 4. Postoperative stage. 4-A: Schematic illustration of the PCMSF transferred to the site of the ear, with the donor area closed. 4-B: Final aspect of the procedure.

or flaps.

The platysma muscle is fixed to the posterior surface of the AC, guaranteeing a vascular supply and a generous amount of skin that insures its implantation free from hairs.

Although in the presented study we waited a long time before reimplanting the ears (Table 2), we believe that this long period of time is not necessary. The ability of a muscle to neovascularize cartilage has been well established. The study of neovascularization of the cartilage of the trachea with the sternohyoid muscle showed that safe neovascularization of the cartilage occurred after 21 days, permitting reimplantation after this time.⁹

After the pioneering study of Futrell et al¹⁰ using a myocutaneous platysma flap for intraoral reconstruction, this type of flap was successfully used for the reconstruction of other regions such as the lip¹¹ and trachea.¹² For ear reconstruction we found only one case published by Arian,¹³ in which the platysma myocutaneous flap was used as a "sandwich" with an outer muscle-cutaneous pedicle and tubulated to cover the auricular region that had lost the skin. The novel feature of the technique described here is the use of a platysma myocutaneous flap with a vascular pedicle in the facial artery and only a skin island at the end for receiving and neovascularizing the AC, which was later transported to the site of origin.

The surgical reconstruction of an ear is a difficult task and the results are poor. The fact that the final result looks like an ear only because of its location is discouraging.¹⁴ Thus, the AC of the patient should always be preserved to guarantee appropriate reconstruction.

The advantages of the use of a PCMSF for ear reimplantation are: the simplicity of surgical technique, which can be applied to totally or partially severed ears, dispensing with the need for microsurgical techniques and grafts; the possibility of saving the ear cartilage regardless of the conditions of the area of the ear itself; the provision of skin tissue identical to that of the ear; the achievement of a stable and adequate aesthetic result with the absence of hairs.

The disadvantages of the RCMPC are: the

need for two surgical steps; the occurrence of a scar in the supraclavicular donor region; the possibility of flap necrosis with a total loss of the implanted ear.

REFERENCES

1. Gilford GH Jr. Replantation of severed part of an ear. *Plast Reconstr Surg* 1972; 49:202-2.
2. Lewis EC II, Fowler JR. Two replantations of severed ear parts. *Plast Reconstr Surg* 1979; 64:703-5.
3. Salyapongse A, Maun LP, Suthunyarat, P. Successful replantation of a totally severed ear. *Plast Reconstr Surg* 1979; 64:706-8.
4. Hurwitz DJ, Robson JA, Futrell JW. The anatomic basis for the platysma skin flap. *Plast Reconstr Surg* 1983; 72:302-14.
5. Pennington DG, Pelly AD. Successful replantation of a completely avulsed ear by microvascular anastomosis. *Plast Reconstr Surg* 1980; 65:820-3.
6. Sucur S, Ninkovic M, Markovic S, et al. Reconstruction of an avulsed ear by constructing a composite free flap. *Br J Plast Sur* 1991; 44:153-4.
7. Wilkes GH, Wolfaardt JE. Osseointegrated alloplastic versus autogenous ear reconstruction: criteria for treatment selection. *Plast Reconstr Surg* 1994; 93:967-79.
8. Mladick RA, Horton CE, Adamson JE, et al. The pocket principle? A new technique for the reattachment of a severed ear part. *Plast Reconstr Surg* 1971; 48:219-23.
9. Mello-Filho FV, Mamede RCM, Velludo MASL. Tracheal neovascularization: a method involving mobilization of a complete tracheal neovascularization segment using a sternohyoid muscle flap. *Laryngoscope* 1996; 106:81-5.
10. Futrell JW, Johns ME, Edgerton MT, et al. Platysma myocutaneous flap for intraoral reconstruction. *Am J Surg* 1978; 136:504-7.
11. Mello-Filho FV, Mamede RCM. Reconstruction of the lower lip with a platysma myocutaneous flap. *Acta Oncol Bras* 1992; 12:119-22.
12. Mello-Filho FV, Mamede RCM, Sader AA, et al. Use of the platysma myocutaneous flap for cervical tracheal reconstruction: an experimental study in dogs. *Laryngoscope* 1993; 103:1161-7.
13. Arian S, Chicarelli ZN. Replantation of a totally amputated ear by means of a platysma musculocutaneous "sandwich" flap. *Plast Reconstr Surg* 1986; 78:385-9.
14. Brent B, Byrd SS. Secondary ear reconstruction with cartilage grafts covered by axial, random and free flaps of tempoparietal fascia. *Plast Reconstr Surg* 1983; 72:41-51.

Acknowledgments - We are grateful to Dr. Rodio Luis Brandão Camara, a postgraduate student in the Department of Surgery, Orthopedics and Traumatology of this Institution, for devising the illustrations used in the present paper.

Francisco Veríssimo de Mello-Filho - MD, PhD. Department of Surgery, Orthopedics and Traumatology, Faculty of Medicine of Ribeirão Preto, University of São Paulo.

Rui Celso Martins Mamede - MD, PhD. Department of Surgery, Orthopedics and Traumatology, Faculty of Medicine of Ribeirão Preto, University of São Paulo.

Adilon Passinho Koury - MD. Department of Surgery, Orthopedics and Traumatology, Faculty of Medicine of Ribeirão Preto, University of São Paulo.

Sources of funding: Not declared

Conflict of interest: Not declared

Last received: 16 November 1998

Accepted: 10 February 1999

Address for correspondence:

Francisco Veríssimo de Mello-Filho

Departamento de Cirurgia, Ortopedia e Traumatologia da

Faculdade de Medicina de Ribeirão Preto, USP

Ribeirão Preto/SP - Brasil - CEP 14049-900

E-mail: fdmfilho@fmrp.usp.br

RESUMO

Contexto: A perda da orelha por trauma produz inconformismo no paciente pela grave deformidade estética que acarreta. O formato característico da orelha, com uma fina pele de revestimento sobre uma delgada e elástica cartilagem, não pode ser encontrado em outros locais de nosso corpo. Portanto, para reconstruir uma orelha, resta aos cirurgiões a tentativa de imitá-la, esculpindo cartilagens e revestindo-as com pele. **Objetivos:** Utilizar o retalho miocutâneo do platísmo para reimplantação de orelha amputada em humanos. **Tipo de estudo:** Relato de casos. **Local:** Unidade de Emergência do Hospital das Clínicas da Faculdade de Medicina de Ribeirão Preto da Universidade de São Paulo. **Relato de casos:** Cinco pacientes foram operados, sendo reimplantada a orelha toda em três e, em dois casos, apenas segmentos. A técnica cirúrgica empregada é original, baseado no princípio da revascularização da cartilagem auricular pelo músculo platísmo. Implantamos a cartilagem auricular amputada no músculo platísmo, homolateral à amputação. Posteriormente, foi realizada a transferência da orelha pré-fabricada para seu local original sob a forma de retalho cartilágeno-músculo-cutâneo e descrita detalhadamente. Dos cinco casos tratados, obteve-se sucesso em quatro. A reimplantação da orelha não apresentou problemas com resultado estético muito próximo do natural. Em um caso ocorreu necrose de todo retalho com perda total da orelha. A técnica cirúrgica aplicada é simples e aproveita a própria orelha amputada do paciente. É excelente sua aplicação nas perdas de pele da região auricular ou da própria orelha, prescindindo-se da utilização de técnica microcirúrgica ou do uso de prótese ou enxerto. **Palavras-chave:** Retalho do platísmo. Retalho miocutâneo. Orelha amputada.