

Four cases of Chédiak-Higashi syndrome

Ana Paula de Azambuja¹
 Bárbara do Nascimento²
 Samuel Ricardo Comar³
 Gisele Loth⁴
 Lisandro Lima Ribeiro⁴
 Carmem Bonfim⁴
 Mara Pianovski⁵
 José Zanis Neto⁴
 Mariester Malvezzi^{1,4}

¹Imunofenotyping and Hematology Laboratory, Hospital de Clínicas, Universidade Federal do Paraná – UFPR, Curitiba, PR, Brazil

²Universidade Federal do Paraná – UFPR, Curitiba, PR, Brazil

³Hematology Laboratory, Hospital de Clínicas, Universidade Federal do Paraná – UFPR, Curitiba, PR, Brazil

⁴Bone Marrow Transplant Service, Hospital de Clínicas, Universidade Federal do Paraná – UFPR, Curitiba, PR, Brazil

⁵Pediatrics Department, Hospital de Clínicas, Universidade Federal do Paraná – UFPR, Curitiba, PR, Brazil

Chédiak-Higashi Syndrome (CHS) is a rare autosomal recessive disorder, with fewer than 500 cases published over the last 20 years.⁽¹⁾ The clinical features of this syndrome include partial oculocutaneous albinism, photosensitivity, grayish hair and skin,^(1,2) severe recurrent bacterial infections, bleeding diathesis and neurological manifestations (central and peripheral neuropathies, sensory loss, muscle weakness, cerebellar ataxia and cognitive impairment).^(1,3)

Mutations in the CHS1 (LYST) gene, located on the long arm of chromosome 1, result in a defect in granule morphogenesis in multiple tissues.⁽²⁾ This gene encodes a protein called the lysosomal trafficking regulator⁽³⁾ which regulates the synthesis, transport and fusion of cytoplasmic vesicles.⁽⁴⁾

The abnormalities observed in these vesicles result in grossly enlarged and non-functional lysosomes, which are identified at cytology as giant coalesced azurophilic granules present particularly in granulocytes and monocytes but also in fibroblasts, melanocytes, astrocytes, Schwann cells and hematopoietic cells.⁽³⁾ These granules are specific to CHS and their presence in granulocytes from peripheral blood or bone marrow is the basis for diagnosis.⁽⁴⁾

Patients are usually diagnosed at around the age of 5 years old. Two presentations of the

disease have been described: childhood and adult.⁽⁵⁾

Approximately 85% of the patients with the childhood form of the disease present the 'accelerated phase', characterized by lymphohistiocytic infiltration of liver, spleen, lymph nodes and bone marrow leading to fever, hepatosplenomegaly, lymphadenopathy and pancytopenia.⁽⁵⁾ Without early hematopoietic stem cell transplantation (HSCT), most of these patients die in the first decade of life due to the accelerated phase or severe infections.^(5,6)

The adult form is characterized by less severe clinical manifestations and neurological impairment may be the most prominent feature.^(5,6)

We reviewed four patients with CHS referred to the Blood Marrow Transplantation Department of the Hospital de Clínicas, Universidade Federal do Paraná.

The diagnosis of CHS was made on the basis of clinical characteristics and identification of the pathognomonic giant azurophilic granules in peripheral blood and bone marrow, which were seen in the cytoplasm of neutrophils, monocytes, eosinophils and lymphocytes (Figures 1 & 2).

Three patients presented with the childhood form of the disease with two of them being referred in the accelerated phase.

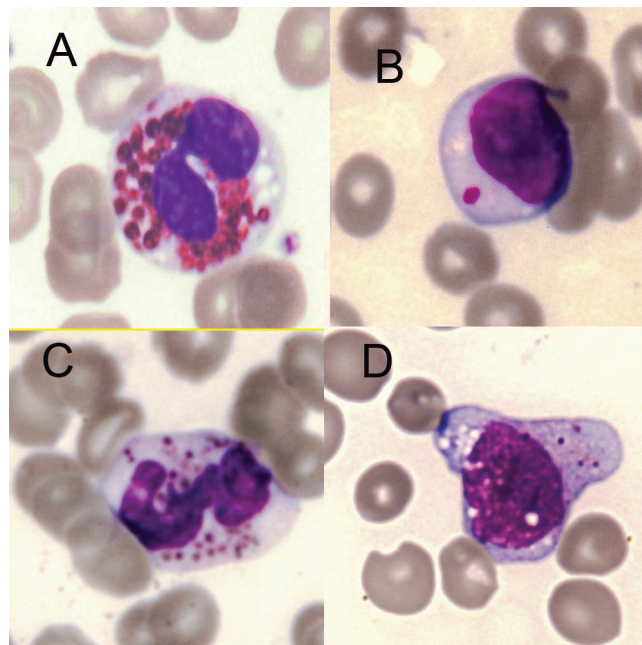


Figure 1 – Chédiak-Higashi Syndrome giant azurophilic granules in peripheral blood. A - Eosinophil; B - Lymphocyte; C - Neutrophil; D - Monocyte

Conflict-of-interest disclosure:
 The authors declare no competing financial interest

Submitted: 12/6/2010
 Accepted: 6/1/2011

Corresponding author:

Ana Paula de Azambuja
 Laboratório de Imunofenotipagem e Hematologia
 Hospital de Clínicas
 Universidade Federal do Paraná
 Rua Gal Carneiro, 181 – Alto da Glória
 80060-150 – Curitiba, PR, Brazil
 Phone: 55 41 3360-7998
 apazamb@gmail.com

www.rbhh.org or www.scielo.br/rbhh

DOI: 10.5581/1516-8484.20110084

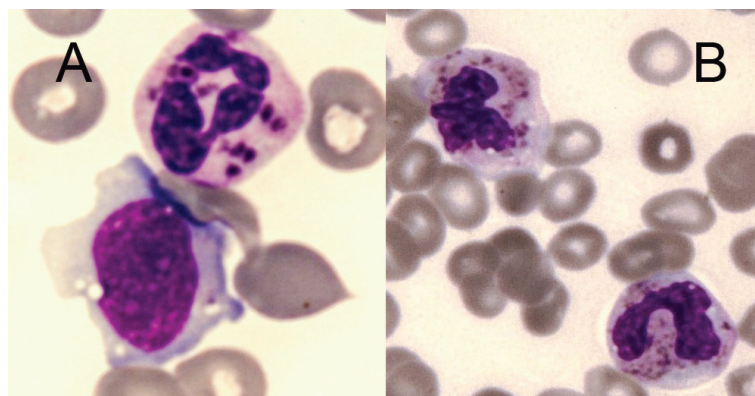


Figure 2 – Chédiak-Higashi Syndrome giant azurophilic granules. A - Neutrophil and Monocyte; B - Neutrophils

The first case, a 20-year-old woman, was diagnosed with CHS in the accelerated phase with pancytopenia, hepatosplenomegaly and peripheral neuropathy. She reported bruising, recurrent episodes of fever and had been submitted to red blood cell and platelet transfusions. Physical examination was remarkable for oculocutaneous albinism and grayish-silver hair, strabismus, hepatosplenomegaly, leg bruises, flaccid paraparesis and cognitive impairment. She had pancytopenia and giant azurophilic granules in neutrophils, lymphocytes and monocytes. Electromyography showed diffuse involvement of peripheral nerve fibers and sensory and motor polyneuropathy.

This patient represents a classic example of the adult form of the disease, presenting with neurologic dysfunction and delayed development of the accelerated phase. She was not submitted to HSCT and has received only transfusional support.

The second and third cases, four-year-old and one-year-old brothers born to consanguineous parents, were referred for HSCT due to widespread skin infections, grayish-silver hair and the presence of coarse azurophilic granules in the cytoplasm of neutrophils of peripheral blood.

The older boy presented with pancytopenia, marked hepatosplenomegaly and diffused skin abscesses, which required hospitalizations and intravenous antibiotic therapy.

The younger brother presented widespread skin infections, but had no hepatosplenomegaly nor received transfusions nor had been hospitalized previously.

Both patients were submitted to unrelated HSCT from a fully matched donor. Preparatory regimen included fludarabine (125 mg/m²) and antithymocyte globulin (rabbit ATG). Cyclosporine and a short course of methotrexate were given as prophylaxis for graft-versus-host disease (GvHD).

The older brother, transplanted in the accelerated phase, developed Grade II GvHD with skin involvement, which initially responded to methylprednisolone and Basiliximab, but later progressed to Grade IV GvHD with gut and liver involvement. He presented severe malnutrition and sepsis. Despite treatment, the patient developed multiple organ failure and died 89 days after transplantation. The younger brother, who was transplanted in the chronic phase, is well one year post transplant, with 100% of donor cells and normal blood counts.

The fourth case was a 3-year-old girl born to consanguineous parents who was referred for treatment in the chronic phase of the disease with grayish hair and albinism. The skin biopsy demonstrated

large grouped melanin granules. She has had skin infections but has never been transfused. An unrelated bone marrow donor is being sought.

Discussion

HSCT is the treatment of choice to correct hematological and immunological complications related to this disease but this therapy does not prevent the progressive neuropathy frequently observed during the long term follow up.^(3,6,7) Chemotherapy can induce transient remission in the accelerated phase, but relapses become less and less sensitive to treatment and eventually lead to death.⁽⁷⁾

HSCT was recommended for the three patients presenting the childhood form of the disease. Only the third patient had an excellent outcome, probably because the HSCT was performed in the chronic phase and there was an excellent donor available. Several reports of successful bone marrow transplantations performed in the chronic phase are found in the literature.^(7,8)

References

1. Kaplan J, De Domenico I, Ward DM. Chediak-Higashi syndrome. *Curr Opin Hematol.* 2008;15(1):22-9. Review.
2. Ward DM, Shiflett SL, Kaplan J. Chediak-Higashi syndrome: a clinical and molecular view of a rare lysosomal storage disorder. *Curr Mol Med.* 2002;2(5):469-77.
3. Olkkonen VM, Ikonen E. Genetic defects of intracellular-membrane transport. *N Engl J Med.* 2000;343(15):1095-104.
4. Shiflett SL, Kaplan J, Ward DM. Chediak-Higashi Syndrome: a rare disorder of lysosomes and lysosome related organelles. *Pigment Cell Res.* 2002;15(4):251-7.
5. Scherber E, Beutel K, Ganschow R, Schulz A, Janka G, Stadt U. Molecular analysis and clinical aspects of four patients with Chédiak-Higashi syndrome (CHS). *Clin Genet.* 2009;76(4):409-12.
6. Tardieu M, Lacroix C, Neven B, Bordigoni P, de Saint Basile G, Blanche S, et al. Progressive neurologic dysfunctions 20 years after allogeneic bone marrow transplantation for Chediak-Higashi syndrome. *Blood.* 2005;106(1):40-2.
7. Haddad E, Le Deist F, Blanche S, Benkerrou M, Rohrllich P, Vilmer E, et al. Treatment of Chediak-Higashi syndrome by allogeneic bone marrow transplantation: report of 10 cases. *Blood.* 1995;85(11):3328-33.
8. Eapen M, DeLaat CA, Baker KS, Cairo MS, Cowan MJ, Kurtzberg J, et al. Hematopoietic cell transplantation for Chediak-Higashi syndrome. *Bone Marrow Transplant.* 2007;39(7):411-5.