

Original Article

Antioxidant associated chemoprophylaxis effect of natural spice and green vegetable on hepatotoxicity

Efeito de quimioprofilaxia na hepatotoxicidade associada a antioxidantes de especiarias naturais e vegetais verdes

A. A. Raza^a, R. Mushtaq^b, S. Khwaja^{b*} , A. Akram^b , A. Karim^c  and A. Akhter^b

^aFederal Urdu University of Arts Science and Technology, Department of Biochemistry, Karachi, Pakistan

^bFederal Urdu University of Arts Science and Technology, Department of Zoology, Karachi, Pakistan

^cSardar Bahadur Khan Women's University Quetta, Department of Zoology, Balochistan, Pakistan

Abstract

This is a case control and cohort study, conducted at Department of Biochemistry in FUAJST, compressing 24 number of albino Wistar rats. *Illicium verum* (star anise) natural spice and green vegetable broccoli are used for chemopreventive herbal treatment in relation with vitamin C antioxidant activity. Hepatotoxicity was induced in liver of model rats by giving interperitoneally single injection of 200 mg/kg bod weight (B.W) of N-nitrosodiethylamine and orally giving 1 mg/kg BW phenobarbital for 14 days during disease prorogation period. The vitamin C analysis from *Illicium verum* (star anise), green broccoli, orange juice, orange peel and orange pulp was done by iodometric quantitative and qualitative titration method. Rats were given compound according to their bodyweight as 1 mg/kg B.W. After 14 days (Disease Promotion and Propagation Period) and 28 days (Disease cure period) of treatment behavioral activity was monitored by locomotors activity in open field experiment, stimulatory activity in home cage and anxiolytic effects observed in light and dark apparatus and also in T maze. Behavioral activity were significantly increased in *Illicium verum* and green broccoli treated rats. Hematological study including hemoglobin (Hb), white blood cells (WBC), red blood cells (RBC), mean corpuscular volume (MCV), mean corpuscular hemoglobin (MCH), mean corpuscular hemoglobin concentration (MCHC), red cell distribution width (RDW) and Platelets was done by abbot laboratory analyzer cell. The value of Hb and RBC was also significantly increased in star anise and broccoli treated rats, showed proper function of RBC in microcirculation. WBC was also in normal range revealed that no disease regards to bone marrow and leukemia's. The biochemical activity of rats including urea, creatinine, total protein, albumin, globulin, A/G ratio, amylase and calcium in blood serum were analyzed while, liver health or performance was also determined by LFT (liver function test). Behavioral and laboratorial variables were analyzed by using SPSS v. 20 and p-value < 0.05 was considered statistically significant. The study report noticeable significant effect of *Illicium verum* and broccoli on hepatotoxicity of experimental model. Recent experimental study statistical outcomes show reciprocal relationship between the consumption of vegetable diet and natural spice with the risk of Hepatotoxicity. Thus, the aim of the study is to enhance the function of star anise or *illicium verum* natural spice and green vegetable broccoli as an anticancer or chemoprophylaxis agent.

Keywords: chemoprophylaxis, hepatotoxicity, antioxidant, LFT.

Resumo

Trata-se de um estudo de caso controle e coorte, realizado no Departamento de Bioquímica da FUAJST, comprimindo 24 ratos albinos Wistar. A especiaria natural *Illicium verum* (anis estrelado) e o brócolis vegetal verde geralmente são utilizados para o tratamento fitoterápico quimiopreventivo por conta da atividade antioxidante da vitamina C. A hepatotoxicidade foi induzida no fígado dos ratos modelo por injeção única interperitoneal de 200 mg/kg de peso corporal (PC) de N-nitrosodietilamina e administração oral de 1 mg/kg de peso corporal de fenobarbital por 14 dias durante o período de prolongamento da doença. A análise da vitamina C de *Illicium verum* (anis estrelado), brócolis verde, suco de laranja, casca de laranja e polpa de laranja foi realizada pelo método de titulação quantitativa e qualitativa iodométrica. Os ratos receberam composto de acordo com seu peso corporal como 1 mg/kg B.W. Após 14 dias (Período de Promoção e Propagação da Doença) e 28 dias (Período de Cura da Doença) de tratamento a atividade comportamental foi monitorada por atividade locomotora em experimento de campo aberto, atividade estimulatória em gaiola e efeitos ansiolíticos observados em aparelhos claros e escuros e também em T Labirinto. A atividade comportamental foi significativamente aumentada em ratos tratados com *Illicium verum* e brócolis verde. O estudo hematológico incluindo hemoglobina (Hb), glóbulos brancos (WBC), glóbulos vermelhos (RBC), volume corpuscular médio (MCV), hemoglobina corpuscular média (MCH), concentração média de hemoglobina

*e-mail: sobia.khwaja@fuuast.edu.pk; sobia.khawaja@hotmail.com

Received: August 16, 2022 – Accepted: October 28, 2022



This is an Open Access article distributed under the terms of the Creative Commons Attribution License, which permits unrestricted use, distribution, and reproduction in any medium, provided the original work is properly cited.

corpúscular (MCHC), largura de distribuição de glóbulos vermelhos (RDW) e Plaquetas foi feito pela célula do analisador de laboratório Abobot. O valor de Hb e RBC também foi significativamente aumentado em ratos tratados com anis estrelado e brócolis, mostraram função adequada de RBC na microcirculação. WBC também estava na faixa normal revelando que nenhuma doença relaciona-se à medula óssea e leucemia. A atividade bioquímica de ratos, incluindo uréia, creatinina, proteína total, albumina, globulina, razão A/G, amilase e cálcio no soro sanguíneo foram analisadas, enquanto a saúde ou desempenho do fígado também foi determinada por LFT (teste de função hepática). As variáveis comportamentais e laboratoriais foram analisadas pelo SPSS v. 20 e valor de $p < 0,05$ foi considerado estatisticamente significativo. O estudo relata efeito significativo perceptível de *Illicium verum* e brócolis na hepatotoxicidade do modelo experimental. Resultados estatísticos de estudos experimentais recentes mostram relação recíproca entre o consumo de dieta vegetal e tempero natural com o risco de hepatotoxicidade. Assim, o objetivo do estudo foi potencializar a função do anis estrelado ou da especiaria natural *Illicium verum* e do brócolis vegetal verde como agente anticancerígeno ou quimioprotetor.

Palavras-chave: quimioprotetor, hepatotoxicidade, antioxidante, LFT.

1. Introduction

In human body liver is main center of detoxification and play a vital role in performance, maintenance and regulation of homeostasis. It is involve with the entire biochemical pathway to growth, fight against disease, nutrient supply, energy provision and reproduction. Liver has storage, filtration, excretory and metabolic function. During transformation and clearance of certain chemicals these chemicals accumulate in liver and cause liver injury and inflammation necrosis, fibrosis and hepatocellular degeneration i-e hepatotoxicity. These chemicals present in certain medicines, laboratories, industries, herbal and natural remedies, these are known as hepatotoxian. Hepatotoxicity is a condition Globally 700,000 death documented annually by liver cancer in which Hepatotoxicity is main attributing factor. Hepatotoxicity is 5th leading cause of hepatic cancer in men and eight in women. Since from ancient time phyto chemical present in plant kingdom and these active compound gifted with potent anti-inflammatory and anti-oxidative property were used to treat various fatal diseases without any side effects (Suresh et al., 2020).

Free radicals have been associated with pathogenesis of various disorder like cancer, diabetes, auto immune diseases and neuro degeneration disorder. Antioxidant prevents the damaging effect produce by free radicals by reducing oxidative stress (Yadav and Bhatnagar, 2007). A number of health benefits of *Illicium verum* were reported in various previous studies, using in many tradition medicines stomachic, antiseptic, anti-spasmodic, carminative, digestive, expectorant stimulant and tonic (Padmashree et al., 2007). In the light of previous study *Illicium verum* also used to prevent oxidative stress viral infection, flu and bacterial infection (Bradley, 2005) due to presence of anethole, Skhemic Acid (Misra and Dey, 2013), Flavanoids, Phenolic Acid, Vitamin C and Vitamin A (Nutrition-And-You.com, 2022), Vitamin C exhibit potent natural antioxidant activity. Dozens of studies have been made on Green Broccoli that show the magical effect of broccoli in prevention of various fatal diseases including cardio vascular diseases, hepatotoxicity, hepatic cancer, bladder, breast, colon and lung cancer (Morsy et al., 2010) because of presence of antioxidant compounds (Fahey, 2006; Gioia et al., 2017). Phenobarbital is the member of barbiturate family used in the treatment of many medical disorders like seizure and epilepsy (Kwan and Brodie, 2004) but it also shows some worse side effects including

allergic reaction, hypersensitivity, fever, rash, edema, hepatic toxicity, hepatic cancer, jaundice and hepatic failure (Mcgeachy and Bloomer, 1953). Our study is based on to produce natural herbal means of treatment and cure of liver diseases by using natural antioxidant present in green vegetable and in spices.

2. Materials and Methods

2.1. Experimental animals

Study carried out by using four groups of rats. Four group of rats are Albino Wistar weighing 160 (C) gm, 155 (T), 150 (T₁) and 150 (T₂) gm were purchased from Dow University and Hospital, Ojha campus, Karachi for the experimental research study. They were house individually in rat cage in animal house Federal Urdu University Karachi with relatively food and water. The duration of study was 14 days disease propagation periods + 28 days treatment periods.

2.2. Plant materials

The *spice Illicium verum* purchase from herbal stock store. Stock up at airtight bottle keeps away moisture and sunlight. Broccoli looks the greenish of the leaves that are deep green, crisp and unblemished. Root are cut after buying and store broccoli in separate plastic bags and air precaution that are not enter into bags. Refrigerate the Broccoli for about 4 days.

2.3. Extract

Illicium verum and green broccoli converted into fine partials (powdered) by mechanical grinder, and then this spice powder was dissolved in ethanol 40% by mix 40 mL ethanol into 100 mL water and 0.9% saline solution separately for purpose of extraction. After two days ethanol and saline extract filter by filter paper. The extract filtrate put into eppendorf. Both the saline and ethanolic extract of spice compounds were made to perform antioxidant activity on rats in contrast of Vit.C analysis.

2.4. Estimation of Vit.C by iodometric titration

Vit.C concentration in *Illicium verum* (saline and ethanol) and broccoli (saline and ethanol) extract was determined by iodometric titration method (Kabasakalis et al., 2000), which is a volumetric analysis in comparison with fresh

orange juice 200 mL, orange pulp 188gm and orange peel 88gm.

2.5. Administration of saline

In 1st segment of experiment, 1 mL saline received by rats orally for 14 days.

2.6. Administration of drug

In 2nd section, initiation of Hepato-carcinogenesis was performed by a single injection of Diethylamine (200 mg/kg, intraperitoneally) and Phenobarbital (ZINOBI) received by rats orally at a dose of 1 mg/g.kg B.W. for 14 days (Zahid et al., 2015).

2.7. Administration of extraction

In 3rd segment of experiment, Phenobarbital (ZINOBI) received by rats orally at a dose of 1 mg/.kg B.W for 14 days and Illicium verum saline extract for 28 days. In 4th section, Phenobarbital (ZINOBI) received by rats orally at a dose of 1 mg/kg B.W for 14 days and green Broccoli every day for 28 days. After received doses by rats, we perform behavioral and memory activity by instrument analysis.

2.8. Experimental protocol

Study carried out by using 24 Albino Wistar rats was purchased from Dow University and Hospital Ojha Campus. Karachi. They were housed individually in rat's cage in animal house of FUUAST. The duration of study was (14+28) days. 14 days disease propagation period and 28 days consider as cure and treatment time. Experimental model were divided into four treatment groups in each group 6 rats are included which are as follows: Group I: control group subjected to saline treatment 14 days as C. Group II: Test group, NDEA 200 mg/kg BW [1] single injection + phenobarbital (ZINOBI) treatment (14 days) as T. Group III. NDEA, Phenobarbital (ZINOBI) 14 days + saline extract containing compound (Illicium verum) 28 days as T₁. Group IV: NDEA, Phenobarbital (ZINOBI) 14 days + vegetable (Green Broccoli) 28 days as T₂. Drug was given to all rats as 1 mg/kg BW [1] because of separate body weight and time duration drug samples were prepared separately. After receiving doses by rats behavioral activity was performed by instrument analysis. Behavioral activity was monitor after one week of treatment, for ten minutes in light and dark environment. Light and dark activity is specific for anxiety this apparatus is used in light and dark experiment consisted of small square area (26×26×26 cm) with an access (1×12 cm) walls of one compartment was transparent and other dark. For the next five minutes the activity was monitored in the open field and the open field apparatus consists of square area (76×76 cm) with walls of 42 cm high. The floor divided by lines into 25 equal squares. Ten minutes in home cage specially designed made up of Perspex (26×26×26cm) with dust covered floor was used for this purpose. Last ten minutes in Plus T maze shaped apparatus used for screening of antiangiogenic and anxiolytic drugs, which have two open and closed arms each have open tool and elevated 40–70 cm from the floor. Number of entries and time spent in open arm are the anxiolytic

drugs effect. After monitoring these activities, the animals returned to their cages. Rats were decapitated after 14 (C and T) and 28 days (T₁ and T₂) of experimental treatment. The blood was collected from laceration on neck in the EDTA tubes for hematology.

All hematological tests has done in abbot laboratory analyzer cell while, blood in the Yellow top gel tubes, centrifuges to collect plasma for biochemical analysis. Biochemical analysis was done with the help of kits in laboratory on HSP system by Merck Company.

3. Results

A total of 24 rats (n=6) were studied. Comparisons were made between different groups of rats as per their treatment. All Results were represented in table and as mean, ± S.D, significant difference by Tukey HSD and Duncan test p<0.05, following one-way ANOVA. After iodometric titration results were found according to which Orange Peel in 89 gm, Vit.C concentration was more than Orange juice and Orange pulp. After Orange Peel, Orange Juice in 20 mL and Orange Pulp in 188 gm contain same conc. of Vit.C. It also revealed that 0.1 mL of Ethanol + Illicium Verum contain less value as compared to 0.1 mL Saline + Illicium Verum, values showed that Vit.C was more in Saline + Illicium Verum as compared to Ethanol + Illicium Verum. In the eye of result analysis determined that in 89 mg of Orange Peel conc. was equal to saline + Illicium Verum in 0.1 mL. Saline extract of broccoli contain 0.085mg Vit.C concentration (Figure 1).

3.1. Biochemical analysis

3.1.1. Liver function test

Urea and Creatinine are showing normal in Control, T₁ and T₂ but show level of elevation in T group of Rats. Amylases are in normal limit in Control, T₁ and T₂ but show slightly low level in T group of Rats. Alkaline phosphates are increases in T as compare to control, T₁ and T₂. SGPT show high level in T group of animals but normal level in control, T₁ and T₂. Total and Direct Bilirubin show high level in T group of Rats but normal in Control, T₁ and T₂. SGOT show elevation level in T group of Rats but show

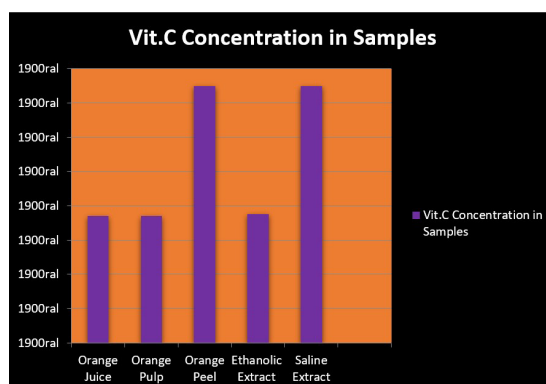


Figure 1. Shows vitamin C concentration in different medium.

normal level in Control, slightly elevated level are seen in T₁ and T₂ group of Rats. Gama GT is in normal range in Control, T₁ and T₂ but show elevation level in T group. Total proteins are in normal range in Control and T₂ but show low level in T group of Rats. Calcium level is normal in Control but show low level in T, T₁ and T₂. Albumin level decrease in T as compare T₁, T₂ and Control. Globulin is in normal range in control but decrease in T, as compare to T₁ and T₂. A/G ratio is in limit in control but show decline level in T as compare to T₁ and T₂ (Table 1 and 2).

3.1.2. Hematological analysis

Hb level is in limit in Control, T, T₁ and T₂. WBC is in limit Control, T, T₁ and T₂. Platelet is in normal range in Control but show decrease level in T as compare to T₁ and T₂. RDW in % is in normal range in Control and T and increase in T₁ and T₂. MCV in normal range in Control but decrease in T, T₁ and T₂. MCH decrease in Control and T but more declines in T₁ and T₂. RBC decrease in Control but in limit of T and increase in T₁ and T₂. T₂ is more elevate than T₁ (Table 3).

3.1.3. Behavioral study

T value decline in as compare to initial days. T₁ cross more boxes in last week as compare first and second week. T₂ cross more boxes in last week as compare first and 2nd week. T₂ and T₁ reading of crossing box last week is equal (Table 4).

T entry and spent time in light box increase in initial days as compare to last days. T rate decline as compare to control. T₁ at last week increase time spent and entry in light box as compare to its 1st week. T₂ at last week increase time spent and entry in light box as compare to other its week. T₁ more time spent in light as compare to T, T₂ and control (Table 4).

T value decrease in last days of activity in which walking, climbing and head moving include. T₁ rate increase at last week in walk decrease in last week as compare to 2nd week. No head movement occurs. Climbing rate increases in last weeks. T₂ value of walking increase in last week as compare to 2nd week and decrease in 1st week. Head movement decrease in last week and climbing rate increase in last week. T₂ walking rate increase in last week as compare to T₁ and T. Climbing rate in last week is increase in T₁ as compare T₂ and T (Table 4).

T decline rate in last week in open arm and entry also zero at last. T₁ time spent and entry in open arm in last week increases as compare to other weeks. T₂ time spent in open arm decline in last week as compare to 2nd week and entry also decreases. T₁ entry and time spent in open arm is more than T₂ and T (Table 4).

4. Discussion

In the light of recent experimental work which based on both control and cohort study we significantly stated that

Table 1. Comparison of mean value of Biochemical results in Control, T, T₁ and T₂.

Biochemical Parameters Results	Mean ± S.D Control	Mean ± S.D T	Mean ± S.D T ₁	Mean ± S.D T ₂	f-Value	p-Value
Urea (mg/dl)	10 ± 1.414	29 ± 2.581	14 ± 1.940	12 ± 1.870	276.62	P < 0.0002*
Creatinine (mg/dl)	0.48 ± 0.211	1.2 ± 0.427	0.54 ± 0.527	0.50 ± 1.054	140.74	P < 0.0002*
Total Protein (mg/dl)	6.2 ± 1.734	2.0 ± 1.035	4.0 ± 1.454	4.5 ± 1.355	896.75	P < 0.0001*
Albumin (mg/dl)	4.5 ± 1.372	1.5 ± 0.533	3.0 ± 1.289	3.5 ± 0.961	468.75	P < 0.0002*
Globulin (mg/dl)	3.5 ± 0.961	1.1 ± 0.440	3.2 ± 1.289	3.09 ± 0.509	471.23	P < 0.0002*
A/G RATIO	2.0 ± 1.170	4.822 ± 1.471	1.31 ± 0.900	1.92 ± 1.028	2340.315	P < 0.0002*
Amylase (U/l)	120 ± 14.014	88 ± 9.717	100 ± 2.366	102 ± 1.940	523	P < 0.0001*
Calcium (mg/dl)	10 ± 1.500	5.5 ± 1.002	6.85 ± 1.286	7.0 ± 1.773	1421.41	P < 0.0001*

Table 2. Comparison of mean value of Liver Function test in Control, T, T₁ and T₂.

Liver function test parameter	Mean ± S.D Control	Mean ± S.D T	Mean ± S.D T ₁	Mean ± S.D T ₂	f-Value	p-Value
Total bilirubin (mg/dl)	0.59 ± 0.664	2.28 ± 0.552	0.60 ± 0.733	0.73 ± 0.564	10.04	P < 0.0003*
Direct bilirubin (mg/dl)	0.10 ± 0.072	1.72 ± 0.394	0.413 ± 0.423	0.43 ± 0.530	18.11	P < 0.0002*
SGPT (U/L)	18 ± 0.646	80 ± 0.972	40 ± 1.099	40.33 ± 1.586	3120.9	P < 0.0002*
ALP (U/L)	79.9 ± 3.685	511 ± 15.892	98.60 ± 2.586	100.7 ± 1.938	3948.92	P < 0.0001*
SGOT (U/L)	36.06 ± 1.545	233 ± 4.226	102 ± 3.001	99 ± 4.707	4864.15	P < 0.0001*
Gama GT (U/L)	8 ± 1.550	50 ± 6.207	12 ± 0.950	10 ± 0.767	248.48	P < 0.0001*

Table 3. Comparison of mean value of Hematology in Control, T, T₁ and T₂.

Hematological Parameter	Mean ± S.D Control	Mean ± S.D T	Mean ± S.D T ₁	Mean ± S.D T ₂	f-Value	p-Value
Hb (gm/dl)	10.48 ± 0.696	12.60 ± 0.473	11.35 ± 2.654	11.00 ± 1.252	2.05	P < 0.0001*
WBC (U/L)	4.23x10 ³ ± 0.842	6.04x10 ³ ± 0.536	5.07x10 ³ ± 0.644	5.09x10 ³ ± 0.906	5.91	P < 0.0001*
Platelet (/ul)	155x10 ³ ± 10.787	104x10 ³ ± 19.608	159x10 ³ ± 11.851	158x10 ³ ± 11.821	9.42	P < 0.0004*
RDW%	12.0 ± 1.654	15.9 ± 1.994	14.6 ± 2.109	14.6 ± 1.781	3.25	P < 0.004*
MCV (fl)	70 ± 20.082	45 ± 5.787	44 ± 3.669	46 ± 7.756	7.22	P < 0.0001*
MCH (pg)	27 ± 1.414	23 ± 2.588	20 ± 1.414	20 ± 3.016	12.63	P < 0.0001*
MCHC (g/dl)	26 ± 2.160	45 ± 2.160	40 ± 1.414	37 ± 1.471	117.18	P < 0.0001*
RBC'S (/ul)	3.0 x 10 ³ ± 1.264	4.50 x 10 ³ ± 1.048	5.30 x 10 ³ ± 1.716	5.20 x 10 ³ ± 1.729	3.2	P < 0.004*

Table 4. Comparison of mean values of Behavioral Results in Control, T, T₁ and T₂.

Behavioral Activity	Mean ± S.D Control	Mean ± S.D T	Mean ± S.D T ₁	Mean ± S.D T ₂	f-Value	p-Value
Light and Dark (No of Entries)	5 ± 0.353	2 ± 0.353	3.5 ± 0.707	4 ± 0.141	36.825	P < 0.0001*
Light and Dark (Time in Seconds)	25 ± 0.070	15 ± 0.212	22.5 ± 0.636	21 ± 0.494	2004	P < 0.0002*
Home Cage Activity (Walk in Seconds)	8 ± 0.424	6 ± 0.777	11 ± 0.141	10.5 ± 0.353	1501	P < 0.0001*
Home Cage Activity (Movement of Head in Seconds)	2 ± 0.565	1 ± 0.212	3 ± 0.636	3.5 ± 0.282	420	P < 0.0001*
Home Cage Activity (Climbing in Seconds)	2 ± 0.565	1 ± 0.212	3.5 ± 0.707	2 ± 0.565	540	P < 0.0001*
Open Field Activity (No of Entries in Cross Box)	28 ± 0.777	20 ± 0.070	32.5 ± 0.494	27.5 ± 0.141	2001	P < 0.0001*
Plus T Maze Activity (Entries in Open Arms in Seconds)	6 ± 0.777	2 ± 0.565	7 ± 0.494	6.5 ± 0.353	5.887	P < 0.0001*
Plus T Maze Activity (Time Spent in Open Arms in Seconds)	240 ± 0.141	48 ± 0.636	175 ± 0.919	145 ± 0.848	3284	P < 0.0002*

antioxidant activity of naturally occurring spice (*Illicium verum*) and green vegetables exert chemoprophylaxis effect on hepatotoxicity which is the prominent leading cause of hepatic cancer and primary hepatic cancer i.e. hepatocellular carcinoma. Verity of risk factor are reported that attribute the production of hepatocellular carcinoma. Likewise free radicals are one of the byproduct of oxygen utilized by each and every living cells of body. These substances produce damaging effect on cellular body through oxidation. Through oxidation free radicals that cause HCC first caused DNA damaged and then radicals combine with histological fibrosis. DNA damage used by oxygen free radicals and DNA repair system high accumulation of cancer related gene mutation. The antioxidant present in spice and green vegetable neutralized free radicals that cause cellular damaged and cancer. In HCC the tissue of hepatic cells show various degree of degeneration and hepatic parenchyma cells also show various abnormal damage and proliferation. Vit.C has potent antioxidant activity towards free radicals. A number of previous studies including both case control, cohort, prospective, epidemiologic, have been done to

explore the magical effect of vegetable and natural spice on development propagation promotion of cancer including pancreatic cancer, prostate cancer, lungs cancer, hepatic cancer, bladder cancer and GIT cancer (Yadav and Bhatnagar, 2007; Zahid et al., 2015; Chandra and Viswanathswamy, 2018; Bohn et al., 2014). These current study results we evaluate the concentration of Vit.C in spice and green vegetables extracts by unique volumetric analytical iodometric method of titration. These unique qualitative and quantitative analysis clearly show that orange peel extract and saline extract of *Illicium verum* give high amount of Vit.C that relates the high antioxidant activity. The unveil results clearly show the reflection of these statements that increase the uptake of nutrients containing potent antioxidant activity reduce the risk of carcinomas. So that's why orange peel and *Illicium verum* saline extract have high potential against oxidation reduction reactions and used for oxidative stress (Padmashree et al., 2007). Orange peel in 88 mg exhibit high antioxidant activity in contrast to orange juice and orange pulp. Whereas the 20 mL sample of orange juice and 188 mg orange pulp have the same concentration of Vit.C which show equal

antioxidant activity. The P value obtained with regard to all fraction of T₁ and T₂ are found to be highly significant. Biochemical parameters of estimation analysis revealed that hypo-amylasia which give reason of pancreatic damaging and inflammation of pancreatic cells because Phenobarbital create toxicity and inflammatory lesion on pancreas in support of this clinical observation (Yadav and Bhatnagar, 2007).

The P value show high level of UREA and CREATININE T group of rats are due to the fact that then liver cells are damage not clear this nitrogen containing compound from the body through kidney so the high level of this compound are make in blood similarly are observed in previous study (Yadav and Bhatnagar, 2007). High level of alkaline enzymes of liver reveled the damaging of liver. Broccoli eating group of test animal T₂ and Illicium verum treated group of animals T1 show normal level of alkaline enzymes of liver which is complimentary to previous study. SGPT level in the blood are normally low if liver cell are subjected to damage and inflamed it will release more SGPT in the blood and finally lead to high level of SGPT in blood. This condition mean liver cannot perform function properly. Phenobarbital induces liver damage which ultimately increases the level of SGPT in blood of test animal as it is previous evidence (Zahid et al., 2015). The P value of Bilirubin is show level of significance in T₁ and T₂ fraction but show reduce in significance level in test animal treated with Phenobarbital that induce liver damage so liver cannot clear Bilirubin properly and its level are raised in blood, supportive evidence of previous study (Yadav and Bhatnagar, 2007). The SGOT enzyme that is normally present in liver and heart cells. SGOT is released into blood when the liver or hearts are subjected to any abnormalities, damage and inflammation. An increase level of SGOT have been reported in Phenobarbital treated test model but SGOT level show level of significance in T₁ and T₂ test model of animal because of intake of broccoli and Illicium verum intake this result make inter link relationship with previous study (Yadav and Bhatnagar, 2007; Chandra and Viswanathswamy, 2018). Gama GT has been show level of significance in T1 and T2 but also show some degree of normal limit in T group of animal. Abnormalities in albumin and globulin protein level also seen in T, T₁ and T₂ test animals because of dysfunctioning of liver due to Phenobarbital effect on hepatic cells accordance to previous study (Chandra and Viswanathswamy, 2018). Hypocalcaemia also seen in T, T₁ and T₂ which reveal the reason of decrease Vit. D production due to hepatic injury or inflammation because Vit. D involve in the absorption of calcium in body. The level of calcium in T group of animals showed decline level but not in T₂ and T₁ because of intake of Illicium and broccoli (Ambrosone and Tang, 2009). In blood cells profile of experimental rats' show that hemoglobin is in normal range because there is no effect exerts RBC synthesis. White blood cells are in normal limits because there is no disease relate to bone marrow and leukemia. Decrease level of platelets occur in T group Rats due to Thrombocytopenia in liver cancer because decrease production of hormone thrombopitin or increase destruction of platelets through phagocytosis. MCH show decline level in all groups of test models

which show that iron deficiency. MCV also show decrease level leaving behind the reason microcytosis and iron deficiency anemia MCHC have been reported in normal limits because there is no suppression in hemoglobin level seen due to green broccoli and Illicium verum. High level of RBCs reflects on the fact that T₁ and T₂ animals get dehydrated due to low oxygen level. In previous study Illicium verum show high potential of anti-cancer agent (Garzo Fernández et al., 2002).

Our current study result support of this clinical observation Morsy et al (2010) purposed potential chemo-preventive agent broccoli in hepatic cancer. Another prior study concluded by Finley (2003). Those effective chemo-preventive roles of broccoli in hepatic cancer similarly current study result agree with this early report. The Bio markers in all the mention studies are Hematological screening liver function tests and biochemical analysis and in our fresh study support the results of previous studies that explore chemo-preventive role of naturally occurring spices, fruits and vegetables. Home cage box activity show suppressive effect in T animals because of reduce stimulant activity home cage activity in T₂ rats was noticed to be declined as compare to 2nd week leaving the reason behind disease does not propagate completely. Stimulatory activity was observed in T₂ group of rats by observing walking and head moments because broccoli increase stimulant activity as compared to Illicium verum that have also show some degree of increase CNS activity. Motor activity are seen increasing in both T₁ and T₂ but show some degree of reduce level in Phenobarbital treated T test group. Motor activity is observed in open field activity. The behavior activity observed in T maze show that anxiolytic effect in T₁ test model whereas T group of animals show anxiogenic effect because of anxiety effect rats spend more time into close arm as compare to open arms. But the rats of T₁ and T₂ spend more time in open arms because of anti-anxiety effect of Illicium verum and green broccoli. Same phenomena of observation are report in light and dark box activity because of anxiolytic effect of Illicium and green broccoli in T₁ and T₂ group of animals. The rats of T₁ and T₂ spend more time in light box whereas the rats of T group of rats spend more and more time in dark box. Illicium verum and broccoli give an idea about cure of anxiety by natural means.

5. Conclusion

Our recent experimental study reflects the light on the fact that reciprocal relationship between the consumption of vegetable diet and natural spice with the risk of liver diseases i.e. hepatotoxicity, hepatocellular carcinoma has been established and the treatment of hepatotoxicity is possible using naturally occurring antioxidant containing spice and green vegetable without any side effects.

References

AMBROSONE, C.B. and TANG, L., 2009. Cruciferous vegetable intake and cancer prevention: role of nutrigenetics. *Cancer*

- Prevention Research*, vol. 2, no. 4, pp. 298-300. <http://dx.doi.org/10.1158/1940-6207.CAPR-09-0037>. PMID:19336722.
- BØHN, S.K., BLOMHOFF, R. and PAUR, I., 2014. Coffee and cancer risk, epidemiological evidence, and molecular mechanisms. *Molecular Nutrition & Food Research*, vol. 58, no. 5, pp. 915-930. <http://dx.doi.org/10.1002/mnfr.201300526>. PMID:24668519.
- BRADLEY, D., 2005. Star role for bacteria in controlling flu pandemic? *Nature Reviews. Drug Discovery*, vol. 4, no. 12, pp. 945-946. <http://dx.doi.org/10.1038/nrd1917>.
- CHANDRA, Y.P. and VISWANATHSWAMY, A.H.M., 2018. Chemopreventive effect of Rutin against N-nitrosodiethylamine-induced and phenobarbital-promoted hepatocellular carcinoma in Wistar rats. *Indian Journal of Pharmaceutical Education and Research*, vol. 52, no. 1, pp. 78-86. <http://dx.doi.org/10.5530/ijper.52.1.9>.
- FAHEY, J., 2006. *Method of extraction of isothiocyanates into oil from glucosinolate-containing plants and method of producing products with oil containing isothiocyanates extracted from glucosinolate-containing plants*. U.S. Patent Application 11/302,118.
- FINLEY, J.W., 2003. Reduction of cancer risk by consumption of selenium-enriched plants: enrichment of broccoli with selenium increases the anticarcinogenic properties of broccoli. *Journal of Medicinal Food*, vol. 6, no. 1, pp. 19-26. <http://dx.doi.org/10.1089/109662003765184714>. PMID:12804017.
- GARZO FERNÁNDEZ, C., CÓMEZ PINTADO, P., BARRASA BLANCO, A., MARTÍNEZ ARRIETA, R., RAMÍREZ FERNÁNDEZ, R. and RAMÓN ROSA, F., 2002. Cases of neurological symptoms associated with star anise consumption used as a carminative. *Anales Espanoles de Pediatria*, vol. 57, no. 4, pp. 290-294. PMID:12392661.
- GIOIA, F.D., RENNA, M. and SANTAMARIA, P., 2017. Sprouts, microgreens and "baby leaf" vegetables. In: F. YILDIZ and R. WILEY, eds. *Minimally processed refrigerated fruits and vegetables*. Boston: Springer, pp. 403-432. http://dx.doi.org/10.1007/978-1-4939-7018-6_11.
- KABASAKALIS, V., SIOPIDOU, D. and MOSHATOU, E., 2000. Ascorbic acid content of commercial fruit juices and its rate of loss upon storage. *Food Chemistry*, vol. 70, no. 3, pp. 325-328. [http://dx.doi.org/10.1016/S0308-8146\(00\)00093-5](http://dx.doi.org/10.1016/S0308-8146(00)00093-5).
- KWAN, P. and BRODIE, M.J., 2004. Phenobarbital for the treatment of epilepsy in the 21st century: a critical review. *Epilepsia*, vol. 45, no. 9, pp. 1141-1149. <http://dx.doi.org/10.1111/j.0013-9580.2004.12704.x>. PMID:15329080.
- MCGEACHY, T.E. and BLOOMER, W.E., 1953. The phenobarbital sensitivity syndrome. *The American Journal of Medicine*, vol. 14, no. 5, pp. 600-604. [http://dx.doi.org/10.1016/0002-9343\(53\)90376-3](http://dx.doi.org/10.1016/0002-9343(53)90376-3). PMID:13040367.
- MISRA, B.B. and DEY, S., 2013. Shikimic acid (*Tamiflu precursor*) production in suspension cultures of East Indian sandalwood (*Santalum album*) in air-lift bioreactor. *Journal of Postdoctoral Research*, vol. 1, no. 1, pp. 1-9.
- MORSY, A.F., IBRAHIMA, H.S. and SHALABYB, M.A., 2010. Protective effect of broccoli and red cabbage against hepatocellular carcinoma induced by N-nitrosodiethylamine in rats. *The Journal of American Science*, vol. 6, no. 12, pp. 1136-1144.
- NUTRITION-AND-YOU.COM, 2022 [viewed 16 August 2022]. *Anise seed nutrition facts* [online]. Available from: <https://www.nutrition-and-you.com/anise-seed.html>
- PADMASHREE, A., ROOPA, N., SEMWAL, A.D., SHARMA, G.K., AGATHIAN, G. and BAWA, A.S., 2007. Star-anise (*Illicium verum*) and black caraway (*Carum nigrum*) as natural antioxidants. *Food Chemistry*, vol. 104, no. 1, pp. 59-66. <http://dx.doi.org/10.1016/j.foodchem.2006.10.074>.
- SURESH, D., SRINIVAS, A.N. and KUMAR, D.P., 2020. Etiology of hepatocellular carcinoma: special focus on fatty liver disease. *Frontiers in Oncology*, vol. 10, pp. 601710. <http://dx.doi.org/10.3389/fonc.2020.601710>. PMID:33330100.
- YADAV, A.S. and BHATNAGAR, D., 2007. Chemo-preventive effect of Star anise in N-nitrosodiethylamine initiated and phenobarbital promoted hepato-carcinogenesis. *Chemico-Biological Interactions*, vol. 169, no. 3, pp. 207-214. <http://dx.doi.org/10.1016/j.cbi.2007.06.032>. PMID:17658503.
- ZAHID, M.S.H., AWASTHI, S.P., ASAKURA, M., CHATTERJEE, S., HINENOYA, A., FARUQUE, S.M. and YAMASAKI, S., 2015. Suppression of virulence of toxigenic *Vibrio cholerae* by anethole through the cyclic AMP (cAMP)-cAMP receptor protein signaling system. *PLoS One*, vol. 10, no. 9, e0137529. <http://dx.doi.org/10.1371/journal.pone.0137529>. PMID:26361388.