

Description of clinical aspects and microscopy of the hair shaft of a carrier of familial monilethrix

Descrição dos aspectos clínicos e da microscopia da haste capilar de um portador de monilêtrix familiar

Maria Angélica T. Ferreira¹; João Francisco O. Gonzales¹; Bruna L. Diniz¹; Maiara A. Floriani¹; Ana Elisa K. Bau^{1, 2}; Rosana C. M. Rosa¹; Rafael Fabiano M. Rosa^{1, 3}; Paulo Ricardo G. Zen^{1, 3}

1. Universidade Federal de Ciências da Saúde de Porto Alegre (UFCSA), Rio Grande do Sul, Brazil. 2. Hospital da Criança Santo Antônio (HCSA), Rio Grande do Sul, Brazil. 3. Irmandade Santa Casa de Misericórdia de Porto Alegre (ISCMPA), Rio Grande do Sul, Brazil.

ABSTRACT

Monilethrix is a genetic condition that affects the hair shaft. We describe a family with this disease, focusing on its clinical aspects and microscopic hair characteristics. The patient was a 10-year-old female with history of hypotrichosis. In addition to diffuse alopecia, there was brittle hair, with ruptures in the hair shaft at different levels. The hair had a nodular appearance at naked eye. Other family members had the same symptoms, what indicates an autosomal dominant pattern of inheritance. Microscopic analysis revealed capillary fibers with areas of elliptical nodular appearance interspersed with regions of dystrophic constriction.

Key words: monilethrix; hair; hypotrichosis; inheritance patterns; microscopy.

INTRODUCTION

Hair abnormalities happen in childhood with some frequency due to acquired and congenital conditions. When the problem is in the hair shaft, these dysfunctions can be differentiated by the presence or not of increased fragility and breakage. Monilethrix is an abnormality characterized by increased fragility of the hair shaft⁽¹⁾. Its name originates from the combination of two words: the Latin word “monile” (necklace), and the Greek “thrix” (hair), referring to the beaded aspect of the hair, which can be observed under light microscopy⁽²⁾.

Monilethrix is a rare and non-syndromic genetic condition which can present two different patterns of inheritance: an autosomal dominant (OMIM 158000) and an autosomal recessive pattern (OMIM 252200)⁽³⁾. It is clinically characterized by short and fragile hair that breaks spontaneously or by friction^(1, 4, 5). Hair is normal at birth. However, the stem gains beaded or moniliform appearance during the first months of life^(1, 4, 5), leading to periodic changes in its diameter⁽³⁾. The hairline presents areas of normal thickness with elliptical nodes alternated with regions of dystrophic

constrictions. These internodal regions are prone to breakdown, which weakens the hair and may lead to alopecia⁽⁶⁾.

Our aim was to report the rare case of a family with monilethrix, highlighting their clinical findings and, mainly, the microscopic characteristics of the hair. A 10-year-old patient was referred for evaluation due to sparse hair. She was daughter of a 35-year-old father and a 33-year-old mother. The father had a similar hair disorder. In addition, the paternal grandfather, an aunt, and two paternal uncles were also affected (**Figure 1**). The child was born by vaginal delivery, at term, weighing 3,830 grams and measuring 50 cm. She was born cyanotic, requiring mechanical ventilation. Her neuropsychomotor and speech development was normal for her age. On physical examination, at the age of 10 years, she presented adequate anthropometric measurements (weight, height and head circumference), as well as diffuse and irregular alopecia with hair rupture at different levels, which gave an appearance of hypotrichosis. Her hair had a nodular appearance and was brittle (**Figure 2**). Her eyebrows and eyelashes were normal, as well as her nails and skin. Microscopic analysis of the hair showed stenosis areas, many of them close to the root.

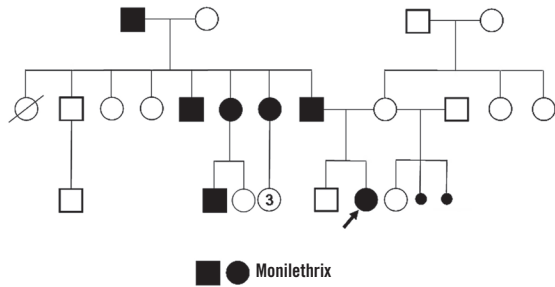


FIGURE 1 – Pedigree showing individuals of the family affected by monilethrix (the patient is indicated by the arrow), in an autosomal dominant pattern of inheritance

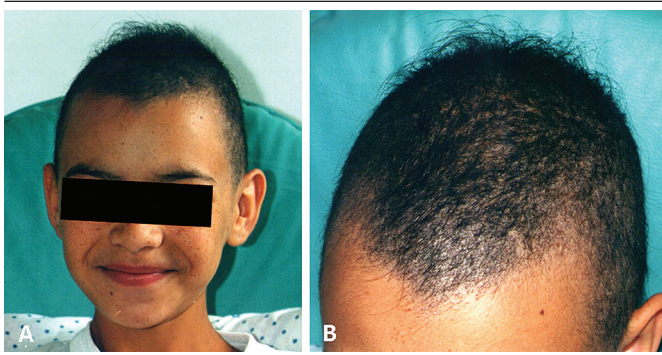

FIGURE 2 – Images of the patient at 10 years of age showing diffuse and irregular alopecia with hair rupture at different levels, giving an appearance of hypotrichosis (A and B)

The dermatological findings of our patient (with presence of sparse hair due to hair disruption) associated with her light microscopy findings (the beaded appearance due to regularly spaced nodes) were compatible with the diagnosis of monilethrix. Nail and skin changes, as onychodystrophy, keratosis pilaris and follicular keratosis, are also common^(7,8), although they were not verified in our patient. Monilethrix is caused by heterozygous and point mutations in hair cortex-specific keratin genes, all located on 12q13.13: *KRT81*, *K83* and *KRT86*⁽¹⁾. Mutations in these genes affect hair stability⁽²⁾, because they interfere in the formation of the intermediate keratin filament present in the cortical capillary rod. However, the specific reason for hair shaft diameter changes in patients with monilethrix is still unknown. The pattern observed in our family was autosomal dominant, which is consistent with almost all cases of the disease. On the other hand, there is a case described in literature presenting *DSG4* mutation and an autosomal recessive form of the disease⁽⁹⁾. Determination of the inheritance pattern has important repercussions on the risk of recurrence for future pregnancies. Affected individuals have a 50% risk of transmission to their children, what impacts on appropriate genetic counseling⁽³⁾.

Despite clinical characteristics, the reliable diagnosis of hair shaft abnormalities can only be made through a detailed structural

evaluation, which compares the normal characteristics with the variations found in the analyzed hair. Some characteristics of hair in monilethrix can be seen at naked eye, but this can lead to a misdiagnosis of the mild forms⁽¹⁰⁾. Therefore, there are different techniques for hair analysis. Typically, diagnosis is made using light microscopy and scanning electron microscopy (SEM)⁽⁷⁾.

Light microscopy, the method used in our case, demonstrates the beaded appearance of the hair^(1, 4, 5). This beaded appearance occurs due to the spaced elliptical fusiform fibers regularly formed or by the spindle-shaped nodes of normal thickness regularly interspersed with areas of constriction (**Figure 3**). Both areas are pigmented, and there are constriction regions of the hair which do not present medulla⁽⁷⁾. For such analysis, the hair should be removed and evaluated under a light microscope⁽¹¹⁾. A representative sample should have around 50 hair threads, cut at the scalp level, preferentially including copies of the shorter hair with the tip broken by the disease⁽¹²⁾. In microscopic analysis, care must be taken with the occurrence of iatrogenic pseudomonilethrix, due to the compression of hair between both glass slides. This may lead to constrictions on the hair shaft that did not previously exist. In the case of iatrogenic pseudomonilethrix, constrictions are irregular and without tendency to break, unlike what is observed in monilethrix⁽¹⁰⁾.

In SEM, the nodules may show normal or worn transverse cuticular scales and internodes with dense longitudinal pattern

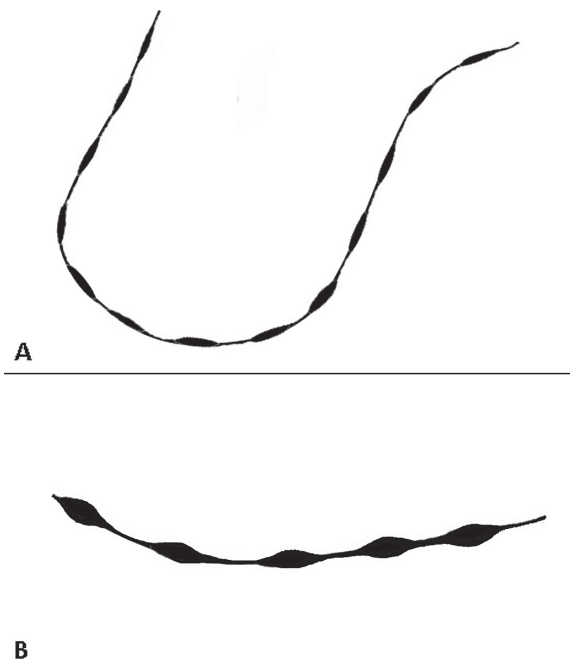


FIGURE 3 – Illustration showing the pattern and characteristics of the hair under light microscopy. Note the beaded appearance of the hair (A and B) due to the spindle-shaped nodes of normal thickness regularly interspersed with areas of constriction

of scales and ridging⁽⁷⁾. However, the investigation of hair shaft abnormalities can also be done using other techniques. Trichoscopy, also known as dermoscopy of the hair and scalp or dry dermoscopy, is currently the most used technique^(1, 2, 7), since it does not require hair removal as in light microscopy⁽¹¹⁾. Through this analysis it is possible to observe the uniform elliptical nodes and the intermittent constrictions of the hair shaft in monilethrix. The hair is regularly bended at multiple locations^(1, 4, 5). In addition, it is easier to avoid pseudomonilethrix. To perform this examination, the patient is asked not to use hair gel, and, the physician, immersion ultrasound gels⁽¹²⁾, because they may interfere in the hair analysis. In trichoscopy, the

dermoscope is used, which is an instrument capable of magnifying and illuminating the analyzed structure, allowing its observation in a 10-fold magnification without light reflex effects⁽⁷⁾.

Monilethrix alterations tend to be maintained throughout life, as there is no specific treatment, although retinoids, glycolic acids and minoxidil may help in some cases^(1, 4, 5). Thus, monilethrix is a rare genetic condition characterized by hair shaft abnormalities. As discussed above, although these alterations may potentially be seen at naked eye, this assessment does not replace microscopic analysis. The definition of diagnosis has important implications, including the family genetic counseling, due to the possibility of recurrence risk.

RESUMO

A monilêtrix é uma condição genética que acomete a haste capilar. Descrevemos uma família com essa doença, enfocando seus aspectos clínicos e as características microscópicas do cabelo. A paciente era do sexo feminino, 10 anos de idade, e apresentava história de hipotricose. Além da alopecia difusa, notava-se um cabelo quebradiço, com rupturas na haste capilar em diferentes níveis. Os cabelos possuíam um aspecto nodular a olho nu. Outros membros da família apresentavam os mesmos sintomas, o que indica um padrão de herança autossômica dominante. A análise microscópica revelou fibras capilares com áreas de aparência nodular elíptica, intercaladas por regiões de constrição distrófica.

Unitermos: monilêtrix; cabelo; hipotricose; padrões de herança; microscopia.

REFERENCES

- Alves R, Grimalt R. Hair loss in children. *Curr Probl Dermatol.* 2015; 47: 55-66.
- Ramot Y, Zlotogorski A. Keratins: the hair shaft's backbone revealed. *Exp Dermatol.* 2015; 24(6): 416-7.
- Shimomura Y. Congenital hair loss disorders: rare, but not too rare. *J Dermatol.* 2012; 39(1): 3-10.
- Ferrando J, Galve J, Torres-Puente M, Santillán S, Nogués S, Grimalt R. Monilethrix: a new family with the novel mutation in KRT81 gene. *Int J Trichology.* 2012; 4(1): 53-5.
- Moreno-Romero JA, Grimalt R. Hair loss in infancy. *G Ital Dermatol Venereol.* 2014; 149(1): 55-78.
- Schweizer J. More than one gene involved in monilethrix: intracellular but also extracellular players. *J Invest Dermatol.* 2006; 126(6): 1216-9.
- Jain N, Khopkar U. Monilethrix in pattern distribution in siblings: diagnosis by trichoscopy. *Int J Trichology.* 2010; 2(1): 56-9.
- Singh G, Miteva M. Prognosis and management of congenital hair shaft disorders with fragility - part I. *Pediatr Dermatol.* 2016; 33(5): 473-80.
- Kato M, Shimizu A, Yokoyama Y, et al. An autosomal recessive mutation of DSG4 causes monilethrix through the ER stress response. *J Invest Dermatol.* 2015; 135(5): 1253-60.
- Liu CI, Hsu CH. Rapid diagnosis of monilethrix using dermoscopy. *Br J Dermatol.* 2008; 159(3): 741-3.
- Haliasos EC, Kerner M, Jaimes-Lopez N, et al. Dermoscopy for the pediatric dermatologist part I: dermoscopy of pediatric infectious and inflammatory skin lesions and hair disorders. *Pediatr Dermatol.* 2013; 30(2): 163-71.
- Leitner C, Cheung S, de Berker D. Pitfalls and pearls in the diagnosis of monilethrix. *Pediatr Dermatol.* 2013; 30(5): 633-5.

CORRESPONDING AUTHOR

Rafael Fabiano Machado Rosa

Genética Clínica UFCSPA; Rua Sarmiento Leite, 245, apto 403; Centro; CEP: 90050-170; Porto Alegre-RS, Brasil; Phone: +55 (51) 3303-8771; Fax: +55 (51) 3303-8810; e-mail: rfmrosa@gmail.com.



This is an open-access article distributed under the terms of the Creative Commons Attribution License.