

HISTOMICROBIOLOGIC ASPECTS OF THE ROOT CANAL SYSTEM AND PERIAPICAL LESIONS IN DOGS' TEETH AFTER ROTARY INSTRUMENTATION AND INTRACANAL DRESSING WITH $\text{Ca}(\text{OH})_2$ PASTES

ASPECTOS HISTOMICROBIOLÓGICOS DO SISTEMA DE CANAIS RADICULARES E DAS LESÕES PERIAPICAIS EM DENTES DE CÃES APÓS INSTRUMENTAÇÃO AUTOMATIZADA E MEDICAÇÃO INTRACANAL COM PASTAS DE $\text{Ca}(\text{OH})_2$

Janir Alves SOARES¹, Mário Roberto LEONARDO², Léa Assed Bezerra da SILVA³,
Mário TANOMARU FILHO⁴, Izabel Yoko ITO⁵

1- DDS, MSc, PhD, Chairman, Discipline of Endodontics, Department of Dentistry, Federal University of Valleys of Jequitinhonha and Mucuri, Diamantina, MG, Brazil.

2- DDS, MSc, PhD, Associate Professor, Department of Endodontics, Faculty of Dentistry of Araraquara, São Paulo State University, Araraquara, SP, Brazil.

3- DDS, MSc, PhD, Chairman, Discipline of Pediatric Dentistry, Department of Pediatric Clinic, Preventive and Social Dentistry, Faculty of Dentistry of Ribeirão Preto, University of São Paulo, Ribeirão Preto, SP, Brazil

4- DDS, MSc, PhD, Associate Professor, Department of Endodontics, Faculty of Dentistry of Araraquara, São Paulo State University, Araraquara, SP, Brazil

5- DDS, MSc, PhD, Chairman, Discipline of Microbiology, Department of Clinical Analysis, Toxicology and Bromatology, Faculty of Pharmaceutical Sciences of Ribeirão Preto, University of São Paulo, Ribeirão Preto, SP, Brazil.

Corresponding address: Prof. Dr. Janir Alves Soares - Universidade Federal dos Vales do Jequitinhonha e Mucuri - Rua da Glória, 187 - Diamantina - MG. - Cep.: 39.100.000 - e-mail: janirsoares@citell.com.br - Tel: (38) 3531 2901

Received: January 16, 2006 - Modification: May 11, 2006 - Accepted: September 1, 2006

ABSTRACT

OBJECTIVE: The purpose of this study was to evaluate the distribution of microorganisms in the root canal system (RCS) and periapical lesions of dogs' teeth after rotary instrumentation and placement of different calcium hydroxide [$\text{Ca}(\text{OH})_2$]-based intracanal dressings. **MATERIALS AND METHODS:** Chronic periapical lesions were experimentally induced in 80 premolar roots of four dogs. Instrumentation was undertaken using the ProFile rotary system and irrigation with 5.25% sodium hypochlorite. The following $\text{Ca}(\text{OH})_2$ -based pastes were applied for 21 days: group 1 - Calen (n=18); group 2 - Calen+CPMC (n=20); group 3 - $\text{Ca}(\text{OH})_2$ p.a. + anaesthetic solution (n=16) and group 4 - $\text{Ca}(\text{OH})_2$ p.a. + 2% chlorhexidine digluconate (n=18). Eight root canals without endodontic treatment constituted the control group. Histological sections were obtained and stained with Brown & Brenn staining technique to evaluate the presence of microorganisms in the main root canal, ramifications of the apical delta and secondary canals, apical cementoplasts, dentinal tubules, areas of cemental resorption and periapical lesions. The results were analyzed statistically by the Mann-Whitney U test ($p < 0.05$). **RESULTS:** The control group showed the highest prevalence of microorganisms in all sites evaluated. Gram-positive cocci, bacilli and filaments were the most frequent morphotypes. Similar microbial distribution patterns in the RCS and areas of cementum resorption were observed in all groups ($p > 0.05$). The percentage of RCS sites containing microorganisms in groups 1, 2, 3, 4 and control were: 67.6%, 62.5%, 78.2%, 62.0% and 87.6%, respectively. **CONCLUSION:** In conclusion, the histomicrobiological analysis showed that the rotary instrumentation and the different calcium hydroxide pastes employed did not effectively eliminate the infection from the RCS and periapical lesions. However, several bacteria seen in the histological sections were probably dead or were inactivated by the biomechanical preparation and calcium hydroxide-based intracanal dressing.

Uniterms: Calcium hydroxide pastes; Endodontic infection; Periapical lesions; Root canal therapy.

RESUMO

OBJETIVO: Neste estudo avaliou-se a distribuição dos microrganismos no sistema de canais radiculares (SCR) e região periapical (RP) de cães após instrumentação automatizada e utilização de pastas à base de hidróxido de cálcio $\text{Ca}(\text{OH})_2$. **MATERIAL E MÉTODOS:** Lesões periapicais crônicas foram induzidas em 80 raízes de pré-molares de quatro cães. Após a instrumentação com o sistema Profile auxiliado pela solução de hipoclorito de sódio a 5,25%, aplicou-se as seguintes pastas contendo $\text{Ca}(\text{OH})_2$: grupo 1-Calén (n=18), grupo 2-Calén/PMCC (n=20), grupo 3-hidróxido de cálcio p.a. + solução anestésica (n=16) e grupo 4-hidróxido de cálcio p.a. + solução de digluconato de clorexidina a 2% (n=18), por 21 dias. Oito canais radiculares sem tratamento endodôntico constituíram o grupo-controle. Nas seções histológicas coradas por Brown & Brenn, avaliou-se a presença de microrganismos nos 3mm apicais do SCR e RP, incluindo o canal radicular principal, deltas, cementoplastas, túbulos dentinários, reabsorções cementárias e lesão periapical. Os resultados foram analisados pelo teste de Mann-Whitney ($p < 0.05$). **RESULTADOS:** Verificou-se que o grupo-controle apresentou a maior frequência de microrganismos em todos os sítios, com nítida presença de biofilmes nas paredes do canal radicular e nas reabsorções cementárias. Cocos, bacilos e filamentosos foram os morfotipos mais frequentes. Similar padrão de distribuição de microrganismos foi observado no SCR e nas áreas reabsorções cementárias de todos os grupos ($p > 0.05$). Nos grupos 1, 2, 3, 4 e controle, os percentuais de sítios do SCR contendo microrganismos foram: 67,6%, 62,5%, 78,2%, 62,0% e 87,6%, respectivamente. **CONCLUSÃO:** Histomicrobiologicamente, os protocolos de anti-sepsia utilizados proporcionaram insignificativa redução dos microrganismos no SCR e na RP, embora, metabolicamente, muitas bactérias vistas nas seções histológicas podem ter sido inativadas irreversivelmente ou mesmo perdido a viabilidade em função dos procedimentos de anti-sepsia utilizados.

Unitermos: Pastas de hidróxido de cálcio; Lesão periapical; Tratamento dos canais radiculares.

INTRODUCTION

Microbiologically, after pulp necrosis the pulp cavity becomes progressively colonized by the microorganisms that inhabit the oral environment and interconnected systems³⁶. The response of the cellular and molecular immunological system to intracanal infection results in the formation and perpetuation of abscesses, granulomas and cysts in the periapical region³⁵. Parallel to the development of periapical lesions, the microbiota, initially located in the principal root canal, propagate throughout the root canal system, invading secondary and accessory canals, isthmus, dentinal tubules, deltas and cement lacunae or cementoplasts^{12,22,26,39}. Microbiological culture reveals gram-positive and gram-negative cocci, bacilli and filaments in the tissues of primary and refractory periapical lesions^{7,19,42-44}, thus constituting the extraradicular infection^{14,16,42}. The scanning electron microscopy show that these microorganisms are organized in amorphous exopolysaccharide structures, adhering to dentinal surfaces, known as biofilms^{5,14,16,19,33,36}.

Clinically, control of the root canal system infection, one of the main goals of the endodontic treatment, consists of attaining a significant reduction in the number of viable microorganisms by elimination or inactivation^{1,3,4,9,10,32,34,38,40,41}. Biomechanical preparation is phase of endodontic treatment with the greatest impact on the intracanal microbiota^{3,4,21,34,37}. However, its antiseptic efficacy is partial and temporary^{21,27,37,38}. Residual microorganisms shall be eliminated or inactivated because they might recolonize the root canals after biomechanical preparation^{3,4,29,30,32} and even after obturation^{10,17,25,26,41}.

In an attempt to eliminate the residual infection, treatment strategies have included the use of calcium hydroxide [$\text{Ca}(\text{OH})_2$] pastes prepared with water-based vehicles (e.g., polyethylene glycol or anaesthetic solution) as intracanal dressings^{1,2,10,12,20,21,31,34,37,38}. Dissociation and diffusion determine the alkalinity responsible for calcium hydroxide direct bactericidal action^{23,30,31}. However, the neutralizing action of dentin on the hydroxide ions²³ and the relative resistance of some microorganisms to certain levels of alkalinity^{1,3,6,20,31}, compromise the ability of calcium hydroxide to eliminate certain microorganisms lodged in the dentinal tubules^{21,30}. In view of this, antiseptic agents such as camphorated paramonochlorophenol^{12,15,34,40} and chlorhexidine digluconate^{1,2,24,39} have been added to $\text{Ca}(\text{OH})_2$ -based pastes

Rotary instrumentation with nickel-titanium files represents one of the most significant technological advances of Endodontics in the last decade and has improved the preparation of root canals^{27,39,40}. Recent modifications of the Brown & Brenn staining technique have yielded the preservation of larger number microorganisms at different endodontic sites, thus allowing a qualitative evaluation in terms of morphotypes and gram staining.

The purpose of this study was to assess, on the basis of a histomicrobiological analysis, the distribution of microorganisms in the root canal system and periapical

lesions of dogs' teeth after rotary root canal instrumentation and placement of calcium hydroxide-based intracanal dressings prepared with different vehicles and antiseptics.

MATERIALS AND METHODS

Induction of periapical lesions

Forty upper and lower premolars of four 1-year-old dogs were used, making up a sample size of 80 roots. For sedation, 2.0 mL of Rompum (Bayer S/A – Veterinary products - Ind. Bras., RS, Brazil) was injected intramuscularly at a dose of 3.0 mg/Kg body weight. For general anaesthesia, 2 mL of Thiopental (Thionembutal-Abbott Laboratórios do Brasil Ltda., RJ, Brazil) was injected intravenously at a dose of 30 mg/Kg body weight. After coronal access, the root canals were explored to the apex with #15 K-files (Dentsply Maillefer, Ballaigues, Switzerland). The working length was established and the pulp was extirpated with a #25 Hedström file (Dentsply, Maillefer). Progressive breakdown of the apical delta was achieved by stepwise increase of file size up to #30 K-file, in order to standardize foramen opening. The root canals remained exposed to the oral cavity for 7 days, after which the coronal access cavity was sealed. After approximately 6 to 8 weeks, well-defined periapical radiolucent areas developed, suggestive of chronic periapical lesions (Figure 1).

Root canal treatment

With rigorous maintenance of aseptic and antiseptic conditions, the root canals were prepared with the ProFile rotary instrumentation system (Dentsply Tulsa Dental Products, Tulsa, OK, USA), using orifice shapers and nickel-titanium files with 0.04 and 0.06 tapers. Copious irrigation with 3.6 mL of 5.25% sodium hypochlorite preceded each change of file. The apical third was progressively enlarged using #45 to #60 K-files, maintaining foramen patency with a #30 K-file.

After removal of the smear layer and drying of the canals, the calcium hydroxide-based pastes, all containing water-soluble aqueous (anaesthetic solution or 2% chlorhexidine digluconate) or viscous (polyethylene glycol) vehicles were

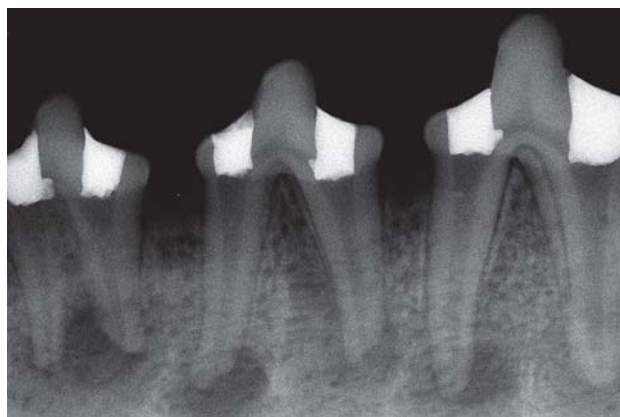

FIGURE 1- Experimentally induced periapical lesion in dog's premolars

applied. Four experimental groups were formed according to the intracanal medication used: group 1 (n=18): Calen paste (S.S. White Artigos Dentários Ltda. Rio de Janeiro, RJ, Brazil); group 2 (n=20): Calen paste associated with camphorated paramonochlorophenol, at a ration of 7.5/2.5 (Calen/CPMC; S.S. White Artigos Dentários Ltda.); group 3 (n=16): paste prepared with $\text{Ca}(\text{OH})_2$ p.a. and anaesthetic solution (Citanest 3% Prilocaine Hydrochloride with Octapressin; Astra Química e Farmacêutica, São Paulo, SP, Brazil); group 4 (n=18): paste prepared with $\text{Ca}(\text{OH})_2$ p.a. plus 2% aqueous solution of chlorhexidine digluconate (FGM Produtos Odontológicos, Joinville, SC, Brazil). The Calen paste is composed of 2.5 g calcium hydroxide, 0.5 g zinc oxide p.a, 0.05 g colophony and 2mL polyethylene glycol 400 (vehicle). The Calen/CPMC paste is formulated by the addition of 0.15 mL camphorated paramonochlorophenol to the Calen paste. The $\text{Ca}(\text{OH})_2$ p.a. powder (Labsynth Ltda, Diadema, SP, Brazil) used in groups 3 and 4 was weighed on electronic analytical balance and mixed to the respective solutions at a ratio of 0.9 g/mL solution to obtain a toothpaste consistency. Calen and Calen/CPMC pastes were applied using a special syringe with a threaded piston (ML syringe; S.S.White Artigos Dentários Ltda., Rio de Janeiro, RJ, Brazil) and a long 27G caliber needle with a silicone stopper to limit penetration up to the working length. The pastes in groups 3 and 4 were applied using a #4 lentulo spiral drill. Coronal sealing was done with zinc-oxide and eugenol cement (IRM; S.S.White Artigos Dentários Ltda., Rio de Janeiro, RJ, Brazil). Eight root canals without endodontic treatment constituted the control group.

A random distribution of the 4 types of treatment was undertaken in each dog. Radiographic evaluation of the filled root canals frequently showed slight periapical extrusion of the pastes. After 21 days, the dogs were sacrificed by anaesthetic overdose.

Histomicrobiological processing and analysis

Tissue blocks containing the roots were fixed in 25% glutaraldehyde solution glutaraldehyde in sucrose-sodium cacodylate buffer at pH7.4. The demineralizing medium, consisting of an aqueous solution of ethylenediaminetetraacetic acid (EDTA) containing 25% glutaraldehyde, sucrose and sodium cacodylate (pH 7.4), was adjusted with a 0.1 N sodium hydroxide solution to reach pH 7.4. Demineralization was undertaken in a microwave oven (Sharp Carousel, Ribeirão Preto, SP, Brazil) at 30°C at medium/maximum power.

Six-micrometer-thick slices were obtained and stained with the Brown & Brenn technique. The presence of microorganisms was evaluated by optical microscopy under oil immersion at 125X, 400X and 1000X magnifications. The 3-mm apical region of the root canal system and periapical region were evaluated at the following sites: 1- main root canal, 2- delta ramifications, 3- cementoplasts, 4- dentinal tubules, 5- areas of cemental resorption and 6- periapical lesion. Microscopic analysis were performed by three examiners, being one microbiologist, one histologist and one endodontist. The results were confirmed by consensus

with regard to the presence, infected site, morphology (cocci, bacilli and filaments) and stain reaction of the microorganisms (gram-positive or negative). The incidence of microorganisms at different sites of the roots and periapical lesions was analyzed statistically using the Mann-Whitney U at 5% significance level.

RESULTS

From the 80 dental roots, 1,394 histological sections were obtained, in which gram-positive and gram-negative cocci, bacilli and filaments were observed in most sites evaluated, frequently forming evident biofilms. As seen in Tables 1 and 2, the control group presented the highest frequencies of roots and sites containing microorganisms. Surprisingly, similar histomicrobiological patterns were seen between the control group and the experimental groups with respect to: ramifications of the delta, cementoplasts, main root canal, dentinal tubules and cement resorption ($p>0.05$). The percentage of sites of the RCS containing microorganisms in the groups 1, 2, 3, 4 and control were: 67.6%, 62.5%, 78.2%, 62.0% and 87.6%, respectively. The periapical lesions of the group filled with $\text{Ca}(\text{OH})_2$ /anaesthetic showed histomicrobiological aspects similar to that of the control group ($p>0.05$), while among the other groups a significant reduction was noted ($p<0.05$). The group filled with $\text{Ca}(\text{OH})_2$ /chlorhexidine showed the highest incidence of germ-free periapical lesions ($p<0.05$). As seen in Table 2, the control group showed the highest percentage of infected sites while the treatment with $\text{Ca}(\text{OH})_2$ /chlorhexidine showed the highest incidence of germ-free sites. There follows a description of the principal histomicrobiological aspects of each group.

Control group

All 160 histological sections showed microorganisms on the root canal walls, delta, cementoplasts and dentinal tubules (Figures 2 and 3). The major morphotypes observed were predominantly gram-positive cocci, bacilli and filaments. Evident and extensive biofilms were seen on the root canals walls. Seven roots (87.5%) contained microorganisms in the periapical region, mainly on cementum surface and Howship's lacunae, of which 50% formed biofilms (Figures 4).

Group 1

Of the 294 sections evaluated, the percentages of samples containing microorganisms in the deltas, cementoplasts, root canal walls and dentinal tubules, were 94.4%, 88.9%, 83.3% and 77.8%, respectively. In the periapical region, microorganisms were detected in 7 specimens (38.9%), of which 4 (22.2%) contained microorganisms in areas of cemental resorption. The most frequent microbial morphotypes were gram-positive cocci and bacilli, with a lower incidence of filaments and gram-negative bacteria (Figures 5 and 5a).

Group 2

All 330 histological slices showed microorganisms in the deltas. The cementoplasts, root canal walls and dentinal tubules showed microorganisms in 80%, 75% and 65% of the samples, respectively. Seven roots (35%) contained microorganisms in the periapical region, sometimes forming extensive microbial groups (Figures 6 and 6a). In areas of cemental resorption, microorganisms were observed in 20% of the specimens, some of which showing extensive biofilms. The major microbial morphotypes were gram-positive and gram-negative cocci and bacilli with a low rate of filaments.

Group 3

All 306 slices showed microorganisms in the deltas and cementoplasts. In the root canal walls and dentinal tubules, this percentage was 93.8% and 87.5%, respectively. Of the experimental groups, the highest incidence of microorganisms was shown in the periapical region and in areas of cemental resorption, in the order of 56.3% and 31.3%, respectively (Figures 7 and 7a). Gram-positive and gram-negative cocci and bacilli as well as gram-positive filaments were the most frequent morphotypes.

TABLE 1- Topographical distribution of microorganisms in the apical 3 mm of the root canal system and periapical region of each root of control and experimental groups

Groups	Regions submitted to histomicrobiological analysis					
	Root canal system				Periapical region	
	Root canal	Apical delta	Apical cementoplasts	Dentinal tubules	Cemental resorption	Periapical lesion
Control (n=8)	8 (100.0%)	8 (100.0%)	8 (100.0%)	8 (100.0%)	4 (50.0%)	7 (87.5%)
1 (n=18)	15 (83.3%)	17 (94.4%)	16 (88.9%)	14 (77.8%)	4 (22.2%)	7 (38.9%)
2 (n=20)	15 (75.0%)	20 (100.0%)	16 (80.0%)	13 (65.0%)	4 (20.0%)	7 (35.0%)
3 (n=16)	15 (93.8%)	16 (100.0%)	16 (100.0%)	14 (87.5%)	5 (31.3%)	9 (56.3%)
4 (n=18)	14 (77.8%)	17 (94.4%)	15 (83.3%)	13 (72.2%)	3 (16.7%)	5 (27.8%)

TABLE 2- Relative and absolute frequencies of sites containing microorganisms in histomicrobiological slices

Groups	Number of roots	Number of histological slices	Number of evaluated sites	Percentage of roots with sites containing microorganisms	Number of sites containing Microorganisms	Percentage of sites containing microorganisms
Control	8	160	960	100.0%	860	87.6%
1	18	294	1,746	100.0%	1,180	67.6%
2	20	330	1,980	100.0%	1,237	62.5%
3	16	306	1,836	100.0%	1,436	78.2%
4	18	304	1,824	100.0%	1,131	62.0%

Group 4

Of the 304 sections, the lowest frequency of sites with microorganisms was observed. In the deltas, cementoplasts, root canal walls and dentinal tubules, microorganisms were observed in 94.4%, 83.3%, 77.8% and 72.2% of the specimens respectively. Of the 5 roots (27.8%) with microorganisms in the periapical region, only 3 (16.7%) showed bacteria in areas of cemental resorption. Gram-positive cocci, bacilli and filaments were the most frequent morphotypes (Figures 8 and 8a).

DISCUSSION

Among the methodologies to study endodontic infection, the Brown & Brenn staining technique offers information concerning the topographical location, morphology and gram-positive or gram-negative structure of microorganisms in the tissue^{12,26,38,39}. The original technique produced significant damage to the cell walls, especially of gram-negative bacteria, due the aggressive acids involved^{44,46}. In this study fixation and demineralization were undertaken using glutaraldehyde, sucrose, sodium cacodylate and EDTA which replaced the original formic acid and sodium nitrate, respectively. Furthermore, microwave activation reduces the demineralization time³⁸.

Dogs have an apical delta consisting of an intricate system of ramifications, due to the absence of a main foramen^{9,12,40}. However, in this study, a standardized foramen was opened mechanically^{12,38-40}. This experimental model was proved useful to evaluate microbial propagation through the root canal system reaching the apical periodontal ligament by the following paths: the artificial foramen, delta ramifications simulating secondary and accessory canals,

dentinal tubules exposed by resorption of apical cementum and dentinal tubules that lead into cementoplasts.

Numerous gram-positive and gram-negative cocci, bacilli and filaments were identified in all sites mostly organized in condensed bacterial layer in a matrix-embedded forming clear biofilms on the dentinal wall of the root canal and root canal system. These morphologic patterns of infection are similar to results from microbiological culture of periapical lesions^{7,44}. Our findings corroborate those of a recent report¹⁸, which used similar fixation and demineralization procedures and found high incidence of cocci, bacilli and filaments in the apical third of the root canal system of human molars after instrumentation, antimicrobial irrigation and obturation in one appointment. Periapical biofilms were also observed in the areas of cemental resorption similar to those identified under scanning electron microscopy^{14,16,19,43,44}.

The microbiological culture technique, which is more sensitive than histomicrobiology^{22,44}, has demonstrated the survival of microorganisms in most primary periapical and recurrent lesions^{7,10,17,32,44} in percentages that vary from 67% to 97.2%. However, the modifications proposed allowed identifying microorganisms in approximately 90% of the periapical lesions in the control group; this percentage is equivalent to those obtained by scanning electron microscopy^{14,16,19}. In the present study, biofilms were observed in areas of cemental resorption in 50% of the control specimens. The formation of these structures involves phases of: adhesion by pili and/or extracellular polysaccharides (adesines and lipopolysaccharides), proliferation with the formation of microcolonies, and stratification and maturation^{5,33}.

Tronstad, et al.⁴² (1987) hypothesized that in long-term endodontic infections, the microbiota show little change inducing the host defenses to become less effective, and

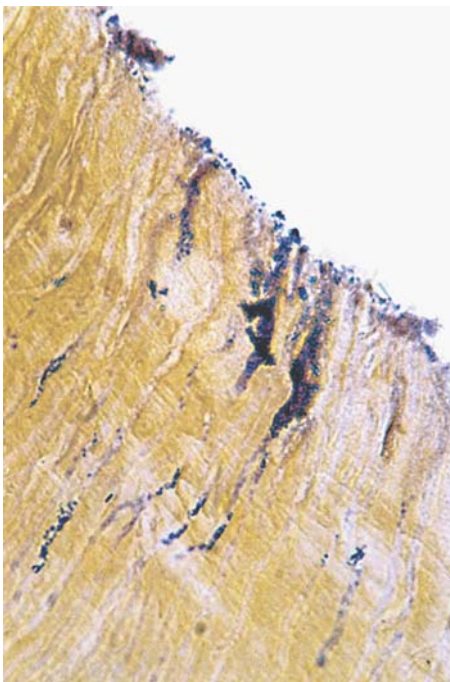


FIGURE 2- Dentinal tubules with several gram-positives and gram-negatives bacteria, Brown & Brenn - 1000X

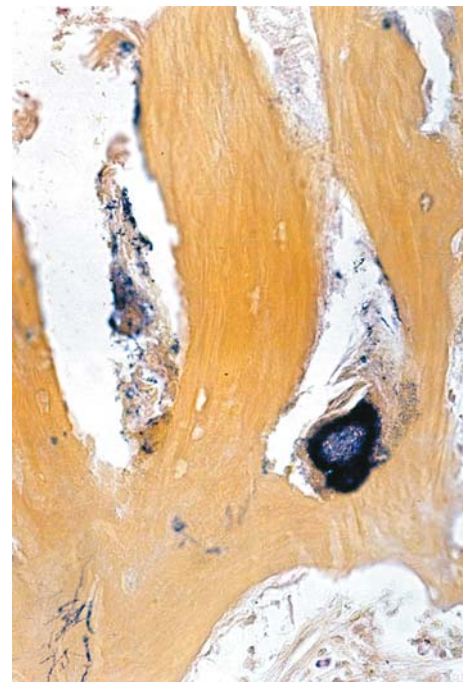


FIGURE 3- Apical delta containing microorganisms - 400X

therefore allowing the microorganisms to slowly invade and colonize the periapical tissues. However, the present study showed biofilm formation after a relatively short time (6 to 8 weeks), i.e., the microorganisms colonized the periapical tissues much earlier than expected. The periapical lesion is an expression of the immunological response, being rich in defense elements (neutrophils, macrophages, lymphocytes and antibodies), and represents an inhospitable

environment for microorganisms. Nevertheless, those that remain in the tissues awaiting death, on the contrary, develop survival strategies. Costerton, et al.⁵ (1995) and Slavkin³³ (1997) reported that bacteria elaborate substances that inactivate or deceive the host's defense mechanisms, allowing their survival within the tissues. Furthermore, they organize and distribute themselves in the amorphous and slimy extracellular material, becoming resistant to environmental challenge such as nutrient deficiency, oscillation of pH, mechanisms of host defense (opsonization and phagocytosis) and to local and systemic antimicrobials or, in other words, are better known as refractory infections^{14,16,18,19,34,35,42,44}.

The protocol of treatment consists of adequate biomechanical preparation associated with irrigation using 5.25% aqueous sodium hypochlorite, maintaining a light flow along the length of the canal, with a quantity and frequency of 3.6mL at each change of file, coupled with consistent apical enlargement corresponding to diameters of #45/60 and a conicity of 0.06 to 0.08 mm/mm followed by the placement of calcium hydroxide-based pastes.

Undoubtedly, biomechanical preparation represents the most important stage of intracanal anti-sepsis^{3,4,21,37,38}. The use of calcium hydroxide-based intracanal dressings has the goal of maximizing the neutralization, reduction or elimination of endodontic infection^{1,2,9,15,30,40,41}. The calcium hydroxide also neutralizes bacterial toxins, is biocompatible with the periapical tissues, inhibits inflammatory root and bone resorption and stimulates periapical regeneration^{28,35,36}. Due to the physicochemical dynamics of diffusion of hydroxyl ions within the root structure, the maximum alkalinity (pH 9-10) is only obtained in the most external layers of dentin after 2 to 3 weeks^{29,30,41}. This is the reason

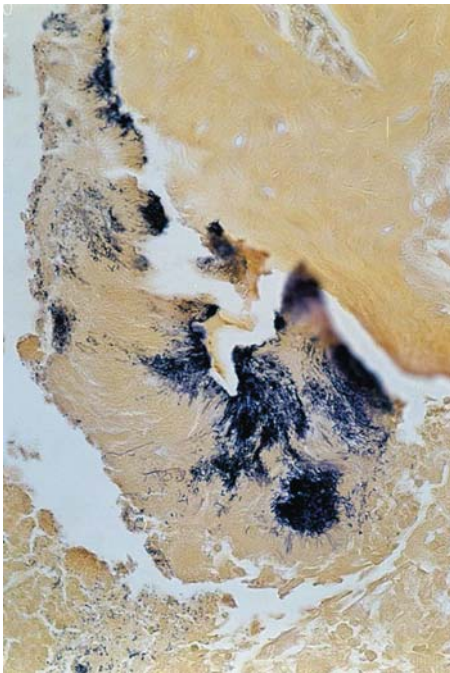


FIGURE 4- Biofilm containing gram-positive and gram-negative cocci bacilli and filaments, Brown & Brenn - 400X

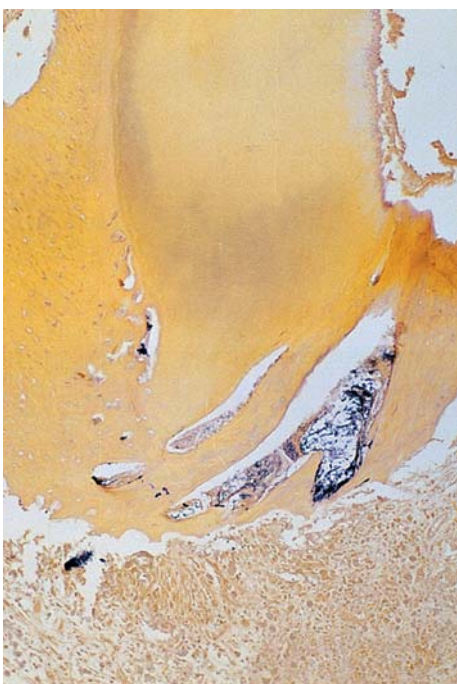

FIGURE 5- Panoramic view of the apical and periapical region. Several microbial morphotypes in the RCS and periapical region, Brown & Brenn - 125X

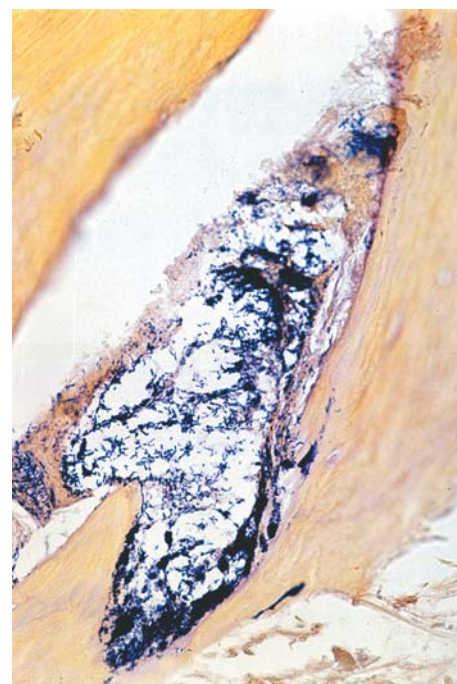

FIGURE 5a- Amplification of Figure 5. Secondary canal densely infected by various microbial morphotypes, Brown & Brenn - 1000X

why pastes remained for 21 days in the root canals in this study. From a chemical standpoint, the antiseptic action of calcium hydroxide is related to its high alkalinity, which alters the molecular structure of DNA, proteins and phospholipids, which are essential for the metabolism and reproduction of microorganisms^{29,30,40}. Physically, the root canal filling inhibits the inflow of nutrients and microbial recolonization²⁹. Polyethylene glycol, anesthetic solution, colophony and

zinc oxide are considered inert. Other substances in the pastes with an antiseptic action were CPMC and 2% chlorhexidine digluconate.

In vitro studies have shown that when in direct contact, calcium hydroxide eliminated all microorganisms present in the root canals in periods that varied from minutes to few days^{3,15,20}. However, *in vivo* studies have not reported similar performance in the root canal system^{4,21,34,37-40}. The relative

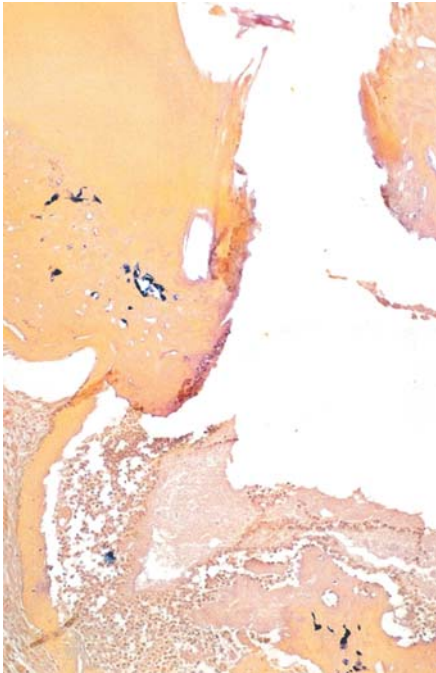


FIGURE 6- Microorganisms in the superficial cementum and periapical region, Brown & Brenn - 125X

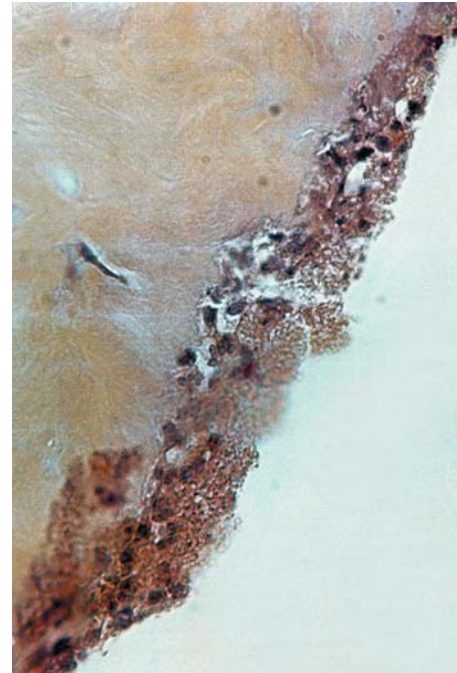

FIGURE 6a- Amplification of the rectangle area in Figure 6. Periapical biofilm of predominantly gram-negative microorganisms, Brown & Brenn - 1000X

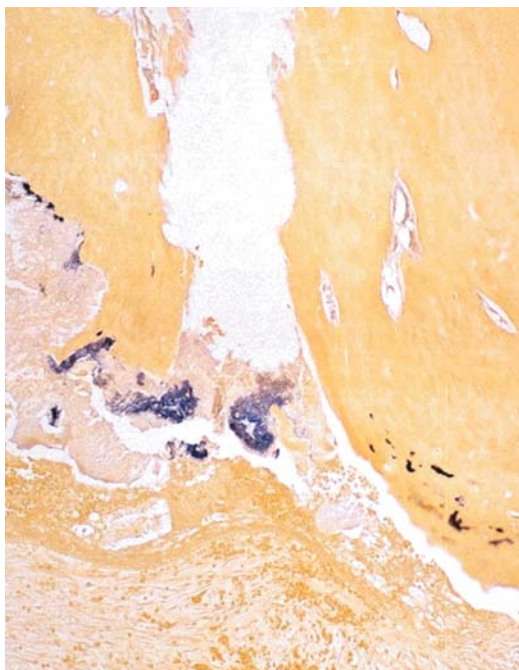


FIGURE 7- Microorganisms forming biofilms in the apical and periapical region, Brown & Brenn - 125X

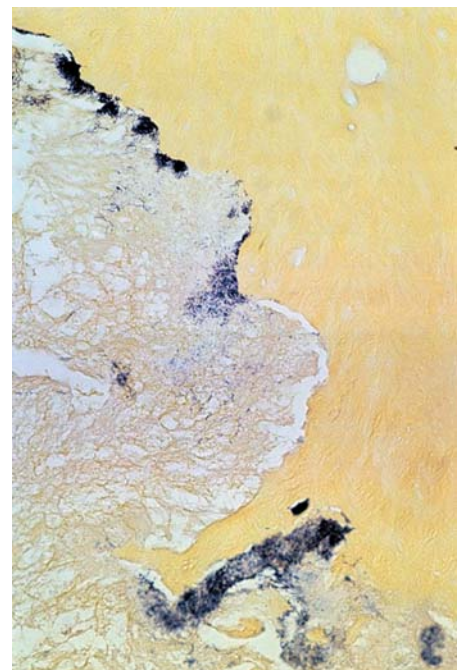

FIGURE 7a- Amplification of Figure 7. Microorganisms in cementum lacunae, Brown & Brenn - 1000X

reduction or inefficacy of antiseptics must be due to several factors that include the presence of organic material and the neutralizing effect of dentin on the hydroxyls²³ and to the particular resistance of some bacteria to certain levels of alkalinity⁶. An alternative strategy consists of adding an antiseptic to calcium hydroxide, for example CPMC, which is effective against microorganisms resistant to calcium hydroxide^{15,20,30}. Another antimicrobial, chlorhexidine digluconate, has been evaluated in liquid and gel forms, as an irrigant^{8,11,13} or intracanal medication^{1,2,24,39} in concentrations that vary from 0.2 to 5%, alone or combined with calcium hydroxide^{24,39,45}. This substance has a wide spectrum of antimicrobial action¹¹, penetrating substantivity^{8,45} and diffuses through dentin².

Notwithstanding, considering that all root canals presented similar initial microbiological status and were submitted to similar instrumentation, this study provides morphological evidence that the rotary instrumentation, associated with copious irrigation with 5.25% sodium hypochlorite and followed by application of calcium hydroxide pastes either prepared or not with antiseptics for 21 days, did not effectively alter the endodontic infection, even though the viability and reproductive capacity of these remaining microorganisms may be questioned. These findings demonstrate the difficulty of complete elimination of microorganisms from infected root canal system^{12,21,26,30,34,37-39}.

The protocols of treatment used in the present study are similar to those of several clinical protocols that offer high levels of clinical and radiographic success to patients^{4,34,41} and animals^{9,12,28} with chronic periapical lesions. Considering that the periapical repair occurs only by significant reduction or elimination of endodontic infection, the following may be conjectured: firstly, in the present study, many of the

microorganisms seen in the histological sections were dead or inactive by the endodontic treatment; secondly, there were resistant and susceptible periapical biofilms to endodontic treatment; and thirdly, possibly endodontic treatment influenced extraradicular infection.

In this concept, the biomechanical preparation disturbs the microbial equilibrium established in the root canal, which is the greatest source of microorganisms. Calcium hydroxide-based intracanal medication acts on the apical region by diffusion through the root canal system, or when extruded by the rapid and intense interaction of calcium and hydroxyl ions, possibly generating a physicochemical disequilibrium and interfering with the mechanisms of biofilm adhesion. Antiseptics combined with calcium hydroxide would co-participate in this process, especially those with ionic interaction capacity, such as chlorhexidine digluconate^{8,11,45}. Alterations in the physiology and organization of biofilms would reduce its resistance to the immunological system, rendering it more susceptible to phagocytosis. This would be a possible hypothesis for the reduction of extraradicular infection in the experimental groups of this study, mainly the group treated with the association of calcium hydroxide and 2% chlorhexidine digluconate.

Further studies should be conducted also addressing the culture technique, aiming to evaluate the viability of remaining microorganisms in the root canal system and periapical lesion after instrumentation, and application of calcium hydroxide dressings, to investigate possible correlations with the clinical, radiographic and histological success of endodontic treatment of teeth with chronic periapical lesions.

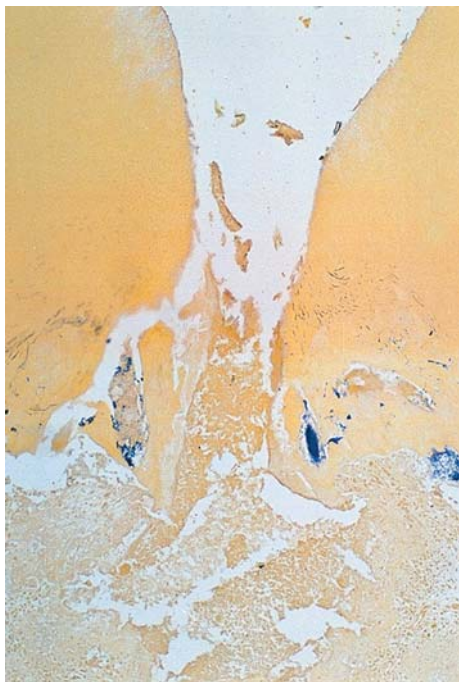

FIGURE 8- Apical region. Microorganisms in secondary canals, cementum lacunae and dentinal tubules. 125X



FIGURE 8a- Amplification of Figure 8. Bacilli and gram-positive filaments, Brown & Brenn - 1000X

CONCLUSIONS

1- Dog's teeth with pulp necrosis and chronic periapical lesions presented an extensive distribution of microorganisms in the root canal system and periapical region.

2- A high incidence of extraradicular infection forming periapical biofilms was observed in cemental resorption areas adjacent to apical foramen.

3- From a histomicrobiological standpoint, rotary instrumentation followed by application of calcium hydroxide pastes presented similar antimicrobial performance, regardless of the vehicle or addition of antiseptics.

4- According to the Brown & Brenn staining, the antiseptic procedures employed did not effectively eliminate the infection from the root canal system and periapical lesions.

REFERENCES

1-Almyroudi A, Mackenzie D, Mchugh S, Saunders WP. The effectiveness of various disinfectants used as endodontic intracanal medications: an in vitro study. *J Endod.* 2002;28:163-7.

2-Barthel CR, Zimmer S, Zilliges S, Schiller R, Göbel UB, Roulet J-F. In situ antimicrobial effectiveness of chlorhexidine and calcium hydroxide: gel and paste versus gutta-percha points. *J Endod.* 2002;28:427-30.

3-Bystrom A, Sundqvist G. The antibacterial action of sodium hypochlorite and EDTA in 60 cases of endodontic therapy. *Int Endod J.* 1985;18:35-40.

4-Bystrom A, Happonen RP, Stogren U, Sundqvist U. Healing of periapical lesions of pulpless teeth after endodontic treatment with controlled assepsis. *Endod Dent Traumatol.* 1987;3:58-63.

5-Costerton JW, Lewandowski Z, Caldwell D, Korber DR, Lappin-Scott HM. Microbial biofilms. *Annu Rev Microbiol.* 1995;49:711-45.

6-Evans M, Daviesd JK, Sundqvist G, Fidgor D. Mechanisms involved in the resistance of *Enterococcus faecalis* to calcium hydroxide. *Int Endod J.* 2002;35:221-8.

7-Iwu C, Macfarlane TW, Mackenzie D, Stenhouse D. The microbiology of periapical granulomas. *Oral Surg Oral Med Oral Pathol.* 1990;69:502-5.

8-Jeansonne MJ, White RR. A comparison of 2.0% chlorhexidine gluconate and 5.25% sodium hypochlorite as antimicrobial endodontic irrigants. *J Endod.* 1994;20:276-8.

9-Holland R, Otoboni JA Filho, Souza V, Nery MJ, Bernabé PFE, Dezan E Jr. A comparison of one versus two appointment endodontic therapy in dog's teeth with apical periodontitis. *J Endod.* 2003;29:121-5.

10-kvist T, Molander A, Dahlén G, Reit C. Microbiological evaluation of one-and two-visit endodontic treatment of teeth with apical periodontitis: a randomized, clinical trial. Status of root-filled teeth with apical periodontitis. *J Endod.* 2004;30:572-6.

11-Lenet BJ, Komorowski R, Wu XY, Huang J, Grad H, Lawrence HP, et al. Antimicrobial substantivity of bovine root dentin exposed to different chlorhexidine delivery vehicles. *J Endod.* 2000;26:652-5.

12-Leonardo MR, Almeida WA, Ito IY, Silva LAB. Radiographic and microbiologic evaluation of posttreatment apical and periapical repair of root canals of dogs' teeth with experimentally induced chronic lesion. *Oral Surg Oral Med Oral Pathol.* 1994;78:232-8.

13-Leonardo MR, Tanomaru M Filho, Silva LAB, Nelson P Filho, Bonifácio KC, Ito IY. In vivo antimicrobial activity of 2% chlorhexidine used as a root canal irrigating solution. *J Endod.* 1998;25:167-71.

14-Leonardo MR, Silva LAB, Rossi MA, Ito IY, Bonifácio KC. Evaluation biofilm and microorganisms on the external root surface in human teeth. *J Endod.* 2002;28:815-8.

15-Leonardo MR, Silva LAB, Tanomaru M Filho, Bonifácio KC, Ito IY. *In vitro* evaluation of antimicrobial activity of sealers and pastes used in Endodontics. *J Endod.* 2000;26:391-4.

16-Lomçali G, Sen BH, Çankaya H. Scanning electron microscopic observations of apical root surfaces of teeth with apical periodontitis. *Endod Dental Traumatol.* 1996;12:70-6.

17-Molander A, Reit C, Dahlén G, Kvist T. Microbiological status of root-filled teeth with apical periodontitis. *Int Endod J.* 1998;31:1-7.

18-Nair PNR, Henry S, Cano V, Vera J. Microbial status of apical root canal system of human mandibular first molars with primary apical periodontitis after 'one-visit' endodontic treatment. *Oral Surg Oral Med Oral Pathol Oral Radiol Endod.* 2005;99:231-52.

19-Noiri Y, Ehara A, Kawahara T, Takemura N, Ebisu S. Participation of bacterial biofilms in refractory and chronic periapical periodontitis. *J Endod.* 2002;28:679-83.

20-Orstavik D, Haapasalo M. Disinfection by endodontic irrigants and dressings of experimentally infected dentinal tubules. *Endod Dent Traumatol.* 1990;6:142-9.

21-Orstavik D, Kerekes K, Molven O. Effects of extensive apical reaming and calcium hydroxide dressing on bacterial infection during treatment of apical periodontitis: a pilot study. *Int Endod J.* 1991;24:1-7.

22-Peters LB, Wesselink PR, Buijs JF, Van Winkelhoff AJ. Viable bacteria in root dentinal tubules of teeth with apical periodontitis. *J Endod.* 2001;27:76-81.

23-Portenier I, Haapasalo H, Rye A, Waltino T, Orstavik D, Haapasalo M. Inactivation of root canal medicaments by dentine, hydroxylapatite and bovine serum albumin. *Int Endod J.* 2001;34:184-8.

24-Quillin B, Dabirsiaghi CI, Krywolap GN, Dumsha TC. Antimicrobial effect of Ca(OH)₂ supplemented with metronidazole and chlorhexidine as intracanal medicaments [poster clinic no.15]. *J Endod.* 1992;18:187.

25-Saunders WP, Saunders EM. Coronal leakage as a cause of failure in root canal therapy: a review. *Endod Dent Traumatol.* 1994;10:105-8.

26-Shovelton DS. The presence and distribution of micro-organisms within non-vital teeth. *Br Dent J.* 1964;117:101-7.

27-Shuping GB, Orstavik D, Sigurdsson A, Trope M. Reduction of intracanal bacteria using nickel-titanium rotary instrumentation and various medications. *J Endod.* 2000;26:751-5.

28-Silva LAB, Nelson P Filho, Leonardo MR, Rossi MA, Pansani CA. Effect of calcium hydroxide on bacterial endotoxin *in vivo*. *J Endod.* 2002;28:94-8.

29-Siqueira JF Jr, Uzeda M. Intracanal medicaments: evaluation of the antibacterial effects of chlorhexidine, metronidazole, and calcium hydroxide associated with three vehicles. *J Endod.* 1997;23:167-9.

30-Siqueira JF Jr, Uzeda M. Influence of different vehicles on the antibacterial effects of calcium hydroxide. *J Endod.* 1998;24:663-5.

31-Siren EK, Haapasalo MPP, Waltino TM, Orstavik D. In vitro antibacterial effect of calcium hydroxide combined with chlorhexidine or iodine potassium iodide on *Enterococcus faecalis*. *Eur J Oral Sci.* 2004;112:326-31.

32-Sjögren U, Fidgor D, Persson S, Sundqvist G. Influence of infection at the time of root filling on the outcome of endodontic treatment of teeth with apical periodontitis. *Int Endod J.* 1997;30:297-306.

33-Slavkin HC. Emerging and re-emerging infectious diseases: a biological evolutionary drama. *J Am Dent Assoc.* 1997;128:108-13.

34-Soares JA, Leonardo RT. Influência da "smear layer" na reparação periapical de dentes com necrose pulpar e patologias periapicais. *Rev Bras Odontol.* 2002;61:40-3.

35-Soares JA, Queiroz CES. Patogênese Periapical - Aspectos clínicos, radiográficos e tratamento da reabsorção óssea e radicular de origem endodôntica. *J Bras Endodontia.* 2001;2:124-35.

36-Soares JA. Microbiota dos canais radiculares associada às lesões periapicais crônicas e sua significância clínica. *J Bras Endodontia.* 2002;3:106-17.

37-Soares JA, Leonardo MR, Tanomaru M Filho, Silva LAB, Ito IY. Influência do preparo biomecânico e da medicação intracanal na anti-sepsia dos canais radiculares. *Rev Bras Odontol.* 2004;61:96-9.

38-Soares JA, Leonardo MR, Tanomaru M Filho, Silva LAB, Ito IY. Effect of biomechanical preparation and calcium hydroxide pastes on the anti-sepsis of root canal systems in dogs. *J Appl Oral Sci.* 2005;13:93-100.

39-Soares JA, Leonardo MR, Silva LAB, Tanomaru Filho M, Ito IY. Effect of rotary instrumentation and of the association of calcium hydroxide and chlorhexidine on the anti-sepsis of root canal systems in dogs. *Braz Oral Res.* 2006;20:120-6.

40-Soares JA, Leonardo MR, Silva LAB, Tanomaru M Filho, Ito IY. Elimination of intracanal infection in dogs' teeth with induced periapical lesions after rotary instrumentation: Influence of different calcium hydroxide pastes. *J Appl Oral Sci.* 2006;14:172-7.

41-Sundqvist G, Fidgor D, Persson S, Sjögren U. Microbiological analysis of teeth with failed endodontic treatment and the outcome of conservative re-treatment. *Oral Surg Oral Med Oral Pathol Oral Radiol Endod.* 1998;85:86-93.

42-Tronstad L, Barnett F, Riso K, Slots J. Extraradicular endodontic infections. *Endod Dent Traumatol.* 1987;3:86-90.

43-Tronstad L, Barnett F, Cervone F. Periapical bacterial plaque in teeth refractory to endodontic treatment. *Endod Dent Traumatol.* 1990;6:73-7.

44-Vigil GV, Wayman BE, Dazey SE, Fowler CE, Bradley DV Jr. Identification and antibiotic sensitivity of bacteria isolated from periapical lesions. *J Endod.* 1997;23:110-4.

45-White RR, Hays G, Janer LR. Residual antimicrobial activity canal irrigation with chlorhexidine. *J Endod.* 1997;23:229-31.

46-Wijnbergen M, van Mullem PJ. The cumulative effect of disinfection, storage, histological fixation and demineralization on number and staining ability of gram-positive bacteria. *Int Endod J.* 1991;24:243-8.