

XX testicular disorder of sex differentiation: case report

Distúrbio da diferenciação sexual testicular XX: relato de caso

Bianca Bianco¹, Denise Maria Christofolini¹, Frederico Rezende Ghersel¹, Marcello Machado Gava¹, Caio Parente Barbosa¹

ABSTRACT

The 46 XX, testicular sex differentiation disorder, or XX male syndrome, is a rare condition detected by cytogenetics, in which testicular development occurs in the absence of the Y chromosome. It occurs in 1:20,000 to 25,000 male newborns and represents 2% of cases of male infertility. About 90% of individuals present with normal phenotype at birth and are generally diagnosed after puberty for hypogonadism, gynecomastia, and/or infertility. The authors present the report of an XX male with complete masculinization and infertility.

Keywords: Gonadal dysgenesis, 46, XX; Gene, SRY; Sex differentiation; infertility, male; Azoospermia; Case reports

RESUMO

O distúrbio da diferenciação sexual testicular 46 XX, ou síndrome do homem XX, é uma anomalia rara, detectada por estudos citogenéticos, em que o desenvolvimento testicular ocorre na ausência do cromossomo Y. A incidência é de 1:20.000 a 25.000 recém-nascidos do sexo masculino e representa 2% dos casos de infertilidade masculina. Cerca de 90% dos indivíduos apresentam fenótipo normal ao nascimento e são geralmente diagnosticados após a puberdade, devido a hipogonadismo, ginecomastia, e/ou infertilidade. Os autores apresentam o relato de um homem XX com masculinização completa e infertilidade.

Descritores: Disgenesia gonadal 46 XX; Gene SRY; Diferenciação sexual; Infertilidade masculina; Azoospermia; Relatos de casos

INTRODUCTION

The testicular disorder of sex differentiation 46,XX (DSD 46,XX; OMIM 278850), or XX male syndrome, was first described by de la Chapelle, in 1964⁽¹⁾. It is a rare condition, in which testicular development occurs in the absence of the Y chromosome detected by cytogenetics. Its incidence is 1:20000 to 25000 male newborns⁽¹⁾ and it represents 2% of cases of male infertility⁽²⁾. For this type of karyotype, three clinical categories may be observed: XX male with normal genitalia; XX male

with ambiguous genitalia, and true XX hermaphrodites with ovarian and testicular tissues⁽³⁾.

Despite the fact that diagnosis may be made at puberty, since one third of patients develop gynecomastia, the disorder is frequently established at the time of investigation of the cause of infertility, by detection of a 46,XX karyotype in an individual with a male phenotype, since all XX males are sterile. In general, these patients present with decreased facial hairs and a tendency toward female distribution of pubic hair. The testicles are small in volume, and their histological aspect resembles those of the Klinefelter syndrome. Wolff ducts develop into male structures (epididymus, vas deferens, seminal vesicle, and ejaculatory ducts) and the Müller ducts undergo apoptosis, resulting in the action of the Anti-Müllerian hormone produced by Sertoli cells. The secretion of testosterone by Leydig cells is usually normal during puberty, but may drop during adulthood, leading to a condition of hypergonadotropic hypogonadism^(3,4). Stature tends to be intermediate, between male and female⁽⁴⁾.

In about 10% of cases, there is genital ambiguity characterized by hypospadias and micropenis, and there may be an association with other congenital anomalies, particularly cardiac anomalies⁽⁵⁾. In most cases, normal intelligence is observed, although many patients present with cognitive problems and learning difficulties⁽⁶⁾.

The authors present the report of an XX male with male phenotype and infertility seen at the Human Reproduction Services of the Faculdade Medicina do ABC (FMABC).

CASE REPORT

A 34-year-old patient was seen at the Andrology Outpatient's Clinic of the Human Reproduction Unit - FMABC and complained of primary infertility for six years. The patient presented with surgical past history of correction of cryptorchidism on the right testis at 3

¹ Faculdade de Medicina do ABC - FMABC, Santo André (SP), Brazil.

Corresponding author: Bianca Bianco - Rua Santo Egídio, 43 - Santana - CEP 02461010 - São Paulo (SP), Brasil - Tel.: +55 11 4438-7299 - e-mail: bianca.bianco@hotmail.com

Received: Aug 24, 2010 - Accepted: Jun 30, 2011

Conflict of interest: none

years of age, and upon physical examination, a penis with no alterations, atrophic right testicle, diminished left testicle, gynecoid hair distribution, and normal growth and development were observed (Figure 1). The patient was 1.61 m in height and weighed 80 kg. Imaging tests, biochemical and hematological results, and serum tests were also normal. Levels of T (404 ng/dL) and PRL (9.2 ng/mL) were within normal limits; however, the levels of FSH (15.45 mUI/mL) and LH (10.9 mUI/mL) characterized a condition of hypergonadotropic hypogonadism. Results of the two seminal analyses of the patients showed non-obstructive azoospermia. Semen analyses were performed as per criteria of the World Health Organization (WHO). Additionally, in order to determine the causes of infertility, cytogenetic analysis and chromosome Y microdeletion investigation were requested. The cytogenetic study revealed a 46,XX chromosome constitution in all 40 cells analyzed (Figure 2). The investigation of Y chromosome microdeletion revealed only the presence of the *SRY* gene (Figure 3). This patient had one brother who was married and had children. The infertile couple was referred for genetic counseling.

Data were collected only after exposure of the objectives of the study and signing of the informed consent forms approved by the Research Ethics Committee of the FMABC.

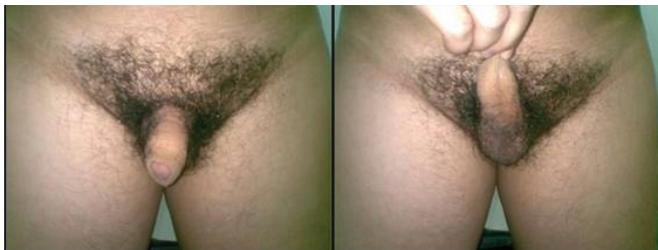

Figure 1. Gynecoid hair distribution, penis with no alterations, atrophic right testicle, decreased left testicle, and ductus deferens present

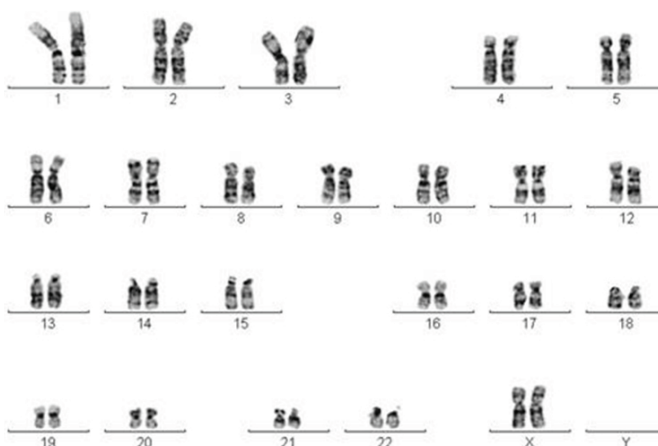


Figure 2. Chromosomal analysis by G banding of the proband showing a 46,XX chromosomal constitution

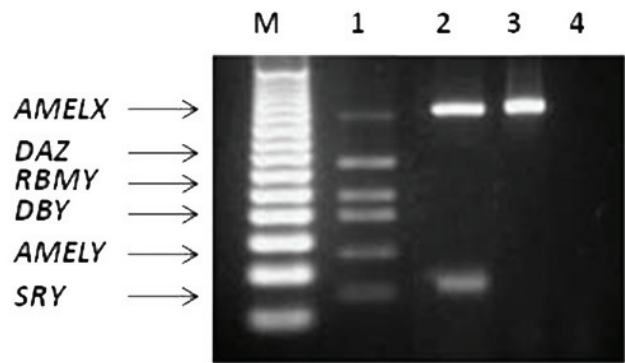


Figure 3. Agarose gel 2.5% showing (M) marker of molecular weight 50pb, (1) male control with all regions of the Y chromosome present, (2) proband with *AMELX* and *SRY* genes present, (3) normal female control with only the *AMELX* gene present and the blank (B)

DISCUSSION

The DNA analysis of the DSD 46,XX demonstrated that in approximately 80 to 90% of cases, there are Y chromosome sequences in the genome, particularly of the *SRY* gene (7). The detection of this gene in men with a 46,XX chromosome constitution elucidated the reason why, in the absence of chromosome Y, the bipotential gonad differentiated into a testicle. In 10 to 20% of patients who do not present with the *SRY* gene, generally hypospadias, cryptorchidism, or various degrees of genital ambiguity are observed. This fact indicates that autosomal genes and/or those X-linked chromosome should be part of a very comprehensive mechanism of gonadal determination(8).

Three different mechanisms were proposed to explain the etiology of XX males: (1) translocation of sequences of the Y chromosome, including the *SRY* gene, for the X chromosome or autosome (Figure 4); (2) mutation in an X-linked gene or autosome, a gene

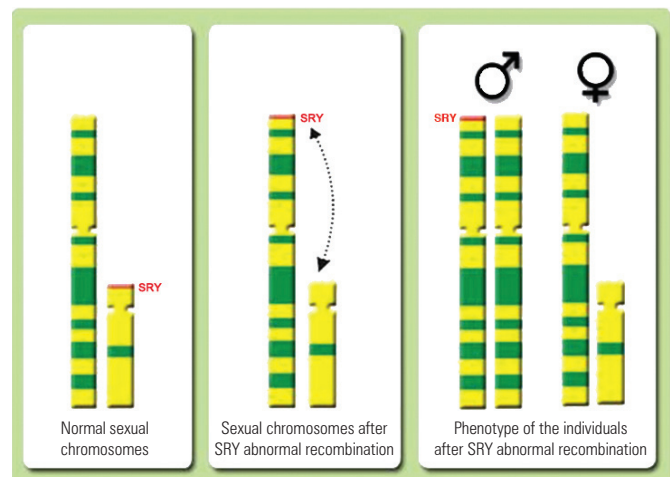


Figure 4. One of the mechanisms proposed to explain the etiology of XX males: translocation of the *SRY* gene to chromosome X due to abnormal crossing-over

that is yet unknown, which would activate the cascade of testicular differentiation in XX and *SRY*-negative males; or (3) occult mosaicism of the Y chromosome limited to the gonadal tissue or eliminated during development⁽⁵⁾.

In this study, we report the case of an *SRY*-positive XX male with masculine phenotype and infertility as the primary complaint. The analysis of 40 metaphases revealed a 46,XX chromosome constitution with no numerical or structural chromosomal alterations. Investigation of the sequences of the Y chromosome showed merely the presence of the *SRY* gene. The patient was of low stature, which could be attributed to the absence of growth spurt during puberty, due to the absence of the Y chromosome.

It is a well known fact that infertile men have 8 to 10 times more chromosomal anomalies than fertile men do, and many times, do not present with other phenotypic characteristics. In a review of 11 studies involving 9766 oligozoospermic males, abnormalities in the sexual chromosomes and autosomes were found in 4.2 and 1.5% of men, in comparison with 0.14 and 0.25%, respectively, of the controls⁽⁹⁾. Based on prevalence data and on the lack of other associated phenotypical characteristics, recommendation is made that routine karyotyping be requested of infertile men with deficient spermatogenesis and sperm concentrations lower than 10 million/mL before they are submitted to any assisted reproduction technique⁽¹⁰⁾.

The heterogeneous nature of chromosomal abnormalities and the potentially complex reproductive result make it indispensable for the geneticist and clinician to be knowledgeable of the modern practice of fertility, both for diagnosis and couple counseling as to natural conception or by assisted reproduction. If sperm is available but the male bears a chromosomal abnormality, there is a higher risk than that of the normal population of an inviable conceptus occurring, or a liveborn with deficiencies. In some cases, the genotype may present a null perspective for the recovery of sperm, for example, as in 46,XX males, and in these cases, other options should be discussed, such as the use of donor sperm or adoption⁽¹⁰⁾.

CONCLUSION

In concluding, the investigation of genetic alterations in men with infertility is very important since the findings may determine the prognosis and direct towards adequate treatment. The finding of men with the 46,XX karyotype, although rare in the population, may be frequent at human reproductive services. In this way, clinics should be aware of clients with different phenotypical presentations that may be seen in these individuals.

ACKNOWLEDGEMENTS

The authors are grateful for the help given by Tatiana Goberstein Lerner.

REFERENCES

1. De la Chapelle A, Hortling H, Niemi M, Wennstrom J. XX sex chromosomes in a human male: first case. *Acta Med Scand*. 1964;175:Suppl:25-38.
2. Camerino G, Parma P, Radi O, Valentini S. Sex determination and sex reversal. *Curr Opin Genet Dev*. 2006;16(3):289-92.
3. Abbas NE, Toublanc JE, Boucekckine C, Toublanc M, Affara NA, Job JC, et al. A possible common origin of «Y-negative» human XX males and XX true hermaphrodites. *Hum Genet*. 1990;84(4):356-60.
4. Damiani D, Guedes DR, Damiani D, Dichtchekenian V, Coelho Neto JR, Maciel-Guerra AT, et al. XX male: 3 case reports during childhood. *Arq Bras Endocrinol Metabol*. 2005;49(1):79-82.
5. De la Chapelle A. The Y-chromosomal and autosomal testis-determining genes. *Development*. 1987;101 Suppl:33-8.
6. Van Dyke DC, Hanson JW, Moore JW, Patil SR, Hawtrey CE, Hansen JR. Clinical management issues in males with sex chromosomal mosaicism and discordant phenotype/sex chromosomal patterns. *Clin Pediatr (Phila)*. 1991;30(1):15-21.
7. Umeno M, Shinka T, Sato Y, Yang XJ, Baba Y, Iwamoto T, et al. A rapid and simple system of detecting deletions on the Y chromosome related with male infertility using multiplex PCR. *J Med Invest*. 2006;53(1-2):147-52.
8. Vilain E, McCabe ER. Mammalian sex determination: from gonads to brain. *Mol Genet Metab*. 1998;65(2):74-84.
9. Johnson MD. Genetic risks of intracytoplasmic sperm injection in the treatment of male infertility: recommendations for genetic counseling and screening. *Fertil Steril*. 1998;70(3):397-411.
10. McLachlan RI, OBryan KM. State of the art for genetic testing of infertile men. *J Clin Endocrinol Metab*. 2010;95(3):1013-24.