

Nifedipine-induced histological changes in the parotid glands of hypertensive rats

Nikos SEFEROS^(a)
Ioanna DASKALA^(a)
Antonia KOTSIU^(b)
Madeleine TSAMOURI^(c)
Christine TESSEROMATIS^(a)

^(a)Department of Pharmacology, Medical School, University of Athens, Athens, Greece.

^(b)Aretaieion University Hospital, Athens, Greece.

^(c)Department of Pathology, General District Hospital "Red Cross", Athens, Greece.

Abstract: Nifedipine is a widely used anti-anginal and anti-hypertensive agent. It is associated with significant gingival changes attributed more to collagen hyperplasia than to enhancement of protein synthesis. We investigated the influence of nifedipine on morphological changes in the parotid glands of rats in a model of hypertension. Twenty-eight male Wistar rats (8–10 weeks; 200 ± 15 g) were divided into four groups (A–D). Hypertension was induced by surgical means in groups C and D. Animals in groups B and D were treated with nifedipine (0.85 mg/kg) *via* a gastroesophageal catheter the day after surgery (experimental day-1) for 2 weeks. A significant difference was observed between the control group and nifedipine group and between the control group and hypertension group with regard to the weight of the parotid gland and its surface area. Histological findings demonstrated changes in the parotid glands of hypertensive animals with mild vessel dilatation and infiltration of inflammatory cells. These histological findings seemed to be due more to changes in venous function than to alterations in gland architecture.

Keywords: Hypertension; Nifedipine; Parotid Gland; Sialadenitis; Salivary Glands.

Declaration of Interests: The authors certify that they have no commercial or associative interest that represents a conflict of interest in connection with the manuscript.

Corresponding Author:
Christine Tesseromatis
E-mail: ctesser@med.uoa.gr

DOI: 10.1590/1807-3107BOR-2014.vol28.0012
Epub Jun 02, 2014

Submitted: Jul 16, 2013
Accepted for publication: Jan 13, 2014
Last revision: Mar 03, 2014

Introduction

Drug-induced parotitis and salivary-gland dysfunction are considered to be infrequent (and often unrecognized side-effects) of drugs.¹ Doxycycline,² nifedipine,³ oxyphenbutazone,⁴ phenylbutazone,⁵ α -methyldopa,⁶ angiotensin-converting enzyme inhibitors (ACEIs),⁷ H₂-receptor antagonists,⁸ nitrofurantoin⁹ iodine,¹⁰ and ibuprofen¹¹ have been reported to induce sialadenitis accompanied by disorders in saliva excretion, thereby depriving the oral cavity from a lubrication medium and antibacterial protection.

Nifedipine is used widely as an anti-anginal and anti-hypertensive drug. Nifedipine inhibits the influx of calcium ions across cells in vascular smooth muscle and cardiac muscle membrane, resulting in arterial vasodilatation and decreased vascular resistance. Nifedipine therapy has been reported to result in significant gingival hyperplasia, which is mediated by the drug's action on calcium transport.¹² Moreover, gingival fibroblasts exposed to nifedipine have been demonstrated to significantly enhance protein synthesis.¹³ Histological and immunohistochemical investigations have shown that nifedipine does not influence fibroblast size. It seems that nifedipine has a direct inhibitory effect on the production of collagen by fibroblasts.

In one study, under nifedipine treatment, the area of collagen was significantly greater, along with strong fibronectin expression with preservation of the elastic fiber network.¹⁴ In another study, a large number of patients treated with nifedipine suffered from lower-limb edema which (*via* Echo-color Doppler examination of the superficial, deep, communicating, and perforating veins of the legs) was attributed to venous insufficiency (but without excluding the possibility of a hypersensitivity reaction).¹⁵

The aim of the present study was to investigate the influence of nifedipine on morphological changes in the parotid gland in a model of experimental hypertension.

Methodology

Twenty-eight male Wistar rats (200 ± 15 g; 8–10 weeks) were divided into four groups of seven (A–D). Hypertension was induced in groups C and D by ligation and obstruction of the right renal artery. The procedure was carried out under injection with sodium thiopental (3 mg/kg, *i.p.*; Abbott Laboratories Hellas, Athens, Greece) and 2% lidocaine (IMS International Medication Systems, Berkshire, UK) plus 250 μ L norepinephrine 1:100000/animal (*Jenapharm*, Jena, Germany) at the incision site.

Nifedipine tablets (Adalat 20 mg; Bayer Hellas AG, Athens, Greece) were pulverized. They were then administered to groups B and D *via* a gastroesophageal catheter at 0.85 mg/kg on the first post-operative day (experimental day-1) for 2 weeks. An equal volume of distilled water was administered to the animals of groups A and C. The Initial body weight of all subjects was estimated. Blood pressure (BP) evaluation in all experimental groups was undertaken using a carotid artery catheter (polyethylene-50) connected to a four-channel data acquisition system (MP35; Biopac, Goleta, USA). Rats were anesthetized with sodium thiopental (as mentioned above) and heparin injected (100 IU/mL) simultaneously to introduction of the catheter. BP was measured after 30 min (Table 1).

Animals of all groups were killed on day-15 by decapitation. The parotid glands were isolated and removed. Body weight (g), weight of the parotid gland (g) and surface area of the parotid gland (cm^2) were

measured. Parotid glands were preserved in 10% buffered formaldehyde fixative solution. Paraffin-embedded tissue sections (4 μ m) were stained with hematoxylin & eosin. Histological examination of the parotid sections was conducted.

Animals were housed under 12 h/12 h light-darkness conditions with food and water available *ad libitum*. They were treated according to the Updated Guide for the Care and Use of Laboratory Animals.¹⁶ The study protocol was approved by the Ethics Committee of the University of Athens (Athens, Greece; EL.25BIO 009).

Significant changes in macro-morphological parameters were evaluated by the Student's *t*-test using QuickCalcs (Graph Pad, San Diego, USA).

Results

Nifedipine seemed to restore systolic blood pressure (SBP) enhancement in the experimental groups. Hypertensive animals (group C) treated with nifedipine demonstrated a decrease in the weight of their parotid glands, just like the animals in group B. The surface area of the isolated parotid glands increased ($p < 0.05$) in all experimental groups (B,D) but the nifedipine groups (B, D) showed considerable enlargement (Table 1).

The ratio of the weight of the parotid gland/body weight increased under the influence of nifedipine and hypertension but was not significant (NS). Examination of the ratio of the surface area of the parotid gland/weight of the parotid gland revealed that the parotid gland was enlarged under the influence of nifedipine ($p < 0.05$) and hypertension (NS).

Post-killing body weight was increased significantly in the hypertension group compared with the control group (group C *versus* group A; $p < 0.05$). A significant difference was observed between the control group and nifedipine group and between the control group and hypertension group with regard to the weight of the parotid gland (group B *versus* group A; group C *versus* group A; $p < 0.05$). With regard to the surface area of the parotid gland, a significant difference was observed between the control group and nifedipine group, the control group and hypertension+nifedipine group, and between the hypertension group and

Table 1. Body weight (g) and parameters of the parotid glands (mean \pm SD) in groups A–D (n = 7 in each group).

	Control (A)	Nifedipine (B)	Hypertension [®]	Hypertension + nifedipine (D)	p (comparison between groups)
Initial body weight (g)	222.7 \pm 27.15	214.29 \pm 26.37	228.43 \pm 20.18	217.14 \pm 12.86	NS
Body weight upon killing (g)	227.33 \pm 46.33	231.67 \pm 29.94	252.00 \pm 13.51*	230.00 \pm 18.71	A vs C p<0.05
Absolute weight of parotid gland (g)	0.124 \pm 0.030	0.149 \pm 0.066*	0.142 \pm 0.010*	0.130 \pm 0.015	A vs B A vs C p<0.05
Ratio of weight of parotid gland/body weight (\times 100)	0.055 \pm 0.002	0.065 \pm 0.008	0.057 \pm 0.005	0.057 \pm 0.005	NS
Surface area (cm ²)	0.890 \pm 0.160	1.250 \pm 0.044*	1.060 \pm 0.070*	1.140 \pm 0.087*	A vs B A vs C A vs D p < 0.05
Ratio surface area of parotid gland/weight of parotid gland (cm ² /g)	7,177 \pm 0,03	8,35 \pm 0,002*	7,437 \pm 0,008	8,7 \pm 0,0042*	A vs B A vs D p < 0.05
Systolic blood pressure (mmHg)	90 \pm 7.3	85 \pm 8	160 \pm 9,5*	111 \pm 7*	A vs C A vs D p < 0.05

*p<0.05; NS, not significant

hypertension+nifedipine group (groups B versus A, D versus A and C versus A; $p < 0.05$). The absolute weight of the parotid gland of hypertensive animals was increased in a significant manner ($p < 0.05$) in comparison with controls, but administration of nifedipine increased the weight of the parotid gland in a non-significant manner. The surface area of the isolated parotid gland increased in the experimental groups (hypertensive, nifedipine) and, in particular, the nifedipine groups exhibited a significant enlargement ($p < 0.05$).

The ratio of the weight of the parotid gland/body weight increased under the influence of nifedipine and hypertension but without statistical significance. The ration of the surface area of the parotid gland/weight of the parotid gland also suggested enlargement of the parotid gland under nifedipine administration ($p < 0.05$) and hypertension (NS) (groups B versus A, D versus A; $p < 0.05$) (Table 1).

Histological analyses revealed mild-to-severe vessel dilatation as well as moderate periductal chronic inflammation and mild stroma edema in animals with hypertension and that had undergone nifedipine treatment. Fibrosis was not observed (Figures 1, 2).

Discussion

Drug-induced parotitis has not been investigated widely because it is considered to be a minor health problem. α -methyl dopa, bretylium, nifedipine, oxyphenbutazone, phenylbutazone, nitrofurantoin and nifedipine have been shown to induce enlargement of the parotid glands.¹⁷ Morphological disorders are followed by functional disability. Reduced production of saliva results into decreased oral mucosa lubrication, dehydration and increased caries risk. ACEIs are widely used hypotensive agents, and adverse reactions associated with their use are expected.¹⁸

Silva¹⁹ reported that swelling of the parotid glands occurred < 1 h after taking captopril, possibly due to a type-B idiosyncratic adverse drug reaction. Similar findings have been observed by Moss *et al.*²⁰

Captopril inhibits the rennin-angiotensin axis, leading to BP decrease by dilatation of blood vessels. Nifedipine exerts a similar anti-hypertensive effect by acting as a calcium-channel antagonist.

Comparable findings have been described by Bosch *et al.*^{3,17} in a case report of bilateral painless enlargement of the parotid glands with dry mouth after sublingual treatment with nifedipine and nicardipine. A total of 83% of the patients studied receiving nife-

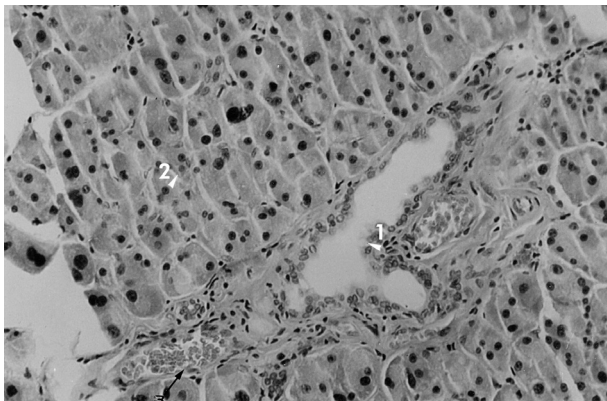


Figure 1. Parotid gland of a control-group rat showing serous-type acini (arrow) and intralobular duct (H&E stain, $\times 160$ magnification).

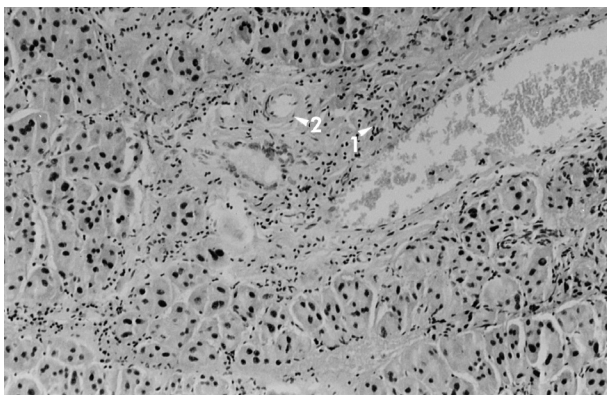


Figure 2. Parotid gland from the experimental hypertension + nifedipine group. Mild periductal chronic inflammation (arrows), dilated venules, and mildly thickened arterial wall (arrowhead) are observed (H&E stain, $\times 100$ magnification).

dipine showed evidence of hyperplastic tissue, and 74% of those on diltiazem had hyperplastic tissue.²¹

The present study showed analogous findings to observations in humans (Table 1), *i.e.*, increase in the weight of the parotid gland and hyperplasia on the surface of the parotid gland in hypertensive animals under nifedipine treatment. Nifedipine induced enlargement of both parotid glands,

possibly affecting their function.²² This enlargement could be associated with drug hypersensitivity reactions or a decrease in venous drainage.²³ Enlargement of the parotid gland was accompanied by mild structural changes as revealed by histology. The observed mild-to-severe vessel dilatation of parotid tissue could have been due to renovascular hypertension. Similar findings by other authors have suggested that the calcium-channel blockers (CCBs) verapamil, nifedipine, and diltiazem decrease amylase secretion from rat parotid glands by elevating levels of dibutyryl cyclic-adenosine monophosphate.²⁴ Such enlargement could be related to venous congestion of the salivary glands. Furthermore, it has been found that nifedipine administration decreases saliva flow, calcium levels, and amylase excretion, resulting in a limitation of salivary function.²⁵ ACEIs (which block the ACE in the renin-angiotensin-aldosterone system) cause dry mouth in approximately 13% of patients.²⁶

CCBs are being used increasingly for the treatment of hypertension in the elderly. Several case reports in the dental literature have suggested that patients treated with CCBs manifest gingival hyperplasia similar to that seen in patients taking phenytoin. Study of 89 patients undertaken at the Westside Veterans Administration Medical Center (Chicago, IL, USA) suggested that nifedipine and diltiazem cause gingival hyperplasia.²¹

Conclusions

A significant difference was observed between the control group and nifedipine group and between the control group and hypertension group with regard to the weight of the parotid gland and its surface area. Histological findings demonstrated changes in the parotid glands of hypertensive animals with mild vessel dilatation and infiltration of inflammatory cells. These histological findings seemed to be due more to changes in venous function than to alterations in gland architecture.

References

- Brooks KG, Thompson DF. A review and assessment of drug-induced parotitis. *Ann Pharmacother*. 2012 Dec;46(12):1688-99.
- Vidal Pan C, González Quintela A. Doxycycline-induced parotitis. *Postgrad Med J*. 1991 Mar;67(785):313-4.
- Bosch X, Campistol JM, Botey A, Cases A, Revert L. Nifedipine-induced parotitis [Letter to the Editor]. *Lancet*. 1986 Aug;2(8504):467.
- Chen J, Ottolenghi P, Distenfeld A. Oxyphenbutazone induced sialadenitis. *JAMA*. 1977 Sep;236(13):1399.
- Mirsky S. Salivary gland reaction to phenylbutazone. *Can Med Assoc J*. 1970 Jan 17;102(1):91-104.
- Mardh P, Belfrage I, Naversten E. Sialadenitis following treatment with α -methyldopa. *Acta Med Scand*. 1974 Apr;195(4):333-5.
- Chauhan V, Negi RC, Sharma A, Gupta S, Mokta J, Verma B, et al. Enalaprilat induced acute parotitis. *J Assoc Physicians India*. 2008 Feb;56(2):128-9.
- Tomasko MA, Luskin AT. Recurrent parotitis with H₂ receptor antagonists in a patient with Sjogren syndrome. *Am J Med*. 1988 Aug;85(2):271-7.
- Pellinen T, Kalske J. Nitrofurantoin-induced parotitis. *Br Med J (Clin Res Ed)*. 1982 Jul;285(6338):344.
- Harden R. Submandibular adenitis due to iodine administration. *Br Med J*. 1968 Jan;1(5585):160-1.
- Mourouzis C, Saranteas T, Tsamouris M, Tesseromatis C. Morphological changes of parotid glands following adjuvant arthritis and ibuprofen treatment in rats. *Int J Oral Maxillofac Surg*. 2003 Feb;32(1):69-73.
- Barclay S, Thomason JM, Idle JR, Seymour RA. The incidence and severity of nifedipine-induced gingival overgrowth. *J Clin Periodontol*. 1992 May;19(5):311-4.
- Johnson RB. Synergistic enhancement of collagenous protein synthesis by human gingival fibroblasts exposed to nifedipine and TNF- α in vitro. *J Oral Pathol Med*. 2003 Aug;32(7):408-13.
- Bonnaure-Mallet M, Tricot-Doleux S, Godeau GJ. Changes in extracellular matrix macromolecules in human gingiva after treatment with drugs inducing gingival overgrowth. *Arch Oral Biol*. 1995 May;40(5):393-400.
- Ciccone M, di Noia D, di Michele L, Corriero F, Biasco MG, Rizzon P. Effects of lacidipine and nifedipine on lower limb veins in nonphlebopathic patients. *J Cardiovasc Pharmacol*. 1994 Jun;23(5):111-2.
- US National Research Council Committee for the Update of the Guide for the Care and Use of Laboratory Animals. *Guide for the Care and Use of Laboratory Animals*. 8th ed. Washington DC: National Academies Press; 2011.
- Bosch X, Sobrino J, Lopez-Soto A, Urbano-Marquez A. Parotitis due to nicardipine. *BMJ*. 1992 Apr;304(6831):882.
- Abecassis S, Roujeau J-C, Bocquet H, Copie-Bergman C, Radier C, Revuz J, et al. Severe sialadenitis: a new complication of drug reaction with eosinophilia and systemic symptoms. *J Am Acad Dermatol*. 2004 Nov;51(5):827-30.
- Silva RMG. Captopril-induced bilateral parotid and submandibular sialadenitis. *Eur J Clin Pharmacol*. 2004 Aug;60(6):449-53.
- Moss JR, Zanation AM, Shores CG. ACE inhibitor associated recurrent intermittent parotid gland swelling. *Otolaryngol Head Neck Surg*. 2005 Dec;133(6):992-4.
- Fattore L, Stablein M, Bredfeldt G, Semla T, Moran M, Doherty-Greenberg JM. Gingival hyperplasia: a side effect of nifedipine and diltiazem. *Spec Care Dentist*. 1991 May-Jun;11(3):107-9.
- Thompson DF. Drug-induced parotitis. *J Clin Pharm Ther*. 1993 Aug;18(4):255-8.
- Massimo C, Sebastianelli G, Noera G. Nifedipine induced parotitis: a hypersensitivity reaction. *Am J Cardiol*. 1988 Apr;61(10):874.
- Nomura H, Izuhara K, Nomura T, Kodama M, Sugiura N, Tachibana M, et al. The interaction of α - and β -adrenergic agonists on amylase release from parotid glands of euthyroid and hypothyroid rats. *Jpn J Pharmacol*. 1986 Jun;41(2):247-56.
- Dehpour AR, Ghafourifar P, Massoudi S, Abdollahi M, Mousavizadeh K. On the relation of calcium channel blockers to rat parotid and submandibular glands function in vivo. *Gen Pharmacol*. 1995 May;26(3):619-22.
- Mangrella M, Motola G, Russo F, Mazzeo F, Giassa T, Falcone G, et al. Hospital intensive monitoring of adverse reactions of ACE inhibitors. *Minerva Med*. 1998 Apr;89(4):91-7.