









Root coverage with platelet-rich fibrin or connective tissue graft: a split-mouth randomized trial

Thaís Macedo Nunes CARRERA^(a) 
Laryssa Moraes MACHADO^(b) 
Marco Thúlio Rocha SOARES^(b) 
Gustavo Patrício PASSOS^(b) 
Guilherme José Pimentel de OLIVEIRA^(a) 
Noé Vital RIBEIRO JÚNIOR^(b) 
Priscilla Barbosa Ferreira SOARES^(a) 
Suzane Cristina PIGOSSI^(a) 

^(a)Universidade Federal de Uberlândia – UFU, School of Dentistry, Department of Periodontology and Implantodontology, Uberlândia, MG, Brazil.

^(b)Universidade Federal de Alfenas – Unifal-MG, School of Dentistry, Alfenas, MG, Brazil.

Declaration of Interests: The authors certify that they have no commercial or associative interest that represents a conflict of interest in connection with the manuscript.

Corresponding Author:

Suzane Cristina Pigossi
E-mail: suzane.pigossi@ufu.br

<https://doi.org/10.1590/1807-3107bor-2023.vol37.0084>

Submitted: July 21, 2022
Accepted for publication: March 14, 2023
Last revision: April 17, 2023

Abstract: This study aimed to compare the use of connective tissue grafts (CTG) and platelet-rich fibrin (PRF) associated with the tunnel technique (TT) for the treatment of multiple gingival recessions (GR). Fourteen patients with multiple bilateral GR [type 1 recession (RT 1)] in the maxillary incisors, canines, and/or premolars were included. The TT was performed on both sides (split-mouth model); CTG (36 GR) was used on one side, and on the other, PRF (36 GR) was used. Clinical parameters, including recession depth (RD), probing depth, clinical attachment level (CAL), and keratinized gingiva thickness/width (GT/KTW), were obtained at baseline and after 1, 3, 6, and 16 months. Lower RD (0.81 ± 0.68 vs. 1.23 ± 0.71 mm) and CAL (2.54 ± 0.63 vs. 2.73 ± 0.82 mm) were observed for CTG compared to PRF after 16 months. Higher GT was obtained for CTG compared to PRF after 3 (1.81 ± 0.56 vs. 1.43 ± 0.47 mm) and 6 months (1.67 ± 0.61 vs. 1.38 ± 0.55 mm, $p < 0.05$). The recession coverage (RC) was higher for CTG ($55.42\% \pm 37.14$) in comparison to PRF ($29.53\% \pm 34.08$) after 16 months ($p < 0.05$). Similarly, CTG presented a more complete coverage of the recession (15; 41.66%) than PRF (9; 24.32%). There were no significant differences between the groups in terms of surgery time, postoperative pain, or healing patterns. Greater esthetic satisfaction was obtained with CTG. It was concluded that CTG combined with TT showed clinical and esthetic results superior to those of PRF in multiple GR treatments.

Keywords: Gingiva; Gingival Recession; Platelet-Rich Fibrin.

Introduction

Different methods have been proposed to obtain complete and predictable coverage of exposed root surfaces. The combination of coronally advanced flap (CAF) and connective tissue graft (CTG) techniques is considered the gold standard, with a significantly higher percentage of root coverage and keratinized tissue gain.¹ However, a donor site is required for CTG acquisition, which results in increased patient discomfort, postoperative pain, and bleeding. Moreover, the necessity of a large amount of graft to treat multiple gingival recession sites limits the use of CTG.² In this context, platelet-rich fibrin (PRF) has



been suggested as an alternative to CTG for gingival recession treatment.³

PRF is an autologous fibrin matrix that contains 50% of the leukocytes from the original blood volume.^{4,5} The three-dimensional fibrin matrix of the PRF supports cells during the regenerative process, acting as a mechanical barrier that simultaneously releases several growth factors associated with wound healing.⁶ In vitro studies have shown a slow release of growth factors by the PRF, including the transforming growth factor β 1 (TGF- β 1), platelet-derived growth factor (PDGF), and vascular endothelial growth factor (VEGF), during the first 7 days in sterile media.^{6,7} The benefits of PRF are also associated with its low cost, relatively simple method of acquisition, and suturing suitability.⁸

The use of PRF in Miller Class I and II (or Cairo Type 1 Recession [RT 1]) defects resulted in similar clinical parameters, except for keratinized tissue (KT) gain, when compared to CTG.^{2,3,9-13} During a histological evaluation, Eren et al.,¹⁴ observed that CAF associated with PRF accelerated blood vessel formation and tissue maturation when compared to CTG. In addition, fewer side effects, including pain and swelling, were observed in sites treated with PRF because of improved tissue healing and the absence of a second surgical donor site.¹⁰

To avoid incisions at the recipient site, an “envelope technique” was proposed, wherein the CTG is inserted into the flap created around the exposed root surface.¹⁵ Following these principles, Allen^{16,17} modified the procedure and indicated the “tunnel technique” (TT) for multiple recession sites. Though TT is indicated for multiple Class I and II Miller recessions, it should be avoided for wide recessions to prevent excessive graft exposure.¹⁸ The main advantage of TT is the maintenance of papillary integrity, which provides more blood supply and accelerates healing.¹⁸ A recent systematic review¹⁹ demonstrated a satisfactory root coverage percentage with the TT of $82.75 \pm 19.7\%$ and $87.87 \pm 16.45\%$ for localized and multiple defects, respectively.

Therefore, the present study aimed to compare the use of CTG and PRF combined with the TT for the treatment of Miller Class I (or Cairo RT 1) multiple

gingival recession through a randomized controlled split-mouth trial.

Methodology

Trial design

This clinical study was designed as a split-mouth, randomized, controlled trial and reported as per the CONSORT 2010 statement. In accordance with the Declaration of Helsinki (1964, revised in 2000), all recruited patients provided written informed consent. The study protocol was approved by the Ethics Committee of Alfnas Federal University (CAAE:99947418.6.0000.5142).

In each patient ($n = 14$), one side of the maxilla served as a control, whereas the contralateral side served as the test. The recessions were treated with the TT using either the PRF membrane (test group, 36 sites) or CTG harvested from the palate (control group, 36 sites).

Participants

Between March and December, 2019, patients from the Alfnas Federal University, School of Dentistry, Alfnas, Minas Gerais, Brazil were recruited for the study. Periodontally and systemically healthy non-smoking patients were included in based on the following inclusion criteria: a) maxillary bilateral Miller Class I or II²⁰ (or Cairo RT 1²¹) multiple gingival recessions located on the incisors, canines, and/or premolars; b) presence of tooth vitality, absence of restorations, and superficial caries at the involved sites; and c) no periodontal surgical treatment in the area to be treated in the previous 24 months. Patients in the pregnancy or lactation period or who self-reported history of corticosteroid, chemotherapy, or immunomodulator use during the previous 6 months were excluded.

Interventions

Gingival recession treatment

All patients received individualized oral hygiene guidance and a full-mouth supragingival scaling and polishing one month prior to surgery. Patients were also encouraged to maintain their oral health

to eliminate habits related to the etiology of GR. The patients were instructed to use the "Roll" brushing technique and a soft toothbrush to protect the soft tissue from trauma. Only patients with a plaque index (PI) of ²² and gingival index (GI)²³ <1 were deemed eligible for surgery. Both surgeries (test and control sites) were performed in a single session by the same experienced surgeon (N.V.R.J.).

Before the surgical procedure, PRF membranes were prepared according to the technique described by Dohan and colleagues.²⁴ Venous blood (four tubes per patient) was drawn using 10-mL glass-coated plastic tubes without anticoagulant. The blood was immediately centrifuged using a centrifuge (IntraSpin, Intra-Lock® System, Germany) at 3000 rpm for 10 minutes.²⁴ Resistant autologous fibrin membranes were easily obtained by compressing fluids (serum) from the PRF clot.

During PRF centrifugation, intra- and extra-oral asepsis were achieved using 0.12% and 2% chlorhexidine gluconate, respectively. Local anesthesia was induced using a 4% articaine solution with epinephrine 1:100.000 (Nova DFL, RJ, Brazil). The

planning of the exposed root surfaces was performed using hand instruments (Gracey Curettes, Hu-Friedy, Chicago, USA). Subsequently, intrasulcular incisions were made using a n°15 C blade to preserve the integrity of the papillae on both sides. The incision was extended to the adjacent tooth on both sides of the recession site. Dissection of the entire buccal aspect was performed as a partial-thickness flap, using sharp tunnel elevators (Quinelato, Brazil) to preserve the papillae (Figures 1A-B). The flap was extended beyond the mucogingival junction and under each papilla, allowing tension-free flap mobilization in the coronal direction.

In the test group (side), three layers of PRF membranes were joined using a Polyglactin 370 suture (Vicryl 4-0, Ethicon Inc., Raritan, USA) (Figure 1C). The PRF membranes were inserted into the tunnel and immobilized over the recession area at the level of the CEJ using suspensory sutures (Figures 1D-E). In the control group, a 1-2-mm thick CTG was harvested from the palate in the area between the second premolar and second molar using the single incision technique²⁵ (Figure 1H).

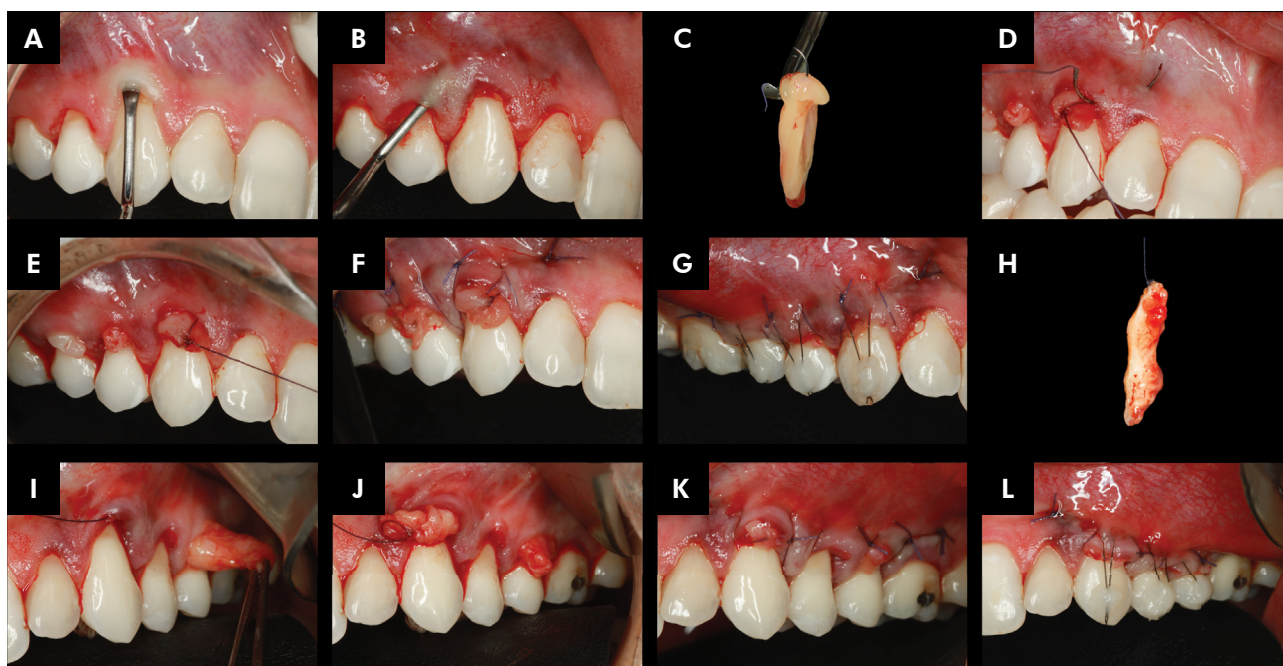


Figure 1. Surgical procedure. A-B: Partial-thickness flap using sharp tunnel elevators; C: Three layers of platelet-rich fibrin (PRF) membranes; D-E: Insertion of PRF membranes into the tunnel; F-G: Suspensory sutures in PRF side; H: Connective tissue graft (CTG); I-J: CTG insertion into the tunnel; K-L: Suspensory sutures in CTG side.

The CTG was placed in the tunnel and stabilized using absorbable suspensory sutures (Figures 1I-J). After harvesting the CTG, a hemostatic sponge was placed on the palatal wound. The donor area was closed with cross-mattress sutures, and an acrylic plate was placed to protect the palatal wound.

The mobilized mucous flap on both sides was advanced coronally to the CEJ and suspensory sutures were stitched (Figures 1F and 1K). In addition, composite resin stops were positioned in the mid-buccal region of the tooth to prevent the collapse of the suspended sutures (Nylon 5-0, Ethicon Inc., Raritan, USA) (Figures 1G and 1L). The patients were prescribed 0.12% chlorhexidine gluconate (Periogard, Colgate, São Paulo, Brazil) and instructed to rinse gently twice daily for 15 days. During this period, tooth brushing was discontinued in the surgical area. An antibiotic (amoxicillin, 500 mg, thrice daily) was prescribed for 7 days to prevent any possible postoperative infection. A non-steroidal anti-inflammatory agent (nimesulide, 100 mg, 12/12 h) and an analgesic (dipyrone, 500 mg, 6/6 h) were also prescribed. The sutures were removed 2 weeks after surgery, and all patients were instructed on mechanical tooth cleaning of the operated areas using a soft toothbrush and roll technique.²⁶ Patients were recalled after 1, 3, 6, and 16 months and received a reinforcement of oral hygiene, supragingival debridement, and tooth polishing.

Outcomes

Periodontal parameters were recorded before surgery (baseline) and at 1-, 3-, 6-, and 16-month follow-up visits by the same blinded and calibrated examiner (S.C.P). Individual acrylic stents were prepared for all patients for measurements at constant points. Demarcations were made on the patient model and transferred to an acrylic stent. The measurements assessed were: recession depth (RD in mm; CEJ to free gingival margin) (Figure 2A); probing depth (PD in mm; free gingival margin to the bottom of the sulcus) (Figure 2B); bleeding on probing (BOP; assessed within 30 seconds after probing to full pocket depth); clinical attachment level (CAL in mm; CEJ to the bottom of the sulcus); keratinized tissue width (KTW in mm; the most apical

point on free gingival margin to the mucogingival junction) (Figures 2C-D) and gingival thickness (GT) (Figures 2E-F). The measurements were recorded at the mid-buccal aspect of the tooth.

The PD, BOP, CAL, RD, and KTW were recorded using a University of North Carolina 15 probe (UNC, Hu-Friedy, Chicago, USA). The GT was measured under local anesthesia using a #15 endodontic reamer attached to a rubber stopper inserted perpendicularly into the gingival tissue at the mid-point location between the gingival margin and mucogingival junction, following which the thickness was measured to the nearest 0.1 mm using a digital caliper (Figures 2E-F).²⁷

The percentage of recession coverage (RC%) was calculated as the percentage of the recession depth for different experimental periods relative to the baseline. The variation Δ KTW and Δ GT was performed to calculate the differences between the values of the follow-up periods compared with the baseline data.

During surgery, the time spent on each side (group) was evaluated (in seconds). Photographs and the Laundry healing index were taken at baseline and at every follow-up' after surgery². The root coverage esthetic score (RES) was also used to assess esthetic outcomes following root coverage procedures in both groups.²⁸

Patient-reported outcomes

Postoperative discomfort was recorded using a visual analog scale (VAS). Patients recorded their pain levels for the first 7 and 15 days after the procedure on a horizontal scale, where the left endpoint indicated no pain (0), the middle point indicated medium pain (50), and the right endpoint indicated severe pain (100). Dentin sensitivity (DS) was determined from the participants' answers regarding the presence or absence of sensitivity at the cervical sites included in the study.

Sixteen months postoperatively, a questionnaire designed by Stefanini et al.²⁹ was given to all participants to gauge their perception of the treatment outcomes. The following questions were presented to the patients: Question 1: "What is your esthetic concern about the recession?" a) Excessive tooth length; b) Lack of gingiva; c) Color contrast; d)

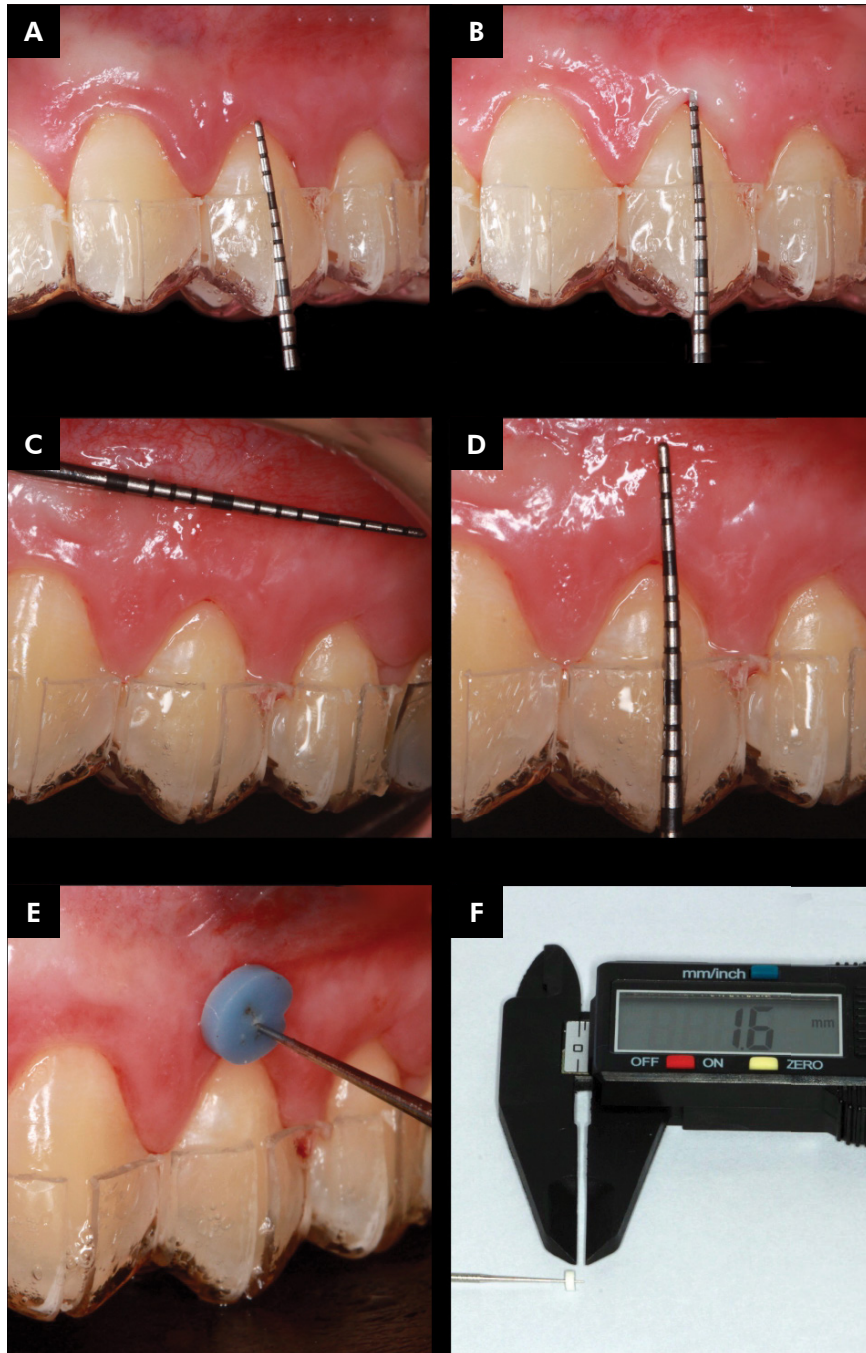


Figure 2. Clinical measures. A: Recession depth; B: Probing depth; C: Mucogingival junction localization; D: Keratinized tissue width; E: Gingival thickness (GT); F: Digital caliper for GT measure.

No complaints; selecting multiple answers was permissible; and Question 2: Which method of treatment and esthetic outcome do you prefer?" a) Left side; b) right side; c) no difference; any one possible answer had to be selected. The patients were also asked to express their overall satisfaction

with the treatment outcomes on a 10-centimetre VAS, with one for each side.²⁹

Sample size

A sample size calculation suggested that a minimum of 12 patients were needed to demonstrate

a 1-mm difference in RD levels between the study groups after treatment [90% power, $\alpha = 0.05$, and a standard deviation of 0.69⁹]. Considering the dropout rate, 14 patients were included in this study.

Randomization and allocation concealment mechanism

On the day of surgery, immediately before the procedure, randomization was performed by a researcher (T.M.I.C) using a coin flip. The same researcher used an opaque envelope that was sealed for allocation concealment, and randomization determined the therapy for each patient's side. The envelope was given to the surgeon before the procedure.

Blinding and examiner calibration

All ECL procedures were performed by the same experienced surgeon (N.V.R.J). An investigator blinded to the treatment (S.C.P) performed participant documentation, clinical measurements, and questionnaire administration. For intra-examiner calibration, repeated measurements of RD in five patients were performed over 2 weeks for reliability testing (Pearson's correlation coefficient, $r = 0.9086$).

Statistical analysis

The experimental data were subjected to the D'Agostino-Pearson normality test. As the RD, PD, CAL, GT, KTW, GT, and KTW values were normally distributed, these were analyzed using the paired t-test for comparison between both groups and the repeated measures ANOVA followed by the Tukey post-test for longitudinal analysis within each group. The recession coverage percentage (RC) distribution was not normal; therefore, these were analyzed using the Wilcoxon test for comparison between both groups and the Friedman test complemented by the Dunn post-test for longitudinal analysis within each group. Comparisons between groups for BOP, DS, and complete recession coverage percentage (CRC) were made using the chi-square test. For the Laundry index, patient VAS scores (pain and esthetic), and RES score, analysis was performed using the Wilcoxon test. The Friedman

test, complemented by post-hoc Dunn's test, was used for longitudinal analysis within each group. Statistical analyses were performed using the GraphPad Prism 6 software (San Diego, USA). Differences were considered significant when the p-value was < 0.05 .

RESULTS

Study population

Fourteen patients (7 men and 7 women, 23–56 years; mean age, 35 years) enrolled in the study completed all examinations over 16 months (Figure 3). In these patients, 72 Miller Class I (or Cairo RT 1) recession-type defects (in each group, 2 maxillary incisors, 19 maxillary canines, and 51 maxillary premolars) were treated.

Outcomes

The baseline and postoperative parameters are summarized in Tables 1-4. At baseline, there were no statistically significant differences in the RD, PD, BOP, CAL, and GT values between the CTG and PRF groups (Tables 1 and 2). There was a significant difference between the two groups in the KTW values at baseline, with higher values observed in the PRF group. The RD values decreased significantly in the two groups from baseline to 16 months. However, RD values were lower in the CTG group at 1, 3, 6, and 16 months (Table 1).

In the PRF and CTG groups, the PS value increased significantly from baseline to 6 and 16 months, respectively, but there was no statistically significant difference between the two groups (Table 1). The CAL values decreased in both study groups from baseline to 16 months ($p < 0.05$); however, the CAL values were lower in the CTG group after 6 months (Table 1). Additionally, higher KTW values were observed in the CTG group at 1, 6, and 16 months postoperatively (Table 1). In comparison to baseline, a significant reduction in KTW values was observed for the CTG group after 3, 6, and 16 months and for the PRF group at all indicated time points (Table 1). Similarly, higher GT values were reported in the CTG group after 3 and 6 months (Table 1). A decrease in GT was observed in both groups after 16 months

compared to 3 and 6 months (Table 1). In contrast, though not statistically significant, the surgical

procedure time on the CTG side was longer than that on the PRF side (Table 1).

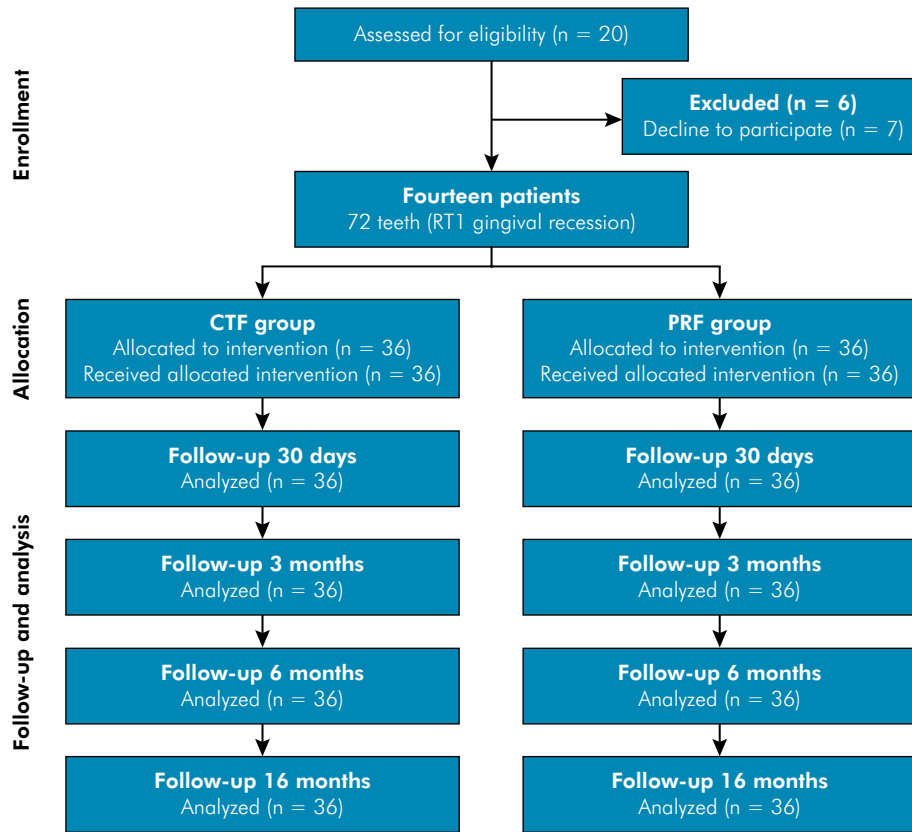


Figure 3. Flowchart depicting the study design.

Table 1. Clinical parameters at baseline, 1, 3, 6, and 16 months for connective tissue graft (CTG) and platelet-rich fibrin (PRF) groups.

Parameter/ Group	CTG					PRF				
	Baseline	1 month	3 months	6 months	16 months	Baseline	1 month	3 months	6 months	16 months
RD (mm)	1.87 ± 0.91 ^b	0.98 ± 0.89 ^a	0.87 ± 0.81 ^a	0.70 ± 0.76 ^a	0.81 ± 0.68 ^a	1.63 ± 0.78 ^c	1.43 ± 0.89 ^{b,c}	1.20 ± 0.69 ^{a,b}	1.14 ± 0.76 ^a	1.23 ± 0.71 ^{a,b}
PD (mm)	1.44 ± 0.48 ^a	1.86 ± 0.96 ^b	1.90 ± 0.55 ^b	1.94 ± 0.53 ^{a,b}	1.72 ± 0.57 ^{a,b}	1.59 ± 0.59 ^{a,b}	2.00 ± 0.66 ^c	1.83 ± 0.60 ^{b,c}	1.86 ± 0.67 ^{b,c}	1.50 ± 0.45 ^a
CAL (mm)	3.31 ± 1.05 ^b	3.23 ± 1.10 ^b	2.91 ± 0.92 ^{a,b}	2.70 ± 0.89 ^a	2.54 ± 0.63 ^a	3.09 ± 1.06 ^{a,b}	3.51 ± 0.92 ^b	3.01 ± 0.90 ^a	2.98 ± 1.11 ^a	2.73 ± 0.82 ^a
KTW (mm)	3.55 ± 1.10 ^{a,b}	4.27 ± 1.25 ^a	2.93 ± 0.91 ^c	3.04 ± 1.12 ^b	3.02 ± 1.04 ^c	4.35 ± 1.63 ^a	3.37 ± 1.27 ^b	2.78 ± 1.03 ^c	2.51 ± 1.00 ^c	2.44 ± 0.73 ^c
GT (mm)	1.44 ± 0.41 ^b	-	1.81 ± 0.56 ^a	1.67 ± 0.61 ^{a,b}	1.44 ± 0.50 ^b	1.41 ± 0.36 ^a	-	1.43 ± 0.47 ^{a,b}	1.38 ± 0.55 ^{a,b}	1.20 ± 0.39 ^b
Surgery time (s)	3202 ± 693.4	-	-	-	-	3082 ± 808.3	-	-	-	-

RD: recession depth, PD: probing depth; CAL: clinical attachment level; KTW: keratinized tissue width; GT: gingival thickness; ^{a,b}Different letters represent statistically significant differences between each follow-up period in the same group (p < 0.05); *p < 0.05 indicates statistically significant differences between groups in the same period.

Higher RC values were obtained for the CTG group during all periods of analysis (Table 2). A reduction in DS was observed in the CTG and PRF groups from baseline to 3 months; however, the differences between the groups were not statistically significant (Table 3). A higher CRC was obtained for CTG than for PRF at all time points (Table 3).

During the postoperative period, all the recipient sites in the CTG and PRF groups healed

uneventfully. The VAS score for pain during the first postoperative week was lower in the PRF group; however, the difference was not statistically significant (Table 4). A good healing process (laundry healing index) was observed for both groups at postoperative 7 and 15 days, without differences between them (Table 4). At 3 months, excellent healing was observed in both groups (Table 4).

Table 2. Recession coverage percentage after 1, 3, 6, and 16 months of post-operative for connective tissue graft (CTG) and platelet-rich fibrin (PRF) groups; the variation of keratinized tissue width and gingival thickness relating to the follow-up values compared with the baseline for both groups.

Parameter/ Group	CTG				PRF			
	1 month	3 months	6 months	16 months	1 month	3 months	6 months	16 months
RC (%)	50.89 (50.00) ± 39.33*	55.03 (55.00) ± 39.77*	62.42 (69.50) ± 38.11*	55.42 (50.00) ± 37.14*	26.44 (0.00) ± 36.66	29.47 (29.50) ± 32.83	34.00 (29.50) ± 36.14	29.53 (25.00) ± 34.08
Δ KTW (mm)	0.72 ± 1.79 ^b	-0.62 ± 1.16 ^a	-0.51 ± 1.07 ^a	-0.52 ± 1.04 ^a	-0.97 ± 1.89 ^b	-1.56 ± 1.53 ^a	-1.83 ± 1.49 ^a	-1.90 ± 1.41 ^a
Δ GT (mm)	-	0.36 ± 0.63 ^b	0.21 ± 0.63 ^{a,b}	0.002 ± 0.59 ^a	-	0.01 ± 0.51*	-0.03 ± 0.60*	-0.20 ± 0.45

RC: recession coverage; Δ KTW: variation of the keratinized tissue width; Δ GT: variation of the gingival thickness; ^{a,b}Different letters represent statistically significant differences between each follow-up period in the same group (p < 0.05); *p < 0.05 indicates statistically significant differences between groups in the same period.

Table 3. Frequency of bleeding on probing (BOP), dentin sensitivity (DS), and complete recession coverage (CRC) at 1, 3, 6 and 16 months connective tissue graft (CTG) and platelet-rich fibrin (PRF) groups.

Parameter/ Group	CTG					PRF				
	Baseline	1 month	3 months	6 months	16 months	Baseline	1 month	3 months	6 months	16 months
BOP	4 (11.11%)	9 (25.00%)*	11 (30.55%)	5 (13.88%)	8 (22.22%)	6 (16.21%) ^a	19 (51.35%) ^b	17 (45.94%) ^b	13 (35.13%) ^a	7 (18.91%) ^a
DS	12 (33.33%)	9 (25.00%)	5 (13.88%)	-	-	11 (29.72%) ^b	11 (29.72%) ^b	8 (21.62%) ^{a,b}	-	-
CRC	-	16 (44.44%) [#]	17 (47.22%) [#]	20 (55.55%) [#]	15 (41.66%) [#]	-	9 (24.32%)	10 (27.02%)	12 (32.43%)	9 (24.32%)

^{a,b}Different letters represent statistically significant differences between each follow-up period in the same group (p < 0.05); *p < 0.05 Lower BOP than PRF group; # Higher CTC in comparison to PRF group.

Table 4. Median and 25th and 75th for visual analogue scale (VAS) for pain and Laundry healing index of connective tissue graft (CTG) and platelet-rich fibrin (PRF) groups.

Parameter/Group	VAS score (Pain)		Laundry healing index	
	CTG	PRF	CTG	PRF
7 days	3.90 (1.22-7.65) ^a	2.40 (0.87-3.92) ^a	3.00 (2.00-3.00) ^a	3.00 (2.00-3.00) ^a
15 days	0.55 (0.00-2.12) ^b	1.00 (0.00-1.72) ^b	3.00 (2.75-4.00) ^{a,b}	3.00 (3.00-4.00) ^{a,b}
1 month	-	-	4.00 (4.00-5.00) ^{b,c}	4.50 (4.00-5.00) ^{b,c}
3 months	-	-	5.00 (4.75-5.00) ^c	5.00 (5.00-5.00) ^c

^{a,b}Different letters represent statistically significant differences between each follow-up period in the same group (p < 0.05).

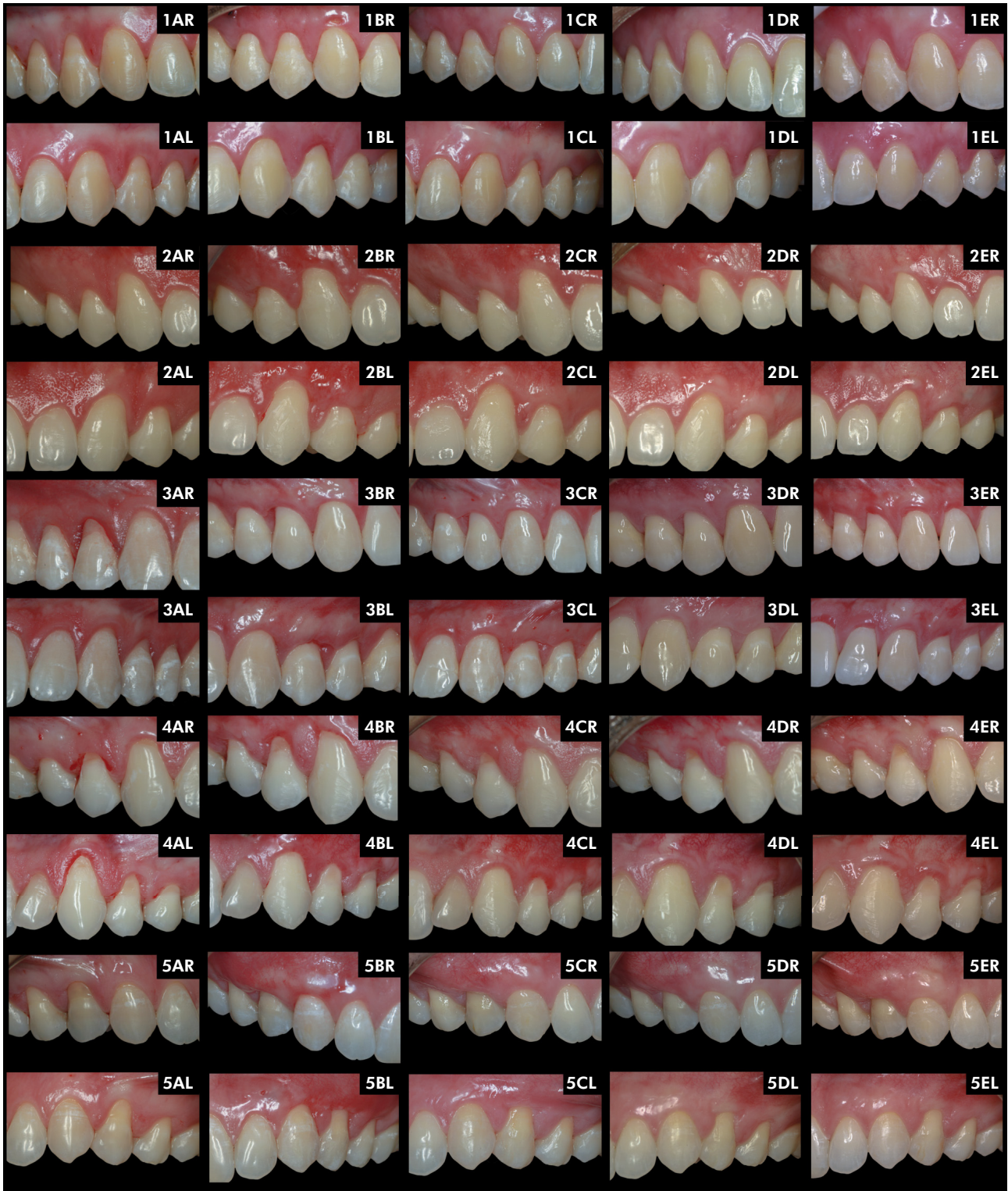

Figure 4. Photographic images of both sides for cases 1-5. A: Baseline; B: 1 month follow-up; C: 3 months follow-up; D: 6 months follow-up; E: 16 months follow-up; cases 1-4, PRF group: right side (R); CTG group: left side (L); case 5, PRF group: left side (L); CTG group: right side (R).

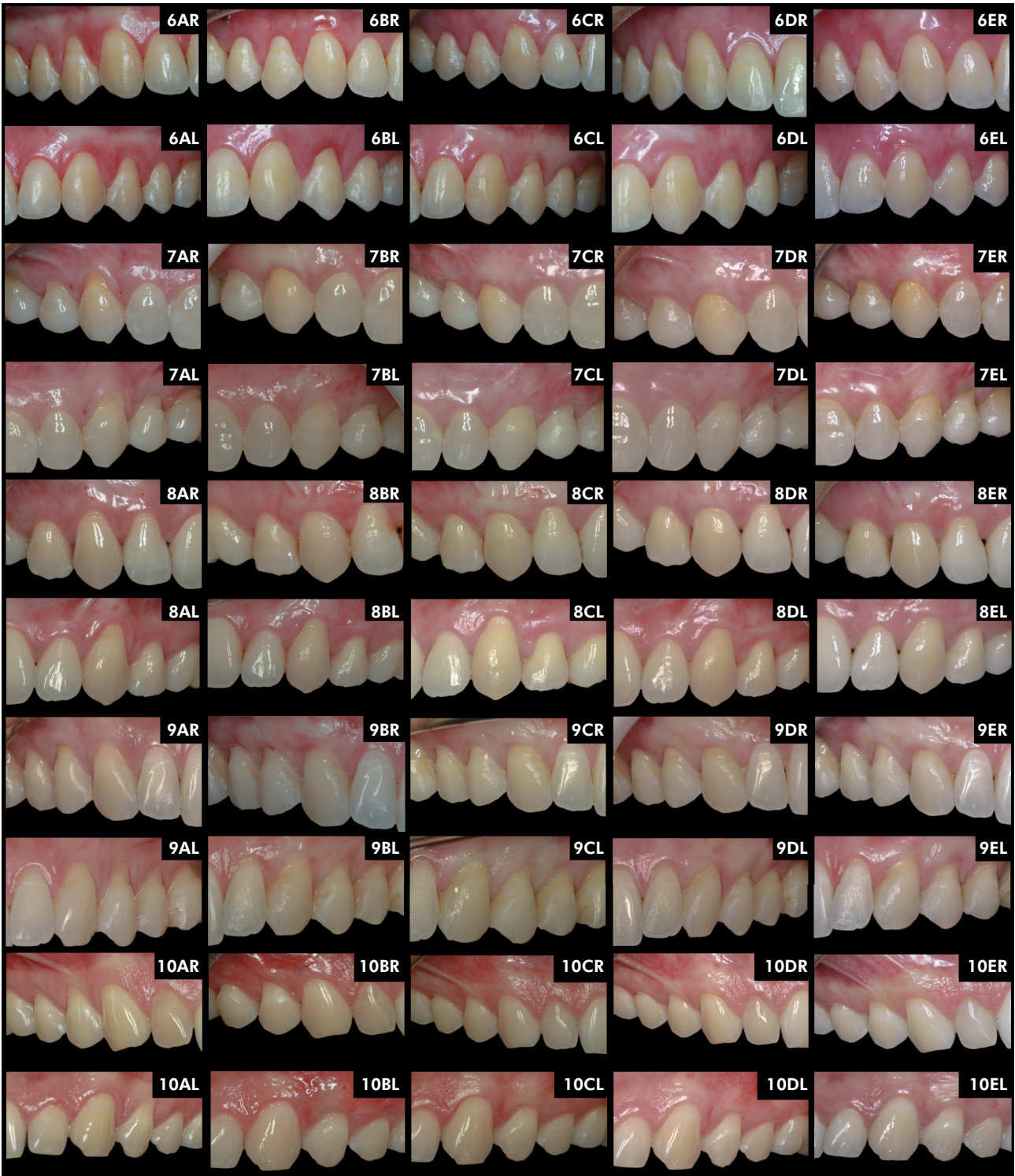


Figure 5. Photographic images of both sides for cases 5-10. A: Baseline; B: 1 month follow-up; C: 3 months follow-up; D: 6 months follow-up; E: 16 months follow-up; cases 6-9, PRF group: left side (L); CTG group: right side (R); case 10, PRF group: right side (R); CTG group: left side (L).

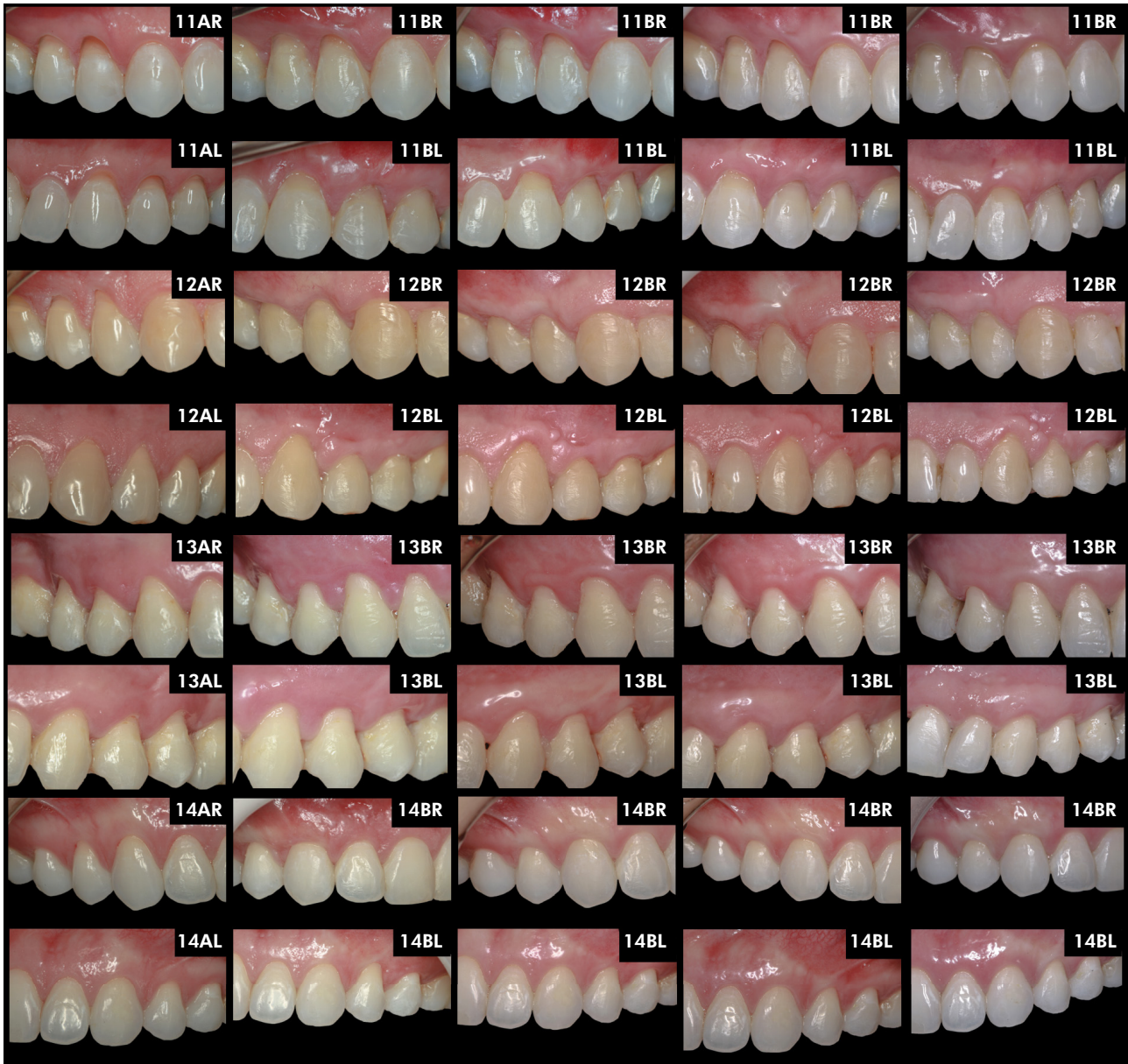

Figure 6. Photographic images of both sides for cases 11-14. A: Baseline; B: 1 month follow-up; C: 3 months follow-up; D: 6 months follow-up; E: 16 months follow-up; cases 11 and 13, PRF group: right side (R); CTG group: left side (L); cases 12 and 14, PRF group: left side (L); CTG group: right side (R).

No differences in RES score were observed between the CTG group [7.00 (6.00–10.00)] in comparison to the PRF group [7.00 (4.00–9.50)] after 16 months of follow-up. However, higher patient satisfaction (VAS score) was observed for the CTG

group [9.65 (7.97–10.00)] in comparison to the PRF group [8.60 (7.67–9.62)] ($p < 0.05$). Regarding the evaluation of the questionnaires by Stefanini et al.,²⁹ nine patients preferred the side of the CTG technique compared to five who preferred the

side using the PRF technique. The biggest esthetic concerns of patients in both groups were the lack of gingiva (CTG, 10 patients vs. PRF, 11 patients), excessive tooth length (CTG, 3 patients vs. PRF, 3 patients), and color contrast (CTG, 1 vs. PRF, 1). No concerns were reported in one patient.

Discussion

As per the findings of the present study, both CTG and PRF membrane techniques reduced RD and CAL values following a 16 month follow-up period. However, the use of CTG resulted in significantly superior clinical outcomes (RD, CAL, KTW, GT, RC, and CRC) and was associated with greater patient satisfaction. To our knowledge, no clinical study has compared gingival recession coverage using CTG or PRF associated with the TT in multiple gingival recessions.

Similarly to our study, the use of both PRF and CTG in the gingival recession treatment promoted an RD and CAL reduction after 6 months of follow-up.^{3,13,30} The potential of PRF may be associated with the intrinsic incorporation of cytokines into the membrane mesh. Progressive cytokine release occurs over time as the fibrin disintegrates.³¹ In this way, the PRF induces the proliferation of periodontal ligament cells, gingival fibroblasts, and osteoblasts while acting as the inhibitor of epithelial cells³². It has been hypothesized that the suppression of epithelial cell proliferation by PRF can prevent the junctional epithelium from down growing to the root surfaces, which might facilitate new attachment formation after root coverage procedures.³² Hegde et al.³⁰ in a parallel study including 32 patients with multiple defects treated using vestibular incision subperiosteal tunnel access [VISTA] obtained an RD of 0.500 ± 0.816 mm for CTG+VISTA and 0.813 ± 1.56 mm for PRF+VISTA after 6 months of follow-up. In addition, Öncü et al.,³ in a split-mouth study that included 20 patients with multiple gingival recessions, compared the use of CTG or PRF associated with a modified coronally advanced flap (MCAP). An RD of 0.68 ± 0.92 mm for CTG+MCAP and 0.90 ± 1.03 mm for PRF+MCAP was obtained after 6 months

of follow-up. However, no significant differences were observed between the PRF and CTG groups in either study. In contrast, a greater RD value reduction was observed in the CTG group than in the PRF group after 16 months in our study.

This coronal improvement in the marginal gingival level in the CTG group might be attributed to the creeping attachment effect over time associated with the higher gingival thickness achieved with CTG³³ mainly after 6 months in the present study. Similar to our study, literature has shown that CTG promotes a higher KT gain than PRF.^{2,3,9-13} This can be explained by the ability of CTG (removed from the palate) to promote keratinized epithelium formation.³⁴ In contrast, the relatively rapid degradation of PRF, with a subsequent reduction in cytokine release,⁷ could negatively interfere with the potential of PRF to improve soft-tissue healing in the long term.⁸ Moreover, although the PRF group showed a higher baseline KTW value, the long-term KTW was significantly lower than the baseline value in our study. This suggests that additional soft tissue augmentation promoted by CTG is essential for improving gingival recession outcomes.³⁵ Thus, CTG appears to be a better choice than PRF for the treatment of gingival recessions associated with limited KT width and gingival thickness.¹¹

The PRF membrane also acts as a scaffold that maintains the space for cellular events associated with periodontal healing.³⁶ A greater number of PRF layers is favorable for root coverage.¹² Therefore, we used three PRF membranes in the test group, because it was not possible to insert a larger number of PRF membranes inside the tunnel without damaging the flap. Culhaoglu et al.¹² compared different numbers of PRF membrane layers (two or four) with CTG for the treatment of Miller class I GR. Clinical attachment gain and RD were higher in the 4PRF+CAF and CTG+CAF groups than in the 2PRF+CAF group, suggesting that PRF membranes should use as many layers as possible. However, the increase in GT was also significantly higher in the CTG+CAF group after 6 months, regardless of the number of membranes.

Although the differences were not statistically significant, a longer surgical time and a higher VAS score for pain (7 days) were observed for the CTG side than for the PRF side. Our results were similar to those of many other studies favoring the PRF group.^{3,9,12,13} Both of these parameters are associated with the requirement for donor-site surgery, which results in postoperative pain and discomfort. In addition, the CTG acquisition technique requires precision, expertise, and additional training.⁹ In addition, the growth factors in PRF stimulate tissue repair, reducing inflammation and subsequent pain and discomfort.³⁷

Clinical studies have described improvements in early wound healing (first and second weeks postoperatively) with the PRF membrane use^{9,13,31} This acceleration in the healing process might be associated with the main growth factors in PRF, including PDGF, VEGF, and TGF, which enhance soft tissue healing by increasing angiogenesis and matrix biosynthesis during wound healing.³⁸ However, no differences were observed between CTG and PRF in the present study with regard to the Laundry healing index. The high level of healing observed in both groups may be associated with the use of the TT on both sides. The tunnel technique has been proposed because it avoids vertically releasing incisions and does not incise the papillae, which may improve the vascularization of the area. Therefore, this technique ensures a premature esthetic result and satisfactory healing because adequate blood supply is necessary to maintain the stability of the gingival attachment to the root surface.³⁹ Skierska et al.⁴⁰ reported satisfactory values for RC (93.31%) and CRC (87.43%) after 2 years of follow-up using the TT associated with CTG in a retrospective study. However, limited gains in RC, CRC, KT width, and gingival thickness were observed on both sides in our study, with a reduction in these gains after 16 months. A possible explanation for this finding is the inclusion of patients with occlusal disorders and parafunctional habits. Furthermore, fair oral hygiene rather than meticulous plaque control was observed in some of the included patients.

Lastly, superior performance of CTG compared to PRF was observed in the VAS score for the esthetic and patient satisfaction questionnaires. These results may be associated with the greater RD reduction and gingival thickness gain observed in the CTG group, which highlights the fact that PRF alone is insufficient to improve areas with deficiencies in KT¹¹. On the other hand, Kumar et al.⁹ evaluated 45 gingival recessions randomly and equally divided into CAF+PRF, CAF+CTG, and CAF alone groups and showed higher patient comfort esthetic scores for CAF+PRF followed by CAF alone and CAF+CTG groups. No difference was observed in the RES scores between the groups. The RES is a scoring system proposed by Cairo et al.²⁸ to assess esthetic outcomes following root coverage procedures. This system was proposed to categorize esthetic assessments and avoid the subjective perceptions of both patients and clinicians in the evaluation of root coverage outcomes.

The present study had some limitations. Although the number of patients included in this study was defined by an adequate sample size calculation, further studies with larger sample sizes may be valuable to authenticate the superiority of CTG for PRF associated with the TT in multiple gingival recessions. In addition, the 16-month follow-up period may be considered short, because additional healing may occur over a longer period (5 years). In addition, we hypothesized that the lower KTW after the procedure in both groups could be associated with certain difficulties in KTW measurements, presumably related to tissue maturation in the first year after surgery, as the KT was measured manually only by visual inspection in this study.

Within the limitations of this study, it was concluded that CTG associated with the TT resulted in significantly better clinical and patient-related outcomes than PRF in multiple gingival recession treatments.

Acknowledgment

The authors acknowledge the scholarships from National Council for Scientific and Technological Development (PIBIC/CNPq; Process number 134955/2019-6).

References

1. Cairo F, Pagliaro U, Buti J, Baccini M, Graziani F, Tonelli P, et al. Root coverage procedures improve patient aesthetics: a systematic review and Bayesian network meta-analysis. *J Clin Periodontol*. 2016 Nov;43(11):965-75. <https://doi.org/10.1111/jcpe.12603>
2. Mufti S, Dadawala SM, Patel P, Shah M, Dave DH. comparative evaluation of platelet-rich fibrin with connective tissue grafts in the treatment of miller's class i gingival recessions. *Contemp Clin Dent*. 2017;8(4):531-7. https://doi.org/10.4103/ccd.ccd_325_17
3. Öncü E. The use of platelet-rich fibrin versus subepithelial connective tissue graft in treatment of multiple gingival recessions: a randomized clinical trial. *Int J Periodont Restor Dent*. 2017;37(2):265-71. <https://doi.org/10.11607/prd.2741>
4. Dohan DM, Choukroun J, Diss A, Dohan SL, Dohan AJ, Mouhyi J, et al. Platelet-rich fibrin (PRF): a second-generation platelet concentrate. Part I: Technological concepts and evolution. *Oral Surg Oral Med Oral Pathol Oral Radiol Endod*. 2006 Mar;101(3):e37-44. <https://doi.org/10.1016/j.tripleo.2005.07.008>
5. Dohan Ehrenfest DM, Rasmusson L, Albrektsson T. Classification of platelet concentrates: from pure platelet-rich plasma (P-PRP) to leucocyte- and platelet-rich fibrin (L-PRF). *Trends Biotechnol*. 2009 Mar;27(3):158-67. <https://doi.org/10.1016/j.tibtech.2008.11.009>
6. Goldstein M, Boyan BD, Cochran DL, Schwartz Z. Human histology of new attachment after root coverage using subepithelial connective tissue graft. *J Clin Periodontol*. 2001 Jul;28(7):657-62. <https://doi.org/10.1034/j.1600-051x.2001.028007657.x>
7. Dohan Ehrenfest DM, de Peppo GM, Doglioli P, Sammartino G. Slow release of growth factors and thrombospondin-1 in Choukroun's platelet-rich fibrin (PRF): a gold standard to achieve for all surgical platelet concentrates technologies. *Growth Factors*. 2009 Feb;27(1):63-9. <https://doi.org/10.1080/08977190802636713>
8. Moraschini V, Barboza ES. Use of platelet-rich fibrin membrane in the treatment of gingival recession: a systematic review and meta-analysis. *J Periodontol*. 2016 Mar;87(3):281-90. <https://doi.org/10.1902/jop.2015.150420>
9. Kumar A, Bains VK, Jhingran R, Srivastava R, Madan R, Rizvi I. Patient-centered microsurgical management of gingival recession using coronally advanced flap with either platelet-rich fibrin or connective tissue graft: a comparative analysis. *Contemp Clin Dent*. 2017;8(2):293-304. https://doi.org/10.4103/ccd.ccd_70_17
10. Castro AB, Meschi N, Temmerman A, Pinto N, Lambrechts P, Teughels W, et al. Regenerative potential of leucocyte- and platelet-rich fibrin. Part A: intra-bony defects, furcation defects and periodontal plastic surgery: a systematic review and meta-analysis. *J Clin Periodontol*. 2017 Jan;44(1):67-82. <https://doi.org/10.1111/jcpe.12643>
11. Miron RJ, Moraschini V, Del Fabbro M, Piattelli A, Fujioka-Kobayashi M, Zhang Y, et al. Use of platelet-rich fibrin for the treatment of gingival recessions: a systematic review and meta-analysis. *Clin Oral Investig*. 2020 Aug;24(8):2543-57. <https://doi.org/10.1007/s00784-020-03400-7>
12. Culhaoglu R, Taner L, Guler B. Evaluation of the effect of dose-dependent platelet-rich fibrin membrane on treatment of gingival recession: a randomized, controlled clinical trial. *J Appl Oral Sci*. 2018 May;26(0):e20170278. <https://doi.org/10.1590/1678-7757-2017-0278>
13. Jankovic S, Aleksic Z, Klokkevold P, Lekovic V, Dimitrijevic B, Kenney EB, et al. Use of platelet-rich fibrin membrane following treatment of gingival recession: a randomized clinical trial. *Int J Periodont Restor Dent*. 2012 Apr;32(2):e41-50.
14. Eren G, Kantarcı A, Sculean A, Atilla G. Vascularization after treatment of gingival recession defects with platelet-rich fibrin or connective tissue graft. *Clin Oral Investig*. 2016 Nov;20(8):2045-53. <https://doi.org/10.1007/s00784-015-1697-8>
15. Raetzke PB. Covering localized areas of root exposure employing the "envelope" technique. *J Periodontol*. 1985 Jul;56(7):397-402. <https://doi.org/10.1902/jop.1985.56.7.397>
16. Allen AL. Use of the suprapariosteal envelope in soft tissue grafting for root coverage. I. Rationale and technique. *Int J Periodontics Restorative Dent*. 1994 Jun;14(3):216-27.
17. Allen AL. Use of the suprapariosteal envelope in soft tissue grafting for root coverage. II. Clinical results. *Int J Periodontics Restorative Dent*. 1994 Aug;14(4):302-15.
18. Ribeiro FS, Zandim DL, Pontes AE, Mantovani RV, Sampaio JE, Marcantonio E Jr. Tunnel technique with a surgical maneuver to increase the graft extension: case report with a 3-year follow-up. *J Periodontol*. 2008 Apr;79(4):753-8. <https://doi.org/10.1902/jop.2008.070274>
19. Tavelli L, Barootchi S, Nguyen TV, Tattan M, Ravidà A, Wang HL. Efficacy of tunnel technique in the treatment of localized and multiple gingival recessions: a systematic review and meta-analysis. *J Periodontol*. 2018 Sep;89(9):1075-90. <https://doi.org/10.1002/JPER.18-0066>
20. Miller PD Jr. A classification of marginal tissue recession. *Int J Periodontics Restorative Dent*. 1985;5(2):8-13.
21. Cairo F, Nieri M, Cincinelli S, Mervelt J, Pagliaro U. The interproximal clinical attachment level to classify gingival recessions and predict root coverage outcomes: an explorative and reliability study. *J Clin Periodontol*. 2011 Jul;38(7):661-6. <https://doi.org/10.1111/j.1600-051X.2011.01732.x>
22. Silness J, Loe H. Periodontal disease in pregnancy. II. Correlation between oral hygiene and periodontal condition. *Acta Odontol Scand*. 1964 Feb;22(1):121-35. <https://doi.org/10.3109/00016356408993968>

23. Loe H, Silness J. Periodontal disease in pregnancy. I. Prevalence and severity. *Acta Odontol Scand.* 1963 Dec;21(6):533-51. <https://doi.org/10.3109/00016356309011240>
24. Dohan DM, Choukroun J, Diss A, Dohan SL, Dohan AJ, Mouhy J, et al. Platelet-rich fibrin (PRF): a second-generation platelet concentrate. Part II: platelet-related biologic features. *Oral Surg Oral Med Oral Pathol Oral Radiol Endod.* 2006 Mar;101(3):e45-50. <https://doi.org/10.1016/j.tripleo.2005.07.009>
25. Hürzeler MB, Weng D. A single-incision technique to harvest subepithelial connective tissue grafts from the palate. *Int J Periodontics Restorative Dent.* 1999 Jun;19(3):279-87.
26. Aroca S, Molnár B, Windisch P, Gera I, Salvi GE, Nikolidakis D, et al. Treatment of multiple adjacent Miller class I and II gingival recessions with a Modified Coronally Advanced Tunnel (MCAT) technique and a collagen matrix or palatal connective tissue graft: a randomized, controlled clinical trial. *J Clin Periodontol.* 2013 Jul;40(7):713-20. <https://doi.org/10.1111/jcpe.12112>
27. Eren G, Atilla G. Platelet-rich fibrin in the treatment of localized gingival recessions: a split-mouth randomized clinical trial. *Clin Oral Investig.* 2014 Nov;18(8):1941-8. <https://doi.org/10.1007/s00784-013-1170-5>
28. Cairo F, Rotundo R, Miller PD Jr, Pini Prato GP. Root coverage esthetic score: a system to evaluate the esthetic outcome of the treatment of gingival recession through evaluation of clinical cases. *J Periodontol.* 2009 Apr;80(4):705-10. <https://doi.org/10.1902/jop.2009.080565>
29. Stefanini M, Jepsen K, de Sanctis M, Baldini N, Greven B, Heinz B, et al. Patient-reported outcomes and aesthetic evaluation of root coverage procedures: a 12-month follow-up of a randomized controlled clinical trial. *J Clin Periodontol.* 2016 Dec;43(12):1132-41. <https://doi.org/10.1111/jcpe.12626>
30. Hegde S, Madhurkar JG, Kashyap R, Kumar MS, Bloor V. Comparative evaluation of vestibular incision subperiosteal tunnel access with platelet-rich fibrin and connective tissue graft in the management of multiple gingival recession defects: A randomized clinical study. *J Indian Soc Periodontol.* 2021;25(3):228-36. https://doi.org/10.4103/jisp.jisp_291_20
31. Kuka S, Ipci SD, Cakar G, Yılmaz S. Clinical evaluation of coronally advanced flap with or without platelet-rich fibrin for the treatment of multiple gingival recessions. *Clin Oral Investig.* 2018 Apr;22(3):1551-8. <https://doi.org/10.1007/s00784-017-2225-9>
32. Tsai CH, Shen SY, Zhao JH, Chang YC. Platelet-rich fibrin modulates cell proliferation of human periodontally related cells in vitro. *J Dent Sci.* 2009;4(3):130-5. [https://doi.org/10.1016/S1991-7902\(09\)60018-0](https://doi.org/10.1016/S1991-7902(09)60018-0)
33. Guiha R, el Khodeiry S, Mota L, Caffesse R. Histological evaluation of healing and revascularization of the subepithelial connective tissue graft. *J Periodontol.* 2001 Apr;72(4):470-8. <https://doi.org/10.1902/jop.2001.72.4.470>
34. Hofmänner P, Alessandri R, Laugisch O, Aroca S, Salvi GE, Stavropoulos A, et al. Predictability of surgical techniques used for coverage of multiple adjacent gingival recessions—A systematic review. *Quintessence Int.* 2012;43(7):545-54.
35. Zuhr O, Rebele SF, Vach K, Petsos H, Hürzeler MB; Research Group for Oral Soft Tissue Biology & Wound Healing. Tunnel technique with connective tissue graft versus coronally advanced flap with enamel matrix derivate for root coverage: 2-year results of an RCT using 3D digital measuring for volumetric comparison of gingival dimensions. *J Clin Periodontol.* 2020 Sep;47(9):1144-58. <https://doi.org/10.1111/jcpe.13328>
36. Ramireddy S, Mahendra J, Rajaram V, Ari G, Kanakamedala AK, Krishnakumar D. Treatment of gingival recession by coronally advanced flap in conjunction with platelet-rich fibrin or resin-modified glass-ionomer restoration: A clinical study. *J Indian Soc Periodontol.* 2018;22(1):45-9. https://doi.org/10.4103/jisp.jisp_283_17
37. Gruber R, Varga F, Fischer MB, Watzek G. Platelets stimulate proliferation of bone cells: involvement of platelet-derived growth factor, microparticles and membranes. *Clin Oral Implants Res.* 2002 Oct;13(5):529-35. <https://doi.org/10.1034/j.1600-0501.2002.130513.x>
38. Kawase T, Okuda K, Wolff LF, Yoshie H. Platelet-rich plasma-derived fibrin clot formation stimulates collagen synthesis in periodontal ligament and osteoblastic cells in vitro. *J Periodontol.* 2003 Jun;74(6):858-64. <https://doi.org/10.1902/jop.2003.74.6.858>
39. Krismariono A. Less invasive vestibule access tunneling with platelet-rich fibrin membrane for the treatment of gingival recession. *J Contemp Dent Pract.* 2019 Sep;20(9):1024-8. <https://doi.org/10.5005/jp-journals-10024-2638>
40. Skierska I, Wyrębek B, Górski B. Clinical and aesthetic outcomes of multiple gingival recessions coverage with modified coronally advanced tunnel and subepithelial connective tissue graft in maxilla and mandible: a 2-year retrospective study. *Int J Environ Res Public Health.* 2022 Sep;19(17):11024. <https://doi.org/10.3390/ijerph191711024>