

# Analysis of the mental foramen using cone beam computerized tomography

*Análise do forame mental em tomografias computadorizadas de feixe cônico*

Kunihiro SAITO<sup>a</sup>, Ney Soares de ARAÚJO<sup>b</sup>, Miki Taketomi SAITO<sup>c</sup>,  
João de Jesus Viana PINHEIRO<sup>a</sup>, Pedro Luiz de CARVALHO<sup>a\*</sup>

<sup>a</sup>Faculdade de Odontologia, UFPA – Universidade Federal do Pará, Belém, PA, Brazil

<sup>b</sup>SLM – Centro de Pesquisas Odontológicas São Leopoldo Mandic,  
Faculdade de Odontologia, Campinas, SP, Brazil

<sup>c</sup>Faculdade de Odontologia, UNICAMP – Universidade Estadual de Campinas, Piracicaba, SP, Brazil

## Resumo

**Introdução:** O conhecimento das estruturas anatômicas localizadas na região entre os forames mentuais é de importância crucial nos planejamentos pré-operatórios. **Objetivo:** Avaliar a posição do forame mental relacionado aos ápices dos dentes, sua distância aos bordos da mandíbula com uso da tomografia computadorizada de feixe cônico. **Material e método:** Foram avaliadas 100 tomografias computadorizadas de feixe cônico da mandíbula realizada num único aparelho de tomografia. Cada imagem escolhida foi avaliada de forma repetida para ambos os lados da mandíbula, a posição do forame mental, indicando a região em que o forame se encontrava e as medidas do forame mental a cortical lingual e base da mandíbula. Os dados foram analisados inicialmente de forma descritiva. Um valor de  $p < 0,05$  foi escolhido como o nível de significância. **Resultado:** 42% dos forames mentuais estavam localizados no ápice do segundo pré-molar. A margem lingual do forame mental localizou-se em média de 3,1 mm a partir da cortical lingual. A margem inferior do forame mental foi localizada 7,25 mm acima da borda inferior da mandíbula. **Conclusão:** O forame mental localizou-se com maior frequência em nível dos ápices dos segundos pré-molares, com distância à cortical lingual, em média, de 3,1 mm e base da mandíbula, em média, de 7,25 mm.

**Descritores:** Nervo mandibular; mandíbula; tomografia computadorizada de feixe cônico.

## Abstract

**Introduction:** Knowledge of the anatomical structures located in the region between the mental foramina is of critical importance in pre-operative planning. **Objective:** To evaluate the position of the mental foramen relative to the apices of the teeth and the distance to the edges of the mandible, using cone beam computerized tomography. **Material and method:** One hundred cone beam computerized tomographs of the mandible were evaluated; the tomographs were taken using a single tomographic device. Each image chosen was evaluated repeatedly from both sides of the mandible, the position of the mental foramen, indicating the region in which the foramen was found and the measures of the mental foramen, the lingual cortex and the mandibular base. Initially, the data were analyzed descriptively. A value of  $p < 0.05$  was chosen as the level of significance. **Result:** Forty-two percent of the mental foramina were located in the apex of the second pre-molar. The lingual margin of the mental foramen was located, on average, 3.1mm from the lingual cortex. The lower margin of the mental foramen was located 7.25 mm above the lower edge of the mandible. **Conclusion:** The mental foramen was located more frequently at a level of the apices of the second pre-molars, with a distance to the lingual cortex, on average, of 3.1mm and to the base of the mandible, on average, of 7.25 mm.

**Descriptors:** Mandibular nerve; mandible; cone-beam computed tomography.

## INTRODUCTION

The mental foramen is an important reference in the external surface of the mandible in the region below the pre-molars, and its variations of position have been studied in different ethnic groups<sup>1-7</sup>. Regarding the location of the mental foramen, there is

considerable anatomical variation in the vertical and horizontal planes. Although most studies have located the mental foramen below the second pre-molar, the positions may range from below the canine to below the first molar. Following extractions of teeth

with posterior ridge resorption, the mental foramen may become located near the bony crest and the mental nerve will be particularly prone to injury during surgical procedures. The mental nerve may be injured during local anesthesia, endodontic treatment and other oral and dental surgical procedures.

The region between the mental foramina and the mandible is considered a safe region for surgical procedures such as the removal of bone graft, placement of plates for the fixation of fractures, mentoplasty and orthognathic surgery since it presents little risk of injury to the neurovascular structures. Also, it is the preferred area for the placement of osseointegratable implants in completely edentulous patients, mainly because it has adequate bone morphology and supports sufficient bone.

Knowledge of anatomical structures located in the region between the mental foramina is of critical important in pre-operative planning. The treatment protocol for dental implants requires examination using imaging, prior to placing the dental implant. Radiographic examination is an important part of the planning for the surgery for the installation of implants, used primarily to locate anatomical structures and to evaluate bone quality and quantity; also, it is indicated for post-surgical follow-up. During planning, it is important to determine anatomical points such as the mandibular canal and the mental foramen in the posterior edentulous mandible, in order to avoid damage to the nerve or vascular trauma which may result in numbness in the lower lip and chin.

Pre-operative evaluation and planning are of fundamental importance in the determination of the success of the treatment. Various methods of imaging diagnosis may be used, but the indication and the limitations of each technique must be observed and taken into consideration during the interpretation<sup>8</sup>.

The helical or spiral (*Fan-Beam*) computerized tomography technique is an evolution of the tomographic exam, in which the X-ray tube moves in a spiral around the patient and the emission of the X-ray beam and the movement of the table occur simultaneously. One advantage of the spiral (*Fan-Beam*) computerized tomography for dentistry is the possibility of working with the window of soft tissue, making it the exam of choice when it is necessary to evaluate changes in those tissues. The *Cone-Beam* computerized tomography is obtained using equipment that emits an X-ray beam in the shape of a cone. The source-detector set of X-rays performs a 360° rotation around the patient's head, and every turn of the device acquires a base image of the patient's head appearing very much like a profile radiographic image. At the conclusion of the exam, this sequence of base images is reconstructed, using specific software, to generate the images. *Cone-Beam* computerized tomography, in addition to its low cost and lower dose of radiation in relation to the spiral (*Fan-Beam*) computerized tomography, gives better visualization of the anatomical references. This contributes to the reduction of damage to the nerves and blood vessels, and the improved efficiency of anesthetic blocks<sup>9-12</sup>.

The use of endosseous implants currently represents one of the best techniques available for partial or total dental rehabilitation. For this type of treatment to have predictable prognoses, it is necessary to use imaging exams that provide sufficient information not only about the quality and quantity of bone, but also the

anatomical structures related to the recipient bed for the implant. A recommended imaging exam is the *Cone-Beam* computerized tomography. Therefore, this study investigated the location of the mental foramen in relation to the dental apices and the margins of the mandible using this type of exam. In order to avoid injury to the mental nerve during the surgery to place the implants, the location of the mental foramen must be known prior to any surgical procedure in the region.

Therefore, the purpose of this study was to evaluate the position of the mental foramen in relation to the apices of the teeth and its distance to the edges of the mandible using cone-beam computerized tomography.

## MATERIAL AND METHOD

This retrospective study was analyzed and approved by the Committee for Ethics in Research of the Graduate Center São Leopoldo Mandic, under number 643.636.

The study was conducted using a database and didactic file from the the College of Dentistry at the Federal University of Pará, in which tomographic exams of the mandibular region of both edentulous and toothed patients were evaluated.

The sample consisted of 100 tomographic exams of patients (34 men, 66 women) having a mean age of 44.7 years (ranging from 19-79 years), who underwent mandibular exams performed using a single I-Cat® tomography device (Imaging Sciences-Kavo, Hatfield, PA, EUA).

The evaluator of the images was a professional with a minimum of 3 years of experience working with *Cone-beam* computerized tomography, previously calibrated to determine the measurements that were made in this study.

The visualization of the anatomical references was accomplished using the Xoran (Icat, Imaging Science, Hatfield, PA, EUA) program in paraxial cuts, from a 17-inch LCD monitor with screen resolution of 1280×1024 pixels. The images were examined under proper lighting conditions at an observation distance of approximately 70 cm from the computer screen.

Each image chosen was evaluated repeatedly from both sides of the mandible, according to the sequence below:

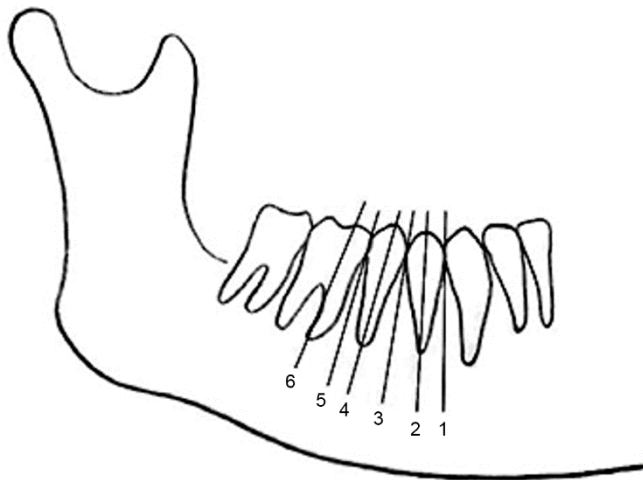
- a) **Horizontal position of the mental foramen.** In the panoramic reconstruction, the mental foramen was analyzed according to the classification system proposed by Chkoura, El Wady<sup>13</sup> in 6 categories: (1) before the long axis of the first lower premolar, (2) in line with the long axis of the first lower premolar, (3) between the long axes of the first and second lower premolars, (4) in line with the long axis of the second lower premolar, (5) between the long axes of the second lower premolar and the first lower molar, and (6) in line with the long axis of the mesial root of the first lower molar (Figure 1).
- b) **Measurements from the edges of the mental foramen to the lingual cortex, and to the base of the mandible.** In the coronal reconstructions, the cut was located where the hypodensity corresponding to the opening of the mental

foramen could be observed and, from this, the evaluated parameters were the measurements of the external edge to the lingual cortices and base of the mandible (Figure 2).

The data were initially analyzed descriptively. In order to detect significant differences in the data sets for the position of the mental foramen in relation to side and sex, the Kruskal-Wallis test was performed to estimate the influence of side, sex and location of the mental foramen on the distances to the lingual cortex and the lower edge of the mandible in coronal cone beam computerized tomographic images. Dunn's method was used to adjust for multiple comparisons. A value of  $p < 0.05$  was chosen as the level of significance; the tests were performed using the Bioestat 5.0 software.

**RESULT**

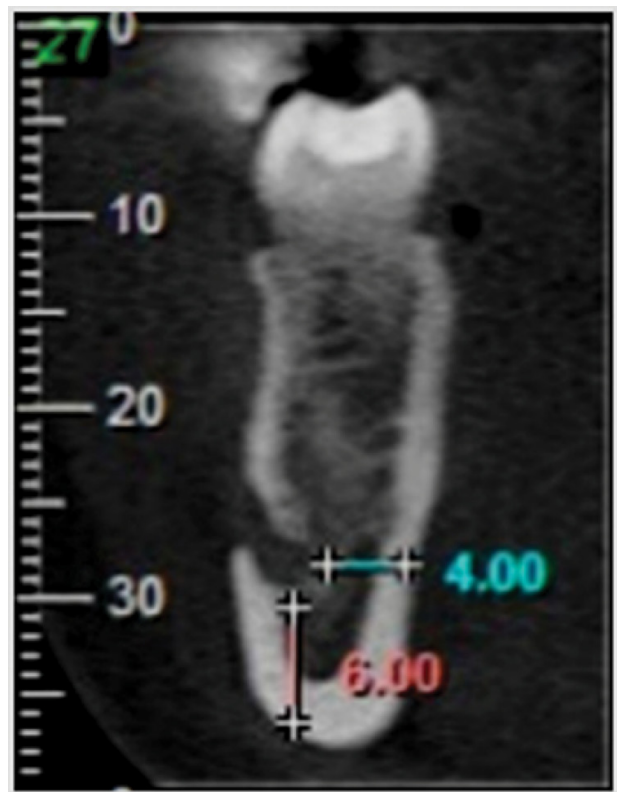
Regarding the location of the mental foramen, Table 1 shows that 15 (7%) were found in the apex of the first premolar, 71 (36%) were found between the apices of the first and second premolars, 84 (42%) were found in the apex of the second premolar, 28 (14%) were found between the apices of the second premolar and the first molar, and 2 (1%) were found in the mesial half of the first molar.



**Figure 1.** Schematic representation of the numeric expression of the position of the mental foramen relative to the tooth. Source: Chkoura, El Wady<sup>13</sup>, p. 72.

In the transversal reconstructions, the cut was located where the hypodensity corresponding to the opening of the mental foramen was observed, therefore, in Table 2, the cases studied were distributed among four age-groups: < 36 years (24 cases), 37 to 45 years (29 cases), 46 to 52 years (24 cases), and > 53 years (23 cases). The lingual edge was located, on average, 3.1 mm (varying from 1.0-8.0 mm) from the lingual cortex. Age had no statistically significant influence ( $p=0.3414$ ), and neither did sex ( $p=0.1038$ ), although an incidence of higher values had been verified in the men.

The lower edge of the mental foramen was located, on average, 7.25 mm (3.75-11.5 mm) above the lower edge of the mandible. Age had no statistically significant influence ( $p=0.5109$ ), but sex was significant ( $p=0.0001$ ). Male patients tended to have higher values than female patients (Table 3).



**Figure 2.** Tomographic illustration showing the measurements taken on the coronal plane (distances from the mental foramen to the lingual cortex and the base of the mandible). Source: Authors.

**Table 1.** Frequency of the position of the mental foramen in relation to the lower teeth between the sides

Location	Right	(%)	Left	(%)	Total	(%)
before the LA of the 1PML	0	0	0	0	0	0
in line with the LA of the 1PML	8	8	7	7	15	7
between the LA of the 1PML and 2PML	38	38	33	33	71	36
in line with the LA of the 2PML	42	42	42	42	84	42
between the LA of the 2PML and 1ML	12	12	16	16	28	14
in line with the LA of the MR of the 1ML	0	0	2	2	2	1
<b>Total</b>	<b>100</b>	<b>100</b>	<b>100</b>	<b>100</b>	<b>200</b>	<b>100</b>

Legend: LA: long axis; 1PML: first premolar, lower; 2PML: second premolar, lower; 1ML: first molar, lower; MR: mesial root. Source: Authors.

**Table 2.** Measurements of the mental foramen to the mandibular lingual cortex, basal cortex in relation to the age ranges of the patients

	< 36 yerars (n=48)	37 a 45 years (n=58)	46 a 52 years (n=48)	> 53 years (n=46)	P
	X <sup>2</sup> +SD	X <sup>2</sup> +SD	X <sup>2</sup> +SD	X <sup>2</sup> +SD	
MF-LC	2.80±0.91 mm	3.20±1.24 mm	3.25±1.40 mm	3.10±1.20 mm	0.3414
MF-BM	7.18±1.30 mm	7.13±1.22 mm	7.43±1.55 mm	7.55±1.79 mm	0.5109

Legend: X<sup>2</sup>: mean; SD: standard deviation; MF-LC: distance from the mental foramen to the lingual cortex; MF-BM: distance from the mental foramen to the base of the mandible. Source: Authors.

**Table 3.** Measurements from the mental foramen to the mandibular lingual cortex and to the basal cortex in relation to the sexes

	Female (n = 132)	Male (n = 68)	P
	X <sup>2</sup> + SD	X <sup>2</sup> + SD	
MF-LC	2.96±1.11	3.34±1.35	0.1038
MF-BM	7.00±1.27	7.91±1.62	<0.0001

Legend: X<sup>2</sup>: mean; SD: standard deviation; MF-LC: distance from the mental foramen to the lingual cortex; MF-BM: distance from the mental foramen to the base of the mandible. Source: Authors.

## DISCUSSION

The present tomographic study evaluated the location of the mental foramen and the distances between adjacent anatomical structures. In addition to the anatomical aspect, it is important to establish the absolute distances from the mental foramen within a clinical context in order to predict, more precisely, the procedures in implantology, maintaining the minimum safe distance of 2 mm between an implant and the edge of the mental foramen<sup>14</sup>. Recently, *Cone-Beam* computerized tomography technology has gained popularity in the dentistry community, particularly in the area of implantology, because of the image quality along with the possibility of taking precise measurements of anatomical and pathological findings.

The location of the mental foramen has influenced surgical planning in implantology. This suggests the need and importance of studies involving the anatomical characteristics of the mental foramen, which permits procedures to be performed more safely on the mandible<sup>15</sup>.

In the present study, the mental foramen was located mainly below the second pre-molar (42%). These results differ from those published recently having total values ranging from 50% to 78%<sup>13,16</sup>. However, in studies with cadavers without bone dissection, mistakes may occur in the interpretation of the location of the mental foramen due to the distal curvature of the roots of the premolars. In a recent study using 400 hemimandibles, 37.75% of the cases had the mental foramen located in the apex between the two premolars<sup>17</sup>. The findings here agree with Lima et al.<sup>18</sup>, who concluded that the results found confirm those found in other studies and justify the importance of the anatomical position of the mental foramen in order to block the nerve better and perform the surgical procedures safely.

In contrast, most of the studies have reported the common position of the mental foramen between the pre-molars, recently

published data also obtained using *Cone-Beam* computerized tomography<sup>11,19</sup> and panoramic radiographs<sup>17,20,21</sup>.

In the present study, the distance of the mental foramen to the lingual cortex of the mandible averaged 3.1 mm. However, Pyun et al.<sup>8</sup> conducted a study to investigate the deviation of the buccolingual pathway from the mandibular canal and the relationship with the location of the mental foramen. The obtained a mean value of 5.60 mm of the buccolingual measurements, using computerized tomography. Their results were larger than those of the present study as they measured from the center of the mandibular canal to the lingual cortex of the mandible. The results of this measurement may help the professional to avoid injury to the lower alveolar nerve during implant procedures, or even in apical surgery on the premolars.

In the present study, the mental foramen was located, on average, 7.31 mm above the edge of the mandible. Afkhami et al.<sup>22</sup> found the value to be 10.72 mm in panoramic radiographs, with no significant differences between the sides and the sexes. Kalender et al.<sup>19</sup> found a mean distance ranging from 11.8 to 12.8 mm, in 386 tomographic slices. The measurements of the present study differed significantly as to side, higher in male patients, which corroborates Chandra et al.<sup>23</sup> in studies using cadavers in which mean values ranging from 12 to 15.6 mm were found. This variation results from some studies using the center of the mental foramen instead of the lower edge as the starting point for the measurement<sup>1</sup>, or the voxel size used to obtain the image. Chen et al.<sup>24</sup>, using *Cone-Beam* computerized tomography in Americans and Taiwanese, revealed no statistically significant difference in the distance from the mental foramen to the lower edge of the mandible between Americans (9.84 mm) and Taiwanese (10.13 mm).

Implantology seeks surgical and prosthetic solutions to resolve rehabilitative treatment with osseointegrated implants safely. This treatment, which shows high indices of success, is achieved through a correct and thorough treatment plan. But, it is not unique: it must follow the demands of esthetically functional dentistry,

together with the technological development of new surgical techniques and the improvement of biomaterials, the better to rehabilitate patients with tooth loss.

Pre-surgical planning is of fundamental importance to the clinical success of the prosthetic implant. A widely accepted exam used in the planning is the *Cone-Beam* computerized tomography. In spite of this, the panoramic radiograph is broadly prescribed for initial evaluation in the planning for implants, as it provides a general visualization, giving broad coverage of the bones and

facial teeth. On the other hand, the magnification of the image and the lack of three-dimensional information are disadvantages of this imaging exam.

## CONCLUSION

The mental foramen is located more frequently in the level of the apices of the second pre-molars, with an average distance to the lingual cortex of 3.1 mm and to the base of the mandible of 7.25 mm.

## REFERENCES

1. Guo JL, Su L, Zhao JL, Yang L, Lv DL, Li YQ, et al. Location of mental foramen based on soft- and hard-tissue landmarks in a chinese population. *J Craniofac Surg*. 2009 Nov;20(6):2235-7. <http://dx.doi.org/10.1097/SCS.0b013e3181bf85f4>. PMID:19934679.
2. Haghani S, Rokouei M. Radiographic evaluation of the mental foramen in a selected Iranian population. *Indian J Dent Res*. 2009 Apr-June;20(2):150-2. <http://dx.doi.org/10.4103/0970-9290.52886>. PMID:19553713.
3. Ilayperuma I, Nanayakkara G, Palahepitiya N. Morphometric analysis of the mental foramen in adult Sri Lankan mandibles. *Int J Morphol*. 2009;27(4):1019-24. <http://dx.doi.org/10.4067/S0717-95022009000400010>.
4. Singh R, Srivastav AK. Study of position, shape, size and incidence of mental foramen and accessory mental foramen in Indian adult human skulls. *Int J Morphol*. 2010;28(4):1141-6. <http://dx.doi.org/10.4067/S0717-95022010000400025>.
5. Guedes OA, Rabelo LEG, Porto OCL, Alencar AHG, Estrela C. Avaliação radiográfica da posição e forma do forame mental em uma subpopulação brasileira. *Rev Odontol Bras Central*. 2011;20(53):160-5.
6. Sankar DK, Bhanu SP, Susan PJ. Morphometrical and morphological study of mental foramen in dry dentulous mandibles of South Andhra population of India. *Indian J Dent Res*. 2011 July-Aug;22(4):542-6. <http://dx.doi.org/10.4103/0970-9290.90290>. PMID:22124049.
7. Koppe T. Summary of: a comparative anthropometric study of the position of the mental foramen in three populations. *Br Dent J*. 2012 Feb;212(4):188-9. <http://dx.doi.org/10.1038/sj.bdj.2012.160>. PMID:22361552.
8. Pyun JH, Lim YJ, Kim MJ, Ahn SJ, Kim J. Position of the mental foramen on panoramic radiographs and its relation to the horizontal course of the mandibular canal: a computed tomographic analysis. *Clin Oral Implants Res*. 2013 Aug;24(8):890-5. <http://dx.doi.org/10.1111/j.1600-0501.2011.02400.x>. PMID:22220715.
9. Simonton JD, Azevedo B, Schindler WG, Hargreaves KM. Age- and gender-related differences in the position of the inferior alveolar nerve by using cone beam computed tomography. *J Endod*. 2009 July;35(7):944-9. <http://dx.doi.org/10.1016/j.joen.2009.04.032>. PMID:19567312.
10. Haktanir A, Ilgaz K, Turhan-Haktanir N. Evaluation of mental foramina in adult living crania with MDCT. *Surg Radiol Anat*. 2010 Apr;32(4):351-6. <http://dx.doi.org/10.1007/s00276-009-0572-1>. PMID:19820890.
11. von Arx T, Friedli M, Sendi P, Lozanoff S, Bornstein MM. Location and dimensions of the mental foramen: a radiographic analysis by using cone-beam computed tomography. *J Endod*. 2013 Dec;39(12):1522-8. <http://dx.doi.org/10.1016/j.joen.2013.07.033>. PMID:24238440.
12. Aminoshariae A, Su A, Kulild JC. Determination of the location of the mental foramen: a critical review. *J Endod*. 2014 Apr;40(4):471-5. <http://dx.doi.org/10.1016/j.joen.2013.12.009>. PMID:24666894.
13. Chkoura A, El Wady W. Position of the mental foramen in a Moroccan population: a radiographic study. *Imaging Sci Dent*. 2013 June;43(2):71-5. <http://dx.doi.org/10.5624/isd.2013.43.2.71>. PMID:23807929.
14. Greenstein G, Tarnow D. The mental foramen and nerve: clinical and anatomical factors related to dental implant placement: a literature review. *J Periodontol*. 2006 Dec;77(12):1933-43. <http://dx.doi.org/10.1902/jop.2006.060197>. PMID:17209776.
15. Balcioglu HA, Kilic C, Akyol M, Ulusoy AT. Horizontal migration of pre- and postnatal mental foramen: an anatomic study. *Int J Pediatr Otorhinolaryngol*. 2011 Nov;75(11):1436-41. <http://dx.doi.org/10.1016/j.ijporl.2011.08.010>. PMID:21917322.
16. Udhaya K, Saraladevi KV, Sridhar J. The morphometric analysis of the mental foramen in adult dry human mandibles: a study on the South Indian population. *J Clin Diagn Res*. 2013 Aug;7(8):1547-51. PMID:24086835.
17. Kçiku L, Sivic E, Weiglein A, Städtler P. Position of the mental foramen: an anatomical study. *Wien Med Wochenschr*. 2011 May;161(9-10):272-3. <http://dx.doi.org/10.1007/s10354-011-0898-2>. PMID:21638218.
18. Lima DSC, Figueredo AA, Gravina PR, Mendonça VRR, Castro MP, Chagas GL, et al. Caracterização anatômica do forame mental em uma amostra de mandíbulas humanas secas brasileiras. *Rev Bras Cir Craniomaxilofac*. 2010;13(4):230-5.
19. Kalender A, Orhan K, Aksoy U. Evaluation of the mental foramen and accessory mental foramen in Turkish patients using cone-beam computed tomography images reconstructed from a volumetric rendering program. *Clin Anat*. 2012 July;25(5):584-92. <http://dx.doi.org/10.1002/ca.21277>. PMID:21976294.
20. Pria CM, Masood F, Beckerley JM, Carson RE. Study of the inferior alveolar canal and mental foramen on digital panoramic images. *J Contemp Dent Pract*. 2011 July-Aug;12(4):265-71. <http://dx.doi.org/10.5005/jp-journals-10024-1045>. PMID:22186861.

21. Gada SK, Nagda SJ. Assessment of position and bilateral symmetry of occurrence of mental foramen in dentate asian population. *J Clin Diagn Res.* 2014 Feb;8(2):203-5. PMID:24701535.
22. Afkhami F, Haraji A, Boostani HR. Radiographic localization of the mental foramen and mandibular canal. *J Dent (Tehran).* 2013 Sep;10(5):436-42. PMID:24910651.
23. Chandra A, Singh A, Badni M, Jaiswal R, Agnihotri A. Determination of sex by radiographic analysis of mental foramen in North Indian population. *J Forensic Dent Sci.* 2013 Jan;5(1):52-5. <http://dx.doi.org/10.4103/0975-1475.114556>. PMID:23960416.
24. Chen JC, Lin LM, Geist JR, Chen JY, Chen CH, Chen YK. A retrospective comparison of the location and diameter of the inferior alveolar canal at the mental foramen and length of the anterior loop between American and Taiwanese cohorts using CBCT. *Surg Radiol Anat.* 2013 Jan;35(1):11-8. <http://dx.doi.org/10.1007/s00276-012-0986-z>. PMID:22669484.

## CONFLICT OF INTEREST

---

The authors declare no conflicts of interest.

## \*CORRESPONDING AUTHOR

---

Pedro Luiz de Carvalho, Rua Augusto Corrêa, 01, Guamá, 66075-110 Belém – PA, Brazil, e-mail: pedrolc@ufpa.br

Received: December 12, 2014

Accepted: March 11, 2015