

OVERLOAD STUDY ON ADJACENT DISC AFTER ARTHRODESIS IN THORACOLUMBAR FRACTURES

ESTUDO DE SOBRECARGA DO DISCO ADJACENTE APÓS ARTRODESE EM FRATURAS TORACOLUMBARES

ESTUDIO DE SOBRECARGA EN EL DISCO ADYACENTE DESPUÉS DE LA ARTRODESIS EN FRACTURAS TORACOLUMBARES

GUSTAVO SERRA REINAS¹, FERNANDO ZANI GARCIA¹, RÉGIS SILVEIRA TEIXEIRA¹, EMILIO CEZAR MAMEDE MURAD¹, RUY YOSHIKI OKAJI², ANDERSON BALESTREIRO FUKOSHIMA¹, ROBERTO RYUJI MIZOBUCHI¹, JOSÉ MARCONDES DA SILVEIRA JUNIOR¹

1. Faculdade de Medicina de Marília (FAMEMA), Hospital das Clínicas, Department of Orthopedics and Traumatology, Marília, SP, Brazil.
2. Faculdade de Medicina de Marília (FAMEMA), Hospital das Clínicas, Department of Neurosurgery, Marília, SP, Brazil.

ABSTRACT

Objective: To analyze the degeneration of the adjacent disc after arthrodesis due to thoracolumbar fractures. **Methods:** Eighty-three patients who underwent posterolateral arthrodesis in thoracolumbar levels had their x-rays analyzed for degeneration of adjacent discs to the arthrodesis. The disc spaces were classified by the UCLA scale. **Results:** Of the 83 patients evaluated, 66 were males (79%) and 18 females (21%), with a mean age of 35.5 years. The mean follow-up period was 40 months. As the fractures 75% were between T12 and L2 ($p < 0.001$), being of the A3 type in 65% of the cases ($p < 0.001$). The most common mechanism of injury, accounting for 50% of the cases ($p < 0.001$), was fall from height. Only 6% of the superior discs and 12% of the inferior ones showed some degree of degeneration. No patient underwent a new surgical approach. **Conclusion:** The incidence of degeneration on adjacent disc in patients after arthrodesis resulting from fractures ranged from 6% to 12% with an average follow-up of 40 months.

Keywords: Spinal fractures; Spinal fusion; Lumbosacral region; Thoracic vertebrae; Intervertebral disc degeneration; Radiography.

RESUMO

Objetivo: Analisar a degeneração do disco adjacente após artrodese devido a fraturas toracolombares. **Métodos:** Oitenta e três pacientes, submetidos à artrodese posterolateral em níveis toracolombares, tiveram suas radiografias analisadas em relação à degeneração dos discos adjacentes à artrodese. Os espaços dos discos foram classificados pela escala de UCLA. **Resultados:** Dos 83 pacientes avaliados, 66 eram do sexo masculino (79%) e 18 do sexo feminino (21%), com média de idade de 35,5 anos. O período de seguimento médio foi de 40 meses. Quanto às fraturas, 75% situavam-se entre T12 e L2 ($p < 0,001$), sendo do tipo A3 em 65% dos casos ($p < 0,001$). O mecanismo de trauma mais comum, responsável por 50% dos casos ($p < 0,001$), foi a queda de altura. Apenas 6% dos discos superiores e 12% dos discos inferiores mostraram algum grau de degeneração. Nenhum paciente foi submetido a nova abordagem cirúrgica. **Conclusão:** A incidência da degeneração do disco adjacente em pacientes após artrodese de coluna decorrente de fraturas variou de 6% a 12% com seguimento médio de 40 meses.

Descritores: Fraturas da coluna vertebral; Fusão vertebral; Região lombossacral; Vértebras torácicas; Degeneração do disco intervertebral; Radiografia.

RESUMEN

Objetivo: Analizar la degeneración del disco adyacente después de artrodese debido a fracturas toracolombares. **Métodos:** Ochenta tres pacientes que fueron sometidos a artrodese posterolateral en los niveles toracolombares tuvieron las radiografías analizadas para la degeneración de los discos adyacentes a la artrodese. Los espacios de los discos se clasifican según la escala de UCLA. **Resultados:** De los 83 pacientes evaluados, 66 eran hombres (79%) y 18 mujeres (21%), con edad promedio de 35,5 años. El período medio de seguimiento fue de 40 meses. Con respecto a las fracturas, el 75% se encontró entre T12 y L2 ($p < 0,001$), siendo del tipo A3 en el 65% de los casos ($p < 0,001$). El mecanismo más común de lesión, representando el 50% de los casos ($p < 0,001$), fue la caída de altura. Sólo el 6% de los discos superiores y 12% de los discos inferiores mostraron algún grado de degeneración. Ningún paciente fue sometido a un nuevo abordaje quirúrgico. **Conclusión:** La incidencia de la degeneración del disco adyacente en pacientes después de la artrodese debido a las fracturas varió de 6% a 12% con un seguimiento promedio de 40 meses.

Descriptorios: Fracturas de la columna vertebral; Fusión vertebral; Región lumbosacra; Vértebras torácicas; Degeneración del disco intervertebral; Radiografía.

INTRODUCTION

Thoracolumbar fractures are the most common fractures of the axial skeleton, corresponding to around 89% of all fractures of the vertebral spine, which mainly occur between T11 and L2.¹

In recent decades, the growing number of automobile and industrial accidents has directly increased the complexity of fractures, as

has the emergence of new instrumentation techniques, which have led to an increased prevalence of thoracolumbar arthrodesis. This results in complications, one of which is adjacent disc disease (ADD).

ADD is defined as an abnormal process that develops at the level above and/or below the segment where the arthrodesis was performed.² This process may take the form of disc degeneration (39%), instability,

Study conducted in the Department of Orthopedics and Traumatology of the Faculdade de Medicina de Marília (FAMEMA), Marília, SP, Brazil.

Correspondence: Department of Orthopedics and Traumatology of the Faculdade de Medicina de Marília- FAMEMA. Marília, SP, Brazil. Ambulatório Governador Mario Covas, Avenida Tiradentes n° 1310, Bairro Fragata C, Marília, SP, Brazil. 17519-030. reinasg82@yahoo.com.br

facet hypertrophy, disc hernia (28%), stenosis of the spinal canal (33%), vertebral fracture and scoliosis (17%). Its occurrence depends on the type of fusion, due to the increased mobility of the free segments of the fusion, intra-disc metabolic changes, increased intradiscal pressure, or biomechanical changes caused by changes to the spinal column, such as loss of lumbar lordosis.²

With the appearance of ADD, careful considerations were made on the use of fusion implants and new implants, such as dynamic stabilization and the use of artificial discs.⁵ However, no conclusions have been drawn on this subject as yet i.e. whether ADD is a radiological finding, or a consequence that indicates poor clinical results.⁵ Some authors still divide the definition of this disease into adjacent level degeneration, in which there are altered imaging exams with asymptomatic patients, or symptomatic patients with compatible imaging exams.⁶

This article performs a retrospective radiographic analysis of 83 patients with thoracolumbar fracture submitted to posterolateral arthrodesis. It evaluates the behavior of the discs adjacent to the fusions performed, with an average follow-up of 40 months.

METHODS

A retrospective study analyzed by the Institutional Review Board of the Faculdade de Medicina de Marília (CAAE: 41787115.4.0000.5413), opinion number 965.154. All the patients agreed with and signed the Informed Consent Form.

A retrospective analysis was conducted of eighty-three records of patients seen at Hospital das Clínicas de Marília (FAMEMA), in the period 2000 to 2012, who presented thoracolumbar fractures, treated surgically and with outpatient follow-up. All the patients had undergone posterolateral arthrodesis, with fixation by pedicle screws of 2 to 5 levels.

The radiographic images of the thoracolumbar spine (T4 to S1) on the day of the trauma, and at least 24 months after surgery, were analyzed and compared, by different doctors. The fractures were given an AO score,⁷ and the discs adjacent to the arthrodesis (upper and lower), by the Scale of the University of California at Los Angeles (UCLA), which was used to measure the radiographic disc degeneration,⁸ (Table 1) type of trauma and some type of associated lesion.

Inclusion criteria: minimum age of 18 years, last level of arthrodesis of the lumbar spine, minimum of 24 months since surgery.

Exclusion criteria: age below 18 years, any motor deficit, pure thoracic arthrodesis, less than 24 months since surgery, signs of degeneration in the initial radiograph, infection, and patients who have undergone removal of material for any reason.

Table 1. Scale of the University of California at Los Angeles (UCLA) to measure intervertebral disc degeneration in radiographs.

Grade	Decrease of disc space	Osteophytes	Sclerosis of the vertebral plateau
I	-	-	-
II	+	-	-
III	+ -	+	-
IV	+ -	+ -	+

RESULTS

Of the 83 patients evaluated, 65 were male (78.3%) and 18 female (21.7%); ages ranged from 18 to 51 years, with an average age of 35.6 years (CI 95%: 32.9 – 38.1). A minimum follow-up period of 24 months and a maximum of 115 months was observed, with an average of 40 months (CI 95%: 36.3 – 46.6). All the patients underwent posterolateral arthrodesis with instrumentation using pedicle screws via the posterior route, and decompression.

The fracture levels were T11 – 9 (10.8%), T12 – 20 (24.1%), L1 – 21 (25.3%), L2 – 23 (27.7%), L3 – 9 (10.8%), L4 – 1 (1.2%) (p < 0.001). (Table 2) Graded as A2 – 4 (4.8%), A3 – 55 (66.3%), B1 – 4 (4.8%), B2 – 13 (15.7%), C – 7 (8.4%) (p < 0.001). (Table 3)

Associated lesions, such as head injury, chest trauma, abdominal trauma and/or other fractures, were found in 31 (37.3%) of the patients (p = 0.02).

Types of trauma: automobile accident 31 (37.3%); being run over 2 (2.4%); falling from a height 42 (50.6%); direct trauma 8 (9.6%) (p < 0.001).

Findings of the disc above: grade 1 – 70 (84.3%), grade 2 – 8 (9.6%), grade 3 – 3 (3.6%), grade 4 – 2 (2.4%); disc below: grade 1 – 56 (67.5%), grade 2 – 17 (20.5%), grade 3 – 9 (10.8%), grade 4 – 1 (1.2%). (Table 4) (Figure 1)

Table 2. Level of the fracture (p < 0.001).

		Frequency	Percentage
Valid	T11	9	10.8
	T12	20	24.1
	L1	21	25.3
	L2	23	27.7
	L3	9	10.8
	L4	1	1.2
	Total	83	100.0

Table 3. Grading of the fractures (p < 0.001).

		Frequency	Percentage
Valid	A2	4	4.8
	A3	55	66.3
	B1	4	4.8
	B2	13	15.7
	C	7	8.4
		Total	83

Table 4. Disc degeneration (UCLA).

		Disc above		Disc below	
		Frequency	Percentage	Frequency	Percentage
Valid	1	70	84.3	56	67.5
	2	8	9.6	17	20.5
	3	3	3.6	9	10.8
	4	2	2.4	1	1.2
		Total	83	100.0	83

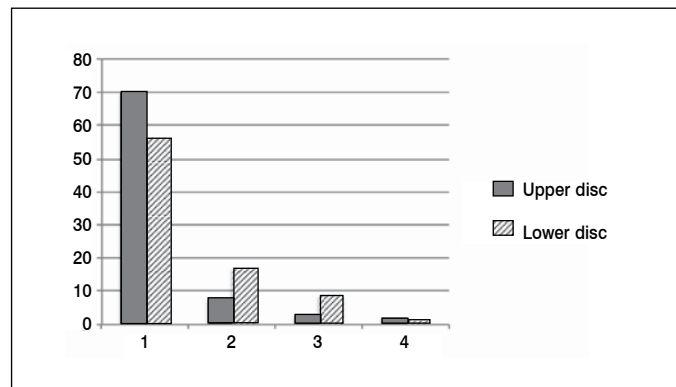


Figure 1. Disc degeneration, number of patients/grade (UCLA).

DISCUSSION

Fractures of the thoracolumbar spine are the most common fractures of the axial skeleton, corresponding to around 89% of all fractures of the vertebral spine, which mainly occur between T11 and L2. Two thirds of thoracolumbar fractures occur at the thoracolumbar transition between T11 and L2 (50% of fractures of the thoracic spine at level T12 and 60% of spinal fractures at level L1). The prevalence of fractures in this region is related to the reduction of stability between the thoracic segment (more rigid and stable) and the lumbar (greater flexibility and greater range of movement). These fractures are the result of falling from a height in 47% of patients, automobile accidents in 44.1% and direct trauma 8.8%.^{1,4} Disc lesion associated with fracture (at the time of the trauma) should be considered, as this influences the stability and genesis of acute and chronic pain, and can lead to

sagittal imbalance and worsening of the quality of life (pain);¹ however, this is rarely found in the discs adjacent to the levels of arthrodesis in the immediate postoperative period.

Adjacent disc disease (ADD) after fusion of the lumbar vertebral spine is responsible for a significant percentage of revision surgeries of the spine. Although the development of degeneration of the adjacent segment can be considered a normal part of the degenerative process that occurs with aging, this phenomenon appears to be, at least in part, influenced by changes that emerge as a result of the lumbar arthrodesis.⁹⁻¹²

Other studies have been conducted on the subject, which take into consideration the height of the disc and the signs of instability. Wide variation in prevalence is seen; from 5% to 43%, but the need for revision surgeries ranged from 2% to 15%,¹³⁻¹⁵ in which, in the majority of cases, only decompression of the canal was performed, without increasing the level of the arthrodesis.

Biomechanical studies defend the increased prevalence of adjacent degenerative disease after arthrodesis.^{9,10,16} Their authors affirm that a possible etiology of degeneration of the adjacent segment after arthrodesis is due to increased stress, or to a hypermobility. Lee and Langrana show that there is increased tension in the adjacent joints of L3-L4 and L4-L5 after lumbosacral arthrodesis.¹⁶ A single level of lumbar arthrodesis was studied by Quinnell and Stockdale, who observed that the adjacent disc above was not affected, unlike the disc below, which suffered changes in its characteristics.¹⁰ Tests using in vitro models were conducted by Axelsson et al.,¹⁷ who found hypermobility of the adjacent segment, thereby proving, biomechanically, that lumbar fusions produce negative consequences on the adjacent discs.

According to Ghiselli et al.,⁸ the incidence of ADD ranged from 0 to 6.1%, with an average of 3.9% per year, with follow-up of five to ten years. Of these patients, 83.5% and 63.9% were free of disease, respectively, and it was concluded that 16.5% and 36.1%, respectively, would require a new surgical procedure due to the adjacent disc disease.

Park et al.,² point out the causes that most favor the development of ADD, described in Chart 1. The main factor for non-occurrence of DDA is preservation of the proximal facet, as affirmed by Wiltse et al.¹⁸

By comparing the increased load on the joints, in the different forms of fusion, it is concluded that in posterior arthrodesis this is great; in anterior, intermediary and circumferential fusion, there is little effect.⁸ ADD has been greater in posterior fusions when compared with circumferential arthrodesis and with anterior fusion.^{15,19,20}

In our study, the vast majority of patients were male (79%) as these are more exposed to traumas. As in the literature, the most frequent level of the fracture was T12 – L2 in 75% of cases, and the most common grade was A3, in 65%.

Chart 1. Main risk factors of ADD after instrumentation.

Posterior arthrodesis
Lesion of the joint facet above the arthrodesis
Sagittal alignment
Size of the fusion
Post-menopause
Osteoporosis
Female
Age over 55 years
Pre-existing degeneration at the adjacent levels

It should be emphasized that in our study, only patients operated on and without neurological deficits were considered. The findings in the literature also corroborate our findings, in terms of the types of trauma found in this research: falling from a height (50%), automobile accident (37%), direct trauma (10%), being run over (3%).

It is observed that the majority of patients involved in traumas are young, and that the follow-up time of this study was too short to allow for evaluation of early disc degeneration. A longer follow-up time is therefore necessary, as only 6% (above) and 12% (below) of the adjacent discs show relevant radiographic signs of degeneration. Also, although magnetic resonance is the gold standard exam for evaluation of the disc, this exam was not performed due to questions of cost.

CONCLUSION

Adjacent disc degeneration (ADD) should continue to be the object of studies, with longer follow-up times, as its incidence is still low in patients with arthrodesis following fractures without previous pathologies and low age group. Within this context, we also emphasize that preservation of the joint facet at the adjacent level above, and sagittal alignment, continue to be the main forms of prevention of ADD.

ACKNOWLEDGEMENTS

We thank the nurse Aparecida Bezerra de Lima, and Ms. Maria Isabel Brichi da Silva for the years of dedication to the Orthopedics and traumatology team of the Faculdade de Medicina de Marília – FAMEMA – Marília (SP), Brazil.

All the authors declare that there are no potential conflicts of interest regarding this article.

CONTRIBUTIONS OF THE AUTHORS: All the authors made individual and significant contributions to the development of the manuscript. GSR, JMSJ, ECMM and RYO performed the surgeries and followed up the patients. GSR, FZG and RST were the main contributors to writing the manuscript and the data collection. JMSJ, ECMM, RYO, ABF and RRM revised the manuscript and contributed to the intellectual concept of the study.

REFERENCES

- Defino HLA. Lesões Traumáticas da coluna vertebral. São Paulo: Bevilacqua; 2006. p. 145-6.
- Park P, Garton HJ, Gala VC, Hoff JT, McGillicuddy JE. Adjacent segment disease after lumbar or lumbosacral fusion: review of the literature. *Spine (Phila Pa 1976)*. 2004;29(17):1938-44.
- Aota Y, Kumano K, Hirabayashi S. Postfusion instability at the adjacent segments after rigid pedicle screw fixation for degenerative lumbar spinal disorders. *J Spinal Disord*. 1995;8(6):464-73.
- Defino HLA, Fuentes AER, Remondi PH, Vallim EC. Fixação monoesegmentar das fraturas da coluna toracolombar. *Rev Bras Ortop*. 1998;33(2):119-24.
- Whitecloud TS 3rd, Davis JM, Olive PM. Operative treatment of the degenerated segment adjacent to a lumbar fusion. *Spine (Phila Pa 1976)*. 1994;19(5):531-6.
- Yang JY, Lee JK, Song HS. The impact of adjacent segment degeneration on the clinical outcome after lumbar spinal fusion. *Spine (Phila Pa 1976)*. 2008;33(5):503-7.
- Hilibrand AS, Robbins M. Adjacent segment degeneration and adjacent segment disease: the consequences of spinal fusion? *Spine J*. 2004;4(Suppl 6):190S-194S.
- Ghiselli G, Wang JC, Bhatia NN, Hsu WK, Dawson EG. Adjacent segment degeneration in the lumbar spine. *J Bone Joint Surg Am*. 2004;86-A(7):1497-503.
- Yang SW, Langrana NA, Lee CK. Biomechanics of lumbosacral spinal fusion in combined compression-torsion loads. *Spine (Phila Pa 1976)*. 1986;11(9):937-41.
- Quinnell RC, Stockdale HR. Some experimental observations of the influence of a single lumbar floating fusion on the remaining lumbar spine. *Spine (Phila Pa 1976)*. 1981;6(3):263-7.
- Boden SD, Davis DO, Dina TS, Patronas NJ, Wiesel SW. Abnormal magnetic-resonance scans of the lumbar spine in asymptomatic subjects. A prospective investigation. *J Bone Joint Surg Am*. 1990;72(3):403-8.
- Torgerson WR, Dotter WE. Comparative roentgenographic study of the asymptomatic and symptomatic lumbar spine. *J Bone Joint Surg Am*. 1976;58(6):850-3.
- Frymoyer JW, Hanley E, Howe J, Kuhlmann D, Matteri R. Disc excision and spine fusion in the management of lumbar disc disease. A minimum ten-year followup. *Spine (Phila Pa 1976)*. 1978;3(1):1-6.
- Lehmann TR, Spratt KF, Tozzi JE, Weinstein JN, Reinartz SJ, el-Khoury GY, et al. Long-term follow-up of lower lumbar fusion patients. *Spine (Phila Pa 1976)*. 1987;12(2):97-104.
- Penta M, Sandhu A, Fraser RD. Magnetic resonance imaging assessment of disc degeneration 10 years after anterior lumbar interbody fusion. *Spine (Phila Pa 1976)*. 1995;20(6):743-7.
- Lee CK, Langrana NA. Lumbosacral spinal fusion. A biomechanical study. *Spine (Phila Pa 1976)*. 1984;9(6):574-81.
- Axelsson P, Johnsson R, Strömqvist B. The spondylolytic vertebra and its adjacent segment. Mobility measured before and after posterolateral fusion. *Spine (Phila Pa 1976)*. 1997;22(4):414-7.
- Wiltse LL, Radecki SE, Biel HM, DiMartino PP, Oas RA, Farjalla G, et al. Comparative study of the incidence and severity of degenerative change in the transition zones after instrumented versus noninstrumented fusions of the lumbar spine. *J Spinal Disord*. 1999;12(1):27-33.
- Guigui P, Lambert P, Lassale B, Deburge A. [Long-term outcome at adjacent levels of lumbar arthrodesis]. *Rev Chir Orthop Reparatrice Appar Mot*. 1997;83(8):685-96.
- Eck JC, Humphreys SC, Hodges SD. Adjacent-segment degeneration after lumbar fusion: a review of clinical, biomechanical, and radiologic studies. *Am J Orthop (Belle Mead NJ)*. 1999;28(6):336-40.