



ORIGINAL ARTICLE

**Evaluation of the ability of an experimental model to induce bacterial rhinosinusitis in rabbits** ☆, ☆



Eduardo Landini Lutaif Dolci<sup>a,\*</sup>, Carlos Augusto Correia de Campos<sup>a,b</sup>,  
Leonardo da Silva<sup>b</sup>, Ricardo Landini Lutaif Dolci<sup>a,b</sup>, José Eduardo Lutaif Dolci<sup>a,b</sup>

<sup>a</sup> Faculdade de Ciências Médicas, Santa Casa de São Paulo (FCMSCSP), São Paulo, SP, Brazil

<sup>b</sup> Department of Otorhinolaryngology, Santa Casa de São Paulo, São Paulo, SP, Brazil

Received 14 March 2013; accepted 22 July 2014

Available online 16 September 2014

**KEYWORDS**

Sinusitis;  
Animal models;  
Rabbits

**Abstract**

*Introduction:* For decades, animals have been used in sinonasal experimental models, and the practice has increased substantially in the last few years. This study aimed to assess the pathogenesis of infectious process and medication efficiency to treat rhinosinusitis.

*Objective:* To evaluate the efficiency of the proposed experimental model to induce an acute bacterial sinonasal infectious process through histological analysis and sinus secretion cultures.

*Methods:* This was an experimental study with 22 New Zealand rabbits, divided into: group A (six rabbits), group B (seven rabbits), group C (seven rabbits), and group D (control group with two rabbits). Rhinosinusitis was induced by the insertion of a synthetic sponge into the right nasal cavity of 20 animals (study groups), followed by the instillation of bacterial strains (50% *Staphylococcus* sp. and 50% *Streptococcus* sp.). The groups were euthanized within 10 days (group A), 17 days (group B), and 30 days (groups C and D).

*Results:* All the rabbits of the study group developed acute bacterial rhinosinusitis, which was diagnosed through macroscopic evaluation, histological analysis, and sinus secretion culture.

*Conclusion:* The proposed model is technically simple to perform, it is similar to the rhinogenic model in human beings, and it is highly efficient to reproduce an acute bacterial sinus infection.

© 2014 Associação Brasileira de Otorrinolaringologia e Cirurgia Cérvico-Facial. Published by Elsevier Editora Ltda. All rights reserved.

☆ Please cite this article as: Dolci EL, de Campos CA, da Silva L, Dolci RL, Dolci JE. Evaluation of the ability of an experimental model to induce bacterial rhinosinusitis in rabbits. Braz J Otorhinolaryngol. 2014;80:480–9.

☆ Institution: Irmandade da Santa Casa de São Paulo, São Paulo, SP, Brazil.

\* Corresponding author.

E-mail: [eduardodolci@hotmail.com](mailto:eduardodolci@hotmail.com) (E.L.L. Dolci).

**PALAVRAS CHAVE**

Sinusite;  
Modelos animais;  
Coelhos

**Avaliação da capacidade de um modelo experimental para indução de rinossinusite bacteriana em coelhos****Resumo**

**Introdução:** A realização de modelos experimentais nasossinusais em animais vem sendo realizada há décadas, com substancial aumento nos últimos anos. Tem como objetivos identificar as alterações fisiopatológicas ocasionadas pelo processo infeccioso sinusal e avaliar a eficácia de medicamentos no tratamento da rinossinusite.

**Objetivo:** Avaliar a eficácia do modelo experimental proposto para a indução de um processo infeccioso nasossinusal agudo bacteriano, utilizando parâmetros histopatológicos e cultura da secreção sinusal.

**Método:** Estudo experimental com 22 coelhos da raça Nova Zelândia, divididos em: grupo A (6 coelhos), grupo B (7 coelhos), grupo C (7 coelhos) e grupo D (controle com 2 coelhos). Induzido quadro de rinossinusite através da inserção de esponja sintética nas fossas nasais direita dos 20 coelhos (grupos de estudo), seguido por instilação de toxoide bacteriano (50% estreptocócico, 50% estafilocócico). Os grupos foram sacrificados com 10 dias (grupo A), 17 dias (grupo B) e 30 dias (grupos C e D).

**Resultados:** Todos os coelhos do grupo de estudo apresentaram quadro de rinossinusite aguda bacteriana, através da identificação macroscópica, análise histológica e cultura das secreções.

**Conclusão:** O modelo proposto apresenta simplicidade técnica para sua execução, similaridade ao quadro rinogênico que acomete os humanos e é altamente eficaz na produção de um quadro infeccioso bacteriano agudo sinusal.

© 2014 Associação Brasileira de Otorrinolaringologia e Cirurgia Cérvico-Facial. Publicado por Elsevier Editora Ltda. Todos os direitos reservados.

**Introduction**

Rhinosinusitis is currently one of the most prevalent diseases; it is the fifth most common disease that requires antibiotics.<sup>1</sup> Approximately 25 million people are diagnosed with sinusitis each year in the United States, making it one of the main diseases that require medical attention with otorhinolaryngologists and general practitioners. The direct and indirect costs associated with rhinosinusitis are high, and include diagnostic methods, therapy, procedures, medications, and decreased productivity.<sup>2</sup>

The prevalence of acute rhinosinusitis (ARS) and chronic rhinosinusitis (CRS) in the general population is quite high, but it is difficult to accurately estimate this prevalence, primarily because many of the episodes are self-limited and mildly symptomatic, and do not compel the patient to seek health care. Rhinosinusitis is responsible for 9% of all antibiotics prescribed to the pediatric population and 21% of the total prescribed for the adult population in the United States, costing approximately US\$ 5.8 billion; US\$ 150 million are spent on antibiotics alone.<sup>3,4</sup>

Several attempts to model the disease in animals have been made; studies with rabbits are the most frequent. These animals have sinonasal anatomy and physiology very similar to humans. They are well suited for studies involving surgical procedures, but they experience a high mortality when in prolonged stress. Other animals used for research are the Wistar and Sprague–Dawley rats, guinea pigs, and sheep.<sup>5–7</sup>

Experimental models of rhinosinusitis discussed in the literature aim to induce inflammation in the paranasal sinuses

similar to that experienced by humans. Experimental models have been used to study the physiopathogenesis of inflammation and to evaluate treatment outcomes.<sup>8–10</sup>

Studies have utilized obliteration of nasal passage maneuvers, sinus drainage ostium obstruction, and instillation of inflammatory process mediators and even materials that act as a culture medium in the nasal passages.<sup>11–14</sup>

The literature search retrieved no detailed experimental model of acute bacterial rhinosinusitis that included a thorough histological analysis of both maxillary sinuses (induced side and contralateral side) and a microbiological analyses of both maxillary sinuses in the presence of a bacterial infection.

No studies that had analyzed the nasal packing when it was used as the method for bacterial rhinosinusitis induction were retrieved. Such an analysis could correlate the microbiological findings of the nasal cavity with those of the maxillary sinus. The few studies that have assessed this correlation did not find significant results.<sup>15</sup>

It was also observed that many studies aimed to produce an infectious picture or to evaluate the therapeutic efficacy of drugs. Therefore, few studies have evaluated the histological and microbiological alterations in the period following the diagnosis of acute sinus infection process without the use of any medication, after removal of the nasal packing, i.e., they did not analyze the recovery period.

Therefore, the literature lacks a simple to perform, easily reproducible, and highly effective experimental model to induce acute rhinosinusitis in animals that has been used to assess microbiological and histopathological parameters on both maxillary sinuses and to analyze nasal packing to study

**Table 1** Description of the groups of animals, number of rabbits and euthanization days and removal of nasal packing.

Group	Rabbits (n)	Euthanization (day)	Nasal packing removal (day)
A	6	10	10
B	7	17	10
C	7	30	10
D	2	30	

the association between the bacteria found in the sinuses and in the nasal passages.

There are still some doubts in the literature regarding the physiopathology and treatment of acute rhinosinusitis, such as the expected period after diagnosis to start the antibiotic therapy, the evaluation of patients with recurrence right after the end of treatment, and why some patients develop recurrent and/or chronic conditions after an acute rhinosinusitis episode.

## Methods

The study was approved by the Ethics Committee on Animal Experimentation (EAEC) and was performed in a private institute, under approval number 008-12. The animals were kept in individual cages, appropriate for the breed and weight. They were offered free food and water throughout the period they were confined. All animals were kept under standard conditions for a period of eight days prior to study initiation. All surgical and experimental procedures were performed in the same institute, in accordance with the ethical principles in animal experimentation, postulated by the Brazilian code for animal experimentation (Código Brasileiro de Experimentação em Animais [COBEA]). Preparations and histological analyses were performed in a private laboratory. Microbiological studies were conducted in the microbiology laboratory of a tertiary hospital.

A total of 22 New Zealand white adult rabbits, of both sexes, weighing between 2500 and 3000 g were used at the beginning of the experiment. The rabbits were divided into four groups: group A (six rabbits), group B (seven rabbits), group C (seven rabbits), and group D as control (two rabbits). The rabbits in group A were euthanized on the day of the nasal packing removal, 10 days after the experiment induction. The rabbits in group B were euthanized 17 days after induction, and the rabbits in group C were euthanized 30 days after induction. The two rabbits from group D were kept in a separate environment, in a different room from the animals in the study groups for 30 days, and euthanized together with the group C rabbits (Table 1). The nasal packing and bacterial toxoid were not introduced into these two animals.

An experiment was performed in order to obtain a sinonasal inflammatory process through the nasal cavity of the animals, simulating an acute infectious rhinosinusitis. The rabbits were submitted to general anesthesia and a sterile Merocel® nasal pack measuring 0.3 cm × 0.5 cm × 2.5 cm was introduced into the right nasal cavity using sterile bayonet forceps, followed by instillation of 1 mL of streptococcal and staphylococcal toxoid (Toxoidepot®) in the ipsilateral

nostril using a sterile syringe and insulin needle. The toxoid instillation was performed in the nasal cavity after placement of the nasal packing, in order to standardize the toxoid amount in all animals. The packing was removed on the 10th day after the start of the experiment from all animals in the three study groups.

Opening and exposure of the anterior wall of the maxillary sinuses were performed bilaterally in each animal, initially on the left side to prevent contamination of the contralateral side to that of the induction experiment, using swabs to collect secretion from them (Cuturet®). The materials were kept at room temperature without exposure to sunlight and sent to the laboratory 24–36 h after collection.

All secretion samples were prepared on slides and stained by the Gram technique for bacterioscopic analysis. Thus, the slides were stained with methyl violet, fixed with Lugol's solution, discolored with ethyl alcohol, and again stained with safranin. Slide reading was performed by light microscopy with oil immersion objective (1000×).

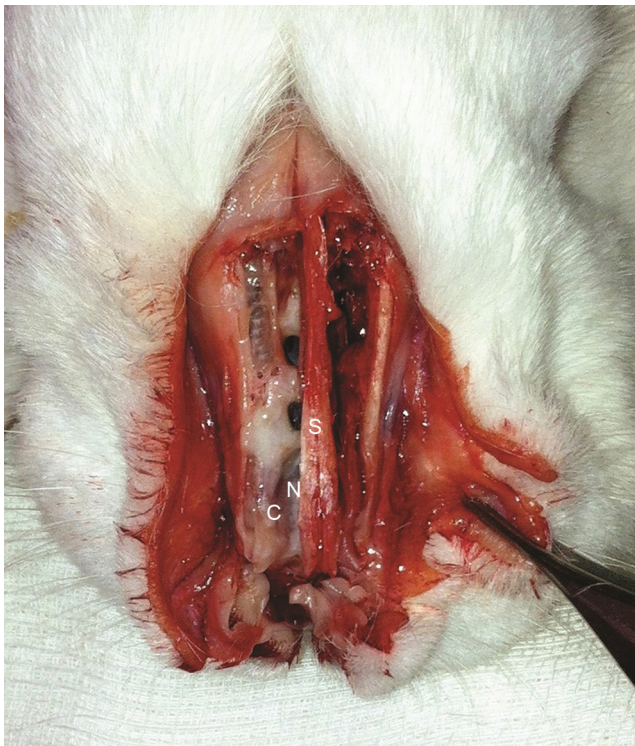After the bacterioscopic analysis, the materials were seeded in blood agar, chocolate agar, and Sabouraud agar. Plates of blood agar and chocolate agar were incubated at 35 ± 2 °C. Daily readings of the plates were performed up to 48 h for blood agar and chocolate agar media, and up to 15 days for Sabouraud agar.

Immediately after euthanization, the structures lining the face of the rabbits were dissected, and the anterior wall of the maxillary sinus was opened, as well as the outer wall of the nasal cavities. Then, the inner mucosa of the maxillary sinus was removed (Fig. 1).

Mucosal samples were obtained from the rabbits after removal of the inner mucosa of the maxillary sinuses, and immediately fixed in 10% buffered formalin; the samples remained in this solution for a minimum of 24 h for adequate fixation. They remained 24–48 h under the authors' responsibility, and were then sent to the pathology laboratory. Subsequently, the cleavage of samples was performed and the histological processing itself was started (dehydration in successive baths with increasing concentrations of ethyl alcohol, diaphanization in xylene; samples were then paraffin-embedded at 60 °C). Then, the microtomy was performed, with each histological slice having a maximum thickness of 4 μm. Finally, the slides were stained with hematoxylin-eosin (HE) and mounted on coverslips for microscopic examination by the pathologist.

All slides were analyzed by a single pathologist, who was unaware of the group to which the specimen belonged. A semi-quantitative assessment of the alterations found during the analyses was performed.

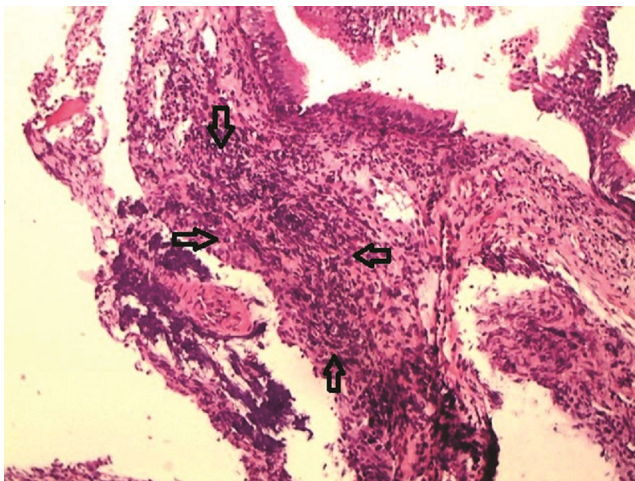
Subsequently, the samples were classified using the adopted criteria for inflammation according to Marks<sup>16,17</sup>: 0, no inflammation; 1, mild inflammation (sparse inflammatory cells without epithelial lesions); 2, moderate inflammation (diffuse inflammatory infiltrate in the lamina propria, without formation of inflammatory aggregates with focal lesions of epithelial cells characterized by disorganization and disruption of epithelial cells); 3, intense inflammation (dense diffuse inflammatory infiltrate with formation of aggregates of inflammatory cells, with diffuse lesion of epithelial cells characterized by disorganization and disruption of epithelial cells); and 4, severe inflammation with ulceration. The fibrous-connective proliferation



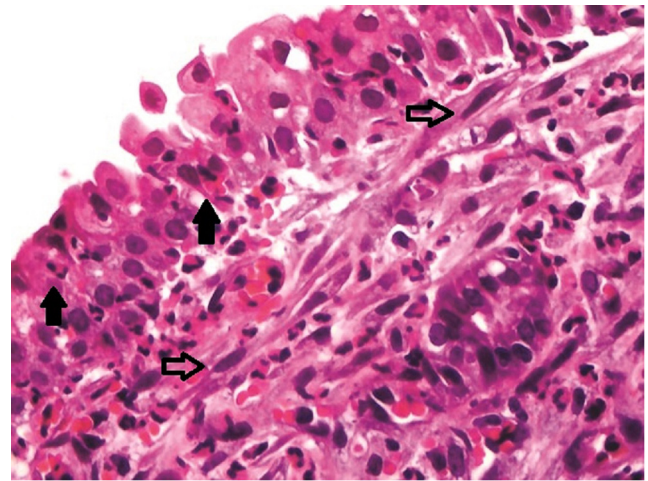
**Figure 1** Outer wall of the open sinonasal cavities, exposing the maxillary sinuses and nasal cavity. Evident infectious process on the right, characterized by mucosal edema and purulent discharge. Anatomical sites represented by the maxillary sinus (M), nasal septum (S), inferior turbinate (T), and nasal cavity (N).

was evaluated according to its intensity, classified as absent, present, or severe (Figs. 2 and 3).

The nasal packing removed from the rabbits' nasal passages was analyzed for microorganism culture through

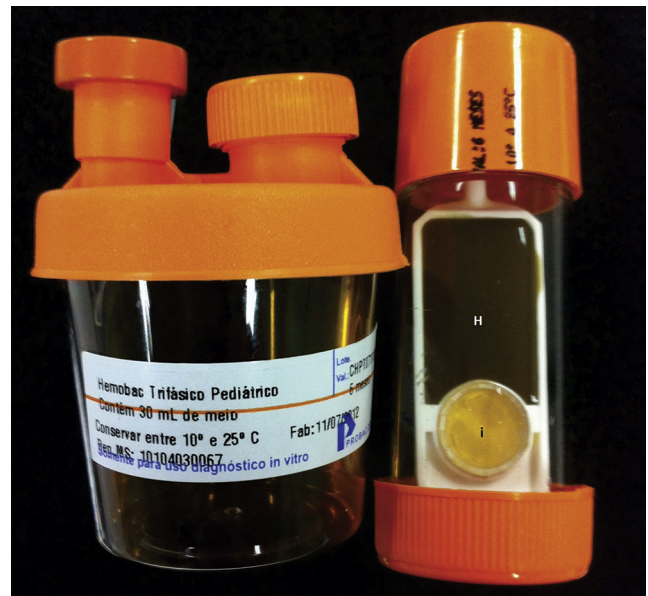

**Figure 2** Sinus mucosa on the right side of the study group euthanized after 10 days, with moderate inflammation characterized by diffuse inflammatory infiltrate in the lamina propria, without formation of inflammatory aggregates (grade 2), delimited by arrows – optical microscope, HE staining, 100× magnification.



**Figure 3** Sinus mucosa on the right side of the study group euthanized after 17 days, with severe inflammation (grade 3), demonstrating the epithelium permeated by neutrophils (filled arrows) and fibroblasts (hollow arrows) in the superficial corium. Optical microscope, HE staining, 200× magnification.

Hemobac® in the same microbiology laboratory. The Hemobac Triphasic® System is a product used in cultures of blood and blood components, stem cells, body fluids, and parenteral nutrition; in the present study, the Pediatric Hemobac Triphasic® system was used. The system consists of two elements: a plastic container containing 30 mL of broth supplemented with yeast extract and sodium polyanethol sulfonate (SPS) and a dipslide (Fig. 4). The latter has two faces: a broad face, consisting of chocolate agar and CO<sub>2</sub> indicator to detect bacterial and/or fungal growth, and a divided face, consisting of Sabouraud agar and MacConkey agar.



**Figure 4** Container with supplemented broth to the left and dipslide to the right. Dipslide side consisting of chocolate agar (H) and CO<sub>2</sub> meter (i).



**Figure 5** System after the end of the incubation period. Nasal packing (T) inside the container of supplemented broth, CO<sub>2</sub> indicator (i) with a strong pink color due to the presence of micro-organisms and chocolate agar medium (H) with the presence of bacterial colonies.

The nasal packing was placed inside the container with the broth, soon after its removal from the nasal cavity of the rabbit, followed by occlusion of the container. For each nasal packing removed, one Pediatric Hemovac Triphasic® system was used. This was gently shaken for homogenization of the sample with the broth. The material was kept for 72 h at room temperature with no sunlight exposure or manipulation of the material. The system was repositioned at the original position so that all the liquid medium would return to the bottom of the container. All materials were again incubated at  $35 \pm 2^\circ\text{C}$  and observed twice daily for colony identification and/or change in the CO<sub>2</sub> indicator (Fig. 5).

The incubation period was seven days and then the separation of the two containers and the identification of colonies present on solid medium were performed. The chocolate agar and MacConkey agar media were used for bacterial identification. The materials were kept incubated for another eight days, totaling 15 days at room temperature, for the investigation of fungi on Sabouraud agar.

Statistical analysis was performed to assess the degree of mucosal inflammation, connective-fibrous proliferation and the presence or absence of bacteria according to the

day of animals' euthanization. All groups of bacteria found in the sample on both sides were described using absolute and relative frequencies. The degrees of mucosal inflammation and connective-fibrous proliferation were compared between the days of euthanization using the Kruskal–Wallis test,<sup>18</sup> followed by Dunn's nonparametric multiple comparisons test<sup>19</sup> to compare days two by two, when necessary. For the presence or absence of bacteria, the association was verified using the likelihood ratio test.<sup>18</sup>

The concordance between the swab and culture performed in the buffer was described according to the days of euthanization and the existence of an association of the concordance with the days of euthanization was verified using the likelihood ratio test. The tests were performed with a significance level of 5% ( $p < 0.05$ ).

## Results

A total of 22 rabbits were used in the study, with 20 rabbits in the study group and two rabbits in the control group. None of the animals died during the study period. After nasal packing removal, on the 10th day of the experiment induction, all rabbits had unilateral purulent rhinorrhea. Thus, all the rabbits euthanized in group A had purulent rhinorrhea at that moment. Few rabbits from group B showed evident rhinorrhea before euthanization. No rabbit from group C had evident rhinorrhea in the nasal cavity at the time of euthanization. However, many rabbits from group B and some rabbits from group C had purulent secretion in the maxillary sinus after euthanization of the animals and exposure of these anatomical structures.

## Secretion culture and bacterioscopic analysis

Secretions from the right and left maxillary sinuses of all rabbits were collected and analyzed. The bacteria found during the analyses were classified into the following groups: non-fermenting Gram-negative bacilli (*Acinetobacter baumannii*, *Acinetobacter lwoffii*, *Achromobacter* sp., and *Pseudomonas aeruginosa*), Gram-negative enterobacteria bacilli (*Escherichia coli*), Gram-positive bacilli (*Bacillus* sp.), and Gram-positive cocci (*Micrococcus* sp., coagulase-negative *Staphylococcus*, and *Staphylococcus aureus*). The results are described in Table 1.

Table 2 shows that the most common group of bacteria found on the side submitted to rhinosinusitis induction (right side) was the group of Gram-positive bacilli (44.4%), while on the contralateral side it was the group of non-fermenting Gram-negative bacilli (40.9%). A higher incidence of Gram-negative bacteria was identified in the total number of assessed rabbits. These were identified in 15 animals (75%); and Gram-positive bacteria were found in only nine animals (45%). The microorganism most often found in the cultures of the right maxillary sinus of the rabbits was *Bacillus* sp., identified in 11 rabbits. Seven rabbits had two microorganisms in culture tests from the right side.

Swab positivity was evaluated bilaterally in the collected samples. The results are shown in Table 3.

Table 3 demonstrates that there is no statistically significant association in swab positivity on the right side ( $p = 0.468$ ). Swab positivity on the left side was statistically

**Table 2** Description of groups of bacteria found in the samples according to the side of the 20 rabbits in the study groups.

Variable	Frequency	%
<i>Bacterial group right side</i>		
Negative	2	7.4
Non-fermenting Gram-negative bacilli	5	18.5
Enterobacter, Gram-negative bacilli	4	14.8
Gram-positive Bacilli	12	44.4
Gram-positive Coccus	4	14.8
Total	27	100
<i>Bacterial group left side</i>		
Negative	6	27.3
Non-fermenting Gram-negative bacilli	9	40.9
Enterobacter, Gram-negative bacilli	1	4.5
Gram-positive Bacilli	5	22.7
Gram-positive Coccus	1	4.5
Total	22	100

Absolute and relative frequencies.

associated with the day of euthanization and that positivity decreases with each passing day ( $p=0.039$ ).

The cultures of the maxillary sinuses of the two rabbits used as controls showed no bacterial growth.

### Histological analysis of sinus mucosa

Histological analysis of the right and left maxillary sinus mucosa showed some degree of inflammation in most samples. The results of the semi-quantitative histological evaluation of mucosal samples are shown in Table 4.

There was a statistically significant difference between groups regarding the degree of inflammation in the induced side ( $p=0.009$ ), with no statistically significant difference in connective-fibrous proliferation between the groups ( $p=0.420$ ; Table 4). On the left side there was no statistically significant difference in either parameter. Regarding the degree of mucosal inflammation in the left maxillary sinus, only grades 0 and 1 were observed.

Table 5 presents the comparison of the inflammation grade on the right side in relation to the three study groups,

showing that the degree of inflammation in group A (day 10) was statistically higher than in group C (day 30),  $p=0.002$ .

Histological analysis of the right and left sinuses of the two rabbits in the control group showed grade 0 inflammation and absent fibrous-connective proliferation.

### Nasal packing analysis

The association between the bacteria found in the swab from the right side and the bacteria identified in the Meroce<sup>®</sup> nasal packing was analyzed.

No statistically significant association was observed between concordance of bacteria found in the nasal swab and nasal packing according to the groups ( $p=0.171$ ; Table 6).

The Meroce<sup>®</sup> nasal packing used as control through the Hemobac<sup>®</sup> system showed no bacterial growth.

### Discussion

Several experimental models have been utilized to induce rhinosinusitis and are described in the literature.<sup>20</sup> Rabbits are the most commonly used animals in this type of study, followed by rats and sheep. It was decided to use rabbits, since they show more anatomical and physiological similarities with the human sinonasal cavities, as reported by Casteleyn et al.<sup>21</sup>

These experimental models have assessed several aspects of sinus infection. Anatomical, physiological, and pathological alterations of the paranasal sinuses have been evaluated,<sup>13,16,22,23</sup> and comparisons of the effectiveness of different treatments for rhinosinusitis have been conducted.<sup>8,9,11,24-26</sup> The study and identification of the presence of bacterial biofilms have also been performed.<sup>27</sup>

Different methods have been used to induce bacterial sinus infection in rabbits. Earlier studies advocated definitive maxillary ostia obstruction through surgical procedures or use of glue.<sup>6,22-24</sup> Although this model of rhinosinusitis has been shown to be extremely effective in the formation of purulent rhinosinusitis, inflammation was generally limited to the maxillary sinus, as a sinus abscess. Furthermore, the manipulation used to generate the ostium obstruction was performed through the sinus cavity into the nasal cavity.

**Table 3** Description of swab positivity according to the day of euthanization of the groups and statistical test results.

Variable	Groups						Total		p
	A		B		C		n	%	
	n	%	n	%	n	%			
<i>Right swab</i>									
Negative	0	0.0	1	14.3	1	14.3	2	10.0	0.468
Positive	6	100.0	6	85.7	6	85.7	18	90.0	
<i>Left swab</i>									
Negative	0	0.0	2	28.6	4	57.1	6	30.0	0.039
Positive	6	100.0	5	71.4	3	42.9	14	70.0	
Total	6	100	7	100	7	100	20	100	

Likelihood ratio test results.

**Table 4** Description of the degree of inflammation and fibrous-connective proliferation according to the day of euthanization of the groups and statistical test results.

Variable	Groups						Total		p
	A		B		C				
	n	%	n	%	n	%	n	%	
<i>Right fibrous-connective proliferation</i>									
Absent	3	50.0	4	57.1	2	28.6	9	45.0	0.420
Present	3	50.0	3	42.9	4	57.1	10	50.0	
Very present	0	0.0	0	0.0	1	14.3	1	5.0	
<i>Left fibrous-connective proliferation</i>									
Absent	5	83.3	5	71.4	6	85.7	16	80.0	0.786
Present	1	16.7	2	28.6	1	14.3	4	20.0	
<i>Degree of inflammation right side</i>									
0	0	0.0	0	0.0	0	0.0	0	0.0	0.009
1	0	0.0	1	14.3	2	28.6	3	15.0	
2	1	16.7	3	42.9	5	71.4	9	45.0	
3	2	33.3	3	42.9	0	0.0	5	25.0	
4	3	50.0	0	0.0	0	0.0	3	15.0	
<i>Degree of inflammation left side</i>									
0	1	16.7	4	57.1	4	57.1	9	45.0	0.267
1	5	83.3	3	42.9	3	42.9	11	55.0	
<i>Total</i>	6	100	7	100	7	100	20	100	

Kruskal–Wallis test results.

**Table 5** Result of multiple comparisons of the degree of inflammation in the induced side between the groups.

Comparison	Z-value	p
A – B	1.82	0.069
A – C	3.05	0.002
B – C	1.28	0.200

In the present study, rhinosinusitis induction was performed by inserting a synthetic sponge in the right nasal cavity of the animals, which was removed after 10 days in all groups. This method is technically simple, causes little damage to the nasal mucosa, and the packing is easy to remove in the rabbits that continued in the study. Furthermore, this method does not cause permanent alterations in

the nasal mucosa of the animals and is reversible, allowing for the assessment of histological recovery after acute rhinosinusitis induction.

Some authors performed the inoculation of the infectious agent inside the maxillary sinus<sup>7,22,25,26,28,29</sup> and others, inside the nasal cavity.<sup>15,20,30</sup> The authors chose not to use the first technique, as it is more invasive and causes iatrogenic alterations in the sinus mucosa. Some studies have demonstrated that the simple obliteration of nasal passages would be enough for the development of a bacterial infection condition.<sup>7,13,31</sup>

The inoculation of streptococcal and staphylococcal toxoid was used in conjunction with the synthetic sponge packing in the same nasal cavity. It was decided to use the toxoid inoculation aiming at standardizing the pathogenic agents present in the samples with the agents that cause

**Table 6** Description of the agreement of the nasal pack bacteria and microbiology in the induced side according to the groups and statistical test results.

Variable	Groups						Total		p
	A		B		C				
	n	%	n	%	n	%	n	%	
<i>Hemobac<sup>®</sup> concordance with right swab</i>									
Different bacteria	4	66.7	7	100.0	6	85.7	17	85.0	0.171
Same bacteria	2	33.3	0	0.0	1	14.3	3	15.0	
<i>Total</i>	6	100	7	100	7	100	20	100	

Likelihood ratio test results.

sinus infection in humans, as well as to accelerate the rhinosinusitis induction time. This finding was demonstrated by Kara et al.,<sup>15</sup> who used computed tomography to disclose the presence of infection in the maxillary sinus of rabbits from day six after induction of rhinosinusitis with toxoid inoculation and on the eighth day without toxoid inoculation.

After the sponge removal on the 10th day, all animals had unilateral purulent rhinorrhea in the nasal cavity where they were inserted. This result is consistent with those of other studies<sup>15,26,32</sup> applying similar methods through the rhinogenic route, a model originally proposed by Marks,<sup>20</sup> using only the insertion of toxoid and/or buffer through the nasal cavity. Marks<sup>20</sup> had 83% success with this method; Liang et al.<sup>31</sup> obtained 91.7% success in the induction of acute infection.

The presence of purulent rhinorrhea in the nasal cavity of the study animals was chosen as the main diagnostic criterion of acute rhinosinusitis. Microbiological and histological evaluations of the animals from group A allowed for the assessment of the infectious process at the time of diagnosis, i.e., 10 days after the start of the experiment. After that, the acute rhinosinusitis recovery period without any treatment was observed. Therefore, some rabbits from group B still had secretions in the nasal cavity and the maxillary sinuses after being euthanized, while some rabbits from group C still had secretion in the maxillary sinuses at the time of euthanization.

In the microbiological and histological analyses of the rabbits in group A, all animals had positive swab of the maxillary sinus for microorganisms and signs of mucosal inflammation bilaterally. The rabbits in groups B and C showed some negative results of the maxillary sinus swabs, while the histological evaluation demonstrated that all animals still had some degree of inflammation in the right maxillary sinus. Considering these results, it can be noted that, during the evolution of an acute bacterial rhinosinusitis picture, inflammatory findings in the sinus mucosa persist longer than the presence of the microorganisms causing the infectious process.

Most of the studies that used strains of *Streptococcus pneumoniae* to aid in the induction of rhinosinusitis demonstrated its replacement by other opportunistic pathogenic agents. Westrin et al.<sup>33</sup> used this bacterium for the induction and observed its replacement after an average of five days. Cheng et al.<sup>26</sup> did not isolate this agent in any rabbit 10 days after the start of induction. In the present study, *S. pneumoniae* was not identified in any of the assessed rabbits.

Most models described in the literature did not evaluate the contralateral sinus to that of the experiment induction. Few studies reported culture of the material from the contralateral sinus, and when performed, the studies had a small sample size. Liang et al.<sup>31</sup> reported little bacterial growth in nasal cavities without the presence of rhinosinusitis. In the present study, bacteria were found in the contralateral sinus of 14 rabbits (70% of total). The authors believe that the progression of the inflammatory condition in the nasal mucosa also favors the growth of opportunistic bacteria on the contralateral side of the induced experiment side.

Histological analysis of the sinus mucosa in rabbits submitted to experiments for rhinosinusitis induction was performed in most studies, with several goals. Its

assessment was used as a diagnostic criterion for the presence of sinus infection,<sup>15,20,29,31</sup> in the assessment of infection severity,<sup>16,34</sup> in the comparison of the effectiveness of different treatments for rhinosinusitis,<sup>12,14,25</sup> and in the physiopathological changes after the induction of an acute sinonasal infection.<sup>13,24,30</sup>

The semiquantitative analysis was used in the present study in order to assess inflammation intensity and compare the three study groups (euthanization after 10, 17, and 30 days). A statistically significant difference was observed in the degree of inflammation between rabbits of the group euthanized at 10 days and the group euthanized at 30 days. Thus, it was demonstrated that the inflammatory process will regress after removal of the nasal packing. But even after 30 days of the start of the experiment (20 days after packing removal), many rabbits still showed inflammation in the sinus mucosa. This finding indicates that acute rhinosinusitis causes more prolonged histological changes than the macroscopic findings and that they persist for a few weeks until complete regression.

Few studies have performed the histological analysis of the maxillary sinus mucosa in the contralateral side of the affected sinus. Jyonouchi et al.<sup>23</sup> observed an increase in glandular and goblet cells in the contralateral sinuses, as well as mild stromal thickening. However, they used permanent obliteration of the sinus ostium with cyanoacrylate as the induction method. Gentian et al.<sup>30</sup> observed no alterations in the contralateral nasal cavity. Liang et al.<sup>31</sup> evaluated only some control sides and found no histological alterations.

The authors believe that this is a quite significant finding and that a progression of inflammation as a response in the entire respiratory epithelium to a local infectious focus can occur, and it can trigger a greater response even in areas without direct continuity. This also occurs in asthma patients with allergic rhinitis and/or rhinosinusitis, whose pulmonary condition deteriorates as a result of the worsening of the nasal condition, an association known as unified airway. There are some other hypotheses for its occurrence, such as nasobronchial neural reflex, contamination of the lower airways with inflammatory cells and mediators through posterior nasal secretion, or absorption of inflammatory cells of the nasal epithelium by the systemic circulation and consequently, into the bronchial mucosa.<sup>35,36</sup> Future studies are needed to assess the association of this response in the presence of rhinosinusitis.

The assessment of the connective-fibrous proliferation showed no statistically significant difference between the groups. Therefore, this parameter could not be used as a marker of infectious process chronicity. The number of rabbits may not have been sufficient to reproduce statistical alteration in this assessed parameter.

In recent decades, most of the experimental studies in rabbits used the insertion of a nasal packing for rhinosinusitis induction. The material used in the studies was Merocel® synthetic sponge,<sup>15,20,26,31</sup> gelatinous sponge,<sup>32</sup> or polyvinyl sponge.<sup>7,29</sup> The objective was to establish an inflammatory and infectious process through obstruction of the sinus ostium. Another hypothesis suggested to initiate this process was the inflammatory reaction of the nasal mucosa to a foreign body, causing a disruption of the ostiomeatal physiology.<sup>7</sup>



Nonetheless, the literature search retrieved no studies that performed the analysis of nasal packing for microorganism culture, or with some other objective.

Kara et al.<sup>15</sup> cultured the right maxillary sinus (infection induction side) and right nasal cavity of all rabbits, through swab collection. This was performed in only one region of the nasal cavity. They expected the dissemination of bacteria from the nasal cavity into the sinus, but did not observe that finding.

The assessment of nasal packing was performed so the microorganisms present in the nasal passages, where the induction of the infection was performed, could be accurately analyzed. This method was used to correlate the bacteria present inside the nasal cavity with the bacteria found in the maxillary sinus. No significant association was observed between the bacteria present in these two different anatomic sites. This association was not observed even in the first group of euthanized rabbits, in whom the removal of the nasal packing was performed on the same day, 10 days after the start of the study.

## Conclusion

The experimental model, conducted and assessed by histopathological parameters of the sinus mucosa, through culture of sinus secretion and nasal packing and by assessing the presence of nasal secretion, was shown to be capable of inducing acute bacterial rhinosinusitis in 100% of the animals used in the study.

## Conflicts of interest

The authors declare no conflicts of interest.

## References

- Ramanathan Jr M, Lee WK, Lane AP. Increased expression of acidic mammalian chitinase in chronic rhinosinusitis with nasal polyps. *Am J Rhinol.* 2006;20:330–5.
- Hamilos DL, Leung DY, Wood R, Cunningham L, Bean DK, Yasruel Z, et al. Evidence for distinct cytokine expression in allergic versus nonallergic chronic sinusitis. *J Allergy Clin Immunol.* 1995;96:537–44.
- Bhattacharyya N. The economic burden and symptom manifestations of chronic rhinosinusitis. *Am J Rhinol.* 2003;17:27–32.
- Bhattacharyya N, Grebner J, Martinson NG. Recurrent acute rhinosinusitis: epidemiology and health care cost burden. *Otolaryngol Head Neck Surg.* 2012;146:307–12.
- Illum L. Nasal delivery. The use of animal models to predict performance in man. *J Drug Target.* 1996;3:427–42.
- Grullón LMB, Suárez MAB. Modelo experimental para el desarrollo de sinusitis maxilar en conejos: an animal experimental model for maxillary sinusitis. *An Otorrinolaringol Mex.* 1996;41:183–5.
- Costa HO, Ruschi e Luchi GE, Augusto AG, Castro M, de Souza FC. Estudo comparativo entre diversas técnicas de confecção de modelo experimental de sinusite inflamatória em coelhos. *Braz J Otorhinolaryngol.* 2007;73:627–31.
- Min YG, Kim YK, Choi YS, Shin JS, Juhn SK. Mucociliary activity and histopathology of sinus mucosa in experimental maxillary sinusitis: a comparison of systematic administration of antibiotic and antibiotic delivery by polylactic acid polymer. *Laryngoscope.* 1995;105:835–42.
- Cable BB, Wassmuth Z, Mann EA, Hommer D, Connely G, Klem C, et al. The effect of corticosteroids in the treatment of experimental sinusitis. *Am J Rhinol.* 2000;14:217–22.
- Çetin CB, Kara CO, Çolakoglu N, Sengul M, Pinar H. Experimental sinusitis model in nasally catheterized rabbits. *Rhinology.* 2002;40:154–8.
- Bende M, Fukami M, Arfors KE, Mark J, Stierna P, Intaglietta M. Effect of oxymetazoline nose drops on acute sinusitis in the rabbit. *Ann Otol Rhinol Laryngol.* 1996;105:222–5.
- Uslu C, Karasen RM, Sahin F, Taysi S, Akcay F. Effect of aqueous extracts of *Ecballium elaterium* rich, in the rabbit model of rhinosinusitis. *Int J Pediatr Otorhinolaryngol.* 2006;70:515–8.
- Kim YM, Lee CH, Won TB, Kim SW, Kim JW, Rhee CS, et al. Functional recovery of rabbit maxillary sinus mucosa in two different experimental injury models. *Laryngoscope.* 2008;118:541–5.
- Bleier BS, Kofonow JM, Hashmi N, Chennupati SK, Cohen NA. Antibiotic eluting chitosan glycerophosphate implant in the setting of acute bacterial sinusitis: a rabbit model. *Am J Rhinol.* 2010;24:129–32.
- Kara CO, Çetin CB, Demirkan N, Sengul M, Topuz B, Pinar HS, et al. Experimental sinusitis in a rhinogenic model. *Laryngoscope.* 2004;114:273–8.
- Marks SC. Acute rhinogenic sinusitis in the rabbit model: histologic analysis. *Laryngoscope.* 1998;108:320–5.
- Perez AC, Cunha Junior A da S, Fialho SL, Silva LM, Dorgam JV, Murashima A de A, et al. Assessing the maxillary sinus mucosa of the rabbits in the presence of biodegradable implants. *Braz J Otorhinolaryngol.* 2012;78:40–6.
- Kirkwood BR, Sterne JAC. *Essential medical statistics.* 2nd ed. Massachusetts, USA: Blackwell Science; 2006.
- Neter J, Kutner MH, Nachtsheim CJ, Wasserman W. *Applied linear statistical models.* 4th ed. Illinois: Richard W. Irwing; 1996.
- Marks SC. Acute rhinogenic sinusitis in the rabbit model. *Laryngoscope.* 1997:107.
- Casteleyn C, Cornillie P, Hermens A, Van Loo D, Van Hoorebeke L, Van den Broeck W, et al. Topography of the rabbit paranasal sinuses as a prerequisite to model human sinusitis. *Rhinology.* 2010;48:300–4.
- Johansson P, Kumlien J, Carlsoo B, Drettner B, Nord CE. Experimental acute sinusitis in rabbits. A bacteriological and histological study. *Acta Otolaryngol.* 1998;105:357–66.
- Jyonouchi H, Sun S, Kennedy CA, Roche AK, Kajander KC, Miller Jr JR, et al. Localized sinus inflammation in a rabbit sinusitis model induced by *Bacteroides fragilis* is accompanied by rigorous immune responses. *Otolaryngol Head Neck Surg.* 1999;120:869–75.
- Hassab MH, Kennedy DW. Effects of long-term induced ostial obstruction in the rabbit maxillary sinus. *Am J Rhinol.* 2001;15:55–9.
- Ozturk M, Selimoğlu E, Polat MF, Erman Z. Serum and mucosal nitric oxide levels and efficacy of sodium nitroprusid in experimentally induced acute sinusitis. *Yonsei Med J.* 2003;30(44):424–8.
- Cheng Y, Wei H, Li Z, Xue F, Jiang M, Chen W, et al. Effects of intranasal corticosteroids in the treatment of experimental acute bacterial maxillary sinusitis in rabbits. *ORL J Otorhinolaryngol Relat Spec.* 2009;71:57–65.
- Perloff JR, Palmer JN. Evidence of bacterial biofilms in a rabbit model of sinusitis. *Am J Rhinol.* 2005;19:1–6.
- Maeyama T. A study of experimental sinusitis in rabbits. *Auris Nasus Larynx.* 1981;8:87–98.
- Campos CAC. Eficácia de solução tópica nasal de extrato de Luffa Operculata para tratamento de rinossinusite bacteriana em coelhos [dissertation]. São Paulo: Faculdade de Ciências Médicas da Santa Casa de São Paulo; 2010.

30. Genc S, Ozcan M, Titiz A, Unal A. Development of maxillary accessory ostium following sinusitis in rabbits. *Rhinology*. 2008;46:121–4.
31. Liang KL, Jiang RS, Wang J, Shiao JY, Su MC, Hasin CH, et al. Developing a rabbit model of rhinogenic chronic rhinosinusitis. *Laryngoscope*. 2008;118:1076–81.
32. Ozcan KM, Ozcan J, Selcuk A, Akdogan O, Gurgen SG, Deren T, et al. Comparison of histopathological and CT findings in experimental rabbit sinusitis. *Indian J Otolaryngol Head Neck Surg*. 2011;63:56–9.
33. Westrin KM, Norlander T, Stierna P, Carlsoo B, Nord CE. Experimental maxillary sinusitis induced by *Bacteroides fragilis*. A bacteriological and histological study in rabbits. *Acta Otolaryngol*. 1992;112:107–14.
34. Shin SH, Heo WW. Effects of unilateral naris closure on the nasal and maxillary sinus mucosa in rabbit. *Auris Nasus Larynx*. 2005;32:139–43.
35. Bousquet J, Khaltaev N, Cruz AA, Denburg J, Fokkens WJ, Togias A, et al. Allergic rhinitis and its impact on asthma (ARIA) 2008 update. *Allergy*. 2008;63:8–160.
36. Bousquet J, Vignola AM, Demoly P. Links between rhinitis and asthma. *Allergy*. 2003;58:691–706.