







Prevalence of Oral Normal Variance in Healthy Elderly Patients: A Descriptive Study on Oral Pseudo-Lesions

Fatma Yasmin Mahdani¹ Adiastuti Endah Parmadiati¹ Diah Savitri Ernawati¹
Vint Erawati Suryanijaya² Candrika Ramya Inastu² Desiana Radithia¹
Nurina Febriyanti Ayuningtyas¹ Meircurius Dwi Condro Surboyo¹ Aulya Setyo Pratiwi¹
Riyan Iman Marsetyo¹

¹ Department of Oral Medicine, Faculty of Dental Medicine, Universitas Airlangga, Surabaya, Indonesia.

² Bachelor of Dental Science, Faculty of Dental Medicine, Universitas Airlangga, Surabaya, Indonesia.

Address for correspondence: Adiastuti Endah Parmadiati, DDS, MDS, Department of Oral Medicine, Faculty of Dental Medicine, Universitas Airlangga, Jl. Mayjen Prof. Dr. Moestopo No.47 Surabaya 60132, Indonesia (e-mail: adiastutie@gmail.com).

Int Arch Otorhinolaryngol 2022;26(4):e671–e675.

Abstract

Introduction The aging process in the elderly can change the condition of the oral cavity, regarding both clinical appearance and function. The oral mucosa becomes more susceptible to mechanical damage and irritant agents. Any changes in the oral mucosa, including normal variance, should be examined. This is especially true for the elderly, to improve oral health and prevent any abnormalities.

Objective To describe the prevalence of oral normal variance in healthy elderly patients.

Methods An observational descriptive study with a cross-sectional design with total sampling conducted from March to April 2020.

Results Among the 117 elderly patients who participated in this study, 58 were described as healthy without any comorbidities. From those subjects, there were 117 cases of normal variance in the oral mucosa. The three most prevalent issues were fissured tongue (93.1%), coated tongue (58.62%), and crenated tongue (27.59%).

Conclusion Fissured tongue is a normal variance of the oral mucosa that is commonly found in healthy elderly patients.

Keywords

- ▶ elderly
- ▶ fissured tongue
- ▶ human & health
- ▶ oral mucosa
- ▶ pseudo lesion

Introduction

The increase in the number of elderly in Indonesia is the result of increased life expectancy.¹ Health problems in the elderly can be influenced by psychological, social, and economic aspects. Additionally, the aging process causes several changes to the morphology and physiology of organs and organ systems, including those of the oral cavity.² Several studies have shown that prevalence of normal variance of

oral mucosa in the elderly is higher than in adults and children.^{3–5} In India, the prevalence of changes in oral soft tissue conditions in the elderly is 89.4% higher than in other age groups.³ In Kuwait, studies show that the highest prevalence of oral soft tissue lesions occur in elderly patients.⁴ Another research conducted in Surabaya, Indonesia, showed that the normal variances of the mucosa with higher prevalence in the elderly are coated tongue, fissured tongue and lingual varices.⁵ These conditions can affect daily activities,

received
May 15, 2021
accepted after revision
October 17, 2021
published online
April 20, 2022

DOI <https://doi.org/10.1055/s-0042-1742328>.
ISSN 1809-9777.

© 2022, Fundação Otorrinolaringologia. All rights reserved.
This is an open access article published by Thieme under the terms of the Creative Commons Attribution-NonDerivative-NonCommercial-License, permitting copying and reproduction so long as the original work is given appropriate credit. Contents may not be used for commercial purposes, or adapted, remixed, transformed or built upon. (<https://creativecommons.org/licenses/by-nc-nd/4.0/>)
Thieme Revinter Publicações Ltda., Rua do Matoso 170, Rio de Janeiro, RJ, CEP 20270-135, Brazil

including mastication, swallowing, and talking, as well as cause symptoms such as xerostomia, halitosis, or dysesthesia.⁶

It is important to distinguish between normal aging processes and pathological conditions in the elderly population. Lack of knowledge about the changes in the oral cavity due to aging can lead to excessive or unnecessary oral management, so normal variance and pathological abnormalities of the oral cavity in the elderly need to be properly evaluated.⁷ Until now, there is little data available in the literature that can describe the prevalence of oral normal variance in healthy elderly people, which means optimum service standards for the elderly do not yet exist. Oral health services must be regulated and improved for both the development of preventive efforts and better treatment of healthy elderly. Achieving such improvements require the involvement of other oral health professionals, such as dentists, as well as other health workers so that the realistic goal of ensuring the quality of life of the elderly can be achieved, and so we can reduce the cost of dental treatments for elderly patients. This research was conducted so that, in the future, it can be applied as a guide to improve the oral health of elderly patients, and provide optimum service standards for elderly patients.

Materials and Methods

Study Design

This descriptive observational study with cross-sectional design was conducted in elderly patients from March to April 2020.

Study Participants

All the participants of this study are elderly. Informed written consent forms were obtained from the patients who were willing to participate in the study. The inclusion criteria of the sample in this study were age over 60 years old, cooperative, and healthy elderly. In this study, we defined healthy elderly patients as those without degenerative diseases (hypertension, diabetes mellitus, coronary heart disease, or chronic kidney disease) that could be assessed for medical history and anamnesis.

Intraoral Examination

A screening examination, which included an intraoral clinical exam, was performed by an oral medicine specialist and students from the oral medicine specialist program. Intraoral examination was done by using an intraoral mirror, and oral mucosa was screened for all soft tissue lesions. Normal variance of the mucosa or pseudo lesions considered as a form of soft tissue variation from its normal shape were diagnosed based on clinical examination. The normal variance, or pseudo lesions, of the mucosa were determined based on the della Vella et al. study of 2019, with modifications⁸ (► **Table 1**).

Data Presentation

The data obtained will be presented descriptively through percentages, and by using a prevalence rate analyzed using

Table 1 The pseudo lesions and their location

Location	Normal variance of the mucosa
Tongue	Fissured tongue
	Crenated tongue
	White and black hairy tongue
	Coated tongue
	Sublingual varices
	Lingual fimbriae
	Papilla circumvallate prominent
	Papilla foliate prominent
	Hyperpigmented papilla of tongue
Oral mucosa	Depapilated tongue, including geographic tongue
	Linea alba buccalis
	Fordyce granules
	White sponge nevus
Gingiva	Steno's duct orifice hyperplasia
	Racial pigmentation on gingiva
Bone	Torus palatinus
	Torus mandibularis

the Microsoft Excel 2020 (Microsoft Corp., Redmond, WA, USA) software.

Results

Subject Demographic

A total of 117 elderly patients participated in this study, but 59 elderly patients were excluded because of degenerative diseases. After the exclusion, our cohort comprised 58 healthy elderly patients, with the diagnosis of one or more oral normal variances. The demographic data from those subjects can be found in ► **Table 2**. The majority of the subjects were in the age range of 60 to 74 years, and almost all of them were women.

Intraoral Examination

We identified seven normal variances of the oral mucosa: fissured tongue (93.1%), coated tongue (58.62%), crenated tongue (27.59%),

Table 2 Demographic data from healthy elderly participating in this study

Demographic aspect	Number of subjects	Percentage
Gender		
Male	3	5.17%
Female	55	94.83%
Age		
60–74 years old	53	91.38%
75–90 years old	5	8.62%
>90 years old	0	0%

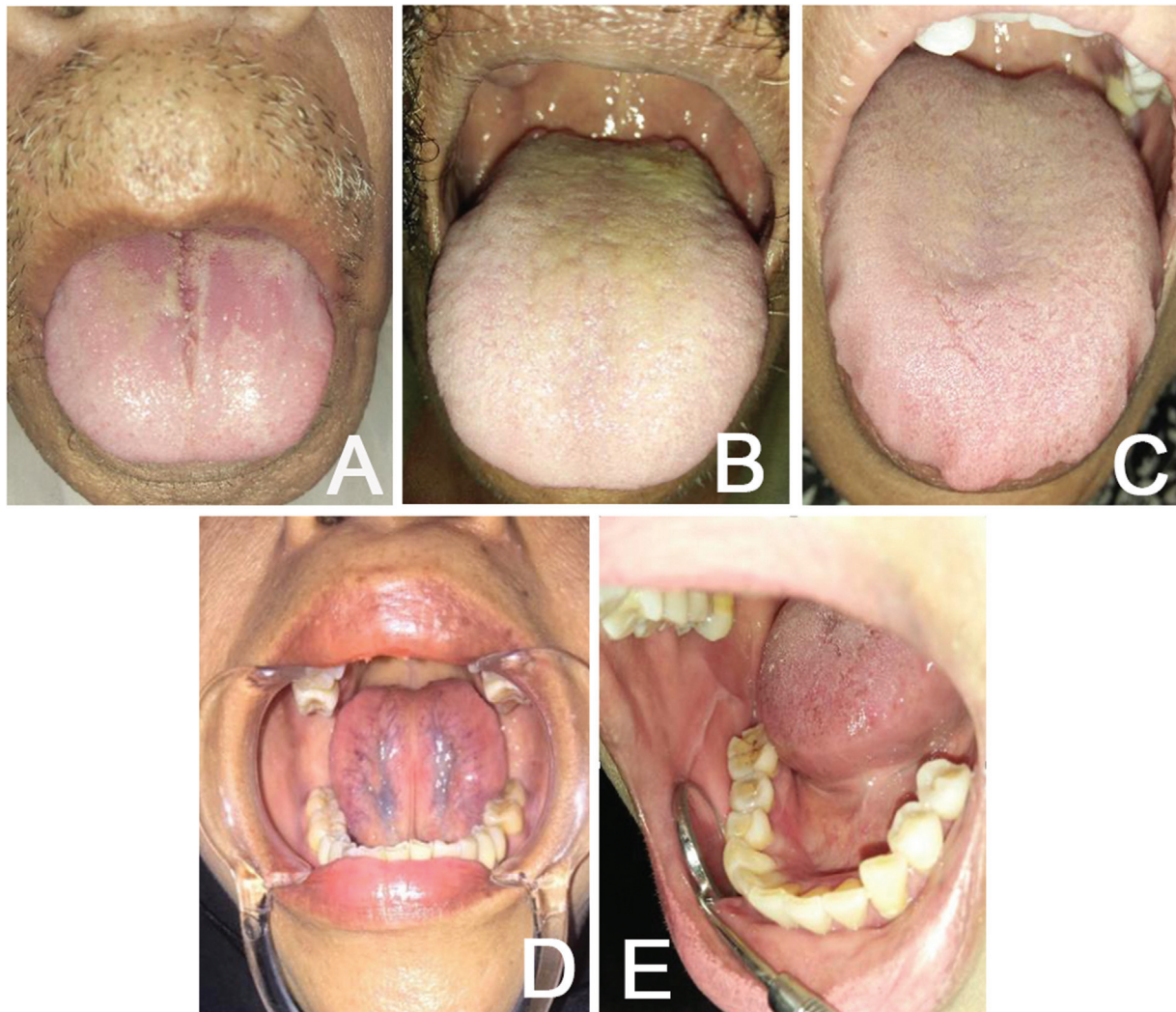

Fig. 1 Clinical appearance of oral normal variance in healthy elderly. (A) fissured tongue and atrophic glossitis; (B) coated tongue; (C) crenated tongue; (D) lingual varices, and (E) linea alba buccalis.

lingual varices (15.52%), atrophic glossitis (3.44%), linea alba buccalis (1.72%), and hyperpigmented papilla of the tongue (1.72%). The clinical appearance of those oral normal variances can be found in ►**Fig. 1**. As previously described, the most common normal variance found in this study was fissured tongue (►**Table 3**).

Table 3 Prevalence of pseudo lesions in healthy elderly

Oral normal variance	Number of subjects	Percentage
Fissured tongue	54	93.1%
Coated tongue	34	58.62%
Crenated tongue	16	27.59%
Lingual varices	9	15.52%
Depapilated tongue	2	3.44%
Linea alba buccalis	1	1.72%
Hyperpigmented papilla of the tongue	1	1.72%
Total subjects	58	100%

Discussion

According to the literature, the main oral health problems in the elderly are dry mouth and dental caries, which are associated with reduced salivary flow.⁹ These problems can worsen the presence of normal variance in the oral cavity of the elderly. As mentioned before, oral soft tissue lesions can interfere with daily activities, including mastication, swallowing, and talking, as well as cause symptoms such as xerostomia, halitosis, or dysesthesia. Therefore, treatment is paramount to improve the health of the oral cavity of the elderly.⁶

Aging affects the structure of the oral cavity, altering the teeth, periodontal tissue, mucosa, salivary glands, bone tissue, and taste buds.² The changes that occur include: Loss of elasticity and reduced vascularization in the oral mucosa, with a pale, thin, dry, and smooth aspect. The epithelium becomes more permeable, meaning it becomes more susceptible to various harmful substances, mechanical injuries, and irritant agents, as well as to microbes and fungi. Physical and immunological defense of the mucosa is impaired and the regenerative ability is reduced, making it

more susceptible to injury.⁶ The atrophy of the salivary gland's cell walls, especially in the ducts, causes a decrease in the salivary flow and results on the oral mucosa becoming dry and losing elasticity, as well as lip rupture and fissures on the tongue. The tongue loses filiform papillae, making it appear smooth, and often there is an increase in lingual varices on the ventral surface.¹⁰

Oral normal variance may occur with aging as a predisposing factor. It is important to identify general variations in the normal anatomy of the oral cavity and clinical findings that can be associated with systemic, psychological and behavioral conditions, especially in the elderly. Clinical findings of normal oral variance can assist clinicians in providing appropriate oral health services.¹¹ In vulnerable age groups, such as the elderly, there is a lot of normal variance in the oral cavity, especially lesions on the tongue, which are indicators of specific needs for oral intervention.¹⁰

In this study, it was found that 93.1% of the healthy elderly patients had a fissured tongue, which was the largest prevalence. Some other studies also found that fissured tongue is common in the elderly. The city of Maharashtra, India, presented the highest prevalence of abnormalities, reporting 51.7% of cases of fissured tongue.¹² In the Airlangga University Hospital, the prevalence of fissured tongue was 25.40%, which makes it fourth most common lesion.⁵ In India, it was reported that fissured tongue was the second-largest type of lesion found, amounting to 20.1%.¹³ Fissured tongue or lingua fissurata, plicated tongue, scrotal tongue, and groove tongue are lesions that are often found in the general population.¹⁴ The etiology has not yet been fully elucidated, but some argue that it is due to congenital factors; however, various other factors also play a role in the development of fissured tongue such as aging, hyposalivation, diabetes mellitus, candidiasis, and vitamin B deficiency.¹² According to the study of Maloth et al., the statistical analysis shows that the prevalence of fissured tongue increases significantly with age.¹⁵ With the high prevalence of fissured tongue in the elderly of Posyandu Lansia at the Public Health Center of Surabaya, it is essential to educate the elderly on good oral hygiene, specifically in relation with the tongue, to clean debris, and reduce the risk of microbial infection and halitosis.¹⁶ Fissured tongue usually does not cause pain, except in the cases of food debris collecting in the grooves, which can result in infections, inflammation, and irritation.⁸ If these lesions cause pain due to infection, then the treatment aims to reduce inflammation and infection.¹⁶

Coated tongue can occur due to the accumulation of debris on the tongue.¹¹ The high prevalence of coated tongue in the elderly is supported by the Omor et al. study, which proved statistically that the prevalence of coated tongue increases with age. The use of mouthwash and tongue brushing can improve tongue hygiene and reduce coated tongue.¹⁷

Crenated tongue can be caused by tongue pressure, such as the habit of pressing the tongue against the teeth, pushing the tongue, sucking the tongue, bruxism, macroglossia, and tongue thrusting.⁸

Lingual varices are developmental anomalies in old age. The etiology of this lesion is not known with certainty. But

according to other studies, lingual varices are related to age, smoking, and cardiovascular diseases.¹⁶ These lesions occur due to changes in the connective tissue or weakening of the venous wall, as a result of degeneration of elastic fibers associated with the aging process. These lesions do not require special treatment, except for aesthetic and personal reasons.¹¹ Lingual varices are harmless lesions, can be diagnosed clinically, and do not require treatment. Surgical excision can be performed for varicose thrombosis, and for the aesthetic importance of lip varicosities.⁸

Depapillated tongue, also known as atrophic glossitis, is characterized by loss of the tongue's papilla. This can be related to the emergence of burning sensation in some patients. The tongue's surface with loss of papillae is characterized by a red area on the dorsal surface of the tongue. Atrophic glossitis usually occurs in patients with nutritional deficiencies, xerostomia, lichenoid reaction, local trauma, candidiasis, and because of the aging process.¹⁸ The oral mucosa in the elderly becomes thinner and smoother. The tongue undergoes clinical changes and is smoother because of the loss of the filiform papillae.^{9,19}

Linea alba buccalis is a hyperkeratosis lesion associated with recurrent pressure, frictional trauma, and other parafunctional habits from the buccal surface of the tooth. There is no specific treatment for this lesion, as it arises because of friction trauma.¹¹ Linea alba buccalis usually does not cause pain. Some patients experience fear, because they mistake it for cancer. The treatment of this lesion is accomplished by eliminating the irritant.²⁰ Prevalence analysis with various factors that can cause linea alba buccalis can help determine the treatment quickly and prevent the emergence of further complications.²¹

It is important for health practitioners, including dentists, to increase their treatment standards and provide better service to the elderly, such as education about oral health and how to manage and treat normal variances. The limitation of this study is that we only used a clinical diagnosis to diagnose the normal variance of oral mucosa. Some normal variances need different tests and exams to reach the final diagnosis.

Conclusion

The most prevalent oral normal variance identified in this study was fissured tongue. However, the results of the current study should be interpreted with caution, and conducting new studies regarding oral hygiene, smoking, and racial populations, with large random samples would be highly recommended. Future studies need a bigger sample to diagnose more normal variances of oral mucosa.

Author's Contribution

All authors declare that they contributed to the critical review of intellectual content and approval of the final version to be published.

Funding

Kementerian Riset Teknologi Dan Pendidikan Tinggi Republik Indonesia. 4/AMD/E1/KP.PTNBH/2020

Conflict of Interests

The authors have no conflict of interests to declare.

References

- 1 KUSDHANY LS, SUNDJAJA Y, FARDANIAH S, ISMAIL RI. Oral health related quality of life in Indonesian middle-aged and elderly women. *Med J Indones* 2011;20(01):62-65
- 2 CHERUVATHOOR DD, THOMAS V, KUMAR NR, JOSE M. High prevalence of oral mucosal lesions in elderly: Call for revolutionizing geriatric dental care strategies. *J Family Med Prim Care* 2020;9(08):4375-4380
- 3 PAI A, DEVERASHETTY A. Changing Trends in the Oral Mucosa of Geriatric Population - An Epidemiological Study. *J Indian Acad Geriatr.* 2017;13(01):10-17
- 4 ALI M, JOSEPH B, SUNDARAM D. Prevalence of oral mucosal lesions in patients of the Kuwait University Dental Center. *Saudi Dent J* 2013;25(03):111-118
- 5 MAHDANI FY, RADITHIA D, PARMADIATI AE, ERNAWATI DS. Prevalence of oral mucosal lesions in geriatric patients in Universitas Air-langga Dental Hospital. *Acta Med Philipp* 2019;53(05):407-411
- 6 SHINDE SB, SHEIKH NN, SR A. Prevalence of tongue lesions in western population of Maharashtra. *Int J Appl Dent Sci.* 2017;3(03):104-108
- 7 AL-MAWERI SA, AL-JAMAEI AA, AL-SUFYANI GA, TARAKJI B, SHUGAA-ADDIN B. Oral mucosal lesions in elderly dental patients in Sana'a, Yemen. *J Int Soc Prev Community Dent* 2015;5(Suppl 1):S12-S19
- 8 DELLA VELLA F, LAURITANO D, LAJOLO C, et al. The Pseudolesions of the Oral Mucosa: Differential Diagnosis and Related Systemic Conditions. *Appl Sci (Basel)* 2019;9(12):2412
- 9 RAZAK PA, RICHARD KMJ, THANKACHAN RP, HAFIZ KAA, KUMAR KN, SAMEER KM. Geriatric oral health: a review article. *J Int Oral Health* 2014;6(06):110-116
- 10 LYNGE PEDERSEN AM, NAUNTOFTE B, SMIDT D, TORPET LA. Oral mucosal lesions in older people: relation to salivary secretion, systemic diseases and medications. *Oral Dis* 2015;21(06):721-729
- 11 MADANI FM, KUPERSTEIN AS. Normal variations of oral anatomy and common oral soft tissue lesions: evaluation and management. *Med Clin North Am* 2014;98(06):1281-1298
- 12 KAMINSKA-PIKIEWICZ K, CHALAS R, BACHANEK T. The condition of oral mucosa in the elderly (over 65 years) of Lublin. *Curr Issues Pharm Med Sci* 2017;30(01):39-42
- 13 BHATTACHARYA PT, SINHA R, PAL S. Prevalence and subjective knowledge of tongue lesions in an Indian population. *J Oral Biol Craniofac Res* 2016;6(02):124-128. Doi: 10.1016/j.jobcr.2015.12.007[Internet]
- 14 JÄRVINEN J, MIKKONEN JJW, KULLAA AM. Fissured tongue: a sign of tongue edema? *Med Hypotheses* 2014;82(06):709-712
- 15 MALOTH S, PADMASHREE S, SHILPA PS, SULTANA N. The Prevalence of Fissured Tongue in 2050 Indian Patients : a Cross Sectional Study. *Int J Dental Res Development* 2015;5(04):5-14
- 16 MANGOLD AR, TORGERTSON RR, ROGERS RS III. Diseases of the tongue. *Clin Dermatol* 2016;34(04):458-469
- 17 OMOR RA, ARABEYAT MA, HIASAT AN, et al. Prevalence and Factors Related to Tongue Coating among a Sample of Jordanian Royal Medical Services Dental Outpatients Rana. *J R Med Serv.* 2015;22(01):35-40
- 18 PATIL S, KASWAN S, RAHMAN F, DONI B. Prevalence of tongue lesions in the Indian population. *J Clin Exp Dent* 2013;5(03):e128-e132
- 19 SURBOYO M, ERNAWATI D, PARMADIATI A. Glossitis mimicking median rhomboid glossitis induced by throat lozenges and refreshment candies. *J Int Oral Health* 2019;11(05):323-328
- 20 KUMAR S, KUMAR T, RANI V. Linea Alba Buccalis a Normal Anatomic Variation of Oral Cavity, Not an Oral Cancer, Awareness among Patients and Professionals: A Case Report. *Scholars Journal of Dental Sciences* 2016;3(04):124-125
- 21 SHARMILA R. Prevalence of linea alba buccalis in Chennai population. *J Pharm Sci Res.* 2016;8(08):835-837