

Enxerto Bovino Orgânico Associado ao PRP em Calvária de Coelho

Organic Bovine Graft Associated with PRP in Rabbit's Calvaria

*Flaviana Soares Rocha**, *Lara Maria Alencar Ramos***, *Jonas Dantas Batista**,
*Darceny Zanetta-Barbosa****, *Paula Dechichi*****.

* Mestre. Professor (a) da Disciplina de Cirurgia e Traumatologia Buco-Maxilo-Facial.

** Mestre. Doutoranda em Estomatopatologia.

*** Doutor. Professor da Disciplina de Cirurgia e Traumatologia Buco-Maxilo-Facial.

**** Doutora. Professora da Disciplina de Histologia Oral.

Instituição: Faculdade de Odontologia da Universidade Federal de Uberlândia.
Uberlândia / MG – Brasil.

Endereço para correspondência: Flaviana Soares Rocha - Avenida Pará s/nº - Campus Umuarama - Bloco 4T - Departamento de Cirurgia e Traumatologia Buco-Maxilo-Facial - Bairro Umuarama - Uberlândia / MG - Brasil - CEP: 38400-902 – Telefone: (+55 34) 3218-2636 / 3238-6095 – E-mail: flavianasoaresha@gmail.com
FAPEMIG

Artigo recebido em 18 de Novembro de 2010. Artigo aprovado em 9 de Março de 2011.

RESUMO

Introdução: O reparo ósseo de grandes defeitos é um grande desafio para a cirurgia reconstrutora atualmente.
Objetivo: O objetivo desse estudo foi realizar avaliação histológica do reparo ósseo em calvária de coelhos depois do uso de enxerto ósseo bovino (Gen-ox-organic®) associado a plasma rico em plaquetas (PRP).
Método: Foram utilizados 12 coelhos, e dois fragmentos ósseos foram removidos da calvária bilateralmente. Então 24 sítios cirúrgicos foram aleatoriamente separados em 3 grupos: coágulo (grupo I), orgânico (grupo II) e orgânico com PRP (grupo III). Depois de quatro semanas, os animais foram sacrificados e a área enxertada foi removida, fixada em formol a 10%, em PBS 0,1M e incluídas em parafina.
Resultados: Os parâmetros histológicos analisados foram: área do defeito preenchida com osso neoformado, presença de células gigantes e partículas do enxerto, e neoformação óssea associada com as partículas. Os defeitos do grupo I foram preenchidos com tecido fibroso que condicionou o periosteio e apresentou uma pequena formação óssea na periferia. Nos grupos II e III, um padrão semelhante foi observado e também ausência de partículas do enxerto e células gigantes. Não houve diferença significativa no número de células gigantes, partículas do enxerto e neoformação óssea em volta das partículas entre o material enxertado e o grupo com PRP associado.
Conclusão: Os resultados obtidos indicam que o biomaterial orgânico isolado ou em associação com o PRP não melhoraram a regeneração óssea.
Palavras-chave: regeneração óssea, plasma rico em plaquetas, compostos orgânicos.

SUMMARY

Introduction: The osseous repairing in big imperfections is a great challenge for the restored surgery in nowadays.
Objective: The objective of this study was to make an histological evaluation of the osseous restore in rabbit's calvaria after the bovine osseous graft's (Gen-ox-organic®) usage associated with plasma rich in platelet (PRP).
Method: It was used 12 rabbits and 02 osseous fragments were removed from bilaterally calvarium. So among 24 surgical sites were randomly, divided in 03 groups: coagulum (group I), organic (group II) and organic with PRP (group III). After 04 weeks the animals were sacrificed and the grafted area was removed, fixed in formaldehyde at 10% in PBS 0,1M and included in paraffin.
Results: The histologic parameters analysed were: imperfection area filled up with neoformed, gigantic cells and graft's particles, and osseous neoformation associated with the particles. The group's I imperfections were filled up with fibrous tissue that conditioned the periosteum and presented a small osseous formation in the perimeter. In groups II and III, a similar pattern was observed and also with graft's particles and gigantic cell's absence. There was no significative difference in gigantic cells, graft's particles and neoformation's numbers around the particles between the grafted material and the group with PRP associated.
Conclusion: The obtained results show that the isolated organic biomaterial or in association with PRP did not improve the osseous regeneration.
Keywords: osseous regeneration, plasma rich in platelet, organic compounds.

INTRODUCTION

Reconstruction methods are essential for functional rehabilitation and treatment of traumatic bone loss or atrophic changes of the upper and lower jaws. Autogenous bone graft is considered the gold standard (17,20), however, autografting is limited by the amount of bone that can be retrieved, morbidity and risk of infection (17,22).

Biomaterials can be used for replacing autografts (22) and organic bovine bone matrix, an osteoconductive biomaterial (17) is used for these purpose (8) demonstrating good results in orthognatic (17) and trauma surgeries (4). During processing, the biomaterial is washed for elimination of blood, fat and any impurities to reduce the infection risks and immunogenic host response (9). Then, it is decalcified and dehydrated by the lyophilization process, which prevents denaturation of the proteins while keeping the active component, including bone morphogenetic protein (BMP) (4). Therefore, the biomaterial retains the trabecular collagenous framework of the original tissue and can serve as a biologic osteoconductive scaffold with osteoinductive proteins despite the loss of structural strength (9). In vivo studies have demonstrated the feasibility of the use of xenogenic bone in in orthognatic (17) and trauma surgeries (4), but the results remain controversial, with different outcomes according to the type of defect (33) and variable resorption rate (24).

The association of biomaterials with repair promoters, like platelet rich plasma (PRP), is promising (14) because it accelerates deposition and incorporation of new bone along the graft material, thereby reducing the time necessary to achieve ideal results. The PRP effect is attributed to local growth factors contained in the platelet. Additional advantages include their adhesive nature (13,18), hemostasis and lack of immune reaction (13). Studies have shown an increase in osteoblast activity and bone formation when mineralized (35,36) and demineralized bone matrices (17) are used associated with growth factors (21). However, some studies did not observe any increase in bone healing when using PRP (1,11,27). Therefore, the purpose of this study was histologically evaluate bone repair in rabbit calvaria bone defects, after using bovine organic bone matrix, associated or not with PRP.

METHOD

Material

The tested material was bovine organic bone (BOB) (GenOx-organic®, Baumer SA, Mogi Mirim, SP, Brazil).

PRP preparation

PRP was prepared following aseptic processing procedures according to Sonnleitner modified method (11). Blood was obtained several minutes before the administration of anesthesia. Five milliliters of blood was drawn from each rabbit from auricular vein using one 5ml vacutainer tubes containing anticoagulant (sodium citrate). A first centrifugation was done during 20 minutes at 1000 rpm (160g) to separate the cell from blood plasma. The supernatant and 2 mm below the dividing line between the phases was pipetted and transferred to a tube without anticoagulant. A second centrifugation was done for 15 minutes at the speed of 1600 rpm (400g). The PRP was separated from platelet poor plasma (PPP). For each 0.5 mL of PRP, 25 microliters of 10% calcium chloride was added as an activator.

Surgery procedure

Twelve healthy mature female New Zealand white rabbits with a weight between 2,5 and 3,5kg were used as experimental animals. The experiment procedures were executed in conformity with the ethical principles of Brazilian College of Animal Experimentation. The animals were anesthetized intramuscularly with ketamine (25 mg/kg)/xylazine (10 mg/kg)/acepran (0.2 mg/kg)/midazolam (0.2 mg/kg) and local anesthesia with 0.9 mL of mepivacaine with epinephrine. A single prophylactic dose of antibiotic therapy with cephalosporin (30 mg/kg) was administered intravenously. With the rabbits in ventral position, trichotomy and antisepsis was performed in the calvaria region with a solution of topical povidine. This region received a middle line incision, which extended from the frontal to the occipital bone. The parietal bone was exposed by detaching the muscle and periosteum. Using an 8mm diameter trephine drill, under abundant irrigation with physiological solution, two defects were created in the right and left parietal bone. The defects were filled with coagulus (group I), BOB (group II) and BOB with PRP (group III). The animals received normal diet consisting of granular food and water *ad libitum*. Four weeks after surgery they were anesthetized with thiopental 2.5% and euthanatized with potassium chloride at 19.1%.

Sample evaluation

The bone pieces with the defects and the attached soft tissue were removed and immediately fixed in 10% phosphate buffered formaldehyde solution during 48h. Thereafter, the tissue blocks were decalcified in EDTA 4,13% during four weeks, dehydrated with graded alcohols and embedded in paraffin. The histological semi-serial

Table 1. Established criteria for evaluation.

| Score | Defects Bone Filling | Giant Cells | Graft particles | Bone neoformation around graft particles |
|-------|---|---|---|--|
| 0 | Absent (no bone formation) | Absent | Absent | Absent |
| 1 | Little (1/4 of the defect filled) | Little (present in 1/4 of the graft particles)* | Little (present in 1/4 of the defect) | Little (present in 1/4 of the graft particles) |
| 2 | Moderate (1/2 of the defect filled) | Moderate (present in 1/2 of the graft particles)* | Moderate (present in 1/2 of the defect) | Moderate (present in 1/2 of the graft particles) |
| 3 | Abundant (more than 1/2 of the defect filled) | Abundant (present in more than 1/2 of the graft particles)* | Abundant (present in more than 1/2 of the defect) | Abundant (present in more than 1/2 of the graft particles) |

* Giant cells were associated to graft particles.

sections of 5µm thickness obtained were stained with Hematoxylin-Eosine and Mallory Trichrome. Histological analysis of bone filling in the defect area, presence of giant cells and graft particles in the defect area, bone neoformation associated with the graft particles, was performed under light microscope at X10 and X40 magnification in 3 sections for each paraffin block. The analysis using scores was conducted according to the following criteria (Table 1).

The results obtained were submitted to normality test, Kruskal-Wallis (Dunns post test) and Mann-Whitney tests. Differences were considered statistically significant at $p \leq 0.05$.

RESULTS

During the experiment all animal remained in good health and did not show complications. The histological analysis of the defect area showed normal healing process. No inflammatory signs or adverse tissue was observed irrespective of the evaluated groups.

In Group I (coagulus) the area of the defect showed a dense connective tissue (Figure 1A) with bundles of collagen fibers and little bone ingrowth from the periphery of the defect. The presence giant cells was not observed. In Groups II (organic) and III (organic with PRP) we observed little bone neoformation mainly from the edges of the defect (Figures 1B and 1C), similarly with Group I. The defect was completely filled with a connective tissue along with the periosteum. Particles of the implanted graft or neoformation associated with them were rarely seen. In all groups, calvaria thickness was reduced in the defect area, with loss of the original architecture.

Histological results revealed no statistically significant differences in defects bone filling between all studied groups ($p=0.83$). There was no significant difference in the

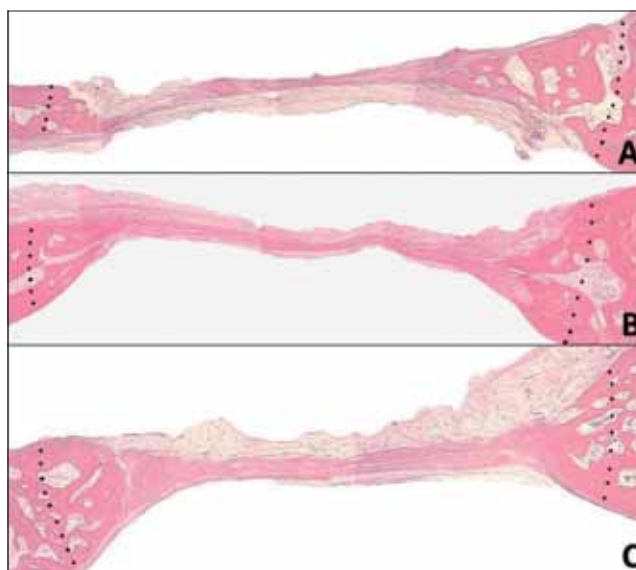


Figure 1. Area of the defect showed a dense connective tissue (Figure 1A) with bundles of collagen fibers and little bone ingrowth from the periphery of the defect, in Groups II (organic) and III (organic with PRP) a little bone neoformation mainly from the edges of the defect (Figures 1B and 1C).

number of giant cells ($p=0.49$), graft particles ($p=0.73$) and bone neoformation around graft particles (p not calculated) between the grafted materials whether PRP was added or not (Table 2).

DISCUSSION

Rabbits are used as biological models for evaluate bone repair due to physiological and metabolic similarities to humans (25). besides offering sufficient blood volume for preparation of platelet concentrates (13). Furthermore, platelets of humans and other mammals have a similar structure and constituents.

Table 2. Mean values and standard deviation of histological scoring of treated defects.

| Groups | Defects Bone Filling | Giant Cells | Graft particles | Bone neoformation around graft particles |
|------------------------------|----------------------|-------------|-----------------|--|
| Coagulous | 1.37 ± 0.49 | 0 ± 0 | 0 ± 0 | 0 ± 0 |
| Bovine Organic Bone | 1.27 ± 0.75 | 0.72 ± 0.46 | 0.05 ± 0.23 | 0 ± 0 |
| Bovine Organic Bone with PRP | 1.37 ± 0.48 | 0.83 ± 0.56 | 0.08 ± 0.28 | 0 ± 0 |

Bone regeneration in calvaria defects has some particularities due to the local tissue environment (10). In this study, care was taken to avoid damage in the underlying dura and also the periosteum, that contributes to graft revascularization and integrity (19). It provides blood supply for bone and osteoprogenitor cells, essential for bone regeneration (2).

Large bone defects cannot heal spontaneously, preventing the natural repair of the damaged bone, therefore, a precise comparison of different graft materials becomes possible (31). Autogenous graft is the pattern for reconstruction (16,17). However, researchers continuously try to improve on current bone grafting techniques and bone regeneration (3,5,30) to reduce the necessity of donor areas. Various bone substitutes and growth factors have recently become important in reconstructive surgeries (3,5).

The performance of organic bone substitutes is not very clear, but some studies in orthognatic (17) and trauma surgeries (4) demonstrated good results, what didn't occurs in the current study. The bone defects didn't exhibit new bone formation in the center of the defect in all experimental groups. Clearly, in the present study, the biomaterial was not able to maintain the original calvarial bone volume and, consequently didn't work as a scaffold. Bovine organic bone was rapidly absorbed and the histological analysis showed that the new bone formation was formed at peripheral areas, indicating a doubtful osteoconductive and osteoinductive (28) ability of the material, which didn't differ from coagulus.

Because the biomaterial resorption must occur just before the material can be replaced by newly formed bone, a delicate balance between the two concurrent processes must be maintained for the graft to be substituted by host bone without appreciable loss of volume (15). As such, the resorption rate and the time elapsed for the material resorption appears to be related to the amount of bone neoformation (24). When the graft particles are slowly absorbed, they act like a scaffold during the healing period, conducting the formation of new bone within the defects. Therefore, the accelerated resorption rate of organic bone matrices observed may be the main disadvantage of this material. As a result, demineralized bone could be indicated in procedures where variable

resorption may be acceptable (7) like the repair of small defects.

The material processing certainly decreases the risk of infection and immunogenic host response, nevertheless the possibility of disease transmission is not eradicated (9). Apparently, the material may elicit an antigenic stimulus sufficient to amount an antibody immune response in the host, resulting in accelerated incorporation and also, rapid graft resorption as observed in the present study. The biomaterial may be, for the host, an antigenic deposit which is continuously exposed to the immune system (23). As long as the graft resortion progress, the previously inaccessible incorporated proteins and, probably residual toxic agents derived from scaffold processing are released, affecting host cell viability and functions, including differentiation of surrounding osteogenic cells.

This material is formely known as an alternative graft formed by placing the harvested bovine bone in acid bath, resulting in an osteoconductive collagen matrix with BMP, which impart the osteoinductive properties of this graft (7). Despite the expected positive effect of the biomaterial, some studies claimed that the material processing can reduce the concentration of matrix incorporated factors or even result in their inactivation thereby accounting for the observed lack of osteoinductivity. This phenomenom may also be compounded by the presence of soluble osteogenic inhibitory factors, that can also be found in these kind of materials.

Platelets are a natural source of growth factors that play an important role in the wound-healing process (34). Increasing the concentration of platelets in a bone defect may lead to improved bone formation. However, the association of PRP to biomaterials stays controversial (27). Some *in vivo* studies demonstrated the effectiveness of PRP associated with bone substitutes for treating periodontal defects or for sinus floor augmentation (26). On the other hand, other studies have failed to show the favorable effect of PRP combined with various biomaterials on bone regeneration (32). The present study failed to identify a markedly increase in bone formation with the addition of PRP. The potency of growth factors liberated by PRP seems to be too weak to induce bone formation in defects with low regenerative capacity (29) like the ones of our study.

Platelets are known to be effective during the initial stage of bone graft healing (12), because the life span of a platelet in a wound and the period of direct influence of its growth factors are less than five days (6). Therefore, a major effect of PRP supposedly occurs during the early stages of bone regeneration (12) and couldnt be seen in long term evaluations like in this study. Additionally, bone neoformation along with the biomaterial particles didn't occur due to its fast resorption, which could have influenced the effectiveness of PRP.

CONCLUSION

In this study bovine bone material was not able to conduct the formation of new bone within defects. In accordance with the results, bovine organic bone matrix, isolated or associated with PRP, did not improve bone repair.

REFERENCES BIBLIOGRAPHICS:

1. Aghaloo TL, Moy PK, Freymiller EG. Evaluation of platelet-rich plasma in combination with freeze-dried bone in the rabbit cranium. A pilot study. *Clin Oral Implants Res.* 2005, 16(2):250-7.
2. Iberius P, Isaksson S, Klinge B, Sjögren S, Jönsson J. Regeneration of cranial suture and bone plate lesions in rabbits. Implications for positioning of osteotomies. *J Craniomaxillofac Surg.* 1990, 18(6):271-9.
3. Barone FC. Endogenous brain protection: models, gene expression, and mechanisms. *Methods Mol Med.* 2005, 104:105-84.
4. Bostrom MP, Seigerman DA. The clinical use of allografts, demineralized bone matrices, synthetic bone graft substitutes and osteoinductive growth factors: a survey study. *HSS J.* 2005, 1(1):9-18.
5. Butz SJ, Huys LW. Long-term success of sinus augmentation using a synthetic alloplast: a 20 patients, 7 years clinical report. *Implant Dent.* 2005, 14(1):36-42.
6. Choi BH, Im CJ, Huh JY, Suh JJ, Lee SH. Effect of platelet-rich plasma on bone regeneration in autogenous bone graft. *Int J Oral Maxillofac Surg.* 2004, 33(1):56-9.
7. Constantino PD, Facs S, Hiltzik D, Govindaraj S, Moche J. Bone Healing and Bone Substitutes. *Fac. Plastic Surg.* 2002, 18(1):25-34.
8. Eppley BL, Pietrzak WS, Blanton MW. Allograft and alloplastic bone substitutes: a review of science and technology for the craniomaxillofacial surgeon. *J Craniofac Surg.* 2005, 16(6):981-9.
9. Giannoudis PV, Al-Lami MK, Tzioupis C, Zavras D, Grotz MR. Tricortical bone graft for primary reconstruction of comminuted distal humerus fractures. *J Orthop Trauma.* 2005, 19(10):741-3.
10. Gosain AK, Santoro TD, Song LS, Capel CC, Sudhakar PV, Matloub HS. Osteogenesis in calvarial defects: contribution of the dura, the pericranium, and the surrounding bone in adult versus infant animals. *Plast Reconstr Surg.* 2003, 112(2):515-27.
11. Hatakeyama M, Beletti ME, Zanetta-Barbosa D, Dechichi P. Radiographic and histomorphometric analysis of bone healing using autogenous graft associated with platelet-rich plasma obtained by 2 different methods. *Oral Surg Oral Med Oral Pathol Oral Radiol Endod.* 2008, 105(1):13-8.
12. Kanno T, Takahashi T, Tsujisawa T, Ariyoshi W, Nishihara T. Platelet-rich plasma enhances human osteoblast-like cell proliferation and differentiation. *J Oral Maxillofac Surg.* 2005, 63(3):362-69.
13. Kim E, Park E, Choung P. Platelet concentrates and its effect on bone formation in calvarial defects: an experimental study in rabbits. *J Prosth. Den.* 2001, 86:428-33.
14. Kim SG, Kim WK, Park JC, Kim HJ. A comparative study of osseointegration of Avana implants in a demineralized freeze-dried bone alone or with platelet-rich plasma. *J Oral Maxillofac Surg.* 2002, 60(9):1018-25.
15. Lewandrowski KU, Rebmann V, Pässler M, Schollmeier G, Ekkernkamp A, Grosse-Wilde H, Tomford WW. Immune response to perforated and partially demineralized bone allografts. *J Orthop Sci.* 2001, 6(6):545-55.
16. Lohmann H, Grass G, Rangger C, Mathiak G. Economic impact of cancellous bone grafting in trauma surgery. *Arch Orthop Trauma Surg.* 2007, 127(5):345-8.
17. Lye KW, Deatherage JR, Waite PD. The use of demineralized bone matrix for grafting during Le Fort I and chin osteotomies: techniques and complications. *J Oral Maxillofac Surg.* 2008, 66(8):1580-5.
18. Lysiak-Drwal K, Dominiak M, Solski L, Zywicka B, Pielka S, Konopka T, Gerber H. Early histological evaluation of bone defect healing with and without guided bone regeneration techniques: experimental animal studies. *Postepy Hig Med Dosw (Online).* 2008, 11(62):282-8.

19. Manson PN. Facial bone healing and bone grafts. A review of clinical physiology. *Clin Plast Surg*. 1994, 21(3):331-48.
20. Maus U, Andereya S, Gravius S, Siebert CH, Ohnsorge JA, Niedhart C. Lack of effect on bone healing of injectable BMP-2 augmented hyaluronic acid. *Arch Orthop Trauma Surg*. 2008, 128(12):1461-6.
21. Mott DA, Mailhot J, Cuenin MF, Sharawy M, Borke J. Enhancement of osteoblast proliferation in vitro by selective enrichment of demineralized freeze-dried bone allograft with specific growth factors. *J Oral Implantol*. 2002, 28(2):57-66.
22. Nacamuli RP, Longaker MT. Bone induction in craniofacial defects. *Orthod Craniofac Res*. 2005, 8(4):259-66.
23. Nordström E, Ohgushi H, Yoshikawa T, Yokobori AT Jr, Yokobori T. Osteogenic differentiation of cultured marrow stromal stem cells on surface of microporous hydroxyapatite based mica composite and macroporous synthetic hydroxyapatite. *Biomed Mater Eng*. 1999, 9(1):21-6.
24. Norton MR, Odell EW, Thompson ID, Cook RJ. Efficacy of bovine bone mineral for alveolar augmentation: a human histologic study. *Clin Oral Implants Res*. 2003, 14(6):775-83.
25. Nunamaker DM. Experimental models of fracture repair. *Clin Orthop Relat Res*. 1998, 355(Suppl):56-65.
26. Okuda K, Tai H, Tanabe K, Suzuki H, Sato T, Kawase T, Saito Y, Wolff LF, Yoshiex H. Platelet-rich plasma combined with a porous hydroxyapatite graft for the treatment of intrabony periodontal defects in humans: a comparative controlled clinical study. *Periodontol*. 2005, 76(6):890-8.
27. Plachokova AS, van den Dolder J, Stoelinga PJ, Jansen JA. Early effect of platelet-rich plasma on bone healing in combination with an osteoconductive material in rat cranial defects. *Clin Oral Implants Res*. 2007, 18(2):244-51.
28. Sanada JT, Rodrigues JGR, Canova GC, Cestari TM, Taga EM, Taga R et al. Análise histológica, radiográfica e do perfil de imunoglobulinas após implantação de enxerto de osso esponjoso bovino desmineralizado em bloco em músculo de ratos. *J. Appl. Oral Sci*. 2003, 11(3): 209-215.
29. Sarkar MR, Augat P, Shefelbine SJ, Schorlemmer S, Huber-Lang M, Claes L, Kinzli L, Ignatius A. Bone formation in a long bone defect model using a platelet-rich plasma-loaded collagen scaffold. *Biomaterials*. 2006, 27(9):1817-23.
30. Schizas C, Triantafyllopoulos D, Kosmopoulos V, Tzinieris N, Stafylas K. Posterolateral lumbar spine fusion using a novel demineralized bone matrix: a controlled case pilot study. *Arch Orthop Trauma Surg*. 2008, 128(6):621-5.
31. Schmitz JP, Hollinger JO. The critical size defect as an experimental model for craniomandibulofacial nonunions. *Clin Orthop Relat Res*. 1986, 205:299-308.
32. Tsay RC, Vo J, Burke A, Eisig SB, Lu HH, Landesberg R. Differential growth factor retention by platelet-rich plasma composites. *J Oral Maxillofac Surg*. 2005, 63(4):521-8.
33. Torricelli P, Fini M, Giavaresi G, Rimondini L, Giardino R. Characterization of bone defect repair in young and aged rat femur induced by xenogenic demineralized bone matrix. *J Periodontol*. 2002, 73(9): 1003-9.
34. Weibrich G, Kleis WK, Hafner G, Hitzler WE, Wagner W. Comparison of platelet, leukocyte, and growth factor levels in point-of-care platelet-enriched plasma, prepared using a modified Curasan kit, with preparations received from a local blood bank. *Clin Oral Implants Res*. 2003, 14(3):357-62.
35. Zambuzzi WF, Oliveira RC, Alanis D, Menezes R, Letra A, Cestari, TM, Taga R, Granjeiro JM. Microscopic analysis of porous microgranular bovine anorganic bone implanted in rat subcutaneous tissue. *Journal of Applied Oral Science*. 2005, 13(4):382-86.
36. Zambuzzi WF, Oliveira RC, Pereira FL, Cestari TM, Taga R, Granjeiro JM. Rat subcutaneous tissue response to macrogranular porous anorganic bovine bone graft. *Braz Dent J*. 2006, 17(4):274-8.