

Use of intrarradicular pins in primary teeth: case report of one year of accompanying

Uso de pinos intrarradiculares em dentes decíduos: relato de caso de um ano de acompanhamento

Rafaela Cavalcanti **AMARAL**¹  000-0002-9162-4622
Ivana Aguiar **FERREIRA**¹  0000-0003-3548-2276
Soraya Cristhina de Souza **CAMPELLO**¹  0000-0003-3059-4658
Ana Flávia Bissoto **CALVO**¹  0000-0001-9572-7955
Tamara Kerber **TEDESCO**²  0000-0003-0794-1578
José Carlos Petorossi **IMPARATO**¹  0000-0002-1990-2851

ABSTRACT

Primary teeth have an important role in the growth and development of the child, besides being important for the good performance of masticatory function, phonation, occlusion and aesthetics, are the best space maintainers and eruption guide for the permanent successor. For anterior region, there are different alternatives of rehabilitation treatment, however, it is up to the professional to choose the best option. **Objective:** To present a therapeutic management of upper incisors affected by carious lesion with intrarradicular pin in early childhood. Case report: male patient, with 2 years and 7 months of age and significant loss of dental structure at an early stage. In the impossibility of performing direct restoration, we opted for the rehabilitation with the use of glass fiber pins for intraradicular reinforcement and composite resin restorations in order to restore shape, function and aesthetics. **Conclusion:** The use of fiberglass intra-radicular pins associated with direct restoration of composite resin is a recommended technique for the reconstruction of anterior teeth with great destruction.

Indexing terms: Dental Caries. Tooth, Deciduous. Mouth rehabilitation. Esthetics. Pediatric Dentistry.

RESUMO

Os dentes decíduos possuem um papel importante no crescimento e desenvolvimento da criança, além de serem importantes para o bom desempenho da função mastigatória, fonação, oclusão e estética, são os melhores mantenedores de espaço e guia de erupção para o sucessor permanente. Para região anterior, existem diferentes alternativas de tratamento reabilitador, porém, cabe ao profissional escolher a melhor opção **Objetivo:** Apresentar uma conduta terapêutica dos incisivos superiores acometidos por lesão de

▼ ▼ ▼ ▼ ▼

¹ Faculdade São Leopoldo Mandic, Instituto de Pesquisas São Leopoldo Mandic, Área de Odontopediatria. Rua José Rocha Junqueira, 13, Swift, 13045-755, Campinas, SP, Brasil. Correspondência para / Correspondence to: AFB CALVO. E-mail: <anacalvo@usp.br>.

² Universidade Ibirapuera, Programa de Pós-Graduação em Ciências Odontológicas. São Paulo, SP, Brasil.

▼ ▼ ▼ ▼ ▼

How to cite this article

Amaral RC, Ferreira IA, Campello SCS, Calvo AFB, Tedesco TK, Imparato JCP. I. Use of intrarradicular pins in primary teeth - case report of one year of accompanying. RGO, Rev Gaúch Odontol. 2019;67:e20190040. <http://dx.doi.org/10.1590/1981-86372019000413672>

cárie com pino intrarradicular na primeira infância. Relato do caso: paciente do sexo masculino, com 2 anos e 7 meses de idade e perda significativa de estrutura dentária de forma precoce. Na impossibilidade de ser realizada restauração direta, optou-se pela reabilitação com o uso de pinos de fibra de vidro para reforço intrarradicular e restaurações em resina composta em para restabelecimento da forma, função e estética. **Conclusão:** A utilização de pinos intraradiculares de fibra de vidro associada a restauração direta de resina composta é uma técnica recomendada para a reconstrução de dentes deciduos anteriores com grande destruição.

Termos de indexação: Cárie dentária. Dente decíduo. Reabilitação bucal. Estética. Odontopediatria.

INTRODUCTION

Primary teeth have an important role in the growth and development of the child [1], besides being important for the good performance of masticatory function, phonation, occlusion and aesthetics, are the best space maintainers and eruption guide for the permanent successor [2].

Currently, pediatric dentistry has as a priority to offer a course with an emphasis on prevention [3,4], but there is still a high rate of dental trauma and early-onset caries disease, with rapid evolution, in children up to 71 months old [4]. Coronary destruction of primary teeth, whether by trauma or caries, can affect speech, generate parafunctional habits, malocclusion, decrease in masticatory efficiency, and psychologically affect the child if the aesthetics is compromised [5,6]. Therefore, it is extremely important to establish a suitable chewing system for the child [7].

For the previous region, there are different alternatives of rehabilitation treatment [8], however, it is up to the professional to choose the best option, in order to return function and esthetics to the child, while at the same time offering maximum safety and comfort during achievement [9]. In some situations, because of extensive coronary destruction, prosthetic resources can not be applied directly to the teeth, requiring intra-radicular retention that can be performed with various materials, such as fiberglass pins [10,11].

Considering the complexity of the early childhood approach to endodontic and rehabilitative treatment [12], the present case report aims to present a therapeutic management of upper incisors with advanced carious lesions in advanced stage.

CASE REPORT

Patient, 2 years and 7 months, male, attended the dental office, located in the city of Santa Inês - MA,

because the mother had perceived loss of dental structure in an early manner. During the anamnesis, good general health was reported, but the child had a diet with excess cariogenic foods, and clinical examination showed incomplete primary teeth, absence of second molars, and oral hygiene. The upper incisors presented with extensive coronary destruction (figure 1), and caries lesions on the occlusal surfaces of the posterior teeth, as well as initial carious lesions on the gingival margins, demonstrating high caries activity. After radiological examination (figure 2), the proposed treatment was: endodontics on teeth 51, 52 and 61, and restoration of the remaining teeth with Z350 composite resin (3M / ESPE; St. Paul, USA). The mother was advised about diet and oral hygiene of the child.

Pulpectomies were performed on the teeth 51, 52 and 61 (figure 3), using Guedes Pinto paste (camphorated paramonochlorophenol, iodoform and rifocort) as sealing paste, sealing with a thin layer of gutta-percha, and subsequent placement of the fiberglass pin (Whitepost, FGM, Joinville, BR) of 1 mm in diameter (figure 4). The pins were cemented in the cervical third, considering that they should be trimmed so that one third is in the root canal and two thirds to the middle of the future crown. The pins were cleaned with alcohol for the removal of oils and residues, followed by a silane layer (Maquira; Maringá, BR) for 1 minute, followed by the adhesive system (Single Bond, 3M / ESPE, St. Paul, USA). The teeth were conditioned with 37% phosphoric acid (Power Etching BM4; Maringá, BR) as a gel, and applied adhesive system. The pins were cemented with dual resin cement (AllCem CORE, FGM, Joinville, BR). Then, the fiberglass pins were covered by composite resin, forming a trunnion, and teeth 51, 52 and 61 were restored

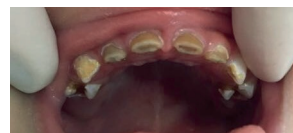

Figure 1. Initial case - upper incisor with extensive coronary destruction.

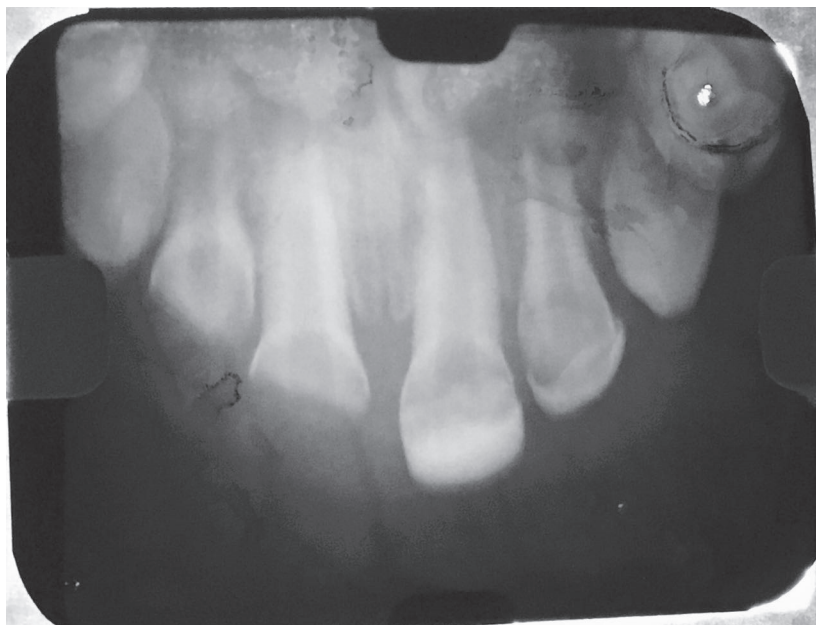


Figure 2. Initial radiograph - upper incisor.

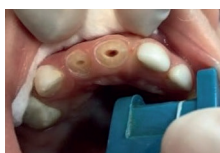


Figure 3. Endodontic preparation on the teeth 51 and 52.

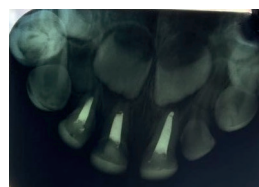


Figure 6. Radiographic follow-up of teeth 51, 52 and 61, after one year.

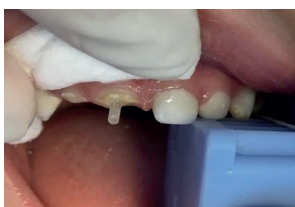

Figure 4. Tooth 51 with cemented fiberglass pin.

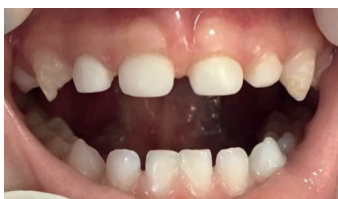

Figure 5. Clinical follow-up of teeth restorations 51, 52 and 61, after one year.

with the same composite resin, color WD by the direct technique. The remaining teeth did not require endodontic treatment, caries removal and restorations with the same composite resin were performed.

After one year of treatment, clinical and radiographic signs indicated treatment success (figure 5 and 6). Changes in habits, both in diet and in oral hygiene, could be identified.

DISCUSSION

For many years, due to the difficulty of retention of the restorative materials to the dental structures, the exodontia was a very indicated treatment option [12]. However, with the advancement of new techniques and evolution of aesthetic adhesive restorative materials, the treatment options increased, allowing a more favorable choice depending on the case [13-15].

The remaining structure of primary teeth with extensive coronary destruction usually does not support masticatory forces and does not have retention for restoration, thus requiring intracanal retention [13,14]. Note that after the endodontic treatment, the intra-radicular pin should occupy the cervical third of the root, because at that time, it will not interfere in the natural process of rhizolysis [15,16], corroborating what was done in the case report.

It is important to consider the degree of rhizolysis of the primary teeth that will receive the intra-radicular pin, the presence of pathological resorption and the rhizogenesis of the permanent successor tooth [14]; besides that in situations where there is bruxism, great loss of vertical dimension and with deep bite, the use of intra-radicular reinforcement is contraindicated, because insufficient prosthetic space for retention can lead to the overload of forces in the tooth in question, causing pathological reabsorption of the root or causing fracture or failure of restoration and intact root reinforcement [13]. The occlusion of the reported patient was class I, and showed no wear related to bruxism in the teeth, indicating the preparation of the pin and crown.

Given the various possibilities for rehabilitation of severely damaged anterior teeth, the professional should seek the best option for each patient, taking into consideration their age, behavior, remaining dental structure, patient occlusion and canal diameter [17].

According to some authors [18,19] when considering the technique performed, one should judge as many advantages as possible, since the maintenance of teeth and arches is of paramount importance for occlusion, phonetics, aesthetics and well-being of the child as of their parents [18]. The use of fiberglass pins has advantages such as ease of work, aesthetics, good mechanical properties, tooth-like elasticity, and uniform distribution of load stresses, which reduces the risk of fracture, increasing the durability of the restoration, in addition to having several diameters, being possible to be applied in narrow or wide channels [10,11,20], as was done in this case.

It is worth noting that in addition to hygiene and diet care, a periodic follow-up is necessary, in order to verify the pin adaptation, aesthetic and functional adjustment needs, as well as evaluation of normal premaxilla growth and eruption stage of the permanent successor tooth [4, 21-23]. The results pointed out in this report are up to one

year of follow-up. However, the patient continues to be re-evaluated periodically at intervals of every three months.

CONCLUSION

The use of fiberglass intra-radicular pins and the direct restoration of composite resin is a recommended technique for the reconstruction of anterior teeth with great destruction. It allows restoration of form, function and aesthetics, as well as being an easy-to-execute alternative.

Collaborators

RC AMARAL case management and article writing, IA FERREIRA Case management and article writing, SCS CAMPELLO article writing and review, AFB CALVO, revision of the article, TK TEDESCO revision and writing of the article, JCP IMPARATO revision and writing of the article.

REFERENCES

1. Gonçalves LM, Sabino-Bezerra JR, Pimentel MJ, Oliveira JCS, Gomes AMM. Uso de prótese fixa adesiva como mantenedor de espaço em dentes anteriores decíduos: um relato de caso. *Archives of Oral Research*. 2013;9(1):85-90. <http://dx.doi.org/10.7213/archivesoforalresearch.09.001.RC01>
2. Menegaz AM, Favetti M, Michelon D, Azevedo MS, Costa CT. Efetividade de mantedores de espaço em odontopediatria: revisão sistemática. *RFO*. 2015;20(2):252-257. <http://dx.doi.org/10.5335/rfo.v20i2.4363>
3. Ramos-Gomez FJ, Crystal YO, Ng MW, Crall JJ, Featherstone JDB. Pediatric dental care: prevention and management protocols based on caries risk assessment. *J Calif Dent Assoc*. 2010; 38(10): 746-761.
4. Oliveira LB, Peixoto LFS, Zardetto CGDC, Corrêa MSNP, Wanderley MT. Reabilitação de dentes decíduos anteriores com uso de pinos de fibra de vidro. *J Health Sci Inst*. 2010; 28(1): 89-93.
5. Ramos-Jorge J, Pordeu IA, Ramos-Jorge ML, Marques LS, Paiva SM. Impact of untreated dental caries on quality of life of preschool children: different stages and activity. *Community Dent Oral Epidemiol*. 2014;42(4):311-322. <http://dx.doi.org/10.1111/cdoe.12086>
6. Bayrak S, Tunc ES, Tuloglu N. Polyethylene fiber-reinforced composite resin used as a short post in severely decayed primary anterior teeth: a case report. *Oral Surg Oral Med Oral Pathol Oral Radiol Endod*. 2009;107(5):60-64. <http://dx.doi.org/10.1016/j.tripleo.2008.12.051>
7. Kantovitz KR, Papa AMC, Sacramento PA, Gavião MBD, Puppini-Rontani RM, Pascon FM. A Clinical report of functional

- and esthetic oral rehabilitation in a high-caries-risk child: one-year follow-up. *Braz Dent Sci.* 2016;19(1):125-128. <http://dx.doi.org/10.14295/bds.2016.v19i1.1151>
8. Damasceno LMCM, Marassi CS, Ramos MEB, Souza IPR. Alterações no comportamento infantil decorrente da perda de dentes anteriores: relato de caso. *Rev Bras Odontol.* 2002;59(3):193-196.
 9. Cardoso CAB, Lourenço Neto N, Paschoal MAB, Silva SMB, Lima JEO. Reabilitação bucal na primeira infância: relato de caso. *Rev Odontol Araçatuba.* 2011;32(2):49-53.
 10. Verrastro AP, Tashima AY, Faria FP, Alves KRG, Bussadori SK, Wanderley MT. Reconstrução de dentes decíduos anteriores com pino de fibra de vidro e matriz anatômica de celulósido: relato de caso clínico. *Conscientiae Saúde.* 2007;6(1):81-88.
 11. Subramaniam P, Babu KL, Sunny R. Glass fiber reinforced composite resin as an intracanal post-a clinical study. *J Clin Pediatr Dent.* 2008; 32(3): 207-210. <http://dx.doi.org/10.17796/jcpd.32.3.700t77h520473149>
 12. Galindo VAC, Nogueira JSE, Yamasaki E, Miranda D. Pinos biológicos e colagens de coroas naturais—uma alternativa na reabilitação de dentes decíduos anteriores. *JBP - J Bras Odontopediatr Odontol Bebê.* 2000;3:513-519.
 13. Pereira MA, Macedo MP, Penido CVSR. Reabilitação de incisivos decíduos superiores com núcleo metálico e coroa estética: relato de caso clínico. *Unimep.* 2012;22(2):51-55. <http://dx.doi.org/10.15600/2238-1236/fo.v26n2p91-98>
 14. Soares AL, Barroso EA, Toledo RA, Machado FC. Reabilitação estética na primeira infância: Relato de caso. *Unimep.* 2016; 26(2) 91-98. <http://dx.doi.org/10.15600/2238-1236/fo.v26n2p91-98>
 15. Schnider G, Rontani RMP. Reabilitação estética do segmento anterior da dentição decídua: alternativas de tratamento. *RFO/UPF.* 2004;9(1):64-70. <http://dx.doi.org/10.5335/rfo.v9i1.1645>
 16. Christensen GJ. Post concepts are changing. *J Am Dent Assoc.* 2004;135(9):1308-10. <http://dx.doi.org/10.14219/jada.archive.2004.0406>
 17. Lara SEL, Ayllón E, López E, Cury PR, Bónecker M. Restauração de dentes decíduos anteriores com uso de diferentes materiais para a confecção de pinos intra-radiculares: caso clínico. *Rev Ibero-am Odontopediatr Odontol Bebê.* 2004;7(35):14-24.
 18. Pereira L, Miasato JM. Mantenedor de espaço estético-funcional em Odontopediatria. *Rev Odontol Univ Cid Sao Paulo.* 2010;22(2):154-162. https://doi.org/10.26843/ro_unicid.v22i2.411
 19. Carneiro RC, Fonseca MS, Cruz RA. Alternativas estéticas e funcionais para a reconstituição de dentes decíduos anteriores com destruição excessiva. *Arq Bras Odontol.* 2006;2(1):17-25.
 20. Marques JN, Gonzalez CB, Silva EM, Pereira GDS, Simão RA, Prado M. Análise comparativa da resistência de união de um cimento convencional e um cimento autoadesivo após diferentes tratamentos na superfície de pinos de fibra de vidro. *Rev Odontol UNESP.* 2016;45(2): 121-126. <http://dx.doi.org/10.1590/1807-2577.18615>
 21. Ota CM, Corteleti JF, Cardenas ML, Novaes TF, Pessoa CP, Imparato JCP. Mantenedor fixo estético-funcional como tratamento para perda precoce de dentes decíduos anteriores. *Rev Assoc Paul Cir Dent.* 2014;68(4): 308-311.
 22. Gonçalves LM, Bezerra JRS, Pimentel MJ, Oliveira CS, Gomes AMM. Uso de prótese fixa adesiva como mantenedor de espaço em dentes anteriores decíduos: um relato de caso. *Archives of Oral Research,* 2013; 9(1): 85-90. <http://dx.doi.org/10.7213/archivesoforalresearch.09.001.RC01>
 23. Sousa JM, Jordão MC, Provenzano MGA, Fracasso MLC, Honório HM, Rios D. Utilização de prótese parcial fixa modificada na primeira infância: relato de caso. *Odontol Clínico-Científica.* 2012;11(3):253-257.

Received on: 27/9/2018

Final version resubmitted on: 10/11/2018

Approved on: 14/12/2018