

The importance of dental practice in oncological treatment: a case report associated with breast cancer

Importância da atuação odontológica no tratamento oncológico: relato de caso associado ao câncer de mama

landra Luah Souza **MAIA**¹  0000-0002-0587-0940

Rosany Larissa Brito de **OLIVEIRA**¹  0000-0001-8782-7585

Ellen Maiany Ribeiro **SANTANA**¹  0000-0001-5547-2417

Paula Patrícia Santos **SANTOS**¹  0000-0002-3995-6013

Álvaro Bezerra **CARDOSO**¹  0000-0002-6725-1547

ABSTRACT

In Brazil, the estimated number of new cancer cases between 2020 and 2022 is 625 thousand, and the most prevalent carcinomas are primarily skin (non-melanoma), followed by those of the breast, prostate, colon, and rectum. Although breast carcinoma still has a high mortality rate, it has a good prognosis due to the increase in early diagnosis and the evolution of anticancer treatments. The proposed treatment can be isolated or associated with resective surgery, radiotherapy, chemotherapy, and/or hormone replacement. Chemotherapy generates extensive immunosuppression and affects both healthy and altered cells, and the cytotoxicity of the treatment is an important effect that can cause lesions on the oral mucosa. Severity is related to the type of chemotherapeutic agent, treatment time, the dose used, and the individual's age. Additionally, chemotherapy treatment can exacerbate preexisting conditions in the individual and cause greater discomfort during treatment. Therefore, monitoring oral health before, during, and after anticancer therapy is essential. The objective of this work is to report a clinical case of dental emergency in a patient after the first cycle of doxorubicin- cyclophosphamide-paclitaxel (ACTdd) to treat breast cancer.

Indexing terms: Breast neoplasms. Dentistry. Oncology.

RESUMO

No Brasil, a estimativa de novos casos de câncer entre os anos 2020 a 2022 é de 625 mil, sendo os carcinomas mais prevalentes, principalmente os de pele (não melanoma), seguido pelos de mama e próstata, cólon e reto. O carcinoma de mama, embora ainda possua uma alta taxa de mortalidade, apresenta um bom prognóstico devido ao aumento do diagnóstico precoce e evolução dos tratamentos antineoplásicos. O tratamento proposto pode ser isolado ou associado, através de cirurgia ressectiva, radioterapia, quimioterapia e/ou reposição hormonal. A quimioterapia gera extensa imunossupressão e atinge tanto as células saudáveis como as alteradas, tendo a citotoxicidade do tratamento um importante efeito que pode gerar lesões na mucosa oral. A severidade está relacionada ao tipo de quimioterápico, ao tempo de tratamento, bem como à dose utilizada e à idade do indivíduo. Adicionalmente,

¹ Universidade Federal de Sergipe, Hospital Universitário, Programa de Residência Multiprofissional em Saúde do Adulto e do Idoso. Rua Cláudio Batista, s/n., Palestina, 49060-676, Aracaju, SE, Brasil. Correspondence: ILS Maia. E-mail: <landralsm.odonto@gmail.com>.

How to cite this article

Maia IIS, Oliveira RLB, Santana EMR, Santos PPS, Cardoso ABFF. The importance of dental practice in oncological treatment: a case report associated with breast cancer. RGO, Rev Gaúch Odontol. 2023;71:e20230035. <http://dx.doi.org/10.1590/1981-86372023003520220083>

o tratamento quimioterápico pode exacerbar condições previamente instaladas no indivíduo e causar um maior desconforto durante o tratamento. Desta forma, o monitoramento da saúde bucal antes, durante e após a terapia antineoplásica é essencial. O objetivo desse trabalho é relatar um caso clínico de urgência odontológica em uma paciente após o primeiro ciclo de doxorubicina-ciclofosfamida-paclitaxel (ACTdd) para o tratamento de câncer de mama.

Termos de indexação: Neoplasias da mama. Odontologia. Oncologia.

INTRODUCTION

Generally, cancer is among the four leading causes of death before the age of 70. Currently, there is a change in the types of cancer in developing countries, with a reduction in the types associated with infections and an increase in carcinomas related to better socioeconomic conditions. Incorporating harmful habits has contributed to this effect, including inadequate diet, sedentary lifestyle, and stress [1]. The estimate of new cancer cases between 2020 and 2022 is 625 thousand, and the most prevalent carcinomas are primarily skin carcinomas (non-melanoma), followed by those of the breast, prostate, colon, and rectum. It is estimated that in the state of Sergipe, 5,950 new cases will be registered annually between 2020 and 2022, with a higher incidence of prostate and breast carcinomas [2]. Therefore, malignant neoplasms are a public health problem whose early diagnosis, control, and prevention should be prioritized in health care [3,4].

Breast cancer can result from the multifactorial combination of genetics, age at first menarche, use of contraceptives, breastfeeding, menopause, hormone replacement therapy, alcohol and cigarette consumption, sedentary lifestyle, and exposure to ionizing radiation, among others. Approximately 5% to 10% are of genetic origin, while the remaining 90% to 95% are due to other factors [2,5]. Due to the increase in early diagnosis and the evolution of antineoplastic treatments, breast cancer has presented a good prognosis, although it still has a high mortality rate [6]. The proposed treatment can be isolated or associated with surgery, radiotherapy, chemotherapy, and/or hormonal treatment [5].

Chemotherapy generates extensive immunosuppression and affects both neoplastic and healthy cells. However, healthy cells recover between 5 and 15 days, while altered cells are disorganized and do not recover. For this reason, chemotherapy treatment is carried out in periodic cycles [7,8]. The cytotoxicity of treatment can exacerbate preexisting conditions and generate oral lesions [3,8-10]. The greatest aggressiveness to the cells happens in the period called NADIR, which occurs around 7 to 14 days right after each cycle of chemotherapy infusion. This period is related to a lower count of cells such as leukocytes, platelets, and red blood cells [2].

The presence of the dental surgeon is essential before, during, and after antineoplastic therapies to establish a protocol that involves adequacy of the oral environment, removal of foci of infection, the orientation of oral hygiene, early diagnosis, and treatment of the manifestations caused by the drugs [11,12].

This paper aims to report a case of a patient diagnosed with breast carcinoma who was referred to the Odontology Service of the University Hospital of the Federal University of Sergipe (HU/UFS) due to a progressing dental abscess.

CASE REPORT

The patient L.D.S., melanodermic, female, 43 years old, was diagnosed with invasive breast carcinoma of non-special type - Grade II, under chemotherapy treatment. Two days after the first cycle of doxorubicin-cyclophosphamide-paclitaxel (ACTdd), the patient sought the HU/UFS Oncology Emergency Service with pain and significant swelling in the right maxilla region. The patient was referred for dental evaluation after being prescribed antibiotic therapy and pain control medication (Amoxicillin 500mg and Dipyron 500mg sodium).

At the initial dental visit (figure 1), the patient reported not visiting the dentist frequently and not having had a dental evaluation before starting chemotherapy. On clinical examination, an extracted dental unit 18 was observed

(without the antagonist tooth) with an extensive caries lesion and signs of a progressing abscess. Radiographic evaluation (panoramic) revealed a thickening of the periodontal space of tooth 18 with the respective carious lesion clinically visualized and the presence of residual roots corresponding to teeth 15 and 24 (figure 2).

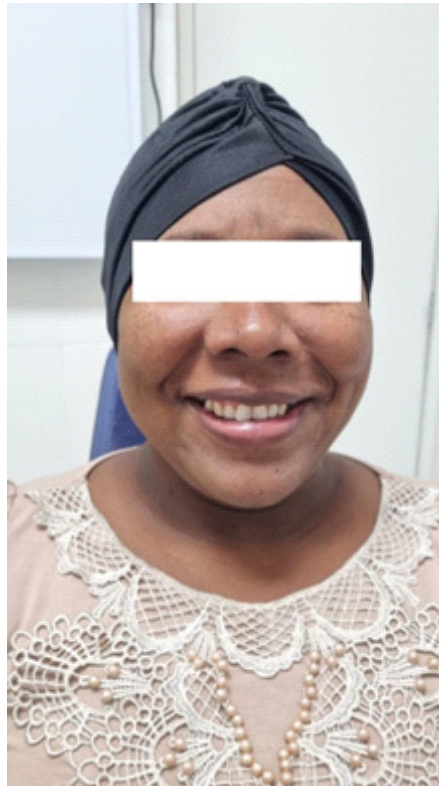

Figure 1. Extraoral photograph of the patient during the first visit with visible volume increase on the right side of the face.

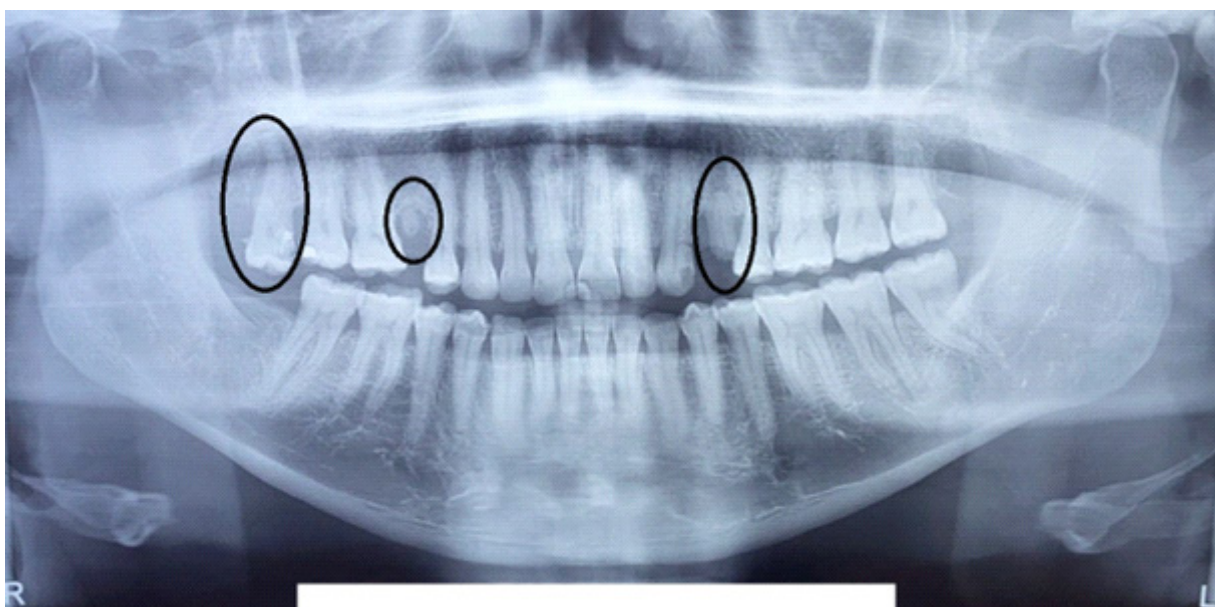


Figure 2. Radiographic exam (panoramic) showing residual roots 15 and 24 and thickening of the periodontal space of tooth 18, as well as a carious lesion.

After controlling the dental abscess with medication, the extraction of tooth 18 and residual roots of teeth 15 and 24 was planned under local anesthesia. Previously, 2g of amoxicillin was orally administered one hour before the procedure due to immunosuppression and a history of recent infection in unit 18.

For the surgical procedure, after intraoral (chlorhexidine 0.12%) and extraoral (chlorhexidine 2%) antiseptis, infiltrative anesthesia with lidocaine 2% and epinephrine 1:100,000 was used. In the region of tooth unit 18, a buccal flap was necessary for the primary closure of the alveolus (figure 3). The exodontia procedure occurred uneventfully, and the surgical sites were irrigated with 0.9% saline solution and sutured with 5-0 nylon (figure 4) and (figure 5).

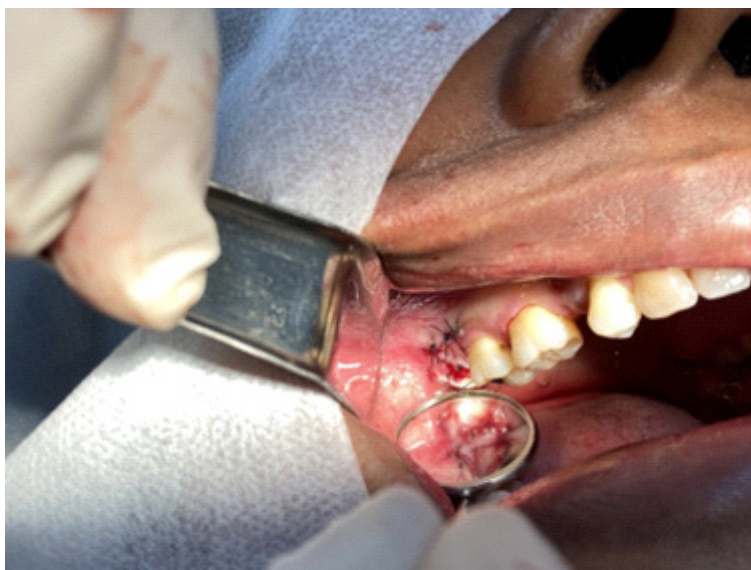

Figure 3. Exodontia of the DU 18 - Suture with primary closure of the alveolus.

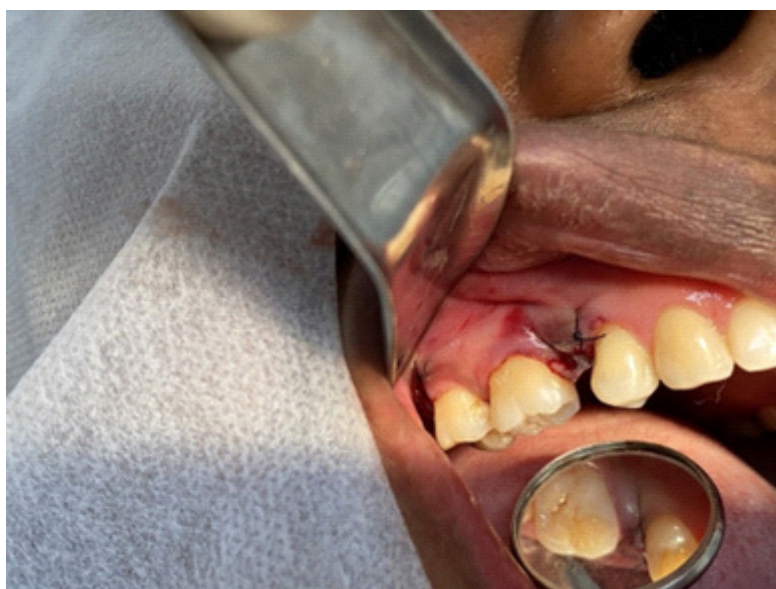

Figure 4. Exodontia of residual root 15 - Sutured alveoli after exodontia of residual root.

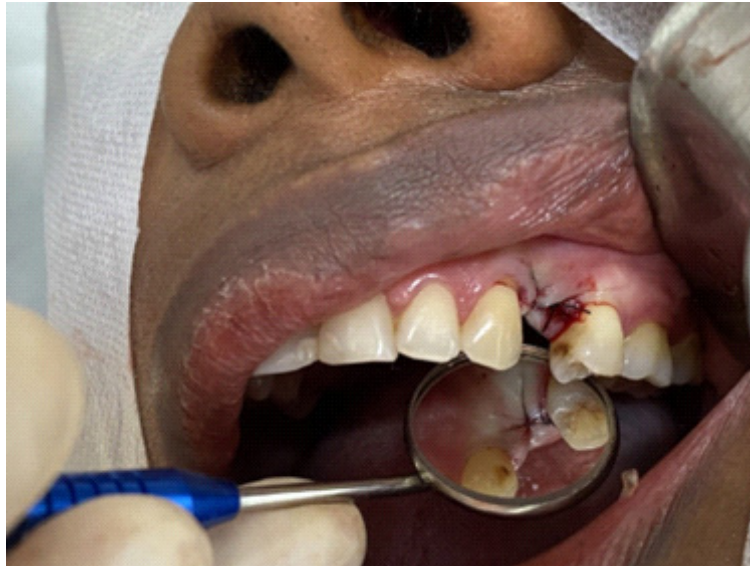

Figure 5. Exodontia of residual roots 24 - Sutured alveoli after exodontia of residual root.

In the figure 6 is visualized DU 18 and residual roots 15 and 24 extracted.

The prescribed postoperative medication consisted of amoxicillin 500 mg every 8 hours for 7 days, Ibuprofen 600 mg every 8 hours for 3 days, and dipyron 500 mg every 6 hours in case of pain. After removing the suture and verifying the epithelialization of the dental alveoli, which was within normal standards, the patient was referred to continue the oncologic treatment with follow-up by the HU/UFS Hospital Dentistry Team.

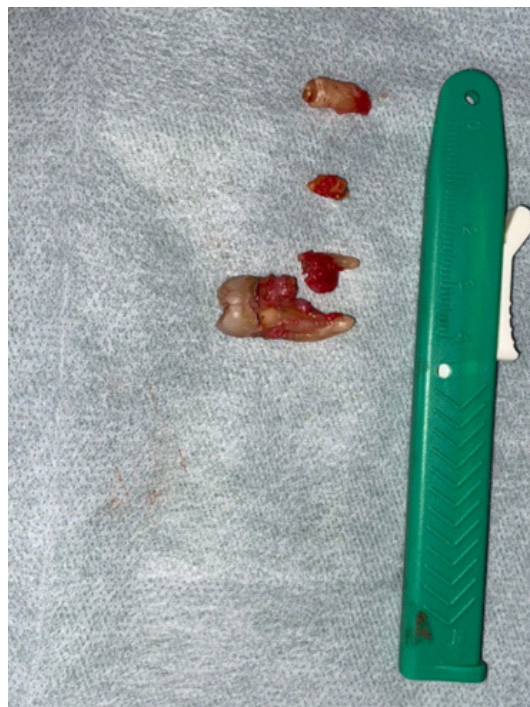

Figure 6. DU 18 and residual roots 15 and 24 extracted.

DISCUSSION

The ideal time to prepare a dental treatment plan and perform the adequacy of the oral environment is always before the patient is submitted to any oncological therapy, such as chemotherapy. The basis of dental treatment in the care of patients with malignant neoplasms consists of health education on preventive care, prevention, and treatment of mucositis, xerostomia, and secondary oral infections. Furthermore, it is important to perform oral hygiene instruction to control dental biofilm, eliminate sources of oral trauma (orthodontic appliances, ill-fitting prostheses, fractured teeth), and ensure the correct adaptation of the oral environment. The elimination of infectious foci performs these measures through supra and subgingival scraping, endodontic treatment, and exodontics [14,15]. Dental follow-up allows the prevention and immediate treatment of oral manifestations, providing control of the foci of pre-existing infections. Thus, they are prevented from becoming gateways for opportunistic infections and/or worsening during antineoplastic treatment with chemotherapy and/or radiotherapy, avoiding compromise of the systemic picture as well as the treatment and prognosis of cancer patients [15-17].

In a systematic review that analyzed 59 articles within the inclusion criteria, Hong et al. [10] updated the prevalence of dental infections and the effectiveness of strategies in preventing dental complications in cancer patients. The authors observed a low weighted prevalence of dental infections and pericoronitis during cancer therapy (5.4 and 5.3%, respectively). However, they recognized the importance of performing dental evaluation and treatment protocols before antineoplastic therapy. In the present case report, the patient required emergency dental treatment soon after the first cycle due to the lack of evaluation and consequent dental treatment prior to chemotherapy. The continuation of chemotherapy treatment (2nd cycle) had to be postponed due to the need to extract tooth 18 and the residual roots of units 15 and 24. In addition to delaying antineoplastic therapy and influencing the prognosis of the disease, this fact increases hospital costs. The previous systematic review also indicates keeping asymptomatic third molars or teeth without inflammation and/or active infection with the following clinical conditions: probing depth less than 8 mm, mobility grade I or II, and periapical lesions less than 5 mm. In these specific cases, only when there is not enough time for complete dental evaluation and treatment protocols [10].

In a prospective, longitudinal evaluation, the full treatment oral health of patients scheduled to receive neoadjuvant chemotherapy for head and neck cancer (pre-, during, and post-therapy periods) was analyzed. One hundred and thirty patients completed the three assessments, and the variables assessed were: 1) Simplified Oral Hygiene Index (S-OHI), 2) score of decayed, lost, or filled teeth (CPOD), 3) degree of mucositis, and 4) trismus. A total of 119 extractions were performed pre-chemotherapy, and the indications were extensive caries and tooth mobility due to advanced periodontitis. Twenty-three participants underwent restorative treatment. It was concluded that preventive oral care ensured that none of the patients undergoing chemotherapy began the treatment with dental abscesses or other signs of infection. Thus, the possibility of interrupting chemotherapy treatment due to dental alterations was also prevented [17].

A previous dental evaluation of the patient before starting oncologic therapy is essential. Ideally, treatment of pulpal and periodontal infections, especially in cases involving exodontia, should be performed at least 14 to 21 days before the start of cancer treatment for proper healing. Traumatic or acute-phase dental treatment during the oncologic treatment process should be avoided whenever possible due to the patient's systemic immunosuppression. Thus, dental follow-up is important for maintaining the good oral condition of patients [10,13,18].

It is noteworthy that, within the initial evaluation protocol of the oncology team of HU/UFS, all patients are referred for dental evaluation and treatment prior to the start of chemotherapy. However, the patient neglected the appointments for dental follow-up and treatment, which resulted in the temporary suspension of chemotherapy infusions due to the dental urgency of the progressing dental abscess.

The importance of initial dental care is evident. Counseling on preventive oral health practices is essential, as should all dental treatment be completed, preferably before the start of immunosuppressive therapy. Moreover, a collaborative and multi-professional care plan by the oncology team during and after antineoplastic therapy allows better results to be obtained for the patient [19,20].

CONCLUSION

Cancer treatment can produce or exacerbate numerous oral complications. Preventing and treating these complications requires the presence of a dentist in the multidisciplinary oncology team. Furthermore, it is necessary to establish a protocol for dental care in oncology services for a better quality of life for the patients treated. This follow-up must occur before and during all phases of oncological treatment to reduce oral complications and avoid delays and/or interruptions in antineoplastic therapy.

Collaborators

ILS Maia, conceptualization (equal), data curation (equal), writing - original draft (equal), writing - review & editing (equal). RLB Oliveira, conceptualization (equal), project administration (equal), writing - original draft (equal), writing - review & editing (equal). EMR Santana and PP Santos, Writing - review & editing (equal). AB Cardoso, conceptualization (equal), project administration (equal), writing - original draft (equal), writing - review & editing (equal).

REFERENCES

- Bray F, Ferlay J, Soerjomataram I, Siegel RL, Torre LA, Jemal A. Global cancer statistics 2018: GLOBOCAN estimates of incidence and mortality worldwide for 36 cancers in 185 countries [published correction appears in *CA Cancer J Clin*. 2020 Jul;70(4):313]. *CA Cancer J Clin*. 2018;68(6):394-424. <http://dx.doi.org/10.3322/caac.21492>
- Instituto Nacional do Câncer José Alencar Gomes da Silva. Estimativa 2020: incidência de câncer o Brasil. Rio de Janeiro: INCA; 2019 [acesso 2021 maio 19]. Disponível em: <<https://www.inca.gov.br/sites/ufu.sti.inca.local/files//media/document/estimativa-2020-incidencia-de-cancer-no-brasil.pdf>>.
- Araujo TLC, Mesquita LKM, Vitorino RM, Macedo AKMN, Amaral RC, Silva TF. Manifestações bucais em pacientes selecionados a tratamento quimioterápico. *Rev Cubana Estomatolog*. 2015;52(4):16-23.
- Facina T. Estimativa 2014: incidência de câncer no Brasil. *Rev Brasil Cancer*. 2014;60(1):63-44.
- Cedolini C, Bertozzi S, Londero AP, Bernardi S, Seriau L, Concina S, et al. Type of breast cancer diagnosis, screening, and survival. *Clinical Breast Cancer*. 2014;14(4):235-40. <http://dx.doi.org/10.1016/j.clbc.2014.02.004>
- Vries YC, Boesveldt S, Kelfkens CS, Posthuma EE, Van Den Berg MMGA, Kruif JThCM, et al. Taste and smell perception and quality of life during and after systemic therapy for breast cancer. *Breast Cancer Research and Treatment*. 2018; 170(1):27-34. <http://dx.doi.org/10.1007/s10549-018-4720-3>
- García-Chías B, Figuero E, Castelo-Fernández B, Cebrián-Carretero JL, Cerero-Lapiedra R. Prevalence of oral side effects of chemotherapy and its relationship with periodontal risk: a cross sectional study. *Support Care Cancer*. 2019;27(9):3479-3490. <https://doi.org/10.1007/s00520-019-4650-6>
- Martinez Martins AC, Caçador NP, Gaeti WP. Complicações bucais da quimioterapia antineoplásica. *Acta Scientiarum. Health Sciences*. 2008;24(2002):663-670. <https://doi.org/10.4025/actascihealthsci.v24i0.2481>
- Cardoso LM, Pansani TN, Hebling J, Souza Costa CA, Basso FG. Chemotherapy drugs and inflammatory cytokines enhance matrix metalloproteinases expression by oral mucosa cells. *Arch Oral Biol*. 2021; 127: 105159. <https://doi.org/10.1016/j.archoralbio.2021.105159>
- Hong C, Hu S, Haverman T, Stokman M, Napeñas JJ, Braber JB, et al. A systematic review of dental disease management in cancer patients. *Support Care Cancer*. 2018;26(1): 155-174. <https://doi.org/10.1007/s00520-017-3829-y>
- Fernandes IS, Fraga CPT. A importância do cirurgião-dentista nos efeitos adversos na cavidade bucal do tratamento oncológico de cabeça e pescoço. *Braz J Health*. 2022;5(1): 2052-2060. <https://doi.org/10.34119/bjhrv5n1-180>
- Freire AA, Honorato PM, Macedo SB, Araújo CS. Manifestações bucais em pacientes submetidos a tratamento quimioterápico no hospital de câncer do acre. *J Amazon Health Sci*. 2016;2(1): 1-21.
- Levi LE, Lalla RV. Dental treatment planning for the patient with oral cancer. *Dent Clin North Am*. 2018;62(1):121-130. <https://doi.org/10.1016/j.cden.2017.08.009>
- Mark AM. Oral care during cancer treatment. *J Am Dental Assoc*. 2019;150(1):82. <https://doi.org/10.1016/j.adaj.2018.10.019>
- Kusiak A, Jereczek-Fossa BA, Cichońska D, Alterio D. Oncological-therapy related oral mucositis as an interdisciplinary problem-literature review *Int J Environ Res Public Health*. 2020;17(7): 2464. <https://doi.org/10.3390/ijerph17072464>
- Silva SC, Queiróz CDS, Silva RD. Principais manifestações bucais em pacientes submetidos à quimioterapia: abordagem e tratamento odontológico. *Rev Multidisciplinar do Nordeste Mineiro*. 2021;1(2021):1-16 [acesso 2021 maio 19]. Available from: <https://revistas.unipacto.com.br/storage/publicacoes/2021/594_principais_manifestacoes_bucais_em_pacientes_submetidos_a_quimioterapia.pdf>.

17. Dholam KP, Sharma MR, Gurav SV, Singh GP, Prabhash K. Oral and dental health status in patients undergoing neoadjuvant chemotherapy for locally advanced head and neck cancer. Oral surgery, oral medicine, oral pathology and oral radiology. 2021; 132(5):539-548. <https://doi.org/10.1016/j.oooo.2021.07.018>
18. El Osta N, El Osta L, Lassauzay C, Ghosn M, Tubert-Jeannin S, Hennequin M. Oral health and chemotherapy act as cofactors in malnutrition in the elderly with other cancers than head and neck malignancies. Clinical oral investigations. 2019; 23(1):235-243. <https://doi.org/10.1007/s00784-018-2430-1>
19. Ritwik P, Chrisentery-Singleton T. Oral and dental considerations in pediatric cancers. Review Cancer Metastasis Rev. 2020; 39(1):43-53. <https://doi.org/10.1007/s10555-020-09842-5>
20. Ritwik P. dental care for patients with childhood cancers. Rev Ochsner J. 2018;18(4): 351-357. <https://doi.org/10.31486/toj.18.0061>

Received on: 1/11/2022

Approved on: 20/12/2022

Assistant editor: Luciana Butini Oliveira