









# Medial plantar flap for reconstruction of heel defects after resection of acral lentiginous melanoma: A series of seven cases

*Retalho plantar medial para reconstrução de defeitos em calcanhar após ressecção de melanoma lentiginoso acral: Uma série de 7 casos*

GIULIA GODOY TAKAHASHI<sup>1,2\*</sup>   
RENAN DIEGO AMÉRICO  
RIBEIRO<sup>1,2</sup>   
VITOR PENTEADO FIGUEIREDO  
PAGOTTO<sup>1,2</sup>   
CAIO AUGUSTO LIMA DE  
ARAÚJO<sup>1,2</sup>   
FÁBIO DE FREITAS  
BUSNARDO<sup>1,2</sup>   
ROLF GEMPERLI<sup>1,2</sup> 

## ■ ABSTRACT

**Introduction:** Resurfacing the sole is still one of the great challenges of reconstructive plastic surgery. The tissues on the sole of the foot have unique characteristics essential for maintaining the limbs functionality. The heel has the most significant weight support and is subjected to the entire soles greatest impact. The medial plantar artery flap is one of the reconstructive options, as it represents similar tissue and maintains sensitivity to the recipient area. **Methods:** A retrospective study was performed by collecting data from medical records of patients who underwent reconstructions of the heel with a medial plantar artery flap from July 2013 to September 2019. The study was approved by the Ethics Committee for Analysis of Research Projects of HCFMUSP (CAAE number: 56849422.0.0000.0068). **Results:** Heel reconstruction was performed in 7 patients after acral lentiginous melanoma excision. Surgical complications were observed in 3 patients, all of whom were aged over 50 years or have associated comorbidity. There were 57.1% of complications, 37.5% related to the flap, and 12.5% related to the donor area. There were three total flap necroses (42.9%) and one total graft loss in the donor area (14.3%). **Conclusion:** The medial plantar flap presents itself as a good alternative for performing oncological reconstructions of defects in the plantar region of the foot. However, the choice of the ideal patient should be considered and we must remember that the dissection of its vascular pedicle is not easily executed.

**Keywords:** Melanoma; Skin neoplasms; Surgical flaps; Reconstructive surgical procedures; Heel.

## ■ RESUMO

**Introdução:** A reconstrução da região plantar ainda é um dos grandes desafios da cirurgia plástica reconstrutiva. Os tecidos dessa região apresentam características únicas e que são essenciais para a manutenção da funcionalidade do membro. De toda a região plantar, a região do calcanhar é a área de maior sustentação do peso e submetida ao maior impacto. O retalho fasciocutâneo plantar medial é uma das opções reconstrutivas, pois representa tecido semelhante e mantém a sensibilidade para a área receptora. **Método:** Foi realizado um estudo retrospectivo através da coleta de dados de prontuário de pacientes que realizaram reconstruções da região do calcanhar com retalho plantar medial, no período de julho de 2013 a setembro de 2019. O estudo foi aprovado pelo Comitê de Ética para Análise de Projetos de Pesquisa do HCFMUSP (Número CAAE: 56849422.0.0000.0068). **Resultados:** A reconstrução de calcanhar após ressecção de melanoma lentiginoso acral foi realizada em 7 pacientes. Complicações cirúrgicas foram observadas em 3 pacientes, sendo que todos eles tinham idade acima de 50 anos e/ou alguma comorbidade associada. Houve 57,1% de complicações, sendo 37,5% relacionadas ao retalho e 12,5% relacionadas à área doadora. Ocorreram 3 necroses totais de retalho (42,9%) e 1 perda total de

Institution: Hospital das Clínicas da Universidade de São Paulo e Instituto do Câncer do Estado de São Paulo, São Paulo, SP, Brazil.

Article received: May 24, 2022.  
Article accepted: June 13, 2023.

Conflicts of interest: none.

DOI: 10.5935/2177-1235.2023RBCP0728-EN

<sup>1</sup> Instituto do Câncer do Estado de São Paulo, São Paulo, SP, Brazil.

<sup>2</sup> Hospital das Clínicas, Faculdade de Medicina, Universidade de São Paulo, São Paulo, SP, Brazil.

enxerto na área doadora (14,3%). **Conclusão:** O retalho plantar medial se apresenta como uma boa alternativa para a realização de reconstruções oncológicas de defeitos na região plantar do pé. Contudo, deve-se ponderar a escolha do paciente ideal e lembrar que a dissecação do seu pedículo vascular não é de fácil execução.

**Descritores:** Melanoma; Neoplasias cutâneas; Retalhos cirúrgicos; Procedimentos cirúrgicos reconstrutivos; Calcâneo.

## INTRODUCTION

Reconstruction of the plantar region is still one of the greatest challenges in reconstructive plastic surgery<sup>1,2</sup>. The tissues in this region have unique characteristics essential for maintaining the functionality of the limb. We can mention local characteristics: strong adhesion between the skin and deep structures, providing stability when walking; the presence of a thick cushion, allowing impact absorption when walking.

Of the entire plantar region, the heel region is the area with the greatest weight-bearing and subjected to the greatest impact. To this end, it is richly vascularized and has fibrous septa that connect the dermis to the periosteum of the calcaneal bone, forming fat compartments<sup>3-7</sup>.

We must, therefore, look for tissues with similar characteristics for the reconstruction of plantar defects in the heel<sup>8</sup>.

There are several methods of reconstruction of the plantar region, ranging from skin grafting to microsurgical flaps, but few meet all of these needs<sup>1,2,8-14</sup>.

The medial plantar fasciocutaneous flap is an excellent option, as it represents similar tissue and maintains sensitivity to the recipient area<sup>15,16</sup>.

Initially described in 1981 by Harrison & Morgan<sup>9</sup>, the medial plantar flap is based on the medial plantar artery and maintains local sensitivity through cutaneous branches of the medial plantar nerve<sup>17</sup>. Since then, several studies have been described in the literature, but few evaluate its use in cancer patients<sup>18,19</sup>.

## OBJECTIVE

To describe a series of 7 cases of reconstruction of heel defects after resection of acral lentiginous melanoma, performed at the Plastic Surgery Service of the Instituto do Câncer of the State of São Paulo, from July 2013 to September 2019.

## METHOD

A retrospective study collected data from medical records of patients who underwent reconstruction of the heel region with a medial plantar flap from July 2013 to September 2019.

Patients were selected according to the type of reconstruction used after resection of acral lentiginous melanoma by the Sarcoma and Melanoma Group at the Instituto do Câncer of the State of São Paulo. The inclusion criteria for the study were: patients admitted to the Instituto do Câncer of the State of São Paulo for resection of acral lentiginous melanoma of the heel region, undergoing reconstruction with a medial plantar flap.

Of the 7 patients, 3 (42.8%) were female, and 4 (57.1%) were male (Table 1). Six patients (85.7%) had some associated comorbidity, with smoking and systemic arterial hypertension being the most prevalent comorbidities. The average age of the patients was 57.3 years, ranging from 45 to 73 years.

The HCFMUSP Ethics Committee approved the study for Analysis of Research Projects (CAAE Number: 56849422.0.0000.0068).

## Surgical technique

The posterior tibial artery is identified through palpation posterior to the medial malleolus, and a broken line demarcation is made just above this region.

The skin island is demarcated according to the size of the defect in the heel region and can extend across the entire area outside of plantar support.

The incision begins with the demarcation posterior to the medial malleolus, and the posterior tibial artery is identified. The medial edge of the flap is incised, and the artery is dissected until its bifurcation. The medial branch is identified between the abductor hallucis and flexor digitorum brevis muscles. The flap is then elevated by including the plantar fascia and the lateral branch of the medial plantar nerve, sparing the medial innervation of the hallux.

The lateral, distal, and proximal edges are incised as the dissection progresses. The flap is transposed to the heel defect, and the donor area is reconstructed with a partial skin graft from the ipsilateral thigh (Figures 1 and 2).

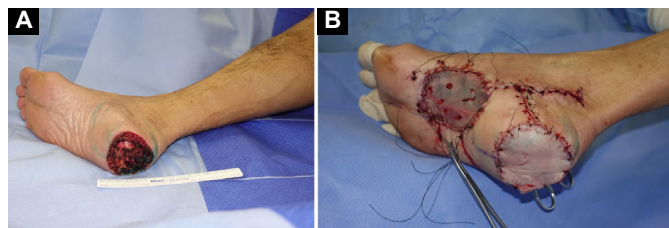
## RESULTS

One patient required additional reconstruction with local skin grafting; in the others, the medial plantar

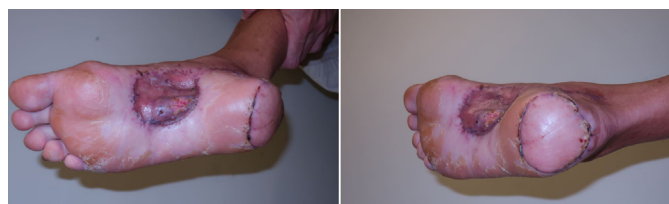**Table 1.** Patient characteristics, type of reconstruction performed, and complications related to the procedures.

	Age	Sex	Histologic Type	Comorbidities	Additional local reconstruction	Donor area	Retail complications	Donor area complications
1	58	M	Acrall Melanoma	Smoking, SAH	No	Partial skin grafting	Necrosis	No
2	53	M	Acrall Melanoma	Smoking, hypertension, DM	No	Partial skin grafting	Necrosis	No
3	64	M	Acrall Melanoma	Smoking, hypertension, alcoholism, CKD	No	Partial skin grafting	No	No
4	73	M	Acrall Melanoma	Smoking, hypertension, previous AMI	No	Partial skin grafting	No	No
5	51	F	Acrall Melanoma	Smoking, rheumatoid arthritis	Total skin grafting	Partial skin grafting	Não	Graft loss
6	45	F	Acrall Melanoma		No	Partial skin grafting	No	No
7	57	F	Acrall Melanoma	SAH	No	Partial skin grafting	Necrosis	No

M: Masculine; F: Female; SAH: Systemic Arterial Hypertension; DM: Diabetes Mellitus; CKD: Chronic Kidney Disease; AMI: Acute Myocardial Infarction.



**Figure 1. A:** Intraoperatively, after resection of the lesion with margins. **B:** Immediate postoperative reconstruction with a pedicled medial plantar flap on the heel and partial skin grafting on the flap donor area.



**Figure 2.** Postoperative result, with adequate functional and aesthetic results.

flap was sufficient to cover the dry areas. In all cases, partial skin grafting was performed in the flap donor area.

Lymphadenectomy was performed in 3 patients (42.8%), 2 (28.6%) in the left inguinal region, and 1 (14.3%) in the left inguinal region associated with the left iliac-obturator region. Among the 7 patients, 2 had metastatic disease (28.6%).

Surgical complications were observed in 3 patients, all over 50 years old and/or had some

associated comorbidity. The flap survival rate was 57%. Regarding complications, there were 3 total flap necrosis (42.9%) and 1 total graft loss in the donor area (14.3%). Of the 3 patients with flap necrosis, 2 required subsequent local reconstruction with an anterolateral fasciocutaneous microsurgical thigh flap and 1 with a lateral fasciocutaneous microsurgical arm flap.

One of the patients with total necrosis of the medial plantar flap underwent resection of acral lentiginous melanoma on the left lower limb, with immediate reconstruction with a medial plantar flap. He progressed well during hospitalization and was discharged on the seventh postoperative day. He returned for an outpatient consultation on the 11<sup>th</sup> postoperative day, presenting a flap with signs of distress at the edges. We opted for expectant treatment of the complication, and the flap presented total necrosis on the 26<sup>th</sup> postoperative day. Debridement and reconstruction with an anterolateral thigh microsurgical flap were performed. Currently, the patient presents a good appearance of the flap and good functionality of the left lower limb.

## DISCUSSION

Reconstruction of the soft tissues of the heel still represents a challenge for plastic surgeons due to the scarcity of local tissues and the complexity of this reconstruction to preserve functionality.

During surgical planning, it is important to assess whether the plantar injury is located in a support area, as grafts in this region can develop complications such as ulceration, scar retraction, pain, bone deformities, and inability to walk.

Initially described in 1981, the medial plantar flap still represents one of the best options for reconstruction of the heel region, especially on its plantar surface<sup>9</sup>. Among its advantages, the following stand out: similar local tissue and preserved innervation.

The local tissue is formed by a thick pad of skin without hair follicles, which provides adequate coverage for the pressure area and support for the patient's weight and is aesthetically more favorable. Innervation through the cutaneous branch of the medial plantar nerve allows the patient to maintain sufficient tactile sensitivity for adequate ambulation and limb protection.

As a disadvantage of the medial plantar flap, we can mention the morbidity of the donor area, located in the plantar cavity region, which constitutes an area of non-support and where partial skin grafting is necessary. Despite the section of the medial plantar artery, the foot maintains its adequate vascularization through the deep plantar arch, formed by the foot's lateral and dorsal plantar arteries.

The medial plantar flap has the following limitations: size and depth of the area to be reconstructed, limited to smaller defects. Larger resections should preferably be reconstructed with fasciocutaneous or musculocutaneous microsurgical flaps, and alternatively, they can be reconstructed with the reverse sural flap.

Although the medial plantar flap is described in the literature with low complication rates, most published studies describe the medial plantar flap in patients suffering from trauma or pressure ulcers, with a lower average age<sup>4,8,11,16,17,20,21</sup>. This work focused on cancer patients, who typically have multiple comorbidities, advanced age, and, therefore, atheromatosis, a selection bias that could explain the higher rate of complications in this study. Furthermore, the study was carried out in a teaching hospital, where the surgical procedures were performed by different surgeons still on the learning curve.

## CONCLUSION

The medial plantar flap is versatile and has a well-known vascular anatomy. Today, it presents itself as a great alternative for conducting oncological reconstructions of defects in the plantar region of the foot. However, the choice of the ideal patient must be

considered, and remember that the dissection of the vascular pedicle is not easy to perform.

## COLLABORATIONS

- GGT** Conception and design study, Final manuscript approval, Investigation, Project Administration, Supervision, Visualization, Writing - Original Draft Preparation, Writing - Review & Editing.
- RDAR** Analysis and/or data interpretation, Conception and design study, Data Curation, Final manuscript approval, Investigation, Visualization, Writing - Original Draft Preparation, Writing - Review & Editing.
- VFPF** Analysis and/or data interpretation, Conception and design study, Data Curation, Final manuscript approval, Project Administration, Supervision, Visualization, Writing - Original Draft Preparation, Writing - Review & Editing.
- CALA** Conception and design study, Final manuscript approval, Investigation, Project Administration, Supervision, Visualization, Writing - Original Draft Preparation, Writing - Review & Editing.
- FFB** Final manuscript approval, Supervision.
- RG** Final manuscript approval, Supervision.

## REFERENCES

1. Shanahan RE, Gingrass RP. Medial Plantar Sensory Flap for Coverage of Heel Defects. *Plast Reconstr Surg.* 1979;64(3):295-8. DOI: 10.1097/00006534-197909000-00001
2. Reiffel RS, McCarthy JG. Coverage of Heel and Sole Defects. *Plast Reconstr Surg.* 1980;66(2):250-60. DOI: 10.1097/00006534-198008000-00014
3. Cichowitz A, Pan WR, Ashton M. The heel: anatomy, blood supply, and the pathophysiology of pressure ulcers. *Ann Plast Surg.* 2009;62(4):423-9. DOI: 10.1097/sap.0b013e3181851b55
4. Liette MD, Ellabban MA, Rodriguez P, Bibbo C, Masadeh S. Medial Plantar Artery Flap for Wound Coverage of the Weight-Bearing Surface of the Heel. *Clin Podiatr Med Surg.* 2020;37(4):751-64. DOI:10.1016/j.cpm.2020.06.002
5. Wan DC, Gabbay J, Levi B, Boyd JB, Granzow JW. Quality of innervation in sensate medial plantar flaps for heel reconstruction. *Plast Reconstr Surg.* 2011;127(2):723-30.
6. Jahss MH, Michelson JD, Desai P, Kaye R, Kummer F, Buschman W, et al. Investigations into the fat pads of the sole of the foot: anatomy and histology. *Foot Ankle.* 1992;13(5):233-42. DOI: 10.1177/107110079201300502
7. Jørgensen U, Bojsen-Møller F. Shock absorbency of factors in the shoe/heel interaction--with special focus on role of the heel pad. *Foot Ankle.* 1989;9(6):294-9. DOI: 10.1177/107110078900900607
8. Mourougayan V. Medial plantar artery (instep flap) flap. *Ann Plast Surg.* 2006;56(2):160-3. DOI: 10.1097/01.sap.0000190830.71132.b8
9. Harrison DH, Morgan BD. The instep island flap to resurface plantar defects. *Br J Plast Surg.* 1981;34(3):315-8.
10. Harttrampf CR Jr, Schefflan M, Bostwick J 3rd. The flexor digitorum brevis muscle island pedicle flap: a new dimension in

- heel reconstruction. *Plast Reconstr Surg*. 1980;66(2):264-70. DOI: 10.1097/00006534-198008000-00016
11. Baker GL, Newton ED, Franklin JD. Fasciocutaneous island flap based on the medial plantar artery: clinical applications for leg, ankle, and forefoot. *Plast Reconstr Surg*. 1990;85(1):47-58. DOI: 10.1097/00006534-199001000-00009
  12. Colen LB, Buncke HJ. Neurovascular island flaps from the plantar vessels and nerves for foot reconstruction. *Ann Plast Surg*. 1984;12(4):327-32. DOI: 10.1097/0000637-198404000-00004
  13. Colen LB, Replogle SL, Mathes SJ. The V-Y plantar flap for reconstruction of the forefoot. *Plast Reconstr Surg*. 1988;81(2):220-8. DOI: 10.1097/00006534-198802000-00014
  14. Morrison WA, Crabb DM, O'Brien BM, Jenkins A. The instep of the foot as a fasciocutaneous island and as a free flap for heel defects. *Plast Reconstr Surg*. 1983;72(1):56-63. DOI: 10.1097/00006534-198307000-00013
  15. El-Shazly M, Yassin O, Kamal A, Makboul M, Gherardini G. Soft tissue defects of the heel: a surgical reconstruction algorithm based on a retrospective cohort study. *J Foot Ankle Surg*. 2008;47(2):145-52. DOI: 10.1053/j.jfas.2007.12.010
  16. Macedo JLS, Rosa SC, Rezende Filho Neto AV, Silva AA, Amorim ACS. Reconstrução de lesões de partes moles de pé com o uso de retalho plantar medial. *Rev Bras Ortop (Sao Paulo)*. 2017;52(6):699-704. DOI: 10.1016/j.rbo.2016.10.009
  17. Opoku-Agyeman JL, Allen A, Humenansky K. The Use of Local Medial Plantar Artery Flap for Heel Reconstruction: A Systematic Review. *Cureus*. 2020;12(8):e9880. DOI: 10.7759/cureus.9880
  18. Woo SJ, Kang J, Hu JL, Kwon ST, Chang H, Kim BJ. Medial Plantar Fasciocutaneous Flap Reconstruction for Load-Bearing Foot Defects in Patients With Acral Melanoma. *Ann Plast Surg*. 2022;88(6):658-64.
  19. Wang M, Xu Y, Wang J, Cui L, Wang J, Hu XB, et al. Surgical Management of Plantar Melanoma: A Retrospective Study in One Center. *J Foot Ankle Surg*. 2018;57(4):689-93. DOI: 10.1053/j.jfas.2017.12.004
  20. Schwarz RJ, Negrini JF. Medial plantar artery island flap for heel reconstruction. *Ann Plast Surg*. 2006;57(6):658-61. DOI: 10.1097/01.sap.0000235426.53175.e3
  21. Khan FH, Beg MSA, Obaid-Ur-Rahman. Medial Plantar Artery Perforator Flap: Experience with Soft-tissue Coverage of Heel. *Plast Reconstr Surg Glob Open*. 2018;6(12):e1991. DOI: 10.1097/GOX.0000000000001991

---

**\*Corresponding author:****Giulia Godoy Takahashi**

Rua Arruda Alvim, 423, apto 51, Pinheiros, São Paulo, SP, Brazil

Zip Code: 05410-020

E-mail: giu.godoy@gmail.com