

Pathologies of *Oligacanthorhynchus pardalis* (Acanthocephala, Oligacanthorhynchidae) in *Leopardus tigrinus* (Carnivora, Felidae) in Southern Brazil

Patologias de *Oligacanthorhynchus pardalis* (Acanthocephala, Oligacanthorhynchidae) em *Leopardus tigrinus* (Carnivora, Felidae) no sul do Brasil

Moisés Gallas^{1*}; Eliane Fraga da Silvera¹

¹Departamento de Biologia, Museu de Ciências Naturais, Universidade Luterana do Brasil – ULBRA, Canoas, RS, Brasil

Received September 9, 2011

Accepted November 23, 2011

Abstract

In Brazil, *Oligacanthorhynchus pardalis* (Westrumb, 1821) Schmidt, 1972 has been observed in five species of wild felines. In the present study, five roadkilled oncillas (*Leopardus tigrinus* Schreber, 1775) were collected in the State of Rio Grande do Sul, Brazil. Chronic lesions caused by *O. pardalis* were observed in the small intestine of one of the specimens. Histological examination identified a well-defined leukocyte infiltration and an area of collagenous fibrosis. Only males parasites (n = 5) were found, with a prevalence of 20%. The life cycle of *Oligacanthorhynchus* species is poorly known, although arthropods may be their intermediate hosts. The low prevalence encountered may be related to the small number of hosts examined, and the reduced ingestion of arthropods infected by larvae of *O. pardalis*. This is the first report of *O. pardalis* parasitizing *L. tigrinus* in the Brazilian state of Rio Grande do Sul.

Keywords: Oncilla, *Oligacanthorhynchus*, lesions, Neotropical Region.

Resumo

Para o Brasil, *Oligacanthorhynchus pardalis* (Westrumb, 1821) Schmidt, 1972 foi registrada em cinco espécies de felídeos silvestres. No presente estudo, cinco gatos-do-mato-pequenos (*Leopardus tigrinus* Schreber, 1775), vítimas de atropelamento, foram coletados no Estado do Rio Grande do Sul, Brasil. Lesões crônicas causadas por *O. pardalis* foram observadas no intestino delgado de um dos espécimes. Cortes histológicos permitiram a identificação de um infiltrado leucocitário bem definido e uma área de fibrose do colágeno. Somente machos (n = 5) de *O. pardalis* foram encontrados, com prevalência de 20%. O ciclo biológico das espécies de *Oligacanthorhynchus* é pouco conhecido, no entanto, artrópodes foram considerados como hospedeiros intermediários. A baixa prevalência encontrada pode estar relacionada ao número de hospedeiros examinados, bem como, com a ingestão de poucos artrópodes infectados por larvas de *O. pardalis*. Este é o primeiro registro de *O. pardalis* parasitando *L. tigrinus* para o Rio Grande do Sul, Brasil.

Palavras-chave: Gato-do-mato-pequeno, *Oligacanthorhynchus*, lesões, Região Neotropical.

Introduction

Westrumb (1821) reviewed the species of the genus *Echinorhynchus* Zoega in Müller, 1776, and described the species *Echinorhynchus pardalis*, which was found parasitizing the intestine of *Felis pardalis* (= *Leopardus pardalis* Linnaeus, 1758). However, this author considered the species to be 'species dubiae'. Travassos (1917) considered *E. pardalis* to be the type species of the genus *Pardalis*, but subsequently (1918) transferred it to the genus *Echinopardalis*. Schmidt (1972) proposed a new classification, and considered the genus *Echinopardalis* to be a synonym of

Oligacanthorhynchus Travassos, 1915. According to this, *Ec. pardalis* was assigned to the genus *Oligacanthorhynchus*, an arrangement supported by Amin (1985).

Travassos (1917) provided morphometric measurements on *P. pardalis* collected from different species of felines in southern and southeastern Brazil: *Felis (Uncia) concolor* (= *Puma concolor* Linnaeus, 1771), *Felis (Leopardus) onça* (= *Panthera onca* Linnaeus, 1758), *Felis (Onçoides) tigrina* (= *Leopardus tigrinus* Schreber, 1775), *Felis (Onçoides) geoffroyi* (= *Leopardus geoffroyi* d'Orbigny & Gervais, 1844), *Felis (Zibethailurus) chibigonzon* (= *L. pardalis*), *Felis (Leopardus) pardus* (= *L. pardalis*) and *Felis (Onçoides) mitis* (= *L. pardalis*).

The oncilla (*L. tigrinus*), an endangered feline, occurs in all Brazilian biomes (SUNQUIST; SUNQUIST, 2002). The helminth

*Corresponding author: Moisés Gallas

Departamento de Biologia, Museu de Ciências Naturais, Universidade Luterana do Brasil – ULBRA, Av. Farrroupilha, 8001, São Luís, CEP 92425-900, Canoas, RS, Brasil

e-mail: mgallas24@yahoo.com.br

fauna of this species is poorly known, although six parasite species (one cestode, three nematodes and two acanthocephalans) have been identified (DIESING, 1851 apud BELDOMENICO et al., 2005; TRAVASSOS, 1917; PETROCHENKO, 1971; HUNGRIA, 1978; SANTOS et al., 2009; GALLAS; SILVEIRA, 2011). The acanthocephalan species *Oncicola campanulata* (Diesing, 1851) Meyer, 1931, and *O. pardalis* were considered to be parasites of *Felis tigrina* (= *L. tigrinus*) by Petrochenko (1971).

Vieira et al. (2008) published a list of the helminth species of Brazilian carnivores. Muniz-Pereira et al. (2009) provided data on the parasites of endangered Brazilian vertebrates, but because they did not include the species reported by Petrochenko (1971), they reported only *Trichuris* sp. as a parasite of *L. tigrinus*.

Acanthocephalan species cause damage to their hosts in the area where the proboscis is attached, which may cause formation of nodules, granulomas and inflammations, and may predispose towards secondary infections (NICKOL, 1985; RICHARDSON; BARNAWELL, 1995; KENNEDY, 2006). Babero (1957) and Richardson and Barnawell (1995) described the lesions caused by *Oligacanthorhynchus tortuosa* (Leidy, 1850) Schmidt, 1972 in opossums in the United States, but no data are available on the lesions caused by other *Oligacanthorhynchus* species.

This study characterizes the lesions caused by *O. pardalis* through histological sections from a specimen of *L. tigrinus* obtained in the Brazilian state of Rio Grande do Sul.

Materials and Methods

Between 2008 and 2010, five roadkilled adult specimens of *L. tigrinus* were collected from highways in the Brazilian state of Rio Grande do Sul. These specimens were donated to the "Laboratório de Zoologia dos Invertebrados" at "Museu de Ciências Naturais da ULBRA", MCNU, for necropsy. The acanthocephalans encountered were processed according to the techniques described by Amato and Amato (2010). Ecological terms were utilized according to Bush et al. (1997). Morphometric measurements are presented as means with ranges and standard deviations and the number of specimens measured (n) is given in parentheses. All measurements are given in micrometers, unless otherwise indicated.

Drawings were made with a drawing tube on a microscope. For histological processing, the sample was dehydrated in a graded series of xylene/ethanol before being embedded in a paraffin block. Histological sections of thickness 5 µm were stained according to the method of Luna (1968). The parasite species was identified according to the classification of Amin (1985) and the host species, based on Wozencraft (2005). A representative specimen was deposited in the "Coleção Helmintológica do Instituto Oswaldo Cruz", CHIOC, Rio de Janeiro, Brazil.

Results

Oligacanthorhynchus pardalis (Westrumb, 1821) Schmidt, 1972

Description based on 5 males. Acanthocephala, Archiacanthocephala, Oligacanthorhynchidae. Body 21-27 mm (23.67; ± 3.05; n = 3) long; 1.68-2.48 mm (2.09; ± 0.29; n = 5)

wide at testes level (Figures 1a, b and 2a). Proboscis 414-667 (559.67; ± 130.78; n = 3) long; 506-621 (575; ± 60.85; n = 3) wide with six rows of hooks (Figures 1a, b and 2a). The hooks are truncated at their tip and the last two rows of hooks lacks the anterior extension (Figure 1a). Hooks of first row measures 221.28-239.72 (230.5; ± 9.22; n = 5) in length, and 92.2-156.74 (125.39; ± 24.04; n = 5) in root; hooks of second row measures 221.28-267.38 (237.88; ± 18.9; n = 5) in length, and 119.86-156.74 (136.46; ± 13.68; n = 5) in root; hooks of third row measures 221.28-239.72 (228.66; ± 7.71; n = 5) in length, and 110.64-156.74 (125.39; ± 19.12; n = 5) in root; hooks of fourth row measures 156.74-202.84 (193.62; ± 20.62; n = 5) in length, and 73.76-92.2 (79.29; ± 8.25; n = 5) in root; hooks of fifth row measures 119.86-129.08 (125.39; ± 5.05; n = 5) in length, and 55.32-92.2 (66.38; ± 16.49; n = 5) in root; hooks of sixth row measures 82.98-101.42 (94.04; ± 7.71; n = 5) in length, and 46.1-92.2 (70.07; ± 21.23; n = 5) in root (Figure 1a). Proboscis receptacle 736-1219 (912.33; ± 266.57; n = 3) long; 414-483 (437; ± 39.83; n = 3) wide (Figure 1b). Small neck and trunk without spines (Figure 1b). Lemnisci 10.95-11.54 mm (11.29; ± 0.30; n = 3) long, representing 47.7% of total body length (TBL) (Figure 1b). Testes elongated, near middle of body, anterior testis 2.3-3.35 mm (2.65; ± 0.42; n = 5) long, 0.60-1.21 mm (0.86; ± 0.22; n = 5) wide; posterior testis 2.18-3.33 mm (2.71; ± 0.44; n = 5) long, 0.80-1.15 mm (0.91; ± 0.14; n = 5) wide (Figure 1b). Distance between the testes 92-575 (262.2; ± 197.58; n = 5). There are four pairs of cement glands 4.14-7.82 mm (5.48; ± 1.73; n = 4) long (Figure 1b). Saeftigen's pouch 2.81-4.05 (3.31; ± 0.52; n = 5) long (Figure 1b). Copulatory bursa 2.78-4.14 (3.27; ± 0.62; n = 4) long, 0.94-1.40 (1.07; ± 0.21; n = 4) wide (Figure 1b).

1. Taxonomic summary

Synonyms: *Echinorhynchus pardalis* Westrumb, 1821; *Pardalis pardalis* (Westrumb, 1821) Travassos, 1917; *Echinopardalis pardalis* (Westrumb, 1821) Travassos, 1918.

Host: *Leopardus tigrinus* Schreber, 1775.

Site of infection: small intestine.

Locality: Dom Pedro de Alcântara, RS, Brazil.

Prevalence: 20%.

Mean intensity of infection: 5 helminths/host.

Mean abundance of infection: 1 helminth/host.

Voucher specimen deposited: CHIOC Nº: 37807.

All five *O. pardalis* specimens were males. The measurements were similar to those reported by Travassos (1917), except for the width of the body, testes and cement glands, for which higher values were recorded in the present study.

One specimen was fixed *in situ* in the intestine, with free trunk and lesions of diameter 1 mm (n = 7), representing the proboscis attachments (Figure 2a). Macroscopic alterations of the serous layer consisting of nodules of 3.5 to 6.0 mm in diameter and 2 to 4 mm in height, corresponded to the sites at which the proboscis was attached to the lumen (Figure 2b).

Microscopic alterations were observed in the mucosa, submucosa, and muscularis layers, which were affected by the proboscis attachment. The analysis identified a leukocytic infiltration

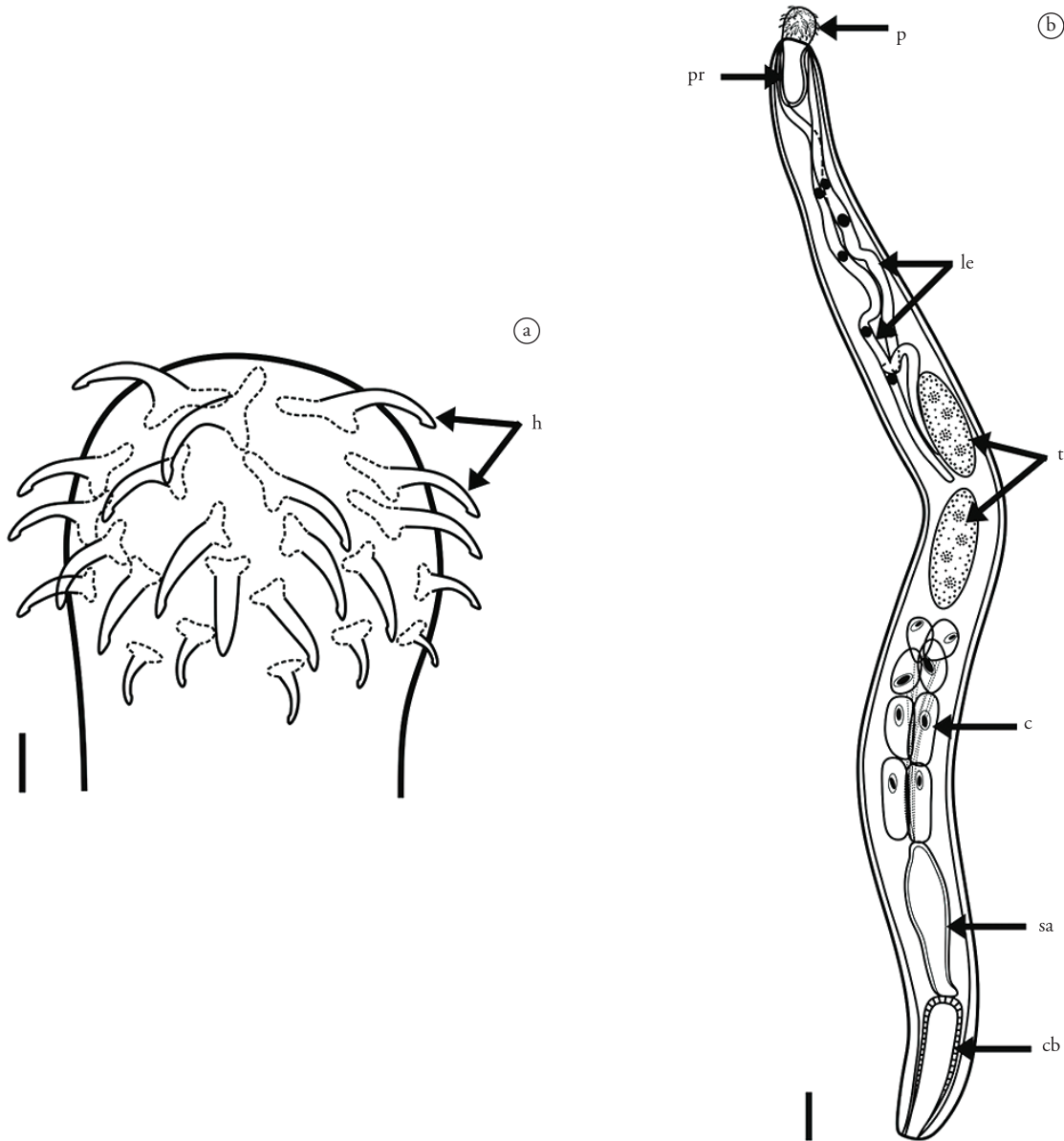


Figure 1. Incomplete diagrams of *Oligacanthorhynchus pardalis*: a) Proboscis with hooks (h), Scale bar = 100 μm; b) Total body with proboscis (p), proboscis receptacle (pr), lemnisci (le), testes (t), cement glands (c), Saefftinger's pouch (sa) and copulatory bursa (cb). Scale bar = 1 mm.

between the submucosa and muscularis layers (Figure 2c). The area adjacent to this infiltration was characterized by coarse, fibrous collagen in a disorderly arrangement, with abundance of fibroblasts and fibrocytes (Figure 2d).

Discussion

In acanthocephalans, the sex ratio (1:1) is determined at fertilization (CROMPTON, 1985). Exclusive occurrence of male specimens may provoke competition among the *O. pardalis* males, thus resulting in changes to body and testis size (SASAL et al., 2000).

The lesions found in the present study are closely similar, in terms of nodule length and damage to the tissue layers, to those reported for *O. tortuosa* (BABERO, 1957; RICHARDSON;

BARNAWELL, 1995). Babero (1957) observed red nodules, which Richardson and Barnawell (1995) interpreted as the result from hemorrhaging caused by the attachment of the parasite. Absence of hemorrhaging and absence of polymorphonuclear leukocytes (PMN) are indicative of the chronic inflammation induced by *O. pardalis*, as reported in relation to *O. tortuosa* by Richardson and Barnawell (1995).

The advanced state of putrefaction of the oncilla specimen impeded a more detailed analysis of the lesions. In particular, atrophic processes and necrotic abscesses, as reported by Babero (1957) and Richardson and Barnawell (1995), were not observed. The extensive fibrosis associated with leukocytic infiltration indicates that the parasites do not migrate after attachment (RICHARDSON; BARNAWELL, 1995). In the present study,

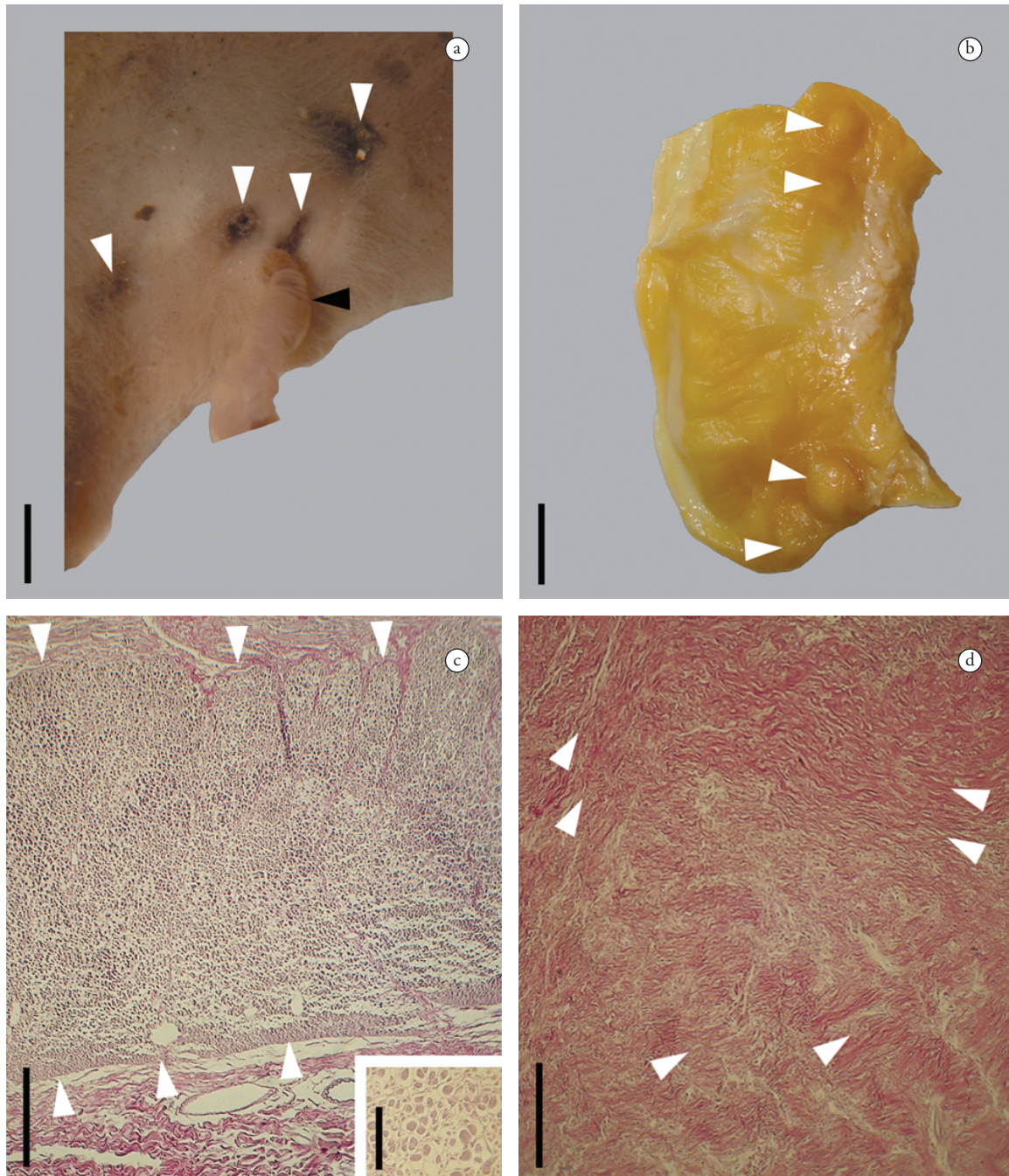


Figure 2. Photomicrographs of the lesions caused by *Oligacanthorhynchus pardalis*: a) Lumen layer showing one specimen attached (black arrowhead) and lesions (white arrowheads), Scale bar = 2 mm; b) Serous layer showing nodules (white arrowheads), Scale bar = 9 mm; c) Histological section showing the well-defined leukocyte infiltration (white arrowheads), Scale bar = 150 μ m, and inset showing detail of the lymphocytes in the leukocyte infiltration, Scale bar = 60 μ m; d) Fibrosis showing disorderly fibrous tissue (white arrowheads), Scale bar = 200 μ m.

the presence of fibrosis indicates that the acanthocephalans did not migrate after attachment of their proboscises to the lumen of *L. tigrinus*. However, the number of lesions ($n = 7$), together with the number of *O. pardalis* specimens encountered ($n = 5$) also indicates that some specimens migrated before definitive attachment and formation of the fibrosis.

The first study on the life cycle of an *Oligacanthorhynchus* species was conducted by Richardson (2006). The diplopod *Narceus americanus* Palisot de Beauvois, 1817, has been identified

as an intermediate host of *O. tortuosa*. Ingestion of rodents, lizards, birds, and arthropods by *L. tigrinus* has been documented by Sunquist and Sunquist (2002). The low infection rates found in the present study may be related to the small number of hosts analyzed and the low ingestion of arthropods infected with the larvae of *O. pardalis*.

Vieira et al. (2008) recorded *O. pardalis* as a parasite of only four feline species, *L. pardalis*, *L. geoffroyi*, *P. onca*, and *Pu. concolor*. However, their study overlooked Travassos (1917), who identified

L. tigrinus from São Paulo, Brazil, as a definitive host of *O. pardalis*. The present study is the first record of *O. pardalis* parasitizing *L. tigrinus* in the Brazilian state of Rio Grande do Sul.

Acknowledgements

We are grateful to PROICT/ULBRA for the scholarship granted to the first author; to the biologist Felipe B. Peters (ULBRA) and Professor Eduardo Eizirik (PUCRS) for the donation of the specimens of *L. tigrinus*; Clarence and Rose (Laboratório de Histologia, ULBRA) for their help with histological procedures; Professor Lígia R. Ponts (ULBRA) for her assistance with characterization of the histological sections; Professor Dennis J. Richardson (Quinnipiac University) for his help with the bibliography; and Stephen Ferrari for revision of the English text.

References

- Amato JFR, Amato SB. Técnicas gerais para coleta e preparação de helmintos endoparasitos de aves. In: Von Matter S, Straube FC, Accordi IA, Piacentini VQ, Cândido-Junior JF, organizadores. *Ornitologia e Conservação: Ciência Aplicada, Técnicas de Pesquisa e Levantamento*. Rio de Janeiro: Technical Books; 2010. p. 369-393.
- Amin OM. Classification. In: Crompton DWT, Nickol BB, editors. *Biology of the Acanthocephala*. Cambridge: Cambridge University Press; 1985. p. 27-72.
- Babero BB. Some helminths from Illinois opossums. *J Parasitol* 1957; 43(2): 232. <http://dx.doi.org/10.2307/3274655>
- Beldomenico PM, Kinsella JM, Uhart MM, Gutierrez GL, Pereira J, Ferreyra HV. Helminths of Geoffroy's cat, *Oncifelis geoffroyi* (Carnivora, Felidae) from the Monte desert, central Argentina. *Acta Parasitol* 2005; 50(3): 263-266.
- Bush AO, Lafferty KD, Lotz JM, Shostak AW. Parasitology meets ecology on its own terms: Margolis et al. revisited. *J Parasitol* 1997; 83(4): 575-583. PMID:9267395. <http://dx.doi.org/10.2307/3284227>
- Crompton DWT. Reproduction. In: Crompton DWT, Nickol BB, editors. *Biology of the Acanthocephala*. Cambridge: Cambridge University Press; 1985. p. 213-271.
- Gallas M, Silveira EF. *Mesocestoides* sp. (Eucestoda, Mesocestoididae) parasitizing four species of wild felines in Southern Brazil. *Rev Bras Parasitol Vet* 2011; 20(2): 168-170. <http://dx.doi.org/10.1590/S1984-29612011000200014>
- Hungria CD. Helmintos parásitos de vertebrados en el estado Zulia (Venezuela) algunas especies nuevas para Venezuela. *Vet Trop* 1978; 3: 15-37.
- Kennedy CR. *Ecology of the Acanthocephala*. Cambridge: Cambridge University Press; 2006. 249 p. <http://dx.doi.org/10.1017/CBO9780511541902>
- Luna LG. *Manual of Histologic Staining Methods of the Armed Forces Institute of Pathology*. New York: McGraw-Hill; 1968. 258 p.
- Muniz-Pereira LC, Vieira FM, Luque JL. Checklist of helminth parasites of threatened vertebrate species from Brazil. *Zootaxa* 2009; 2123: 1-45.
- Nickol BB. Epizootiology. In: Crompton DWT, Nickol BB, editors. *Biology of the Acanthocephala*. Cambridge: Cambridge University Press; 1985. p. 307-346.
- Petrochenko VI. *Acanthocephala of domestic and wild animals*. Jerusalém: Israel Program for Scientific Translations; 1971. v. 2, 478 p.
- Richardson DJ, Barnawell EB. Histopathology of *Oligacanthorhynchus tortuosa* (Oligacanthorhynchidae) Infection in the Virginia Opossum (*Didelphis virginiana*). *J Helminthol Soc Wash* 1995; 62(2): 253-256.
- Richardson DJ. Life Cycle of *Oligacanthorhynchus tortuosa* (Oligacanthorhynchidae), an Acanthocephalan of the Virginia Opossum (*Didelphis virginiana*). *Comparative Parasitol* 2006; 73(1): 1-6. <http://dx.doi.org/10.1654/4207.1>
- Santos KR, Faciulli P, Papatotto T, Takahira RK, Lopes RS, Silva RJ. First report of *Strongyloides* sp. (Nematoda, Strongyloididae) in *Leopardus tigrinus* (Carnivora: Felidae) in the municipality of Botucatu, State of São Paulo, Brazil. *Rev Bras Parasitol Vet* 2009; 18(S1): 77-79. <http://dx.doi.org/10.4322/rbpv.018e1016>
- Sasal P, Jobet E, Faliex E, Morand S. Sexual competition in an acanthocephalan parasite of fish. *Parasitology* 2000; 120: 68-69. <http://dx.doi.org/10.1017/S0031182099005272>
- Schmidt GD. Revision of the class Archiacanthocephala Meyer, 1931 (Phylum Acanthocephala), with emphasis on Oligacanthorhynchidae Southwell et Macfie, 1925. *J Parasitol* 1972; 58(2): 290-297. PMID:5022866. <http://dx.doi.org/10.2307/3278091>
- Sunquist ME, Sunquist F. *Wild cats of the world*. Chicago: The University of Chicago Press; 2002. 452 p.
- Travassos L. Contribuições para o conhecimento da fauna helmintológica brasileira. *Mem Inst Oswaldo Cruz* 1917; 9(1): 5-62. <http://dx.doi.org/10.1590/S0074-02761917000100001>
- Travassos L. Helminthes parasitos de animaes domésticos. I. *Rev Vet Zootec* 1918; 8: 3-15.
- Vieira FM, Luque JL, Muniz-Pereira LC. Checklist of helminth parasites in wild carnivore mammals from Brazil. *Zootaxa* 2008; 1721: 1-23.
- Westrumb AHL. *De Helminthibus acanthocephalis; commentatio historico-anatomica*. Hanoverae Helwing; 1821. 85 p. Adnexo recensu animalium, in Museo Vindobonensi circa helminthes dissectorum, et singularum speciocrum harum in illis repertarum. [cited 2010 Nov.]. Available from: <http://www.archive.org/details/dehelminthibusac00west>.
- Wozencraft WC. Order Carnivora. In: Wilson DE, Reeder DM, editors. *Mammal Species of the World: A Taxonomic and Geographic Reference*. Baltimore: Johns Hopkins University Press; 2005. p. 532-628.