


First report of myiasis caused by *Cochliomyia hominivorax* in free-ranging giant otter (*Pteronura brasiliensis*)

Primeiro relato de miíase causada por *Cochliomyia hominivorax* em ariranha (*Pteronura brasiliensis*) de vida livre

Nathalie Foerster^{1,2*} ; Grazielle Soresini²; Fernando Paiva³; Fabiano Aguiar da Silva¹; Caroline Leuchtenberger^{2,4}; Guilherme Mourão⁵

¹Programa de Pós-Graduação Em Ecologia e Conservação, Universidade Federal de Mato Grosso do Sul, Campo Grande, MS, Brasil

²Giant Otter Conservation Fund, Arroio do Meio, RS, Brasil

³Instituto de Biociências, Universidade Federal de Mato Grosso do Sul, Campo Grande, MS, Brasil

⁴Instituto Federal Farroupilha, Santa Maria, RS, Brasil

⁵Laboratório de Vida Selvagem, Embrapa Pantanal, Corumbá, MS, Brasil

How to cite: Foerster N, Soresini G, Paiva F, Silva FA, Leuchtenberger C, Mourão G. First report of myiasis caused by *Cochliomyia hominivorax* in free-ranging giant otter (*Pteronura brasiliensis*). *Braz J Vet Parasitol* 2022; 31(4): e009522. <https://doi.org/10.1590/S1984-29612022058>

Abstract

Giant otters are territorial semi-aquatic mammals. It is common to find several individuals exhibiting wounds and scars due to intraspecific conflicts. Myiasis is a parasitic infestation on living tissues of vertebrates caused by dipterous larvae, that usually develops in freshly open wounds and can seriously threaten the host's health. Ectoparasites seem to be rare among giant otters and myiasis had not been recorded in this species until now. Here, is presented one record of myiasis in a free-ranging giant otter found dead in the Pantanal, Brazil. An ulcerative lesion was found in the frontoparietal region, from which 22 larvae were recovered and identified as *Cochliomyia hominivorax*. The low occurrence of ectoparasites in giant otters might reflect their semi-aquatic habits and their grooming behavior, which makes it difficult for parasites to remain on the skin. The injured otter probably got the larvae after an intraspecific fight. Agonistic encounters between groups of giant otters have been reported before and these fights can result in serious wounds or even death. It was hypothesized that the myiasis caused by *C. hominivorax* deteriorated the health of the infested giant otter, which prevented recovery and accelerated its death.

Keywords: Mustelid, ectoparasite, Lutrinae, Pantanal, neotropical wetland.


Resumo

As ariranhas são mamíferos semiaquáticos habitantes do território brasileiro. É comum encontrar vários indivíduos apresentando feridas e cicatrizes devido a conflitos intraespecíficos. A miíase é uma infestação parasitária em tecidos vivos de vertebrados, causada por larvas de dípteros que, geralmente, se desenvolvem em feridas recém-abertas, podendo ameaçar seriamente a saúde do hospedeiro. Ectoparasitos parecem ser raros em ariranhas e, até o presente, não há relatos de miíase nesta espécie. Aqui, é apresentado um registro de miíase em uma ariranha de vida livre, encontrada morta no Pantanal, Brasil. Foi encontrada uma lesão ulcerativa na região frontoparietal, na qual foram recuperadas 22 larvas identificadas como *Cochliomyia hominivorax*. A baixa ocorrência de ectoparasitos em ariranhas pode refletir seus hábitos semiaquáticos e seu comportamento de limpeza, o que dificulta a permanência dos parasitos na pele. A ariranha ferida, provavelmente, se infestou com as larvas após uma briga intraespecífica. Encontros agonísticos entre grupos de ariranhas já foram relatados antes, e essas lutas podem resultar em ferimentos graves ou até mesmo em morte. Foi hipotetizado que a miíase causada por *C. hominivorax* deteriorou a saúde da ariranha infestada, o que impediu a recuperação e acelerou sua morte.

Palavras-chave: Mustelídeo, ectoparasito, Lutríneos, Pantanal, áreas úmidas neotropicais.

Received July 7, 2022. Accepted October 26, 2022.

*Corresponding author: Nathalie Foerster. E-mail nathalie.foerster@gmail.com.



This is an Open Access article distributed under the terms of the Creative Commons Attribution License, which permits unrestricted use, distribution, and reproduction in any medium, provided the original work is properly cited.

Introduction

Giant otters (*Pteronura brasiliensis*) are semi-aquatic mammals and the largest members of the family Mustelidae. They are social and territorial. Giant otters scent-mark and vocalize a wide repertoire to mark their territories and to avoid agonistic encounters with other groups (Leuchtenberger & Mourão, 2009). However, during the dry season their territories shrink, and the conflicts tend to increase (Ribas & Mourão, 2004; Leuchtenberger & Mourão, 2009), and it is common to find several individuals exhibiting wounds and scars (Rosas & Mattos, 2003).

Myiasis is a parasitic infestation on living or necrotic tissues of vertebrates caused by dipterous larvae (Hope, 1837; Zumpt, 1965). Myiasis can involve heavy infestation of freshly open wounds causing swelling, inflammation, pain, and thus seriously threat the host's health (Hall, 1997; Yan et al., 2019). The North American river otter (*Lontra canadensis*) is susceptible to myiasis (Kimber & Kollias, 2000). However, it was unknown if the giant otter was susceptible to myiasis.

There are a few records of myiasis in free-ranging mammals in Brazil, including in maned wolf (*Chrysocyon brachyurus*) (Cansi et al., 2011), porcupine (*Coendou prehensilis*) (Lacey & George, 1981), opossum (*Didelphis marsupialis*) (Reis et al., 2008) and gracile mouse opossum (*Gracilinanus* sp.) (Reis et al., 2008). Recently, May-Júnior et al. (2021) captured 13 jaguars in the Pantanal presenting subcutaneous nodules due to parasitism by *Dermatobia hominis* larvae. In some of these jaguars, myiasis caused by *Cochliomyia hominivorax* was also found. In mustelids, only two records of myiasis infestation have been reported in Brazil. One occurred in a captive lesser grison (*Galictis cuja*) (Figueiredo et al., 2010), and the other in a neotropical otter (*Lontra longicaudis*) that was rescued exhibiting health problems on the banks of a lake in southern Brazil (Michelazzo et al., 2022). A report of myiasis in the North American river otter resulted in death three days after it was captured due to extensive damage caused by the dipteran larvae, which were not specifically identified (Serfass et al., 1993).

Here, is presented one record of myiasis caused by the larval stage of *Cochliomyia hominivorax*, in a free-ranging giant otter in the Pantanal, a large wetland located near the center of South America. To the author's knowledge, this is the first report of myiasis in giant otters.

Methods

On the morning of September 4, 2021, a dead giant otter was found floating at the side of the Miranda River (19° 31' 13.95" S 57° 7' 12.96" W), in the state of Mato Grosso do Sul, Brazil. The animal was near the entrance of a former den. The carcass was collected and taken straight to a field lab (license SISBIO/ICMBio 79173-1). Judging from the fresh condition of the carcass, the time of death was estimated as only a few hours before the animal was found.

It was a young male, in poor body condition, measuring 116 cm in total length and weighing 18.77 kg. This individual had several injuries along its body, most of them probably due to bites and other wounds from a possible fight (Figure 1A and 1B). At the necropsy, it was observed that the animal no longer had any fat tissue remaining and the internal organs had normal macroscopic appearance. In a skin lesion measuring 8.5 x 6 cm, in the frontoparietal region with many cavitations on the edges, dipteran larvae were found. All the larvae were collected and stored in 70° GL ethyl alcohol for subsequent identification.

The larvae were cleaned with the aid of a brush and then were examined for their taxonomic characteristics by means of light microscopy, under a Leica M205 C™ stereomicroscope or a Leica DM5500 B™ microscope, both equipped with Leica cameras, models DFC 420 and 490, respectively (Leica Microsystems™, Wetzlar and Mannheim, Germany). Images were registered in the Leica Application Suite image analysis system (LAS™ 3.8; Leica Microsystems™, Wetzlar and Mannheim, Germany). Two specimens were randomly selected and passed through a clarification process, using a solution of potassium hydroxide (KOH) (10% w/v) (Zumpt, 1965), and were placed in an oven at 46°C until translucent (approximately five hours). The specimens were dehydrated in a progressive ethyl alcohol series, from 70 to 99° GL, at one-hour intervals between each dilution (70, 80, 90 and 99° GL). Then they were immersed in hexamethyldisilazane (cat. number 440191; Sigma-Aldrich™) for 10 minutes, followed by deposition onto carbon conductive tabs (12 mm OD, Pelco Tabs™; Ted Pella®, Inc., USA) attached to Pelco® Q pin stubs of dimensions 12.7 x 12.7 mm (Ted Pella®, Inc., USA). The images were documented using a Hitachi® model TM3000™ scanning electron microscope (Hitachi, Tokyo, Japan) in the analysis mode. The specimens were deposited in the Zoological Reference Collection of the Federal University of Mato Grosso do Sul (ZUFMS-DIP01276).

The taxonomic characteristics considered were those previously described by Laake et al. (1936), Knipling (1939), James (1947), Zumpt (1965) and Shewell (1981).

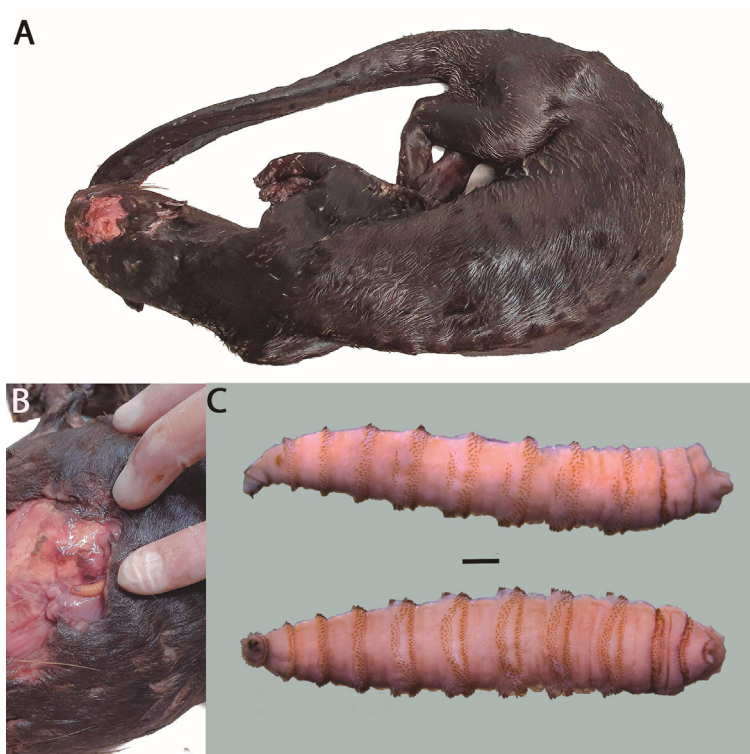


Figure 1. Carcass of a giant otter (*Pteronura brasiliensis*) found in the wild with myiasis lesion. A – General view of the animal; B – Details of the lesion, with third-instar larva; C – Third-instar larva of *Cochliomyia hominivorax* (Coquerel, 1858) recovered from skin; lateral view and ventral view (bar = 1 mm).

Results and Discussion

During the necropsy examination of the giant otter 22 live larvae were recovered. Macroscopically, the larvae were whitish, cylindrical, and tapered anteriorly, with 12 visible segments surrounded by band spines (Figure 1C). The lesion was characterized as typical primary ulcerative myiasis (Laake et al., 1936; Knipling, 1939; James, 1947).

All the larvae were in the third stage and were identified as *Cochliomyia hominivorax* (Coquerel, 1858). They showed the following characteristics: anterior portion armed with a pair of strong mouth hooks (Figure 2A and 2B); peritremes of posterior spiracle incomplete and not defined enclosing the button poorly; encircling three straight subparallel opening lined up diagonally (Figure 2C and 2D); cephalopharyngeal apparatus well developed and highly sclerotized, with conspicuous paired of mandibular hooks (Figure 3A and 3B); tracheal trunks lightly blackened, pigmented from the posterior spiracle (Figure 3C); dorsal region of the cornua not incised (Figure 3D); and anterior spiracle with short flattened stalk, with 10 nodular branches arranged fanwise (Figure 3E) (Knipling, 1939; James, 1947; Shewell, 1981). The length of the larvae ranged from 10 to 15 mm.

Cochliomyia hominivorax, commonly known as the New World screwworm (NWS), is a dipteran species of the family Calliphoridae. The NWS is one of the main causes of myiasis in livestock, wildlife, and humans in tropical and subtropical parts of the Americas where it has not been eradicated, including Brazil (Wyss, 2000; Zumpt, 1965). Gravid adult female *C. hominivorax* lay their eggs in open wounds on the host. Upon hatching, the fly larvae, or maggots, also known as screwworms, feed on living dermal or subdermal tissues of the parasitized host (Knipling, 1939).

Myiasis is very rare in aquatic vertebrates, with only a few records in fish (Bristow et al., 1990; Öktener & Alas, 2009; Zumpt, 1965). The low occurrence of ectoparasites in giant otters, especially dipterans, might reflect their semi-aquatic habits, but also their grooming and allogrooming behavior, which makes it difficult for parasites to remain on the skin.

The NSW cannot develop in carrion; it feeds only on living tissues. The time taken for the larvae to reach the third stage is 5 to 7 days (Hall, 1997). Thus, the otter probably acquired the NSW after being injured either by an accident or even intraspecific fights. Agonistic encounters between groups of giant otters have been reported before (Ribas & Mourão, 2004). These fights can result in serious wounds or even death (Rosas & Mattos, 2003; Leuchtenberger et al., 2015), even though many individuals can show rapid recovery from injuries in the wild

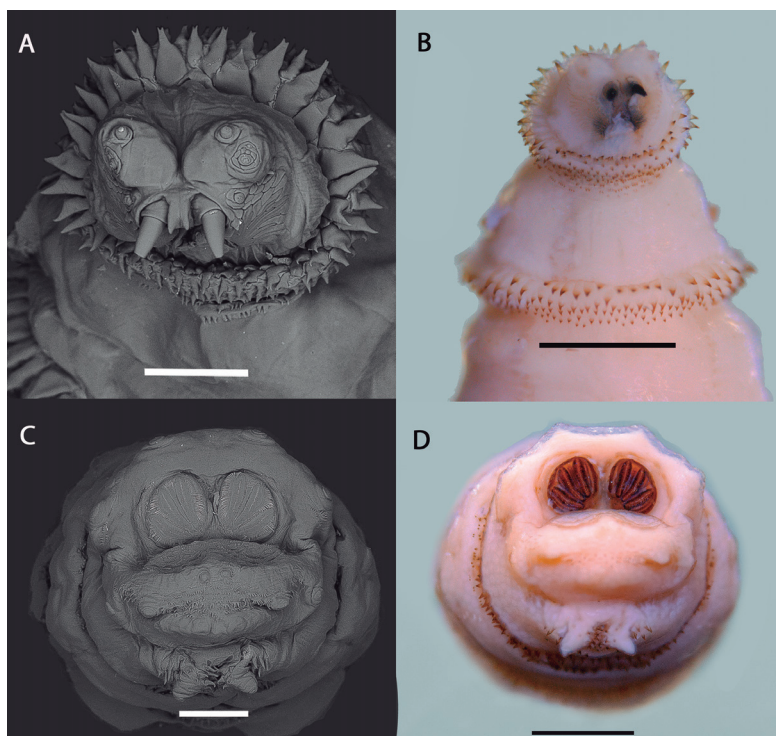


Figure 2. Third-instar larva of *Cochliomyia hominivorax* (Coquerel, 1858) recovered from skin lesion in giant otter (*Pteronura brasiliensis*) in the Pantanal, Brazil. A and B – Details of the anterior portion; C and D – View of the posterior portion. Scale bars: A and C = 250 µm; B and D = 1 mm.




Figure 3. Third-instar larva of *Cochliomyia hominivorax* (Coquerel, 1858) recovered from skin lesion in giant otter (*Pteronura brasiliensis*) in the Pantanal, Brazil. A, B and C – specimen cleared with 10% solution of potassium hydroxide (KOH) (bar = 1 mm); A – Anterior portion in lateral view; B – Anterior portion in ventral view; C – Posterior portion in ventral view, highlighting the pigmentation of the tracheal trunks. D – Diagrammatic drawing of cephalopharyngeal apparatus in the lateral view (bar = 200 µm); and E – Diagrammatic drawing of anterior spiracle (bar = 250 µm).

(Foerster, person. obs.). It was hypothesized that the myiasis caused by *C. hominivorax* deteriorated the health of the infested giant otter, which prevented recovery and accelerated its death.

The NSW is very important in economic terms where endemic, since it infests cattle and other livestock species (Vargans-Terán, 2020). In Brazil, the economic loss caused by NSW infestation on the livestock industry was estimated to be USD 380 million annually (Grisi et al., 2014). Although information regarding its impact on wildlife populations is scant, Vargas-Terán (1991) reported an 80% loss among fawns of the white-tailed deer (*Odocoileus virginianus*) in Texas, in the United States, due to NSW infestation.

The records of myiasis in endangered species such as jaguars (May-Junior, 2021), giant otters reported herein, and invasive vertebrate species like feral hogs (Altuna et al., 2021), demonstrate the importance of studies on the impact of these parasites on wildlife.

Acknowledgements

The authors are very grateful to all the employees of the Pantanal Study Base of the Federal University of Mato Grosso do Sul for the support during the field work and necropsy. The study was funded by Fundação de Ciência e Tecnologia do Estado de Mato Grosso do Sul (Fundect/CNPq grant PRONEX 006/2015) and by Houston Zoo. Coordenação de Aperfeiçoamento de Pessoal de Nível Superior (CAPES) provided a scholarship to NF (88887.311430/2018-00) and Conselho Nacional de Desenvolvimento Científico e Tecnológico (CNPq) awarded a productivity fellowship to GM (308934/2017-2).

Ethics declaration

The study was approved by the Biodiversity Authorization and Information System (SISBio) of the Environmental Institute (number 79173-1).

Conflict of interest

The authors declared no conflicts of interest.

References

- Altuna M, Hickner PV, Castro G, Mirazo S, Pérez de León AA, Arp AP. New World screwworm (*Cochliomyia hominivorax*) myiasis in feral swine of Uruguay: one Health and transboundary disease implications. *Parasit Vectors* 2021; 14(1): 26. <http://dx.doi.org/10.1186/s13071-020-04499-z>. PMID:33413607.
- Bristow GA, Berland B, Fosså SA. A first case of myiasis in fish. *J Parasitol* 1990; 76(2): 256-257. <http://dx.doi.org/10.2307/3283026>. PMID:2319427.
- Cansi ER, Bonorino R, Ataíde HS, Pujol-Luz JR. Myiasis by screw worm *Cochliomyia hominivorax* (Coquerel) (Diptera: Calliphoridae) in a wild maned wolf *Chrysocyon brachyurus* (Mammalia: Canidae), in Brasília, Brazil. *Neotrop Entomol* 2011; 40(1): 150-151. <http://dx.doi.org/10.1590/S1519-566X2011000100025>. PMID:21437499.
- Figueiredo MA, Santos ACG, Guerra RMSNC. Ectoparasitos de animais silvestres no Maranhão. *Pesq Vet Bras* 2010; 30(11): 988-990. <http://dx.doi.org/10.1590/S0100-736X2010001100013>.
- Grisi L, Leite RC, Martins JRS, Barros ATM, Andreotti R, Caçado PHD, et al. Reassessment of the potential economic impact of cattle parasites in Brazil. *Rev Bras Parasitol Vet* 2014; 23(2): 150-156. <http://dx.doi.org/10.1590/S1984-29612014042>. PMID:25054492.
- Hall MJR. Traumatic myiasis of sheep in Europe: a review. *Parassitologia* 1997; 39(4): 409-413. PMID:9802103.
- Hope FW. On insects and their larvae occasionally found in the human body. *Trans R Entomol Soc Lond* 1837; 2: 256-271.
- James MT. The flies that cause myiasis in man. *USDA Misc Pub* 1947; 631: 175. <http://dx.doi.org/10.5962/bhl.title.65688>.
- Kimber KR, Kollias GV 2nd. Infectious and parasitic diseases and contaminant-related problems of North American river otters (*Lontra canadensis*): a review. *J Zoo Wildl Med* 2000; 31(4): 452-472. [http://dx.doi.org/10.1638/1042-7260\(2000\)031\[0452:IAPDA C\]2.0.CO;2](http://dx.doi.org/10.1638/1042-7260(2000)031[0452:IAPDA C]2.0.CO;2). PMID:11428392.
- Knipling EF. A key for blowfly larvae concerned in wound and cutaneous myiasis. *Ann Entomol Soc Am* 1939; 32(2): 376-383. <http://dx.doi.org/10.1093/aesa/32.2.376>.

- Laake EW, Cushing EC, Parish HE. Biology of the primary screw worm fly, *Cochliomyia americana*, and a comparison of its stages with those of *C. macellaria*. *U S Dept Agr Tech Bui* 1936 [cited 2022 Oct 27]; 500: 24. Available from: <https://www.nal.usda.gov/exhibits/speccoll/items/show/7338>
- Lacey LA, George TK. Myiasis in an Amazonian porcupine. *Entomol News* 1981 [cited 2022 Oct 27]; 92(2): 79-80. Available from: <https://biostor.org/reference/77199>
- Leuchtenberger C, Magnusson WE, Mourão G. Territoriality of giant otter groups in an area with seasonal flooding. *PLoS One* 2015; 10(5): e0126073. <http://dx.doi.org/10.1371/journal.pone.0126073>. PMID:25955248.
- Leuchtenberger C, Mourão G. Scent-marking of giant otter in the southern Pantanal, Brazil. *Ethology* 2009; 115(3): 210-216. <http://dx.doi.org/10.1111/j.1439-0310.2008.01607.x>.
- May-Junior JA, Fagundes-Moreira R, Souza VB, Almeida BA, Haberfeld MB, Sartorelo LR, et al. Dermatobiosis in *Panthera onca*: first description and multinomial logistic regression to estimate and predict parasitism in captured wild animals. *Braz J Vet Parasitol* 2021; 30(1): e023820. <http://dx.doi.org/10.1590/s1984-29612021003>. PMID:33787735.
- Michelazzo M, Martinelli T, Amorim V, Silva L, Silva FH, Xavier A, et al. Canine distemper virus and canine adenovirus type-2 infections in neotropical otters (*Lontra longicaudis*) from southern Brazil. *Braz J Microbiol* 2022; 53(1): 369-375. <http://dx.doi.org/10.1007/s42770-021-00636-7>. PMID:34709597.
- Öktener A, Alaş A. Cases of external myiasis caused by Diptera (*Sarcophaga* sp.) on three cyprinid species. *Rev Fish Sci* 2009; 17(1): 68-69. <http://dx.doi.org/10.1080/10641260802178818>.
- Reis FS, Barros MC, Fraga EC, Penha TA, Teixeira WC, Santos ACG, et al. Ectoparasitos de pequenos mamíferos silvestres de áreas adjacentes ao rio Itapecuru e área de preservação ambiental do Inhamum, estado do Maranhão, Brasil. *Rev Bras Parasitol Vet* 2008; 17(Suppl 1): 69-74. PMID:20059819.
- Ribas C, Mourão G. Intraspecific agonism between giant otter groups. *IUCN Otter Spec Group Bull* 2004; 21(2): 89-93.
- Rosas FCW, Mattos GE. Natural deaths of giant otters (*Pteronura Brasiliensis*) in Balbina hydroelectric lake, Amazonas, Brazil. *IUCN Otter Spec Group Bull* 2003; 20(2): 62-64.
- Serfass T, Peper R, Whary M, Brooks R. River otter (*Lutra canadensis*) reintroduction in Pennsylvania: prerelease care and clinical evaluation. *J Zoo Wildl Med* 1993; 24: 28-40.
- Shewell GE. Calliphoridae. In: McAlpine JF, Peterson BV, Shewell GE, Teskey HJ, Vockertoth JR, Wood DM, editors. *Manual of Nearctic Diptera*. Ottawa: Biosystematics Research Centre; 1981. p.1133-1145.
- Vargas-Terán M, Spradbery J, Hofmann H, Tweddle N. Impact of screwworm eradication programmes using the sterile insect technique. In: Dyck VA, Hendrichs J, Robinson AS, editors. *Sterile insect technique. Principles and practice in area-wide integrated pest management*. Boca Raton: CRC Press; 2020. p. 949-978. <https://doi.org/10.1201/9781003035572-29>
- Vargas-Terán M. The New World screwworm in Mexico and Central America. *World Anim Rev* 1991 [cited 2022 Oct 27]. Available from: <https://www.fao.org/3/u4220t/u4220t0d.htm>
- Wyss JH. Screwworm eradication in the americas. *Ann NY Acad Sci* 2000; 916(1): 186-193. <http://dx.doi.org/10.1111/j.1749-6632.2000.tb05289.x>. PMID:11193620.
- Yan L, Zhang M, Tang LP, Ente M, Ma XP, Chu HJ, et al. First reports of nasal and traumatic myiasis infection in endangered Przewalski's horses (*Equus ferus przewalskii*). *Int J Parasitol Parasites Wildl* 2019; 9: 21-24. <http://dx.doi.org/10.1016/j.ijppaw.2019.03.018>. PMID:30976513.
- Zumpt F. *Myiasis in man and animals in the Old World: a textbook for physicians veterinarians, and zoologists*. Michigan: Butterworth; 1965.