

# Late Clinical Outcomes of Firebird™ Sirolimus-Eluting Stent for the Treatment of Coronary Artery Disease in Daily Practice – 24-Month Follow-up of the CLARIFIRE Registry

Rodrigo Souza<sup>1,2</sup>, Ricardo A. Costa<sup>1,3</sup>, Alexandre Abizaid<sup>1,3</sup>, Mônica Buchalla<sup>4</sup>, Ronaldo da Rocha Loures Bueno<sup>5</sup>, George C. Ximenes Meireles<sup>6</sup>, Kleber Bomfim Araújo Martins<sup>7</sup>, J. Ronaldo Mont'Alverne Filho<sup>8</sup>, Costantino Costantini<sup>9</sup>, Décio Salvadori Jr.<sup>10</sup>, Wilson A. Pimentel-Filho<sup>10</sup>, Andrea S. Abizaid<sup>1,3</sup>, Juliana Polachini de Castro<sup>1</sup>, Expedito Ribeiro<sup>11</sup>, Fausto Feres<sup>3</sup>, on behalf of the CLARIFIRE registry.

## ABSTRACT

**Background:** The Firebird™ sirolimus-eluting stent has proven to be effective in inhibiting neointimal hyperplasia in selected patients undergoing percutaneous coronary intervention. Our objective was to evaluate the performance and long-term outcomes of Firebird™ in patients undergoing percutaneous coronary intervention in daily practice in Brazil. **Methods:** The CLARIFIRE Registry was a prospective, non-randomized, multicenter study enrolling 455 patients (536 lesions) in 14 Brazilian sites between December 2008 and May 2011. Clinical follow-up was performed at 1, 6, 12, and 24 months, and adverse events were adjudicated by the independent Clinical Events Committee. **Results:** Mean age was 61.1 ± 10.4 years, 30.8% were women, 41.9% had diabetes, and 58.2% had stable angina. The left anterior descending artery was the most prevalent target vessel (46.5%), 29.9% were restenotic lesions, and 8% were bifurcations. Six hundred and thirteen stents were implanted, and the mean nominal stent length and diameter were 22.0 ± 6.4 mm and 2.90 ± 0.40 mm, respectively. Procedural success was 97.6%. The cumulative major adverse cardiac events rate at 12 months (primary endpoint) was 8.1%. Considering post-discharge events up to 24 months (409/455), major adverse cardiac events were observed in 9.8%, cardiac death in 3.9%, and target vessel revascularization in 7.6% of the patients. Definite/probable stent thrombosis was observed in nine cases (2%) up to 30 days, and no further occurrences were

## RESUMO

### Resultados Clínicos Tardios do Stent Farmacológico Liberador de Sirolimus Firebird® no Tratamento de Pacientes com Doença Arterial Coronária na Prática Diária – Seguimento de 24 Meses do Registro CLARIFIRE

**Introdução:** O stent farmacológico liberador de sirolimus Firebird® já demonstrou eficácia na inibição de hiperplasia neointimal em pacientes selecionados submetidos à intervenção coronária percutânea. Nosso objetivo foi avaliar o desempenho e o resultado clínico tardio do dispositivo Firebird® em pacientes submetidos à intervenção coronária percutânea na prática diária nacional. **Métodos:** O Registro CLARIFIRE foi um estudo prospectivo, não randomizado, multicêntrico, que incluiu 455 pacientes (536 lesões) em 14 centros no Brasil entre dezembro de 2008 e maio de 2011. O seguimento clínico foi realizado aos 1, 6, 12 e 24 meses, e os eventos adversos foram adjudicados por um Comitê de Eventos Clínicos independente. **Resultados:** A média das idades foi de 61,1 ± 10,4 anos, 30,8% eram do sexo feminino, 41,9% tinham diabetes e 58,2% apresentaram-se com angina estável. O vaso-alvo mais prevalente foi a artéria descendente anterior (46,5%), 29,9% eram lesões reestenóticas e 8% lesões em bifurcação. Foram implantados 613 stents e as médias de extensão e diâmetro nominal dos stents foram 22,0 ± 6,4 mm e 2,90 ± 0,40 mm, respectivamente. O sucesso do procedimento foi de 97,6%. A taxa cumulativa de eventos

<sup>1</sup> Cardiovascular Research Center, São Paulo, SP, Brazil.

<sup>2</sup> Escola Paulista de Medicina, Universidade Federal de São Paulo, São Paulo, SP, Brazil.

<sup>3</sup> Instituto Dante Pazzanese de Cardiologia, São Paulo, SP, Brazil.

<sup>4</sup> Santa Casa de Misericórdia de São José do Rio Preto, São José do Rio Preto, SP, Brazil.

<sup>5</sup> Universidade Federal do Paraná, Curitiba, PR, Brazil.

<sup>6</sup> Hospital Stella Maris, São Paulo, SP, Brazil.

<sup>7</sup> São Lucas Clínica e Hospital, Aracaju, SE, Brazil.

<sup>8</sup> Hospital Universitário Walter Cantídio, Fortaleza, CE, Brazil.

<sup>9</sup> Hospital Cardiológico Costantini, Curitiba, PR, Brazil.

<sup>10</sup> Hospital Beneficência Portuguesa de São Paulo, São Paulo, SP, Brazil.

<sup>11</sup> Instituto do Coração, Hospital das Clínicas, Faculdade de Medicina, Universidade de São Paulo, São Paulo, SP, Brazil

**Corresponding Author:** Ricardo A. Costa. Instituto Dante Pazzanese de Cardiologia, Cardiovascular Research Center – Rua Dr. Astolfo Araújo, 521 – Vila Mariana – CEP: 04012-070 – São Paulo, SP, Brazil  
E-mail: rcosta@crmed.com.br

Received on: 09/02/2014 • Accepted on: 11/06/2014

found. **Conclusions:** The Firebird™ sirolimus-eluting stent has demonstrated good performance and sustained safety and efficacy for patients treated in daily practice, as evidenced by the high procedural success rates and relatively low adverse event rates after 2 years.

**Descriptors:** Coronary disease. Percutaneous coronary intervention. Drug-eluting stents.

The advent of drug eluting stents (DES), at the beginning of this century, allowed for overcoming the main limitations of coronary stents: neointimal hyperplasia and subsequent angiographic restenosis, and the need for revascularization of the target lesion (TLR).<sup>1-3</sup> However, with the expansion and diversification of the use of first-generation DES systems (Cypher; Cordis – Miami Lakes, United States, a sirolimus-eluting stent; and Taxus; Boston Scientific – Natick, United States, a paclitaxel-eluting stent), concerns have arisen regarding the late effectiveness and safety of these devices, especially in more complex subgroups.<sup>4,5</sup> These concerns have encouraged the development of new DES systems, including alternative stent platforms, more biocompatible drug-carrier systems, and potent antiproliferative agents.<sup>6-13</sup>

The Firebird® stent (MicroPort Medical Co., Ltd. – Shanghai, China) is a DES system already approved for clinical use in Asia and South America, which incorporates a stainless steel platform with a low crossing profile, associated with a potent and widely-studied immunosuppressant (sirolimus) and a durable drug-carrier component (polymer), designed to optimize the transport of the product in a proper and safe manner.<sup>11</sup> Initial studies with selected populations have demonstrated the efficacy of this new device in preventing neointimal hyperplasia, with restenosis rates comparable to those in studies with first-generation DES, as well as reducing target vessel revascularization (TVR) and major adverse cardiovascular events (MACE) at late follow-up, compared to bare-metal stents.<sup>3,14-17</sup> Thus, because the production of the Firebird® stent is facilitated in selected locations, with its reduced costs, now this type of technology is available to a larger portion of the population.<sup>18</sup>

This study aimed to evaluate the performance and late clinical outcome of Firebird®, a sirolimus-eluting stent, in the treatment of a minimally selected Brazilian

cardíacos adversos maiores aos 12 meses (desfecho primário) foi 8,1%. Considerando-se os eventos pós-hospitalização até 24 meses (409/455), observaram-se eventos cardíacos adversos maiores em 9,8%, morte cardíaca em 3,9% e revascularização do vaso-alvo em 7,6%. Já a trombose de stent (definitiva/provável) ocorreu em nove casos (2%) até 30 dias, sem ocorrências subsequentes. **Conclusões:** O stent farmacológico liberador de sirolimus Firebird® demonstrou desempenho favorável, além de segurança e eficácia sustentadas no tratamento de pacientes da prática diária, conforme evidenciado pela elevada taxa de sucesso do procedimento e pela ocorrência relativamente baixa de eventos adversos ao final de 2 anos.

**Descritores:** Doença das coronárias. Intervenção coronária percutânea. Stents farmacológicos.

population in daily clinical practice.

## METHODS

### Protocol and study population

The Brazilian Protocol for Evaluating Long-Term Safety and Efficacy of Firebird® Stent in Clinical Practice (CLARIFIRE) Registry was a prospective, non-randomized, multicenter, single-arm, Phase IV (post-marketing) study held in Brazil in order to evaluate the performance of Firebird®, a sirolimus-eluting stent, in daily practice.

This study included individuals aged > 18 years undergoing routine or emergency percutaneous coronary intervention (PCI) in several participating centers; such patients were required to have at least one lesion with ≥ 50% stenosis in a native coronary artery, with a diameter ≥ 2.5 mm by visual estimate, and with favorable anatomy for PCI, with implantation of at least one Firebird® stent, with no pre-established limitations as to the number of injuries and/or vessels to be treated. In patients with multivessel disease, “target lesion” was defined as an injury compatible with the coronary territory involved, as indicated by complementary tests (electrocardiogram [ECG], myocardial scintigraphy, or stress echo). The operating physician was solely responsible for the final decision with respect to the vessels’ approach strategy. Patients with a life expectancy < 12 months, with inability to perform all pre-established clinical follow-up procedures, as well as with an inadequate coronary anatomy for Firebird® sirolimus-eluting stent implantation, were excluded.

The study was conducted under the principles of the Declaration of Helsinki regarding human research, and was approved by the Research Ethics Committee of the participating centers, as well as complying with regulations and requirements of Comissão Nacional de Ética em Pesquisa (CONEP). In addition, each

participating patient signed an informed consent prior to his/her inclusion in the study.

### Device description

Firebird®, a sirolimus-eluting system, uses the Mustang® stent (MicroPort Medical Co., Ltd. – Shanghai, China) as platform and is approved for commercial use in Brazil and the European Community. This device incorporates a 316L stainless steel metal platform, whose design features sinuous curves of varying sizes, connected by brackets in the form of “n”, with 0.0040” (101 µm) thickness, in order to obtain a balance of flexibility and radial strength. The device is coated with a durable polymer that carries and controls the release of sirolimus.<sup>11</sup> Such components are distributed in three levels: (1) coating, or base coating, consisting only of the polymer, which involves the entire surface of the stent and adheres to the drug, ensuring that the base remains linked during device implantation; (2) drug layer, comprising the drug and polymer composition; and (3) top coating, consisting of a dedicated co-polymer formulation (ethylene-vinyl-acetate), which controls the release rate of sirolimus (Figure 1).

### Procedure

PCI procedures were performed according to current guidelines,<sup>19</sup> leaving at the operating physician's discretion the final strategy for the procedure – staging or revascularization of all injuries in the same procedure (in the case of multiple target lesions). The following measures of the sirolimus-eluting stent Firebird® were provided: diameter, 2.5 mm, 2.75 mm, 3 mm, 3.5 mm, and 4.0 mm; length, 13 mm, 18 mm, 23 mm, 29 mm, and 33 mm.

In general, dual antiplatelet therapy consisted of acetylsalicylic acid (100-325 mg/day), plus thienopyridine (clopidogrel) (75 mg/day) in the case of chronic use (at least seven days before the procedure); or, alternatively, the choice was in favor of a loading dose of 300 to 600 mg before the procedure, in those patients where clopidogrel had not been

started yet. After PCI, the acetylsalicylic-acid therapy was maintained indefinitely, and thienopyridine was continued for at least six months (as recommended by the attending physician and/or according to the institution protocol). During the procedure, antithrombotic therapy with intravenous unfractionated heparin at a dose of 70-100 U/kg was also used in order to maintain an activated coagulation time of > 250 seconds (or > 200 seconds in the case of glycoprotein inhibitor IIb/IIIa administration). The decision on the use of a glycoprotein inhibitor IIb/IIIa was taken at the discretion of the operating physician.

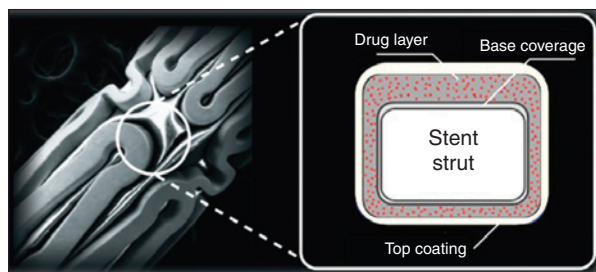
In general, a 12-lead ECG was requested before, immediately after, and 24 hours after PCI. Laboratory tests, among them cardiac enzymes (creatin kinase[CK] and creatine kinase MB fraction [CK-MB]) before the procedure (< 24 hours), 18-24 hours after the procedure, and then daily, in case of some change, were performed until hospital discharge.

### Database and monitoring

The study was conducted independently by a representative clinical research organization in the city of São Paulo (SP), through electronic registration of patients' data collection, procedures, and clinical outcomes, as already described.<sup>20</sup> To this end, this study used an electronic data capture system, with restricted access via personal passwords. All data entered were verified, to correct any discrepancies or inconsistent information through remote monitoring. In cases of occurrence of some adverse event, assessments were performed directly in the documentation-source, and subsequently adjudicated by the independent Clinical Events Committee. The information for identification was kept strictly confidential, since the patients were identified by a unique identifier code used in the electronic medical record. Prior to PCI, information was collected on baseline demographics, medical history, current medication, clinical presentation, laboratory tests, and ECG. Angiographic data consisted of morphology of coronary vessels and target lesions, quantitative estimate of the target lesion, and left-ventricular function estimate. Procedural data included pre- and/or post-dilatation of the lesion, stenting, adjuvant procedures and treatments, as well as angiographic and procedural complications. Post-procedure data also included clinical complications, laboratory data, ECG, and prescribed medications, including antiplatelet therapy.

### Definitions, outcomes, and clinical follow-up

The primary combined end point was the occurrence of MACE at 12 months of follow-up, while secondary endpoints included success rates of the procedure, MACE in the pre-specified intervals of the study, TLR at 6 and 12 months, and stent thrombosis



**Figure 1** – Sirolimus-eluting Firebird® stent (left), including schematic representation of the drug-polymer layers and the metal strut level (right). Source: [http://www.microport.com.cn/en/product.php?curr\\_page=product\\_firebird2&id=2](http://www.microport.com.cn/en/product.php?curr_page=product_firebird2&id=2)

up to 24 months. MACE was defined as cardiac death, myocardial infarction (MI), TLR, or TVR. All deaths were considered as of cardiac origin, unless a non-cardiac cause could be clearly established by clinical and/or pathological study. The occurrence of MI was considered for the following: onset of new pathological Q waves in  $\geq 2$  contiguous leads in ECG and/or elevation of CK-MB or troponin above the upper limit of normal (ULN); or elevation of CK  $\geq 2 \times$  ULN with any elevation of CK-MB and/or troponin in the absence of Q waves. TLR and TVR were defined as a new percutaneous or surgical intervention in the target injury and target vessel, respectively. Definite or probable stent thrombosis was defined according to Academic Research Consortium criteria;<sup>21</sup> this complication was considered as definite when there was presence of acute coronary syndrome and angiographic or pathological confirmation of stent occlusion; and probable if there was occurrence of sudden death  $\leq 30$  days after the procedure-index, or target vessel MI, without angiographic confirmation of stent occlusion. Stent thrombosis was also classified according to its temporal occurrence: acute ( $\leq 24$  hours), subacute ( $> 1$  day and  $< 30$  days), late ( $> 30$  days and  $\leq 360$  days), and very late ( $> 360$  days). Angiographic success was defined as a residual stenosis (visual estimate)  $< 30\%$  at the end of the procedure. Procedural success was defined as angiographic success and non-occurrence of MACE during hospitalization.

Clinical follow-up consisted of a preclinical visit or telephone contact, according to a predefined protocol at the end of 30 days, and 6, 12, and 24 months after the procedure.

### Statistical analysis

Distributions of continuous variables were expressed as mean  $\pm$  standard deviation. Distributions of discrete (or categorical) variables were expressed as frequencies and percentages.

### RESULTS

From December 2008 to May 2011, 455 individuals were included in 14 national centers, and 447 (98.2%) and 409 (89.9%) patients completed their clinical follow-up (or had data available) at 12 and 24 months, respectively, as shown in Figure 2.

With regard to baseline characteristics, the patients' mean age was  $61.1 \pm 10.4$  years; 30.8% were female. There was a predominance of patients with systemic hypertension, dyslipidemia, and smoking history, and 41.9% had diabetes mellitus. Regarding clinical presentation, the majority (58.2%) had stable angina, while only 2.9% had a diagnosis of AMI (Table 1). The most commonly used adjuvant medications were statins (87.7%), beta-blockers (83.9%), angiotensin-converting-enzyme inhibitors (58.7%), angiotensin-II-receptor antagonists

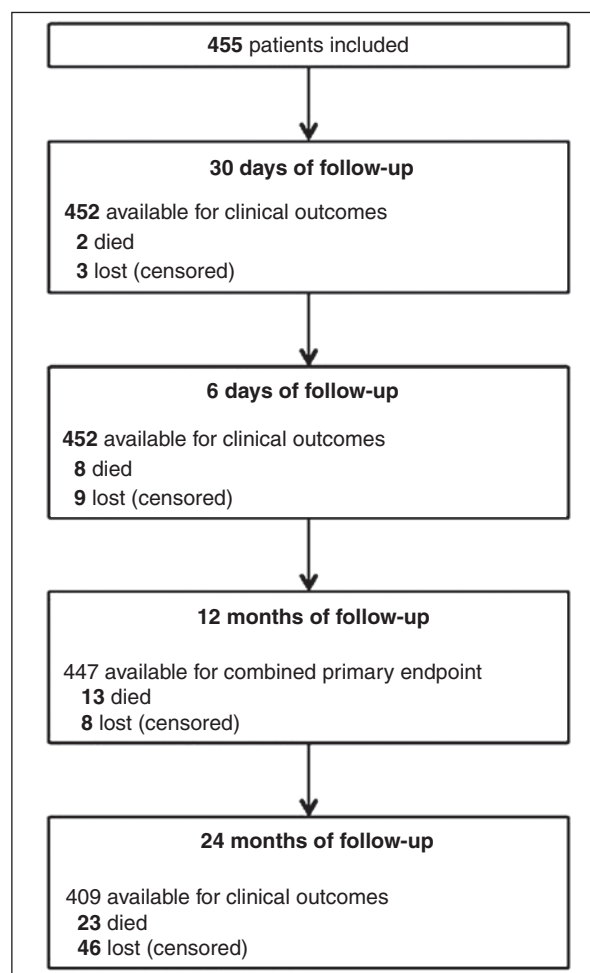


Figure 2 – Clinical follow-up flowchart of patients included in the CLARIFIRE registry.

(22.2%), nitrates (37.6%), calcium channel antagonists (21.1%), and diuretics (21.5%).

### Angiographic and procedural characteristics

Tables 2 and 3 show angiographic and procedural data. The anterior descending artery (AD) was the most treated target vessel; 29.9% were restenotic lesions and 8% occurred in bifurcations. 536 injuries were treated with 613 stents (mean of stents per patient  $> 1.3$ ). In most cases, it was decided to carry out pre- (60.6%) and/or post-dilatation (59.1%). Although there is no restriction as to the staged procedure, only 13 (2.9%) cases were treated in this manner. Additionally, in 433 (95.2%) cases, only the study stent was used; in the other 4.8%, the study stent was combined with another stent, at the discretion of the operating physician.

Before the procedure, the mean lesion length, reference diameter, and stenosis diameter were  $19.0 \pm 8.0$  mm,  $3.03 \pm 2.2$  mm, and  $80.4 \pm 14.1\%$ , respectively.

**TABLE 1**  
**Baseline clinical characteristics**

Variable	n = 455
Age, years	61.1 ± 10.4
Female gender, n (%)	140 (30.8)
Diabetes mellitus, n (%)	191 (41.9)
Using insulin	62 (13.6)
Hypertension, n (%)	397 (87.3)
Dyslipidemia, n (%)	361 (79.3)
Smoking history, n (%)	251 (55.2)
Current smoking	71 (15.6)
Family history of CAD, n (%)	146 (32.1)
Previous AMI, n (%)	226 (49.7)
Prior PCI, n (%)	243 (53.4)
Prior CABG, n (%)	55 (12.1)
Previous stroke, n (%)	14 (3.1)
Peripheral vascular disease,	20 (4.4)
Renal failure <sup>a</sup> , n (%)	33 (7.3)
Clinical presentation, n (%)	
Silent ischemia	109 (24.0) <sup>b</sup>
Stable angina	265 (58.2)
Unstable angina	54 (11.9)
AMI without ST-segment elevation	13 (2.9)
AMI with ST-segment elevation	13 (2.9)

<sup>a</sup> Defined by creatinine clearance < 60 mL/min; <sup>b</sup>includes recent post-AMI asymptomatic patients. CAD, coronary artery disease; AMI, acute myocardial infarction; PCI, percutaneous coronary intervention; CABG, coronary artery bypass graft surgery.

**TABLE 2**  
**Angiographic characteristics**

Variable	n = 455 (536 injuries)
Target vessel, n (%)	
AD	249 (46.5)
Cx	133 (24.8)
RC	139 (25.9)
LMCA	15 (2.8)
In-stent restenosis, n (%)	160 (29.9)
Bifurcation, n (%)	43 (8.0)
Quantitative coronary angiography <sup>a</sup>	
Lesion length, mm	19.0 ± 8.0
Reference diameter, mm	3.0 ± 2.2
Stenosis diameter,%	80.4 ± 14.1

<sup>a</sup>Visual analysis estimate, as reported by the operating physician. AD, anterior descending coronary artery; Cx, circumflex coronary artery; RC, right coronary artery; LMCA, left main coronary artery.

Correspondingly, the mean nominal values of stent length and diameter were 22.0 ± 6.4 mm and 2.90 ± 0.35 mm, respectively (Table 3). At the end of PCI, procedural success was achieved in 97.6% of patients.

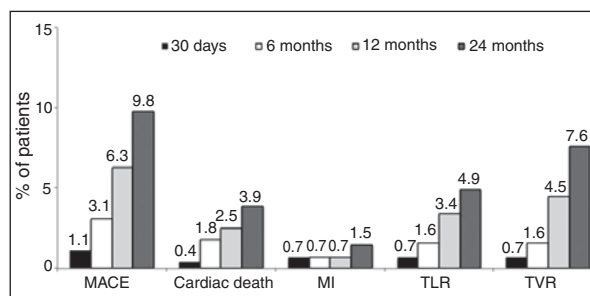
**Clinical events**

In the in-hospital phase, clinical event rates were as follows: MACE 1.8%, MI 1.5%, TLR 0.9%, and TVR 1.1%, with no reported deaths in that period. In the late follow-up, the cumulative rates of adverse events after discharge can be seen in Figure 3. It is noted that the cumulative rate of the primary endpoint of MACE at 12 months was 8.1%, including a total of 11 (2.5%) cases of cardiac death. Between 12 and 24 months, ten new deaths (five cardiac, five non-cardiac) occurred. Table 4 lists a detailed description of all fatal events that occurred until the 24-month follow-up.

In relation to definite or probable stent thrombosis,

**TABLE 3**  
**Procedural characteristics**

Variable	n = 455 (536 injuries)
Radial access route, n (%)	94 (20.7)
Pre-dilatation, n (%)	325 (60.6)
Nominal length of balloon, mm	16.1 ± 5.1
Nominal diameter of balloon, mm	2.37 ± 0.63
Inflation pressure, atm	10.7 ± 3.6
Implanted stent	
Nominal length of stent, mm	22.0 ± 6.4
Nominal diameter of stent, mm	2.90 ± 0.40
Inflation pressure, atm	13.6 ± 3.4
Post-dilatation, n (%)	317 (59.1)
Nominal length of balloon, mm	15.7 ± 5.5
Nominal diameter of balloon, mm	3.10 ± 0.60
Maximum insufflation pressure, atm	18.2 ± 4.3



**Figure 3** – Cumulative rates of adverse events occurring after in-hospital phase at 30-day and at 6-, 12-, and 24-month follow-up. MACE, major adverse cardiac events; MI, myocardial infarction; TLR, target-lesion revascularization; TVR, target vessel revascularization.

**TABLE 4**  
**Description of deaths up to 24 months of follow-up**

Case	Age (years)	Gender	Previous history (pre-procedure)	Clinical indication of PCI	Target vessel	Primary clinical presentation of the event	Time to event (days)	Adjudication <sup>a</sup>
1	76	F	DM, SBP, DLP, former smoker, CRF	SA II	Cx	CHF/ARF	16	Cardiac death
2	72	M	DM, SBP, DLP, former smoker, AMI, PCI, CABG	ACS	Cx	Sudden death	17	Cardiac death
3	71	F	DM, SBP, DLP	ACS	AD	Unknown	44	Cardiac death
4	82	M	DM, DLP, AMI, CRF	Silent ischemia	Cx	Sudden death	50	Cardiac death
5	67	M	SBP, DLP, former smoker, AMI, PCI	SA III	RC	Sudden death	50	Cardiac death
6	73	F	DM, SBP, DLP	ACS	Cx	Respiratory failure	54	Cardiac death
7	69	M	DM, SBP, DLP, former smoker, AMI, CABG	SA IV	LMCA	Acute pulmonary edema	85	Cardiac death
8	80	F	DM, SBP	Silent ischemia	Cx	ARF	111	Cardiac death
9	55	M	SBP, DLP, former smoker, AMI, PCI	ACS	AD	Cardiogenic shock	203	Cardiac death
10	53	M	DM, SBP, DLP, CRF, AMI, PCI	ACS	RC	Septic shock	230	Non-cardiac death
11	50	F	DM, SBP, DLP, CRF, AMI, PCI	Silent ischemia	AD	Pneumonia	325	Cardiac death
12	63	M	DM, SBP, DLP, AMI, CABG, stroke	SA I	RC-AD	Hemorrhagic stroke	335	Non-cardiac death
13	66	M	DM, SBP, DLP, PCI	SA II	RC	Unknown	339	Cardiac death
14	61	M	DM, SBP, DLP, CABG	SA II	Cx	Unknown	371	Cardiac death
15	77	F	DM, SBP, DLP, AMI, PCI	SA II	AD	Sudden death	392	Cardiac death
16	64	F	DM, SBP, DLP, former smoker, AMI, PCI	SA II	Cx	Unknown	556	Cardiac death
17	49	M	DM, former smoker, AMI, PCI	SA II	AD <sup>b</sup>	Septic shock	568	Non-cardiac death
18	53	F	DM, SBP, DLP, former smoker, AMI, PCI	ACS	AD	Cardiogenic shock	569	Cardiac death
19	64	F	DM, SBP, DLP, former smoker, PCI	ACS	RC	Sudden death	593	Cardiac death
20	62	M	SBP, DLP, PCI	SA III	AD	Hemorrhagic stroke	613	Non-cardiac death
21	50	M	Former smoker, PCI	Silent ischemia	AD	Gastrointestinal cancer	664	Non-cardiac death
22	55	M	DM, SBP, DLP, former smoker, AMI, stroke	ACS	AD	Peripheral arterial thrombosis	739	Non-cardiac death
23	58	F	DM, SBP, DLP, former smoker, AMI, PCI	ACS	Cx	Breast cancer	758	Non-cardiac death

<sup>a</sup>Events adjudicated by the Independent Clinical Events Committee; <sup>b</sup>Bifurcation lesion treated with two-stent technique. PCI, percutaneous coronary intervention; F, female; DM, diabetes mellitus; SBP, systemic hypertension; DLP, dyslipidemia; CRF, chronic renal failure; SA, stable angina; Cx, circumflex coronary artery; CHF, congestive heart failure; ARF, acute renal failure; M, male; AMI, acute myocardial infarction; CABG, coronary artery bypass graft; ACS, acute coronary syndrome; AD, anterior descending coronary artery; RC, right coronary artery; LMCA, left main coronary artery; LIM, left internal mammary artery.

the non-occurrence of late and very late events stands out, despite nine cases of early thrombosis (up to 30 days).

## DISCUSSION

DES, especially sirolimus-eluting systems, have consistently demonstrated their effectiveness in inhibiting neointimal hyperplasia, in angiographic restenosis, and in cases needing repeat revascularization.<sup>1-3,11,14-18,22</sup> In

an analysis by Stone et al.,<sup>23</sup> including patients from the RAVEL, SIRIUS, E-SIRIUS, and C-SIRIUS studies, the effectiveness of these devices in reducing TLR rates in four years was evidenced, when compared to bare-metal stents (7.8% vs. 23.6%;  $p < 0.001$ ), besides their long-term safety, with no significant difference with respect to stent thrombosis rates, death, and MI. In this context, new sirolimus-eluting devices have been developed, among these the Firebird® system,<sup>11-13</sup> which, in this study, was safe and effective in both the

in-hospital period and in the long-term monitoring of minimally selected patients in clinical practice, including high percentages of diabetic patients (> 40%) and restenotic lesions (30%).

The results of the first Chinese registry using Firebird® stents suggested that such device was safe and effective in a non-selected Chinese population, since MACE and TVR rates after 12 months were 4.8% and 2.4%, respectively.<sup>11</sup> Additionally, in another study involving 509 consecutive patients treated with Firebird® in Chinese centers and followed for up to three years, rates for MACE of 7.9% and for TVR of 5.1% were found.<sup>18</sup> Compared to the first Chinese registry, the findings of this study showed higher cumulative rates of MACE and TVR at 12 months (8.1% vs. 4.8%), but that study involved only 84 patients, which, in general, showed lower cardiovascular risk, with lower prevalence of important risk factors compared to the CLARIFIRE registry (systemic hypertension: 66.7% vs. 87.3%; dyslipidemia: 40.5% vs. 79.3%; diabetes: 15.5% vs. 41.9%, respectively).<sup>11</sup> Also in comparison with the study by Zhang et al.,<sup>18</sup> the population appeared to be at lower cardiovascular risk (hypertension, 59.3%; dyslipidemia, 33.8%; diabetes, 20.2%); even so, the results in the very late stage were similar to the present findings. Interestingly, these authors demonstrated that the occurrence of MACE more than doubled (13.7% vs. 6.4%) in diabetic patients as compared to non-diabetic patients, which could explain, at least in part, the rates of MACE in the present population (42% of diabetics).<sup>18</sup> Moreover, the result of a previous study involving diabetic patients with multivessel disease and treated with Firebird® stents was a rate of MACE at 12 months of 21%, mostly at the expense of new revascularization.<sup>24</sup> This has been confirmed by Rapamycin-Eluting Stent Evaluated At Rotterdam Cardiology Hospital (RESEARCH) registry findings; that study demonstrated that presence of diabetes mellitus can increase the chance of occurrence of MACE by up to 2.6 times in patients treated with a sirolimus-eluting stent.<sup>25</sup>

When compared with conventional stents or with the Cypher® system in the treatment of *de novo* lesions with length  $\geq$  30 mm, the Firebird® DES was superior to bare-metal stents with respect to binary restenosis rates at 6 months, both in intrasegment (14.6% vs. 36.1%; relative risk – RR = 0.41,  $p = 0.04$ ) and intrastent (9.8% vs. 30.6%; HR = 0.32;  $p = 0.03$ ) analysis, with a significant impact on MACE rates at 12 months (7.7% vs. 27.0%;  $p = 0.03$ ), respectively. In comparison with the Cypher® system, Firebird® showed comparable results, with similar rates of intrasegment restenosis (14.6% vs. 12.8% [RR = 1.14;  $p = 0.81$ ]) and intrastent restenosis (9.8% vs. 10.3% [RR = 0.95;  $p = 0.94$ ]); and also MACE rate, 7.7% vs. 5.4% ( $p = 1.0$ ), respectively.<sup>17</sup> These results are comparable to those of the present analysis, whose cumulative rates of MACE at 12 and

24 months were 8.1% and 10.5%, respectively, corroborating the safety and efficacy of the device under study in a population of higher complexity. Of note is the fact that the Firebird® system has shown remarkable efficacy in restenotic lesions,<sup>26</sup> which were widely represented in the CLARIFIRE registry.

Furthermore, the impact of the Firebird® stent was also evaluated in high-risk subgroups, including acute coronary syndrome. Gao et al.,<sup>15</sup> studying patients with acute myocardial infarction with ST-segment elevation, showed superiority of the Firebird® DES when compared to bare-metal stents, with significant reductions in TVR (6.9% vs. 30.9%;  $p < 0.05$ ) and MACE (9.9% vs. 36.4%;  $p < 0.05$ ) at 5 months follow-up. These authors also found a low incidence of acute and subacute stent thrombosis. In the present registry, the occurrence of thrombosis (definite or probable) was also relatively low (2.0%), and was confined to the first 30 post-procedural days. It should be emphasized that late or very late stent thrombosis did not occur, which highlights the long-term safety of the device. In general, the occurrence of stent thrombosis, both acute and subacute, has been associated to factors (or complications) related to the procedure and to compliance with dual antiplatelet therapy, with no difference between DES and bare-metal stents.<sup>5,27</sup> However, the occurrence of late or very late events has been instrumental in the safety assessment of modern types of DES.<sup>28</sup>

The presence of a durable polymer has been a cause of concern about the safety of DES, due to its association with pathological changes and toxicity in the vessel wall.<sup>29,30</sup> With that in mind, Liu et al.,<sup>22</sup> in a study of 190 patients with angiographic follow-up at 6 months, compared Firebird® with Excel®, a bio-absorbable-polymer sirolimus-eluting stent (JW Medical Co. Ltd. – Shandong Province, China). In these authors' analysis, low rates of MACE (0% vs. 2.1%;  $p > 0.05$ ) and of binary restenosis (0% in both groups) were observed, with no significant difference.<sup>22</sup>

The present study had some limitations. First, the study had no control group, which may compromise the comparative assessment of the safety and efficacy of the device. Secondly, the majority of patients completed 12 months of follow-up (98.2%); however, the 24-month follow-up was slightly lower (~ 90%), which could influence the interpretation of the actual occurrence of late adverse events. This can be understood as a limitation in studies of this nature (real world "registries") with a very late follow-up. However, all adverse events reported in this study were adjudicated by the independent Clinical Events Committee. Finally, the device tested does not represent the later generations of the Firebird® DES system – with low cobalt-chromium profile platforms, which should be available soon in this community.<sup>31,32</sup>

## CONCLUSIONS

Firebird®, a sirolimus-eluting stent, showed a favorable performance, besides continuing safety and effectiveness in the treatment of daily practice patients, as evidenced by the high success rate of the procedure and the relatively low occurrence of adverse events at the end of two years in a minimally selected Brazilian cohort from clinical practice, with high cardiovascular risk and a high proportion of diabetics. In general, the results obtained in this study are comparable to the results of several previous studies in different populations, as well as with those findings demonstrated by the first generation sirolimus-eluting stent.

## CONFLICTS OF INTEREST

The authors declare no conflicts of interest.

## FUNDING SOURCE

None.

## REFERENCES

1. Sousa JE, Costa MA, Abizaid A, Abizaid AS, Feres F, Pinto IM, et al. Lack of neointimal proliferation after implantation of sirolimus-coated stents in human coronary arteries: a quantitative coronary angiography and three-dimensional intravascular ultrasound study. *Circulation*. 2001;103(2):192-5.
2. Morice MC, Serruys PW, Sousa JE, Fajadet J, Ban Hayashi E, Perin M, et al. A randomized comparison of a sirolimus-eluting stent with a standard stent for coronary revascularization. *N Engl J Med*. 2002;346(23):1773-80.
3. Moses JW, Leon MB, Popma JJ, Fitzgerald PJ, Holmes DR, O'Shaughnessy C, et al. Sirolimus-eluting stents versus standard stents in patients with stenosis in a native coronary artery. *N Engl J Med*. 2003;349(14):1315-23.
4. Daemen J, Wenaweser P, Tsuchida K, Abrecht L, Vaina S, Morger C, et al. Early and late coronary stent thrombosis of sirolimus-eluting and paclitaxel-eluting stents in routine clinical practice: data from a large two-institution cohort study. *Lancet*. 2007;369(9562):667-78.
5. Iakovou I, Schmidt T, Bonizzoni E, Ge L, Sangiorgi GM, Stankovic G, et al. Incidence, predictors, and outcome of thrombosis after successful implantation of drug-eluting stents. *JAMA*. 2005;293(17):2126-30.
6. Costa RA, Lansky AJ, Mintz GS, Mehran R, Tsuchiya Y, Negoita M, et al. Angiographic results of the first human experience with everolimus-eluting stents for the treatment of coronary lesions (the FUTURE I trial). *Am J Cardiol*. 2005;95(1):113-6.
7. Serruys PW, Ong AT, Piek JJ, Neumann FJ, van der Giessen WJ, Wiemer M, et al. A randomized comparison of a durable polymer Everolimus-eluting stent with a bare metal coronary stent: The SPIRIT first trial. *EuroIntervention*. 2005;1(1):58-65.
8. Meredith IT, Ormiston J, Whitbourn R, Kay IP, Muller D, Bonan R, et al. First-in-human study of the Endeavor ABT-578-eluting phosphorylcholine-encapsulated stent system in de novo native coronary artery lesions: Endeavor I Trial. *EuroIntervention*. 2005;1(2):157-64.
9. Costa RA, Lansky AJ, Abizaid A, Mueller R, Tsuchiya Y, Mori K, et al. Angiographic results of the first human experience with the Biolimus A9 drug-eluting stent for de novo coronary lesions. *Am J Cardiol*. 2006;98(4):443-6.
10. Meredith IT, Worthley S, Whitbourn R, Walters DL, McClean D, Horrigan M, et al. Clinical and angiographic results with the next-generation resolute stent system: a prospective, multicenter, first-in-human trial. *JACC Cardiovasc Interv*. 2009;2(10):977-85.
11. Liu HB, Xu B, Gao R, Yang Y, Yao M, Qin X, et al. Outcomes of using Firebird rapamycin eluting stents in routine coronary intervention practice: one-year results from the pilot study of Firebird in China registry. *Chin Med J (Engl)*. 2006;119(7):609-11.
12. Dani S, Costa RA, Joshi H, Shah J, Pandya R, Virmani R, et al. First-in-human evaluation of the novel BioMime sirolimus-eluting coronary stent with bioabsorbable polymer for the treatment of single de novo lesions located in native coronary vessels – results from the merIT-1 trial. *EuroIntervention*. 2013;9(4):493-500.
13. Ribeiro EE, Campos CM, Ribeiro HB, Lopes AC, Esper RB, Meirelles GX, et al. First-in-man randomised comparison of a novel sirolimus-eluting stent with abluminal biodegradable polymer and thin-strut cobalt-chromium alloy: INSPIRON-I trial. *EuroIntervention*. 2014;9(12):1380-4.
14. Li Y, Li CX, Wang HC, Xu B, Fang WY, Ge JB, et al. Efficacy and safety of Firebird sirolimus-eluting stent in treatment of complex coronary lesions in Chinese patients: one-year clinical and eight-month angiographic outcomes from the FIREMAN registry. *Chin Med J (Engl)*. 2011;124(6):817-24.
15. Gao H, Yan HB, Zhu XL, Li N, Ai H, Wang J, et al. Firebird sirolimus eluting stent versus bare metal stent in patients with ST-segment elevation myocardial infarction. *Chin Med J (Engl)*. 2007;120(10):863-7.
16. Yu M, Zhou YJ, Wang ZJ, Shi DM, Liu YY, Zhao YX, et al. A comparison of clinical outcomes of Chinese sirolimus-eluting stents versus foreign sirolimus-eluting stents for the treatment of coronary artery disease. *Neth Heart J*. 2011;19(10):418-22.
17. Fan L, Chen LL, Lin CG, Peng YF, Zheng XC, Luo YK, et al. Firebird and cypher sirolimus-eluting stents and bare metal stents in treatment of very long coronary lesions. *Chin Med J (Engl)*. 2008;121(16):1518-23.
18. Zhang Q, Xu B, Yang YJ, Qiao SB, Zhang RY, Zhang JS, et al. Long-term efficacy and safety of Chinese made sirolimus eluting stents: results, including off label usage, from two centres over three years. *Chin Med J (Engl)*. 2008;121(17):1670-4.
19. Mattos LA, Lemos Neto PA, Rassi A Jr, Marin-Neto JA, Sousa AGMR, Devito FS, et al. Diretrizes da Sociedade Brasileira de Cardiologia – Intervenção Coronária Percutânea e Métodos Adjuntos Diagnósticos em Cardiologia Intervencionista (II Edição – 2008). *Arq Bras Cardiol*. 2008;91(6 Supl.1):1-58.
20. Abreu-Silva EO, Costa RA, Abizaid AS, Perin M, Cardoso RF, Prudente ML, et al. Stents farmacológicos liberadores de Everolimus XienceTMV no tratamento de pacientes com lesões coronárias complexas na prática diária: resultados iniciais do Registro Brasileiro BRAVO. *Rev Bras Cardiol Invasiva*. 2011;19(4):357-66.
21. Cutlip DE, Windecker S, Mehran R, Boam A, Cohen DJ, van Es G-A, et al. Clinical end points in coronary stent trials: a case for standardized definitions. *Circulation*. 2007;115(17):2344-51.
22. Liu HB, Xu B, Qiao SB, Yang YJ, Ma WH, Qin XW, et al. A comparison of clinical and angiographic outcomes after Excel bioabsorbable polymer versus Firebird durable polymer rapamycin-eluting stent for the treatment of coronary artery disease in a “real world” setting: six-month follow-up results. *Chin Med J (Engl)*. 2007;120(7):574-7.
23. Stone GW, Moses JW, Ellis SG, Schofer J, Dawkins KD, Morice MC, et al. Safety and efficacy of sirolimus- and paclitaxel-eluting coronary stents. *N Engl J Med*. 2007;356(10):998-1008.
24. Osterne EMC, Pimentel WAF, Custódio WB, Petrucci FS, Soares



- MMN, Maiello PCA, et al. Desempenho do stent farmacológico Firebird™ em diabéticos portadores de doença coronária multiarterial. *Rev Bras Cardiol Invasiva*. 2012;20(1):58-62.
25. Lemos PA, Hoye A, Goedhart D, Arampatzis CA, Saia F, van der Giessen WJ, et al. Clinical, angiographic, and procedural predictors of angiographic restenosis after sirolimus-eluting stent implantation in complex patients: an evaluation from the Rapamycin-Eluting Stent Evaluated At Rotterdam Cardiology Hospital (RESEARCH) study. *Circulation*. 2004;109(11):1366-70.
26. Freitas LZ, Feres F, Costa Jr JR, Abizaid A, Staico R, Costa R, et al. Tratamento de reestenose intrastent com o novo stent farmacológico Firebird™, liberador de Sirolimus – resultados angiográficos e ultrassonográficos de um ano de evolução. *Rev Bras Cardiol Invasiva*. 2010;18(4):379-86.
27. Fujii K, Carlier SG, Mintz GS, Yang YM, Moussa I, Weisz G, et al. Stent underexpansion and residual reference segment stenosis are related to stent thrombosis after sirolimus-eluting stent implantation: an intravascular ultrasound study. *J Am Coll Cardiol*. 2005;45(7):995-8.
28. Windecker S, Serruys PW, Wandel S, Buszman P, Trznadel S, Linke A, et al. Biolimus-eluting stent with biodegradable polymer versus sirolimus-eluting stent with durable polymer for coronary revascularisation (LEADERS): a randomised non-inferiority trial. *Lancet*. 2008;372(9644):1163-73.
29. Finn AV, Nakazawa G, Joner M, Kolodgie FD, Mont EK, Gold HK, et al. Vascular responses to drug eluting stents: importance of delayed healing. *Arterioscler Thromb Vasc Biol*. 2007;27(7):1500-10.
30. John MC, Wessely R, Kastrati A, Schomig A, Joner M, Uchihashi M, et al. Differential healing responses in polymer- and nonpolymer-based sirolimus-eluting stents. *JACC Cardiovasc Interv*. 2008;1(5):535-44.
31. Zhang Q, Xu B, Yang YJ, Zhang RY, Li JP, Qiao SB, et al. Sirolimus-eluting cobalt alloyed stents in treating patients with coronary artery disease: six-month angiographic and one-year clinical follow-up result: a prospective, historically controlled, multi-center clinical study. *Chin Med J*. 2007;120(7):533-8.
32. Qian J, Xu B, Lansky AJ, Yang YJ, Qiao SB, Wu YJ, et al. First report of a novel abluminal groove filled biodegradable polymer rapamycin-eluting stent in de novo coronary artery disease: results of the first in man FIREHAWK trial. *Chin Med J (Engl)*. 2012;125(6):970-6.