



Journal of Coloproctology

www.jcol.org.br



Case reports

Management of ileal pouch prolapse with endoscopic hot snare

Xian-rui Wu^a, Xiu-li Liu^b, Nan Lan^c, Bo Shen^{c,*}

^aDepartment of Colorectal Surgery, the Cleveland Clinic Foundation, Cleveland, OH, USA

^bDepartment of Anatomic Pathology, the Cleveland Clinic Foundation, Cleveland OH, USA

^cDepartment of Gastroenterology/Hepatology, the Cleveland Clinic Foundation, Cleveland, OH, USA

ARTICLE INFO

Article history:

Received 20 December 2012

Accepted 12 February 2013

Keywords:

Endoscopy

Hot snare

Ileal pouch anal anastomosis

Pouch prolapse

Palavras-chave:

Endoscopia

Alça diatérmica

Anastomose íleo-anal com bolsa ileal

Prolapso da bolsa

ABSTRACT

Pouch prolapse is a complication following the creation of restorative proctocolectomy. There is a paucity of information in the literature pertaining to its management. An ileal J pouch patient with dyschezia presented to our Pouch Center. Under sedation, pouchoscopy was performed with a gastroscope. We detected an anterior distal pouch mucosal prolapse, 1.5 cm in diameter, blocking the anal canal. The prolapsed mucosa was excised with hot snare under a retroflex view. There was no bleeding or perforation. The entire procedure took 25 minutes. The patient tolerated the procedure well and was discharged home 30 minutes after post-procedural observation. The patient reported the resolution of the dyschezia symptom. The histopathological examination of excised specimen showed small bowel mucosa and sub-mucosa with changes compatible with mucosal prolapse. Endoscopic hot snare appears to be feasible in the management of pouch mucosal prolapse.

© 2013 Elsevier Editora Ltda. All rights reserved.

Tratamento de prolapso da bolsa ileal com alça diatérmica endoscópica

RESUMO

O prolapso da bolsa ileal é uma complicação que pode surgir após a criação da proctocolectomia restauradora. As informações na literatura são escassas quanto ao tratamento. Um paciente com bolsa ileal em "J" e apresentando disquezia deu entrada em nosso centro médico. Sob sedação, realizamos uma endoscopia da bolsa ileal. Detectamos uma bolsa distal anterior com prolapso da mucosa, com 1,5 cm de diâmetro, bloqueando o canal anal. O prolapso da mucosa foi retirado com alça diatérmica sob visão retroflexa. Não houve sangramento ou perfuração. A duração de todo o processo foi de 25 minutos. O paciente tolerou bem o procedimento e recebeu alta após 30 minutos de observação pós-procedimento. O paciente relatou a resolução do sintoma de disquezia. O exame histopatológico do espécime extirpado mostrou a mucosa e submucosa do intestino delgado com alterações compatíveis com o prolapso da mucosa. A alça diatérmica endoscópica parece ser viável no tratamento de prolapso da mucosa da bolsa ileal.

© 2013 Elsevier Editora Ltda. Todos os direitos reservados.

* Corresponding author.

E-mail: shenb@ccf.org (B. Shen)

Introduction

Restorative proctocolectomy with ileal pouch-anal anastomosis (IPAA) has become the procedure of choice for patients with ulcerative colitis (UC) and familial adenomatous polyposis (FAP) who require colectomy. This bowel-anatomy-altering surgery reduces the risk for colitis-associated neoplasia and improves patients' health-related quality of life (QOL) by preserving the natural route of defecation. On the other hand, IPAA carries a significant risk for various complications. Pouch prolapse has been recently described.^{1,2} However, there is a paucity of information in the literature pertaining to its management. Here we reported on a patient who developed mucosal prolapse in the distal pouch and was successfully managed by endoscopic hot snare therapy.

Case report

A 62-year-old male presented to our Pouch Center with a 6-month history of the sensation of incomplete evacuation in February 2012. His past medical history was significant for UC which was diagnosed at age 29. Subsequently, he developed medically refractory disease and underwent a two-stage J pouch surgery at an outside hospital in 1998. Both surgery and hospitalization were uneventful. Postoperatively, the patient had an average of 12 bowel movements a day which were watery and soft, and occasionally had nocturnal symptoms with mild incontinence.

At the presentation, we performed pouchoscopy, which revealed distal pouch mucosal prolapse, blocking the anal canal during the suction of the air. Anorectal manometry was unremarkable, with an average of resting and squeeze pressure of 41 mmHg (normal level: > 40 mmHg) and 185 mmHg (normal level: > 100 mmHg), respectively. There were no paradoxical contractions and the patient was able to expel a 50-mL balloon. His barium defecography showed complete emptying of the J pouch. No specific treatment was given at the time point.

The patient went back to our Pouch Center for follow-up visit four months later, when he complained of the progression of dyschezia symptoms, with the need to push on the abdomen in order to pass the bowel movement. The patient was taken to the outpatient endoscopy suite. Informed consent was obtained. Under sedation, a repeat pouchoscopy was performed with a GIF-H180 gastroscope (Olympus, Tokyo, Japan). The afferent limb, pouch inlet, and proximal and mid pouch body, and anal transitional zone were normal. However, we again found the anterior distal pouch mucosal prolapse, 1.5 cm in diameter, blocking the anal canal. We believed that the structural abnormality was the source of his dyschezia symptom. The prolapsed mucosa was excised with a hot snare (Boston Scientific, MA, USA) on a retroflex view (Fig. 1). There was no bleeding or perforation. As a safety precaution, we applied two Endoclips (Wilson-Cook, Winston-Salem, NC, USA) in the area. The entire procedure took 25 minutes. The total dose of merperidine was 100 mg and midazolam 4 mg. The patient tolerated the procedure well and was discharged home 30 minutes after post-procedural observation. The patient continued to do well and reported the resolution of the dyschezia symptom. The histopathological examination

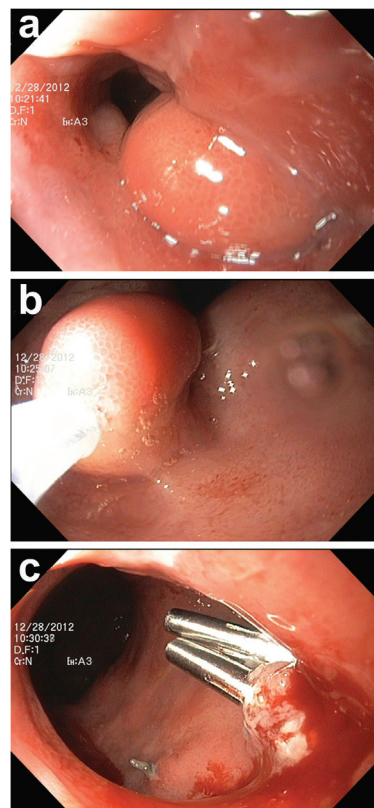


Fig. 1 – Pouch mucosal prolapse: (a) endoscopic appearance of the pouch mucosal prolapse; (b) removal of prolapsed mucosa with hot snare; and (c) two endoclips were deployed after the procedure.

of excised specimen showed small bowel mucosa and sub-mucosa with congestion, villous blunting, and reactive loss of mucin, which were compatible with mucosal prolapse.

Discussion

Mucosal or full-thickness prolapse is a structural or mechanical complication of pelvic ileal pouches. The disease entity was first reported in 1994³. In 2004, a survey sent to all members and fellows of the American Society of Colon and Rectal Surgeons showed a total of 83 cases of ileal pouch prolapse out of 23,541 pouches, with a prevalence of 0.4%.¹ In 2010, we reported 11 cases (0.3%) of pouch prolapse out of 3,176-case Pouch Registry at our institution.² It is speculated that this condition may be partly due to the tension of mesentery of the pouch.

The disease course and management of ileal pouch prolapse are yet to be elucidated. The most commonly symptoms are external prolapse of tissue, sensation of incomplete evacuation, dyschezia, seepage, incontinence, and anal pain.^{1,2} Some of those symptoms may mimic that seen in levator ani syndrome. The management of mucosal or full-thickness ileal pouch prolapse may be different, but no treatment algorithm is established. Patients with full-thickness prolapse frequently require definitive surgical treatment. The reported surgical procedures include pouchpexy with or without biological mesh, redo pouch construction, and pouch excision with permanent

diversion.^{1,2,4-6} Patients with mucosal prolapse can be initially managed with stool bulking agents, bio-feedback treatment, mucosal banding or local transanal excision of redundant mucosa.¹⁻³ However, when patients fail these therapies or progress to full-thickness prolapse, definitive surgical management may be applied. In our case, ileal pouch prolapse was diagnosed based on a combined assessment of symptoms and endoscopic and histologic findings. To the best of our knowledge, ours is the first case in the literature, which showed the feasibility of management of pouch mucosal prolapse with endoscopic hot snare. Endoscopic management has benefits of being minimally invasive, and easy to perform. No hospitalization is required and the patient had a quick recovery. However, this procedure needs to be done in experienced hands.

In conclusion, endoscopic hot snare appears to be feasible in the management of mucosal prolapse in the ileal pouch reservoir.

Conflict of interest

The authors declare no conflicts of interest.

REFERENCES

1. Ehsan M, Isler JT, Kimmins MH, Billingham RP. Prevalence and management of prolapse of the ileoanal pouch. *Dis Colon Rectum*. 2004;47: 885-888.
2. Joyce MR, Fazio VW, Hull TT, Church J, Kiran RP, Mor I, et al. Ileal pouch prolapse: prevalence, management, and outcomes. *J Gastrointest Surg*. 2010;14: 993-997.
3. Blazeby JM, Durdey P, Warren BF. Polypoid mucosal prolapse in a pelvic ileal reservoir. *Gut*. 1994;35: 1668-1669.
4. Williams NS, Giordano P, Dvorkin LS, Huang A, Scott SM. Full-thickness pouch prolapse after restorative proctocolectomy: a potential future problem treated by the new technique of external pelvic neorectal suspension (the Express procedure). *Dis Colon Rectum*. 2004;47: 1415-1419.
5. Funayama Y, Fukushima K, Shibata C, Takahashi K, Sasaki I. Transabdominal repair of prolapsed pelvic ileal J-pouch after restorative proctocolectomy. *Int J Colorectal Dis*. 2005;20: 553-554.
6. Ragupathi M, Patel CB, Ramos-Valadez DI, Haas EM. Robotic-assisted laparoscopic "salvage" rectopexy for recurrent ileoanal J-pouch prolapse. *Gastroenterol Res Pract*. 2010;2010: 790462.