



# Journal of Coloproctology

www.jcol.org.br



## Original Article

# Anatomical characteristics of anal fistula evaluated by three-dimensional anorectal ultrasonography: is there a correlation with Goodsall's theory?



Sthela Maria Murad-Regadas<sup>a,\*</sup>, Iris Daiana Dealcanfreitas<sup>b</sup>,  
Maura Tarciany Coutinho Cajazeiras de Oliveira<sup>c</sup>, David Pessoa Morano<sup>d</sup>,  
Francisco Sérgio P. Regadas<sup>e</sup>, Lusmar V. Rodrigues<sup>f</sup>,  
Graziela Olivia da Silva Fernandes<sup>b</sup>, Francisco Sérgio P. Regadas Filho<sup>b</sup>

<sup>a</sup> Department of Surgery, Medicine School, Universidade Federal do Ceará (UFC), Fortaleza, CE, Brazil

<sup>b</sup> Universidade Federal do Ceará (UFC), Fortaleza, CE, Brazil

<sup>c</sup> University School of Medicine Hospital, Universidade Federal do Ceará (UFC), Fortaleza, CE, Brazil

<sup>d</sup> Santa Casa de Misericórdia, Universidade Federal do Ceará (UFC), Fortaleza, CE, Brazil

<sup>e</sup> Department of Digestive System, Medicine School, Universidade Federal do Ceará (UFC), Fortaleza, CE, Brazil

<sup>f</sup> Service of Coloproctology, Medicine School, Universidade Federal do Ceará (UFC), Fortaleza, CE, Brazil

## ARTICLE INFO

### Article history:

Received 29 December 2014

Accepted 20 February 2015

Available online 20 April 2015

### Keywords:

Transsphincteric fistula

Goodsall's rule

Three-dimensional anorectal ultrasonography

## ABSTRACT

**Purpose:** We aimed to correlate the course of the anal fistula tract (T), location of the external opening (EO) and internal opening (IO) in anterior (A) and posterior (P) circumference using 3D-US according to Goodsall's rule.

**Methods:** 151 patients with primary cryptoglandular Transsphincteric fistulas were examined with 3D-US and compared with surgical finding. The type of the T (straight or curved), EO and IO were identified and divided into 3 Groups: GI: EO and IO are located in a position; GII: EO and IO are located in P position and GIII: OE and OI are located in the opposite position. The findings were correlated with Goodsall's rule.

**Results:** 74/151(49%) were included in GI, of them, 41 (55%) were male (33/44% had straight tract and 8/11% curved) and 33 (45%) female (15/20%-straight and 18/25%-curved). GII included 68 (45%), of them, 50 (74%) were male (39/57%-straight and 11/15%-curved) and 18 (26%) female (14/20%-straight and 04/8%-curved). GIII = 9 (6%) and all of them had curved tract. The overall concordance between 3D-US and surgical finding was 98% for tract and 96% for IO.

\* Corresponding author.

E-mail: [smregadas@hospitalsaocarlos.com.br](mailto:smregadas@hospitalsaocarlos.com.br) (S.M. Murad-Regadas).

<http://dx.doi.org/10.1016/j.jcol.2015.02.006>

2237-9363/© 2015 Sociedade Brasileira de Coloproctologia. Published by Elsevier Editora Ltda. All rights reserved.

**Conclusion:** The 3D-US findings correlate with the Goodsall's rule in transsphincteric fistulas located in the anterior circumference straight type, in male, while in females the distribution of curved and straight paths is similar. In the posterior circumference no correlation was observed in both the sexes.

© 2015 Sociedade Brasileira de Coloproctologia. Published by Elsevier Editora Ltda. All rights reserved.

## Características anatômicas da fístula anal avaliadas por Ultrassonografia Anorretal Tridimensional: Há correlação com a teoria de Goodsall?

### R E S U M O

#### Palavras-chave:

Fístula transesfínctérica  
Teoria de Goodsall  
Ultrassonografia anorretal  
tridimensional

**Objetivo:** Correlacionar o trajeto (T) da fístula anal, localização do orifício externo (OE) e orifício interno (OI) na hemicircunferência anterior (HCA) e posterior (HCP), utilizando 3D-US, com a lei de Goodsall.

**Método:** 151 pacientes com fístulas transesfínctéricas criptoglandulares foram examinados com US-3D correlacionando com os achados cirúrgicos. Identificou-se o tipo de T (retilíneo ou curvo), OE e OI e distribuiu-se os pacientes em 3 grupos: GI:OE e OI localizados em HCA; GII:OE e OI localizados em HCP e GIII:OE e OI em posições opostas. Os achados foram correlacionados com a lei de Goodsall.

**Resultados:** 74/151(49%) incluídos no GI, destes, 41(55%) homens(33/44% com trajeto retilíneo e 8/11% curvo) e 33(45%) mulheres(15/20%-retilíneo e 18/25%-curvo). No GII incluídos 68(45%), destes, 50(74%) homens(39/57%-retilíneo e 11/15%-curvo) e 18(26%) mulheres(14/20%-retilíneo e 04/8%-curvo). GIII = 9(6%) todos os trajetos curvos. A concordância entre o US-3D e os achados cirúrgicos foi de 98% para trajetos e 96% para o OI.

**Conclusão:** Os achados ultrassonográficos permitiram correlacionar fístulas transesfínctéricas com trajetos retilíneos localizadas na hemicircunferência anterior, em homens, enquanto em mulheres a distribuição dos trajetos em curvo e retilíneo foram similares. Na hemicircunferência posterior não houve correlação em ambos os sexos.

© 2015 Sociedade Brasileira de Coloproctologia. Publicado por Elsevier Editora Ltda. Todos os direitos reservados.

## Introduction

A perianal, or anal, or *per anus*, fistula is defined as an anomalous pathway linking two epithelia from different origins. This defect is characterized by three basic components: internal opening (IO), fistulous tract (FT) and external opening (EO).<sup>1</sup> More often, the perianal fistula results from an infectious and inflammatory process with its origin in the cryptoglandular area.<sup>1,2</sup> This condition depends on a medical treatment that aims to prevent recurrence and damage to sphincter muscles. Thus, an anatomical knowledge of the perianal region, an understanding of the pathophysiology of the disease and an accurate and appropriate surgical planning are essential.

The extent of the fistulous path is variable and can compromise several anatomical structures in the anorectal region. The most often used classification for fistulae was proposed by Parks et al.,<sup>3</sup> relating the extent of the fistulous path with sphincteric muscles involved, and the defect is classified into four main types: intersphincteric, transsphincteric, suprasphincteric and extrasphincteric. Proctologic examination is the first propaedeutic measure, but this may not allow a correct classification of fistulae and can miss deep fistulae and the visualization of the internal opening.<sup>4</sup> David Henry Goodsall's

clinical observations, aiming to define the course of anal fistulae, led to the formulation of a rule that came to bear his name (Goodsall's rule), indicating that OEs situated posteriorly to a transverse line drawn across the center of the anal canal drain toward an IO located at 6 h (i.e., form a curved-path type). On the other hand, OEs situated anteriorly to this line drain for an IO radially located (i.e., form a straight-type path).<sup>5</sup> Goodsall's original observations were listed at the meeting of the West London's Medical and Chirurgical Society on May 6, 1887 by Edwards<sup>6</sup> and afterwards were universally accepted and published in the form of Goodsall's "rule" or "law". Although this rule is useful, some studies have shown variable results for primary fistulae.<sup>7,8</sup>

Recent technological advances have allowed a careful complementary evaluation, using imaging methods such as anorectal ultrasonography, especially the three-dimensional mode, and magnetic resonance imaging.<sup>9-15</sup> The 3D mode with automatic acquisition enables a mutiplanar assessment of the anal canal and rectum, as well as a detailed study of the anatomy of these anatomical structures, allowing the clinical application of three-dimensional ultrasound in the choice of surgical approach. Some studies have used this type of exam to assess patients with anal fistula, correlating the fistulous path to sphincter muscle, as well as the anatomical

details of the distribution of fistulous paths and the rate of muscle involvement in each hemicircumference and in both genders.<sup>14,15</sup>

Therefore, this study aims to evaluate the anatomic characteristics of the fistulous path and of the external and internal openings in patients with transsphincteric anal fistula using the three-dimensional anorectal ultrasound (US-3D), and correlate the findings with Goodsall's theory, with a comparison between genders.

## Method

From January 2010 to June 2013, 151 patients with transsphincteric anal fistulae from the Coloproctology Clinic, Hospital Universitário Walter Cantídio, Universidade Federal do Ceará (HUWC-UFC) and from the outpatient clinic, Coloproctology Center, Hospital São Carlos were prospectively evaluated. The study was approved by the Ethics Committee on Research of the Hospital Universitário Walter Cantídio. These patients were submitted to US-3D in the Coloproctology Center, Hospital São Carlos, and those patients with transsphincteric anal fistula of cryptoglandular origin, with identification of all its components, external opening, primary and secondary fistulous path, and internal opening, were included. Those patients with other benign or malignant anorectal diseases, sphincter muscle injury diagnosed by US-3D, previous colorectal/proctologic surgery, more than one internal opening, recurrent fistulae, and with intersphincteric, extrasphincteric and suprasphincteric fistula were excluded.

Patients were divided into 3 groups according to the position of EO and IO with respect to anal circumference, using positions of 3 and 9 hours (h), drawing a line through the anal canal, as proposed by Goodsall, with its division in an anterior hemicircumference (AHC) corresponding to the interval between 9 and 3 h (anus in the lithotomy position) and a posterior hemicircumference (PHC) corresponding to the interval between 3 and 9 h: Group I (EO and IO in AHC); Group II (EO and IO in PHC) and Group III (EO and IO in opposite hemicircumference – OHC). The data were evaluated for the position of EO and IO, path types (straight and curved) in each group, comparing genders (male – M and female – F), and correlating our findings with the Theory of Goodsall.

All patients underwent surgery, and US-3D findings were compared with intraoperative findings: type of path, location of the internal orifice, and identification of the secondary path. The concordance rate was calculated.

### Three-dimensional anorectal ultrasound

A Pro-Focus BK Medical (Herley, Denmark) ultrasound machine with a type 2052, 360-grade rotational transducer with frequency of 9–16 MHz and focal length ranging from 2.8 to 6.2 cm was used. This transducer provides automatic image acquisition in a proximal-distal direction in a 6.0-cm segment during 50 s. It is not necessary to move the transducer inside the rectum and/or anal canal. Acquisition of a sequence of numerous transaxial parallel images (0.25 mm) is obtained, resulting in a cube-shaped digitalized volumetric image with great mobility, enabling its analysis in multiple planes and in

real time. Thus, afterwards the examiner has the opportunity to review the test, as many times as necessary, which results in more information.

Our patients underwent rectal enema 2 h before the exam, with the procedure not requiring anesthetic sedation. They were initially placed in left lateral decubitus (Sims position). After a static inspection and identification of the external fistulous opening, digital rectal examination was held to evaluate the retrograde preparation. Then the transducer was introduced to the lower rectum. Two scans were acquired to evaluate the anatomy of the full anal canal, identifying path(s), internal orifice(s) and/or the presence of adjacent cavities, allowing the identification of transsphincteric fistulae, according to Parks et al.<sup>3</sup>

The first scan was done without application of hydrogen peroxide. At this stage, the fistulous path was ecographically represented by a hypoechoic image situated laterally to the sphincter muscle and crossing the external anal sphincter (EAS) and the internal anal sphincter (IAS) in transsphincteric fistulae. Secondary paths could be identified by proximal or distal extensions of the main path. The internal fistulous orifice corresponded to a rupture image in IAS (in the absence of prior sphincterotomy) and to a hypoechoic image in subepithelial tissue.

The second scan was obtained after EO catheterism with a vascular catheter (intracath) and an injection of 0.3–1.0 mL of 10% hydrogen peroxide (H<sub>2</sub>O<sub>2</sub>) in all cases. The presence of H<sub>2</sub>O<sub>2</sub> in contact with the inflamed tissue produces air bubbles, and the hypoechoic ultrasound images become hyperechoic images, with more enhancement.<sup>9,10,14,15</sup> All examinations were performed by a single coloproctologist experienced in this method.

### Statistical analysis

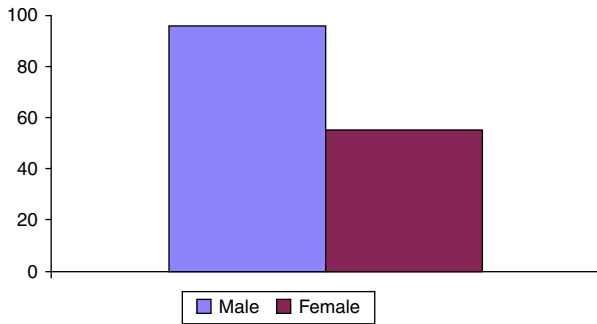
Statistical analyses were performed using SPSS version 17 for Windows®. Evaluation of data included descriptive statistics (mean, standard deviation, interquartile range). The analytical methods applied were Student's t-test and Fisher's exact test. The level of statistical significance was set at  $p < 0.05$ .

## Results

151 patients with transsphincteric anal fistula of cryptoglandular origin, aged from 18 to 74 years, with a mean age of 40.3 ( $\pm$  11.6) years, were evaluated. Of this total, 55 (36%) were women and 96 (64%) men (Fig. 1). Seventy-four (49%) patients (M: 41, F: 33) were included in G1; 68 (45%) (M: 50, F: 18) were included in G2; and 9 (6%) (M: 5, F: 4) were included in GIII (Table 1).

The fistulous path was straight in 103 (68%) (M: 74, F: 29) and curved in 48 (32%) (M: 22, F: 26) patients, with no statistical difference when compared to the type of path in each hemicircumference ( $p = 0.090$ ). However, a higher incidence of straight paths was evidenced in male patients ( $p = 0.006$ ), and a similar distribution between straight and curved paths was observed in female patients (Table 2).

In Group I, 48 (65%) patients (M: 33/44%; F 15/20%) had straight fistulous paths (Fig. 2), while 26 (35%) (M 8/11%,



**Fig. 1 – Prevalence of transsphincteric anal fistulae between genders.**

**Table 1 – Distribution of patients between genders according to the position of external and internal fistulous orifices in anterior and posterior hemicircumferences.**

Groups	Gender	
	Female	Male
GROUP 1	15 (20%)	33 (44%)
GROUP 2	04 (8%)	11 (15%)
GROUP 3	04 (%)	05 (%)

**Table 2 – Distribution of patients between genders according to fistula path type.**

Gender	Type of path	
	Straight	Curve
Female	29 (19%)	26 (17%)
Male	74 (49%)	22 (15%)

**Table 3 – Distribution of patients among groups according to fistula path type.**

Total = 151	Straight – 103 (68%)		Curve – 48 (32%)	
	Male	Female	Male	Female
Path type				
Group I (74)	33 (44%)	15 (20%)	8 (11%)	18 (25%)
Group II (68)	39 (57%)	14 (20%)	11 (15%)	04 (8%)
Group III (09)	02 (22%)	–	03 (33%)	04 (45%)

F: 18/25%) had curved paths (Table 3), and a higher incidence of straight paths in male patients was observed, compared to female patients ( $p=0.003$ ). However, in women the distribution of curved (see Fig 3) and straight paths was similar. Secondary paths were seen in 18 (24%) patients, of whom 50% were women.

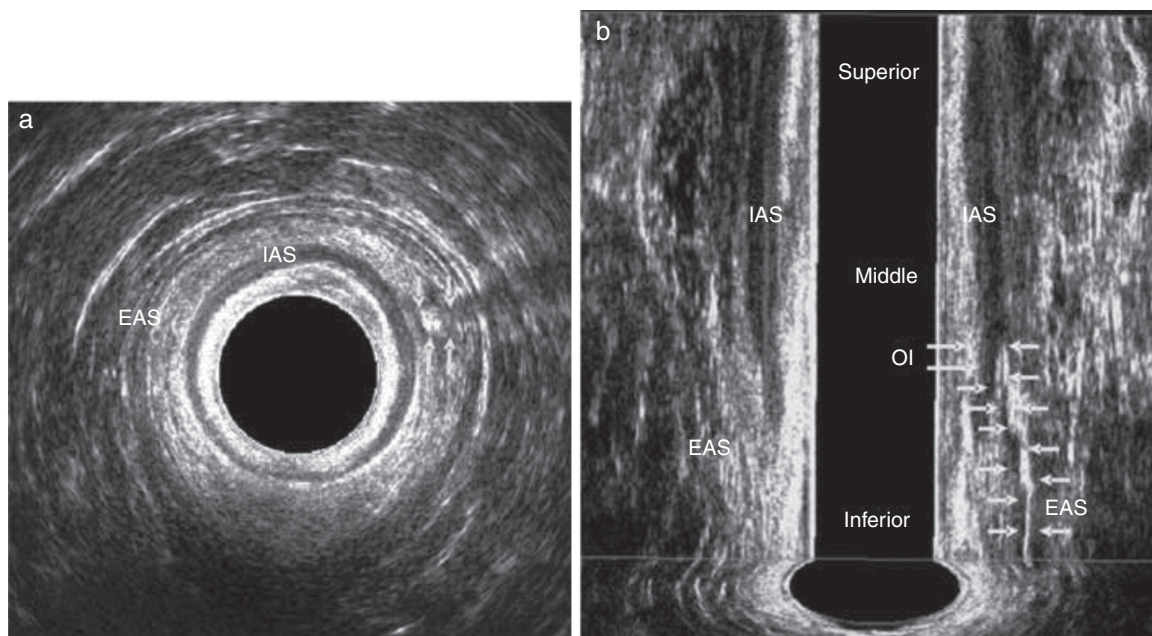
In Group II, 15 (22%) patients (M: 11/15% F: 4/8%) had curved paths, and 53 (78%) patients (M: 39/57%; F: 14/20%) had straight paths (Table 3 and Fig. 4). There was no statistical difference, regarding the presence of curved and straight paths, in the comparison between men and women. Secondary paths were seen in 17 (25%) patients, of whom 9 were men.

In Group III, all its 9 patients had curved paths (M: 5, F: 4) (Table 3). Secondary paths were observed in 4 (44%) patients, all of them females.

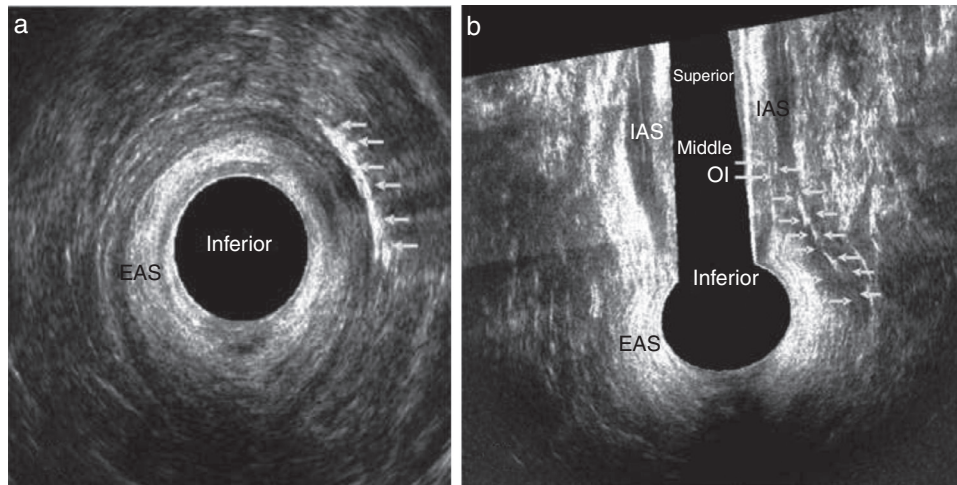
The concordance degree among US-3D and intraoperative findings was: primary path=99%, secondary path=98%, and internal opening=98%.

**Discussion**

The treatment of anal fistulae is a major challenge for the coloproctologist. Studies show high injury rates for fecal continence (18–82%) in patients undergoing surgical treatment



**Fig. 2 – Transsphincteric fistula in a male patient after application of hydrogen peroxide. Straight path located in anterior hemicircumference. EAS – external anal sphincter; IAS – internal anal sphincter. (a) Axial plane and (b) coronal plane.**



**Fig. 3 – Transsphincteric fistula in a female patient after application of hydrogen peroxide. Curved path located in anterior hemircumference. EAS – external anal sphincter; IAS – internal anal sphincter. (a) Axial plane and (b) coronal plane.**

resulting in section of sphincter muscle.<sup>14,16</sup> Therefore, a full assessment is necessary for a therapeutic conduct to be correctly chosen. Technological advances with complementary imaging methods have contributed to the understanding of the correlation between the fistulous complex and anal canal anatomy.<sup>14,15</sup>

The evaluation of any fistula starts with a proctologic exam, with the position of the external and internal fistulous openings relative to anal circumference. The “Goodsall’s rule” remains in use by a number of surgeons during the evaluation of anal fistulae in pre- and transoperative phases, often without evidence of concordance between rule and surgical findings, in an attempt to predict the type of path, as well as the internal opening localization, beginning from the location of the perianal external opening. Therefore, the evaluation with a complementary imaging method would help in choosing the therapeutic approach. Studies have shown that even fistulae described as simple, that is, with a superficial, subcutaneous or low transsphincteric path (representing approximately 95% of the treated fistulae), may present, after the fistulotomy, high complication rates due to the presence of secondary paths or flaws in the identification of the primary internal opening.<sup>17,18</sup> The attention on identifying the paths and their relationship to the anal sphincter improve the outcome of a subsequent surgical approach, and may result in less trauma to the sphincteric apparatus and, consequently, in lower morbidity for the patient.<sup>19</sup>

The aim of this study was to evaluate the anatomical characteristics of anal fistulae (of transsphincteric type) using US-3D and correlating its findings of EO and IO position and the type of path with Goodsall’s theory, with the confirmation by surgical findings. The selection of patients with transsphincteric fistulae for inclusion in this study is due to the higher prevalence of this type of defect in the study period, and the incidence of anal fistulae is greater in men by a ratio of 2:1 and in young adults with an overall mean age of 40 years – data similar to other studies in the literature.<sup>20</sup>

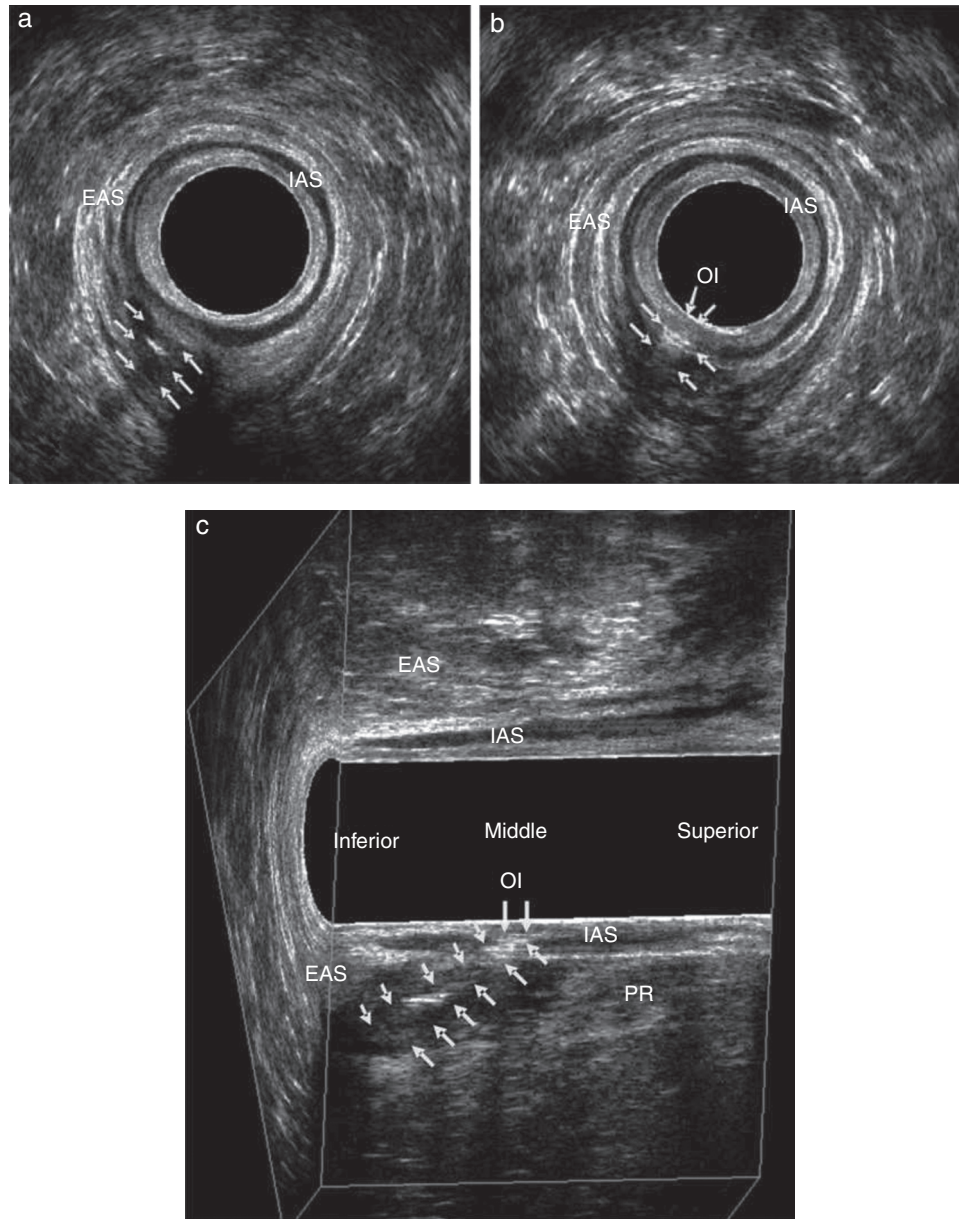
The Goodsall’s rule postulates that anterior fistulae have radial (straight) paths, which is consistent with the results of

this study when assessing males – the majority of our sample. However, for women a similarity between straight and curved paths was found. Cirocco and Rielly evaluated their intraoperative findings and correlated their results with the Goodsall’s rule, showing association in only 49% of anterior fistulae with radial paths, while 71% of this group of fistulae were presented with an internal opening in the middle line, with no straight paths, and including 4 cases of horseshoe fistulae. Therefore, even in fistulae of the anterior segment, which may seem simple conditions on physical examination, the preoperative ultrasonographic definition can avoid surprises for the surgeon. In the present study, a higher correlation with anterior fistulae was noted, and 65% of paths were of straight type; of these, 44% affected men and only 20%, women.

In this series, there was no evidence of correlation of posterior paths with Goodsall’s rule in both genders, with predominance of straight paths; Cirocco and Reilly showed that Goodsall’s rule was accurate in describing the path of anal fistulae with posterior external opening, both in male and female subjects (90% of 124 patients; 87% of men and 97% of women with posterior external opening had their path toward posterior midline).

The results of this study did reveal neither a complete correlation with Goodsall’s rule nor with the results presented by Cirocco and Reilly, comparing patients with anal fistula with this rule. This is due to the complexity of fistulae, making it difficult to characterize these defects as simple or complex, according to the position of their orifices with the anal circumference. Therefore, our data suggest the elimination of the distinction between anterior and posterior fistulae as of the type of path presented. Each fistula shows the distribution of its components (OE, OI and FT) differently, not following a single rule.

An additional assessment is mandatory, with imaging procedures that can shed light on important aspects of the fistulous complex, enabling to plan the type of surgical approach. The advantage of US-3D with automatic acquisition and multiplanar evaluation is based not only on the definition of type of path (curved or straight), but also in its relationship with



**Fig. 4 – Transsphincteric fistula in a male patient after application of hydrogen peroxide. Straight path located in posterior hemicircumference. EAS – external anal sphincter; IAS – internal anal sphincter; PR–puborectal. (a) Axial plane – path, (b) axial plane – internal opening and (C) paramedian sagittal plane.**

sphincter muscle. This enables the classification of fistulae according to Parks et al.<sup>3</sup> and the identification of secondary paths (in this study, secondary paths were identified in 14% of patients). This complementary assessment also allows an evaluation of the portion of musculature involved by the fistulous path, and the quantification of muscle tissue that will be severed during surgery.<sup>14</sup> Taken together, all these data will characterize the fistula as complex or simple, and will serve as guidance in the choice of treatment, in order to prevent recurrence and to preserve sphincter function. Likewise, the position of the fistula (anterior or posterior) could have greater importance relative to sphincteric muscle distribution, which shows differences when comparing anterior versus posterior hemicircumference.<sup>20,21</sup> In studies evaluating the anal canal

of normal patients of both genders, the distribution of sphincteric musculature was studied, and the smaller length of the anal sphincter in women was evidenced, which characterizes more complex fistulae, especially those located in the anterior quadrant.<sup>14,21</sup>

The anorectal ultrasound has been widely used to assess anal fistulae and to identify components of the fistulous complex using bi- and tri-dimensional modes, with the use of hydrogen peroxide for image enhancement, for confirming findings. In the literature, the comparison of ultrasound in its different modalities with transoperative findings showed good results for the identification of the primary path, ranging from 61 to 100% and, with the use of hydrogen peroxide, from 77 to 98%. In the identification of the secondary path,

the results ranged from 65 to 100% and, with the use of hydrogen peroxide, from 71 to 99%. For internal opening, the results ranged from 64 to 96% and, with the use of hydrogen peroxide, from 77–98% to 54–97%.<sup>22–24</sup> The results of the study were similar to those in the literature, with high correlation with transoperative findings.

The choice of US-3D is due to the ease of carrying out the procedure by a colorectal surgeon, as all patients with an anal fistula are evaluated preoperatively with this imaging method in this institution. Another option, magnetic resonance imaging, is a more costly method, and is performed by a radiologist. This method should be used in doubtful cases.<sup>13</sup> This is the first study to correlate anal fistula components with Goodsall's rule using US-3D and intraoperative findings.

The number of patients included in this study is clinically relevant, and here we emphasize the importance of a full evaluation with US-3D by a single evaluator with experience in this method and the uniqueness of patients operated by a team of three trained colorectal surgeons. However, these are patients with only one type of fistula (transsphincteric). Further studies are needed, with inclusion of intersphincteric fistulae, or still, with the study of patients with another imaging method, such as magnetic resonance imaging.

## Conclusion

In conclusion, our ultrasound findings correlate with Goodsall's theory for anterior hemicircumference, straight-type, fistulae in men, while in women the distribution of curved and straight paths is similar. On the other hand, in posterior hemicircumference no correlation was observed in both genders. US-3D showed high correlation with intraoperative findings.

## Conflicts of interest

The authors declare no conflicts of interest.

## REFERENCES

- Corman ML. *Colon and rectal surgery*. 2nd ed. Philadelphia: J.B. Lippincott; 1989. p. 137.
- Hamalainen KP, Sainio AP. Incidence of fistulas after drainage of acute anorectal abscesses. *Dis Colon Rectum*. 1998;41:1357–61.
- Parks AG, Gordon PH, Hardcastle JD. A classification of fistula-in-ano. *Br J Surg*. 1976;63:1–12.
- Buchanan GN, Halligan S, Bartram CI, Williams AB, Tarroni D, Cohen CR. Clinical examination, endosonography and MR imaging in preoperative assessment of fistula in ano: comparison with outcome-based reference standard. *Radiology*. 2004;233:674–81.
- Goodsall DH, Miles WE. Ano-rectal fistula. In: Goodsall DH, Miles WE, editors. *Diseases of the anus and rectum*. London: Longmans, Green & Co.; 1990. p. 92–137.
- Edwards FS. Some of the rarer forms of rectal fistulae. *Lancet*. 1887;1:1089.
- Cirocco WC, Reilly JC. Challenging the predictive accuracy of Goodsall's rule for anal fistulas. *Dis Colon Rectum*. 1992;35:537–42.
- Gunawardhana PA, Deen KI. Comparison of hydrogen peroxide instillation with Goodsall's rule for fistula-in-ano. *ANZ J Surg*. 2001;71:472–4.
- Navarro-Luna A, García-Domingo MI, Rius-Macías J, Marco-Molina C. Ultrasound study of anal fistulas with hydrogen peroxide enhancement. *Dis Colon Rectum*. 2004;47:108–14.
- Sudol-Szopinska I, Szczepkowski M, Panorska AK, Szopinski T, Jakubowski W. Comparison of contrast-enhanced with noncontrast endosonography in the diagnostics of anal fistulas. *Eur Radiol*. 2004;14:2236–41.
- West RL, Dwarkasing S, Felt-Bersma RJ, et al. Hydrogen peroxide-enhanced three-dimensional endoanal ultrasonography and endoanal magnetic resonance imaging in evaluating perianal fistulas: agreement and patient preference. *Eur J Gastroenterol Hepatol*. 2004;16:1319–24.
- Ratto C, Grillo E, Parello A, Costamagna G, Doglietto GB. Endoanal ultrasound-guided surgery for anal fistula. *Endoscopy*. 2005;37:722–8.
- Sun MR, Smith MP, Kane RA. Current techniques in imaging of fistula in ano: three-dimensional endoanal ultrasound and magnetic resonance imaging. *Semin Ultrasound CT MRI*. 2008;29:454–71.
- Murad-Regadas SM, Regadas FSP, Rodrigues LV, Holanda EC, Barreto RGL, Leticia O. Role of three-dimensional anorectal ultrasonography in the assessment of anterior transsphincteric fistula. *Dis Colon Rectum*. 2010;53:1035–40.
- Murad-Regadas SM, Regadas FSP, Rodrigues LV, et al. Anatomic characteristics of anal fistula on three-dimensional anorectal ultrasonography (3-DAUS). *Dis Colon Rectum*. 2011;54:460–6.
- Ommer A, Wenger FA, Rolfs T, Walz MK. Continence disorders after anal surgery: a relevant problem? *Int J Colorectal Dis*. 2008;23:1023–31.
- Sangwan YP, Rosen L, Riether RD, Stasik JJ, Sheets JA, Khubchandani IT. Is simple fistula-in-ano simple? *Dis Colon Rectum*. 1994;37:885–9.
- Ahmed A, Abou-Zeid. Anal fistula: intraoperative difficulties and unexpected findings. *World J Gastroenterol*. 2011;17:3272–6.
- Garcia-Aguilar J, Belmonte C, Wong WD, Goldberg SM, Madoff RD. Anal fistula surgery: factors associated with recurrence and incontinence. *Dis Colon Rectum*. 1996;39:723–9.
- Williams AB, Bartram CI, Halligan S, Marshall MM, Nicholls RJ, Kmiot WA. Multiplanar anal endosonography – normal anal canal anatomy. *Colorectal Dis*. 2001;3:169–74.
- Regadas FS, Murad-Regadas SM, Lima DM, et al. Anal canal anatomy showed by three-dimensional anorectal ultrasonography. *Surg Endosc*. 2007;21:2207–11.
- Gustafsson UM, Kahvecioglu B, Astrom G, et al. Endoanal ultrasound or magnetic resonance imaging for preoperative assessment of anal fistula: a comparative study. *Colorectal Dis*. 2001;3:189–97.
- Navarro A, Rius J, Collera P, et al. Anal fistulas: results of ultrasonographic studies. *Dis Colon Rectum*. 1998;41:A57.
- Deen KI, Williams JG, Hutchinson R. Fistulas in ano: endoanal ultrasonographic assessment assists decision making for surgery. *Gut*. 1994;35:391–4.