



Original Article

Association of fecal occult blood tests results with colonoscopic findings in a general hospital and validation of the screening test



Ana Flávia Saraceni^{a,*}, Rodrigo Azevedo^a, Clarissa Maria Gomes Almeida^b,
Antônio Carlos Baraviera^a, Desiderio Roberto Kiss^a, Maristela Gomes Almeida^a

^a Complexo Hospitalar Professor Edmundo Vasconcelos, São Paulo, SP, Brazil

^b Faculdade de Medicina do ABC (FMABC), Santo André, SP, Brazil

ARTICLE INFO

Article history:

Received 17 September 2018

Accepted 30 October 2018

Available online 23 November 2018

Keywords:

Colonoscopy

Fecal occult blood test

Polyps

Adenoma

Adenocarcinoma

ABSTRACT

Globally, colorectal cancer is the third leading cause of cancer death among men and the second among women, corresponding to about 10% of all cancers. The Brazilian Ministry of Health and National Cancer Institute recommend the screening of colorectal cancer for people over 50 years-old with Fecal Occult Blood Test. Endoscopy is limited to patients with positive screening results. The aim of this study is to evaluate the incidence of malignant or premalignant lesions diagnosed by endoscopy in patients with positive or negative Fecal Occult Blood Test and assess the efficacy of Fecal Occult Blood Test to predict the finding of a malignant colorectal lesion. We carried out a cross-sectional study among patients with a Fecal Occult Blood Test result that were submitted to colonoscopy, in the same hospital, from March 2016 to July 2017. Sensitivity, specificity, positive and negative predictive value of Fecal Occult Blood Test compared to colonoscopy neoplastic findings was calculated. The total of 92 patients were enrolled, 52 (56.5%) were female, Fecal Occult Blood Test was positive in 42.4% of them and in 41 (44.6%) the colonoscopy showed abnormal findings. Polyps were the most frequent alteration, found in 20 patients (21.7%). Among the patients with polyps, 15 (16.3%) had neoplastic and 5 (5.4%) presented non-neoplastic polyps. The Fecal Occult Blood Test sensitivity for detection of neoplastic polyps was 66.7%, specificity 62.3%, positive predictive value 11% and negative predictive value was 94.2%. Considering the need for a screening method, Fecal Occult Blood Test showed to be an effective and reliable screening test that can be applied in public health programs to detect and prevent colorectal cancer.

© 2018 Sociedade Brasileira de Coloproctologia. Published by Elsevier Editora Ltda. This is an open access article under the CC BY-NC-ND license (<http://creativecommons.org/licenses/by-nc-nd/4.0/>).

* Corresponding author.

E-mail: anafsaraceni@yahoo.com.br (A.F. Saraceni).

<https://doi.org/10.1016/j.jcol.2018.10.011>

2237-9363/© 2018 Sociedade Brasileira de Coloproctologia. Published by Elsevier Editora Ltda. This is an open access article under the CC BY-NC-ND license (<http://creativecommons.org/licenses/by-nc-nd/4.0/>).

Achados colonoscópicos em pacientes submetidos a exame de sangue oculto nas fezes e validação deste teste de triagem

R E S U M O

Palavras-chave:

Colonoscopia

Pesquisa de sangue oculto nas fezes

Pólipos

Adenoma

Adenocarcinoma

Globalmente, o carcinoma colorretal é a terceira principal causa de morte por neoplasia entre homens e a segunda entre mulheres, correspondendo a 10% de todas as neoplasias. O Ministério da Saúde Brasileiro e o Instituto Nacional do Câncer recomendam a triagem do câncer colorretal para indivíduos acima de 50 anos, utilizando a Pesquisa de Sangue Oculto nas fezes. A endoscopia é reservada para aqueles com Pesquisa de Sangue Oculto nas fezes positiva. O objetivo deste estudo é avaliar a incidência de lesões malignas/pré-malignas diagnósticas na colonoscopia e correlacionar com os resultados prévios da Pesquisa de Sangue Oculto e verificar a eficácia da Pesquisa de Sangue Oculto para predizer uma lesão colorretal maligna. Realizamos um estudo transversal em pacientes que apresentavam resultados positivos ou negativos de Pesquisa de Sangue Oculto nas fezes e foram submetidos à colonoscopia, na mesma instituição, entre março de 2016 e julho de 2017. Dos 92 participantes; 52 (56,5%) eram do sexo feminino, a Pesquisa de Sangue Oculto nas fezes foi positiva em 42,4%; e em 41 (44,6%) a colonoscopia mostrou alterações. Em 20 pacientes (21,7%) havia pólipos; 15 (16,3%) eram neoplásicos e 5 (5,4%) não neoplásicos. A sensibilidade da Pesquisa de Sangue Oculto nas fezes para detecção de pólipos neoplásicos foi 66,7%; a especificidade 62,3%; o valor preditivo positivo 11% e o valor preditivo negativo 94,2%. Considerando a necessidade de um método de triagem, a Pesquisa de Sangue Oculto nas fezes mostrou ser um exame de triagem eficaz e confiável para ser aplicado em programas de saúde pública com o objetivo de detectar e prevenir o carcinoma colorretal.

© 2018 Sociedade Brasileira de Coloproctologia. Publicado por Elsevier Editora Ltda. Este é um artigo Open Access sob uma licença CC BY-NC-ND (<http://creativecommons.org/licenses/by-nc-nd/4.0/>).

Introduction

Globally, colorectal cancer is the third leading cause of cancer death among men and second among women. The incidence among men is 746,000 cases/year, and among women, 614,000 cases/year, corresponding to almost 10% of all cancers found in both sexes. From the total cases of colorectal cancer, 55% are diagnosed in countries with a high human development index, mainly in Europe, North America and Australia.¹ In Brazil, there were 16,660 new cases of colorectal cancer among men and 17,620 among women, in 2016, with a risk estimation of 16.84 new cases per 100,000 men and 17.10 for 100,000 women.¹ The incidence of colorectal cancer increases from the age of 50 and over and about 95% of them are derived from adenomas polypoid or planes.²

The symptoms of the disease appear in advanced stages in most patients, when morbidity and mortality are high and treatment expensive. Thus, the early diagnosis is needed to properly prevent and treat colorectal cancer. Considering the evolution from adenomatous polyps to adenocarcinoma takes in average 10 years, screening tests to identify malignant polyps of the population are an important step to early detection colorectal cancer and a priority to reduce mortality and treatment costs.^{2,3} In recent years, special attention has been given to the different modalities of colorectal cancer screening and their applications in populations with different grades of disease risks.⁴ Among the screening methods, the Fecal Occult Blood Test (FOBT), a lab test used to check stool samples for hidden hemoglobin, has aroused interest.⁵ The FOBT,

traditionally can be performed by the o-tolidine method and more recently by immunological methods,⁶ and is aimed to detect hidden blood characterized by the presence of human hemoglobin.⁷ If the test is positive, meaning that blood was detected, additional tests may be warranted to determine the source of the bleeding.

Colonoscopy has been widely accepted as a the gold standard method for polyps and pre-malignant colorectal lesions screening.⁸ Besides the precise diagnosis, the colonoscopy allows the removal of neoplastic polyps, reducing the incidence of colorectal cancer and changing the natural history of this disease.⁹ Although colonoscopy is considered a safe procedure, complications such as intestinal perforation, hemorrhage and cardiopulmonary damages, in response to sedation, can occur and increase de morbidity of the patient under examination. Inaccurate indications and abusive use of colonoscopy are recognized as reasons for the increased demand and overload of exams in public health centers. The precise indication, based on well-defined clinical criteria, is essential for an adequate cost-benefit ratio and to mitigate complications.¹⁰

The guidelines of the American Society of Gastrointestinal Endoscopy (ASGE) and the European Panel on Adequacy of Gastrointestinal Endoscopy II (EPAGE II) indicate colorectal cancer screening by colonoscopy, for asymptomatic patients with no family history of colorectal cancer older than 50 years every 10 years.^{3,10} The Brazilian Ministry of Health and the Brazilian National Institute of Health recommend the Fecal Occult Blood Test (FOBT) screening of colorectal cancer for people over 50 years-old and colonoscopy is limited to patients

with positive screening results. It is noteworthy that the colonoscopy use as a first screening method involves higher costs and is only accessible for a minority of Brazilians who have a private health insurance.⁷ Nevertheless, larger studies using the FOBT for colorectal cancer screening consistently indicate a reduction in cancer mortality up to 15%–33%.¹¹

The aim of this study is to evaluate the incidence of malignant or premalignant lesions diagnosed by colonoscopy in patients with positive or negative FOBT and assess the efficacy of FOBT to predict the finding of a malignant colorectal lesion.

Materials and methods

Study design, setting and ethical considerations

We carried out a cross-sectional study among patients who had a FOBT result registered in the hospital laboratory data system and were further submitted to a colonoscopy, in the Coloproctology Service of Complexo Hospitalar Edmundo Vasconcelos, from March 2016 to July 2017.

Complexo Hospitalar Edmundo Vasconcelos is a tertiary private hospital located in São Paulo, Brazil. The hospital has 220 beds, performs approximately 1000 FOBT and 1500 colonoscopies per year and has several clinical and surgical specialties.

The study was approved by the Ethical Committee of Complexo Hospitalar Edmundo Vasconcelos, the ethical review board of the institution.

Subjects and sampling

All the results of the FOBT from patients with 18 years-old and over submitted were reviewed in the study period. From the total, those patients with FOBT results who underwent colonoscopy in the same period were included. Each patient's clinical chart was assessed to check the patient's age, gender, the FOBT result, abnormal findings in colonoscopy, histopathologic results of biopsied polyps and tissues, and any other bowel lesion. Patients were excluded if the cecum could not be visualized during the colonoscopy or bowel cleansing was inadequate.

Measurements

Occult Blood – iFOB/immunochromatography method

The Occult Blood Kit-iFOB is a rapid and a lateral flow immunochromatographic test for the qualitative detection of fecal occult blood. It can be used as a screening test, aiding in the detection of bleeding caused by gastrointestinal disorders, such as diverticulitis, colitis, polyps and colorectal cancer. Do not use visible blood sample like menstrual bleeding, hemorrhoid bleeding, constipation bleeding or urinary bleeding. The test is only for human fecal sample and exclusive for in vitro diagnostic use. Food restrictions are not required. The sensitivity of the test is 100% and the accuracy is 99%. The analytical sensitivity of the test is 50 ng hHb/mL buffer or 7 µg hHb/g feces.¹²

The Occult Blood Kit-iFOB should be used as an aid in diagnosis and should not replace other procedures necessary for an accurate diagnosis. A positive result can be used as a diagnostic parameter, but requires additional confirmation to determine the exact fecal occult blood origin.¹²

The test device consists of: (1) A conjugate carrier containing human anti-hemoglobin (anti-hHb) monoclonal antibody labeled with colloidal gold (conjugated anti-hHb); (2) A strip of nitrocellulose membrane containing a Test line (T line) and a Control line (line C). T-line has immobilized anti-hHb monoclonal antibody, and line C anti-mouse IgG goat antibody. When a sufficient volume of sample is placed in the sample well of the test device, it migrates by capillarity therethrough. In the presence of Human Hemoglobin (hHb) in a concentration greater than or equal to 50 ng/mL, it will bind to the conjugated antibodies, forming immunocomplexes. Immunocomplexes are then captured by membrane immobilized antibodies, forming a reddish colored line in the Test line (T), which indicates a positive test result for fecal occult blood. The absence of the T line suggests that the hHb concentration in the sample is below the detectable level indicating a negative result. The test contains an internal Control (line C), which should have a reddish colored line due to immunocomplex formation between the conjugate and the immobilized antibody, regardless of the presence of hHb in the sample. If line C does not appear, the test result is invalid and the sample must be tested again with another device.¹²

Colonoscopy

The colonoscope used for the examination is the Olympus CF180. Colonoscopy technics occurs in a conventional manner after the colon preparation with bisacodyl on the eve of the test and with 10% mannitol on the day of examination. The lesions excision occurs in all plausible cases of resectability, with delivery material for pathology. If it is impossible to remove the lesion, a biopsy is carried out and the sample is sent for pathological anatomy.

Statistical analysis

The database was created using the Excel-Microsoft program, and then reviewed to verify its accuracy. Subsequently, the data were exported to statistical analysis. Quantitative variables were presented as mean, median, standard deviation, minimum, maximum, first quartile and third quartile. Qualitative variables were presented by absolute and relative frequency. Accuracy, sensitivity, specificity, positive predictive value and negative predictive value of the FOBT were calculated based on the prevalence of polyps, adenoma and adenocarcinoma. The reference prevalence was used from a former study also performed among patients from the same hospital. To calculate positive and negative predictive values the reference prevalence for polyps was 16.64%, for neoplastic polyps 10.36%, for adenomas 10.01% and, 0.30 for adenocarcinomas.¹³ The 95% Confidence Interval was calculated for each of these variables and the 5% was considered as a significant statistical difference.

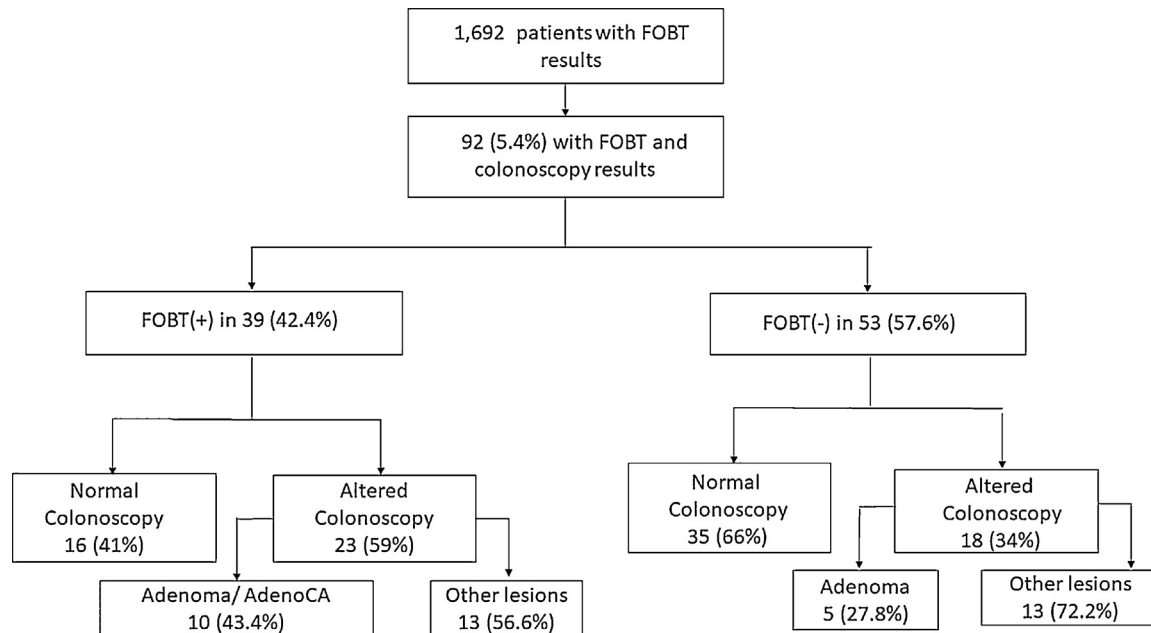


Fig. 1 – Flow chart FOBT.

Results

We retrieved the FOBT results of 1692 patients during the study period. Among them, 92 (4.3%) patients have also been submitted to a colonoscopy, 52 (56.5%) were women and 40 (43.5%) were men. The mean age \pm SD was 61.66 ± 15.9 years-old, ranging from 33 to 92 years-old. The FOBT was positive in 39 (42.4%) patients and negative in 53 (57.6%); colonoscopies were normal in 51 (55.4%) and altered in 41 (44.6%). Polyps were found in 20 patients (21.7%) and in 21 (22.8%), other lesions were found, such as diverticulosis, angiodysplasia and actinic rectites. In 15 (16.3%) patients, polyps were neoplastic and in 5 (5.4%) non-neoplastic. Considering the distribution of polyps by gender we found 12 polyps (60%) among men and 8 polyps (40%) among women. Among men, 11 (91.6%) of the found polyps were neoplastic and among women 4 (50%). Histopathologic exam of the neoplastic polyps showed that 11 (12%) cases were adenoma (pre-malignant lesion) and 4 (4.3%) adenocarcinoma (Fig. 1).

The FOBT sensitivity to detect any polyp was 65% (95% CI 40.8%–84.6%), specificity 63.9% (95% CI 51.7%–74.9%), positive predictive value 16.9% (95% CI 11.4%–22.3%) and negative predictive value was 90.1% (95% CI 84.4%–95.8%).

The FOBT sensitivity to detect neoplastic polyps was 66.7% (95% CI 38.4%–88.2%), specificity 62.3% (95% CI 50.6%–73.1%), positive predictive value 11% (95% CI 6.9%–15%) and negative predictive value 94.2% (95% CI 89.9%–98.3%).

The sensitivity of FOBT to detect adenomas was 54.5% (95% CI 23.4%–83.3%), specificity 59.3% (95% CI 47.8%–70.1%), positive predictive value 9.3% (95% CI 4.2%–14.3%) and negative predictive value 92.1% (95% CI 87%–97.3%).

The FOBT sensitivity to detect adenocarcinomas was 100% (95% CI 39.8%–100%), specificity 60.2% (95% CI 49.2%–70.5%), positive predictive value 0.5% (95% CI 0.4%–0.6%) and negative

predictive value 100% (95% CI 100%–100%), since in this study there were no case of adenocarcinoma in patients with negative FOBT.

The FOBT accuracy was 64.1% for polyps (95% CI 53.5%–73.9%), 63% for neoplastic polyps (95% CI 52.3%–72.9%), 58.7% for adenomas (95% CI 47.9%–68.9%) and 62% for adenocarcinomas (95% CI 51.2%–71.9%). Table 1 shows the different FOBT sensitivity, specificity, positive and negative predict values and accuracy according to the colonoscopy finding.

Discussion

A screening method for colorectal carcinoma screening is undoubted needed. In Brazil other median or low-income countries, an ideal method should combine low price, easy execution, high sensitivity and social acceptance. When evaluating the existing resources, the FOBT becomes an attractive alternative.¹⁴ The FOBT showed to be a sensitive and specific screening method to predictive the presence of polyps, in general, neoplastic polyps and mostly adenocarcinomas. The FOBT showed a high negative predictive value and low positive predictive value to detect benign and malignant colorectal lesions with an accuracy to detect almost two out of three lesions.⁷

Former studies showed that the sensitivity for the FOBT varies from 45%–75%, specificity from 35%–94%, the positive predictive values from 10%–60% and the negative predictive values from 97%–99.5%.^{7,15} Our study showed similar results, and the high negative predictive value that we found can assure that a patient does not have a pre-malignant or malignant lesion if the FOBT result is negative.

Several studies reporting the use of the FOBT as a screening and monitoring method to identify patients with no risk factors for colorectal cancer have been published lately.^{7,16}

Table 1 – Sensitivity, specificity, positive predict value, negative predict value for lesions found during colonoscopy (n = 92).

Lesion	Prevalence %	Sensitivity		Specificity		PPV ^a		NPV ^b		Accuracy	
		%	95% CI ^c	%	95% CI	%	95% CI	%	95% CI	%	95% CI
Any polyp	16.64	65.0	40.8–84.6	63.9	51.7–74.9	16.9	11.4–22.3	90.1	84.4–95.8	64.1	53.5–73.9
Neoplastic polyps	10.36	66.7	38.4–88.2	62.3	50.6–73.1	11.0	6.9–15.0	94.2	89.9–98.3	63.0	52.3–72.9
Adenomas	10.01	54.5	23.4–83.3	59.3	47.8–70.1	9.3	4.2–14.3	92.1	87.0–97.3	58.7	47.9–68.9
Adenocarcinomas	0.30	100.0	39.8–100	60.2	49.2–70.5	0.5	0.4–0.6	100	100–100	62.0	51.2–71.9

^a Positive predict value.

^b Negative predictive value.

^c Confidence interval.

Some estimates that an annual FOBT can reduce colorectal cancer mortality by up to 16%.⁷ Since the FOBT is a low cost and non-invasive test its use as a screening method for colorectal cancer is useful to withdraw this diagnostic, even though colonoscopy is still acknowledged as the gold standard. However, in populations in which colonoscopy is not available, the FOBT can be used as a preventive examination in asymptomatic patients over 40 years with no risk for colorectal cancer.^{7,17}

When polyps are detected in the colonoscopy, they should be removed to histological exam, regardless of their size or morphology.¹⁸ Polypectomy reduces the incidence of colorectal cancer from 76% up to 90%.² We found and resected polyps in 13 out of 39 patients submitted to colonoscopy that previously presented a positive FOBT. Most of the polyps were malignant or pre-malignant and potentially could advance to a colorectal cancer. The natural history of colon and rectum cancer offers ideal conditions for prevention and early detection of the disease. Adenomas can evolve to a malignant lesion and precede colorectal cancer in 10–15 years.¹⁹ Screening programs for detection and removal of adenomas can interrupt the adenoma progression to cancer and diagnosis neoplasm at early stages, increasing the survival from 5 years to 90%.²⁰ Thus, algorithms including the FOBT and colonoscopy can help to improve colorectal cancer detection and prevention.

Our study has some limitations. Not all patients who performed FOBT and who had a positive test result necessarily returned for colonoscopy at our hospital service which may have limited our sample. The colonoscopy is dependent of the examiner; however colonoscopies were carried out by only two professionals trained and qualified physicians. About iFOBT a negative result can be obtained even when a gastrointestinal disorder is present. For example, some polyps and colorectal cancer may bleed intermittently or not at certain stages of the disease, and also if the amount of hidden blood present in the sample is below the detection limits of the test, despite being an exceptional situation. The excess sample collection for iFOBT may interfere with the migration process, but the professionals who perform the exam know the amount of sample that should be used. Alcohol and certain medications like aspirin, indomethacin, phenylbutazone, reserpine, corticosteroids and non-steroidal anti-inflammatory drugs can cause gastrointestinal irritation and subsequent bleeding, thus giving positive reactions.¹² Therefore, the patients are

advised by the laboratory about not using these medications to perform iFOBT.

Conclusion

We found that the high negative predictive value of the FOBT assures that in patients with a negative test result colonoscopy can be avoided, in line with the Brazilian guidelines. The FOBT low cost and the safe profile, as a non-invasive method, calls attention to its use in larger population as a reliable screening test for colorectal cancer, especially in countries with mid and low financial resources.

Conflicts of interest

The authors declare no conflicts of interest.

Acknowledgments

I would like to thank Professor Dr. Cesar de Almeida Neto, for the invaluable collaboration in the revision of English and suggestions provided to the article.

REFERENCES

- INCA. Estimativa da incidência do câncer no Brasil em; 2016. Available from: <http://www.inca.gov.br> [accessed 13.11.17].
- Assis RVBF. Rastreamento e Vigilância do Câncer Colorretal: Guidelines Mundiais. *Gastroenterol Endosc Dig*. 2011;30:62–74.
- Jucá MJ, Assunção PRT, Júnior HNHR. Fecal occult blood test and flexible rectosigmoidoscopy: tools for the screening of colorectal neoplasms in asymptomatic patients. *J Coloproctol (Rio de Janeiro)*. 2015;35:35–41.
- Kaminski MF, Regula J, Kraszewska E, Polkowski M, Wojciechowska U, Didkowska J, et al. Quality indicators for colonoscopy and the risk of interval cancer. *N Engl J Med*. 2010;362:1795–803.
- Almeida FFN, Araujo SEA, Santos FPS, Franco CJCS, Santos VR, Nahas SC. Colorectal cancer screening. *Rev Hosp Clín Fac Med S Paulo*. 2000;55:35–42.
- Almeida FFN, Araujo SEA, Santos FPS, Franco CJCS, Santos VR, Nahas SC, et al. Colorectal cancer screening. *Rev Hosp Clin*. 2000;55:35–42.

7. Altenburg FL, Biondo-Simões MLP, Santiago A. Pesquisa de sangue oculto nas fezes e correlação com alterações nas colonoscopias. *Rev Bras Coloproctol*. 2007;27:304-9.
8. Imperiale TF, Glowinski EA, Lin-Cooper C, Larkin GN, Rogge JD, Ransohoff DF. Five-year risk of colorectal neoplasia after negative screening colonoscopy. *N Engl J Med*. 2008;359:1218-24.
9. Benevides IBS, Santos CHM. Colonoscopy in the diagnosis of acute lower gastrointestinal bleeding. *J Coloproctol (Rio J)*. 2016;36:185-8.
10. Freitas CD, Sartor MC, Correa MFM, Junior IF, Martins JF, Kotze PG, et al. Appropriateness of colonoscopy indication for colorectal neoplasm detection in patients under 50 years old with hematochezia. *J Coloproctol*. 2012;32:40-9.
11. Shaukat A, Mongin SJ, Geisser MS, Lederle FA, Bond JH, Mandel JS, et al. Long-term mortality after screening for colorectal cancer. *N Engl J Med*. 2013;369:1106-14.
12. http://www.katal.com.br/index.php/reagentes/testes-rapidos/item/download/687_1400da03a0c478f99992777554d20a5e
13. Almeida MG, Baravieira AC, Malheiros APR, Bellandi DM, Cury RM, Milman MHSA, et al. Polipectomias endoscópicas – estudo histopatológico e complicações. *Rev Bras Coloproctol*. 2003;23:100-4.
14. Jatobá MP, Candelaria PAP, Klug WA, Fang CB, Capelhuchnik P. Pesquisa de sangue oculto nas fezes e achado colonoscópico em 60 pacientes. *Rev Bras Coloproctol*. 2008;28:425-30.
15. Elsafi SH, Alqahtani NI, Zakary NY, ZahraniM EMA. The sensitivity, specificity, predictive values, and likelihood ratios of fecal occult blood test for the detection of colorectal cancer in hospital settings. *Clin Exp Gastroenterol*. 2015;8:279-84.
16. Quintero E, Castells A, Bujanda L, Cubiella J, Salas D, Lanás A, et al. Colonoscopy versus fecal immunochemical testing in colorectal-cancer screening. *N Engl J Med*. 2012;366:697-706.
17. Ciatto S, Martinelli F, Castiglione G, Mantellini P, Rubeca T, Grazzini G, et al. Association of FOBT-assessed faecal Hb content with colonic lesions detected in the Florence screening programme. *Br J Cancer*. 2007;96:218-21.
18. Zandoná B, Carvalho LP, Schimedt J, Koppe DC, Koshimizu RT, Mallmann CM. Prevalência de adenomas colorretais em pacientes com história familiar para câncer colorretal. *Rev Bras Coloproctol*. 2011;31:147-54.
19. Brooks DD, Winawer SJ, Rex DK, Zauber AG, Kahi CJ, Smith RA, et al. Colonoscopy surveillance after polypectomy and colorectal cancer resection consensus guidelines from the U.S. Multi-Society Task Force on Colorectal Cancer and the American Cancer Society, vol. 77; 2008, 995-1002, 1003-4.
20. Torres Neto JR, Arcieri JS, Teixeira FR. Aspectos epidemiológicos dos pólipos e lesões plano-elevadas colorretais. *Rev Bras Coloproctol*. 2011;30:419-29.