





Review Article

Anal mycobacterial infections^{††}

Lúcio Sarubbi Fillmann  ^{a,b,*}, Henrique Sarubbi Fillmann  ^{a,b},
 Laura Pinho Fillmann  ^c, Lana Becker Micheletto  ^c, Michel Hoefel  ^a,
 Josenel Maria Barcelos Marçal  ^b, Rafael Nazario Bringhenti  ^b

^a Pontifícia Universidade Católica do Rio Grande do Sul (PUC-RS), Hospital São Lucas, Porto Alegre, RS, Brazil

^b Pontifícia Universidade Católica do Rio Grande do Sul (PUC-RS), Escola de Medicina, Porto Alegre, RS, Brazil

^c Pontifícia Universidade Católica do Rio Grande do Sul (PUC-RS), Curso de Graduação em Medicina, Porto Alegre, RS, Brazil

ARTICLE INFO

Article history:

Received 5 August 2019

Accepted 15 September 2019

Available online 30 October 2019

Keywords:

Mycobacterial infections

Tuberculosis

Anal canal

Fistula in ano

ABSTRACT

Background: Mycobacterial infections are a serious public health problem worldwide. Involvement of the anal canal and perineum is very rare, but constitute an important differential diagnosis with other equally serious pathologies that may affect the region, such as malignant neoplasms and Crohn's disease.

Objectives: To conduct a literature review on mycobacterial infections of the perianal region considering the most recent information for diagnostic and therapeutic guidance of this disease.

Methods: Research was performed on the PUBMED and LILACS databases with the expressions Mycobacterium, Anal, Infection and Tuberculosis. We reviewed articles referring to series of treated cases, clinical reports and literature review published since 2005.

Results: Information was compiled on the epidemiology of mycobacterial infections; the clinical behavior of affected individuals; diagnostic options and their validity in clinical practice; and, finally, therapeutic options.

Conclusions: Mycobacterial infections of the anus and perineum are rare. The most common clinical presentations are the presence of ulceration and fistulization. The diagnosis involves more than one procedure for identifying the bacilli and should consider the presence of manifestations in more than one organ. The treatment is based on pharmacological intervention. Surgery is recommended for acute complications or chronic sequelae of the disease.

© 2020 Sociedade Brasileira de Coloproctologia. Published by Elsevier Editora Ltda. This is an open access article under the CC BY-NC-ND license (<http://creativecommons.org/licenses/by-nc-nd/4.0/>).

[†] Institution: Serviço de Coloproctologia do Hospital São Lucas da PUC-RS.

* Corresponding author at: Pontifícia Universidade Católica do Rio Grande do Sul (PUC-RS), Hospital São Lucas, Porto Alegre, RS, Brazil.
 E-mail: lsfillmann@yahoo.com.br (L.S. Fillmann).

<https://doi.org/10.1016/j.jcol.2019.09.008>

2237-9363/© 2020 Sociedade Brasileira de Coloproctologia. Published by Elsevier Editora Ltda. This is an open access article under the CC BY-NC-ND license (<http://creativecommons.org/licenses/by-nc-nd/4.0/>).

Infecções micobacterianas do ânus

R E S U M O

Palavras-chave:

Infecções por micobactéria
Tuberculose
Canal anal
Fístula anal

Introdução: Infecções micobacterianas constituem um grave problema de saúde pública a nível mundial. As manifestações anoperineais são raras, mas constituem um importante diagnóstico diferencial com outras patologias igualmente graves que podem acometer a região, como as neoplasias malignas e a doença de Crohn.

Objetivos: Realizar um levantamento da literatura sobre infecções micobacterianas da região anoperineal, considerando as informações mais atuais para orientação diagnóstica e terapêutica dessa enfermidade.

Métodos: Foi realizada pesquisa nos bancos de dados PUBMED e LILACS com as expressões *Mycobacterium*, *Anal*, *Infection* e *Tuberculosis*. Foram revisados artigos referentes a séries de casos tratados, relatos clínicos e revisão da literatura publicada a partir de 2005.

Resultados: Foram compiladas informações sobre a epidemiologia das infecções micobacterianas; o comportamento clínico dos indivíduos afetados; opções diagnósticas e sua validade na prática clínica; e, por fim, opções terapêuticas.

Conclusões: Infecções micobacterianas da região anoperineal são raras. As apresentações clínicas mais comuns são a formação de úlceras e a fistulização. O diagnóstico envolve mais de um procedimento para identificação dos bacilos, e deve considerar a presença de manifestações em mais de um órgão. O tratamento é principalmente medicamentoso, sendo a cirurgia recomendada nas complicações agudas ou sequelas crônicas da doença.

© 2020 Sociedade Brasileira de Coloproctologia. Publicado por Elsevier Editora Ltda. Este é um artigo Open Access sob uma licença CC BY-NC-ND (<http://creativecommons.org/licenses/by-nc-nd/4.0/>).

Introduction

Mycobacterial infections are a serious health problem worldwide, particularly in developing countries.¹⁻⁵ The increased life expectancy of the world population, as well as the increased number of individuals with clinical immunosuppression, especially HIV infection, are responsible for the growing number of people with mycobacteriosis, mainly tuberculosis.^{1,2} The extrapulmonary clinical presentation, however, is the least common form of the disease.²⁻⁴ When it reaches the anal region, this infectious process has several clinical forms, the most common being anal fistula as well as perineal ulcerations.⁶ Thus, mycobacteriosis of the anus is a differential diagnosis, with other granulomatous diseases in this region, being important especially regarding Crohn's disease.⁵

Objectives

The aim of the present study is to obtain an updated review of the clinical behavior of individuals with anoperineal mycobacterium infection, as well as to investigate diagnostic and therapeutic options for this disease.

Methods

A literature review of the PUBMED and LILACS databases was performed using the terms *Mycobacteria*, *Anorectal*, *Infection*, and *Tuberculosis*. Articles related to literature review, case series, and clinical reports were included. We reviewed

publications identified on these search platforms from 2005 onwards.

Discussion

Based on the review and clinical experience of the authors in dealing with cases of perianal mycobacterium infection, data regarding the disease epidemiological behavior, most frequent clinical presentations, available diagnostic instruments and their sensitivity and specificity, and recommended therapeutic options for disease control were analyzed.

Epidemiology

Mycobacterial infection, especially tuberculosis, is a worldwide epidemic.⁷ Data from the World Health Organization indicate that tuberculosis is one of the top 10 clinical entities related to human mortality, being the leader among infectious diseases.⁷ In 2017, it was estimated that 1.3 million people perished as a result of this condition, an increase of at least 300,000 more deaths in HIV-positive individuals.⁷ The number of cases is especially higher in developing countries, but there are reports in all nationalities and all age groups.^{1-5,7} Adults represent approximately 90% of those infected, with 9% of individuals carrying the HIV virus, of which 72% live in the African continent. Two-thirds of all reported cases are found in eight countries: India, China, Indonesia, Philippines, Pakistan, Nigeria, Bangladesh, and South Africa. These eight nations, together with 22 others with high disease rates, account for 87% of all tuberculosis cases.⁷ Brazil is included in this group of 30 countries.⁷ Most infections affect the

respiratory tract. Extrapulmonary manifestations represent between 5% and 15% of the total cases of the disease.^{4,6} In tuberculosis, non-pulmonary manifestations include pleura (26%), lymph nodes (17%), genitourinary tract (15%), joints and bones (14%), meninges (6%), peritoneum (4%), and the miliary form (8%).⁴ The gastrointestinal tract accounts for only 1% of non-respiratory infections,^{3,4} a number credited to sanitary measures adopted for a long time such as milk pasteurization.⁴ When this region is affected, the disease is mainly located in the ileum and cecum.³ The anus represents only 1% of the mycobacterial infection sites, especially tuberculosis, which reach the digestive tract.³ In the United Kingdom, one review identified only 2 cases of perineal tuberculosis in 22 years.² Comprehensive reviews of the international literature performed between 1970 and 2014 and addressing reports of perianal tuberculosis, particularly presenting with abscess, fistula or ulceration type, found only 58 cases and 70.7% of the reports were from the Asiatic continent.⁵ In our service, two cases were diagnosed within 25 years.

Clinical presentation

The development of anal fistula seems to be the most common presentation of mycobacterial infection of the anorectoperineal region.^{3,6,7,9} However, there is a low specificity of symptoms reported by patients to characterize the infection as associated with mycobacteria, contrary to the much more frequent complication of a crypto-glandular infectious process.⁹ Constitutional symptoms, such as anorexia, weight loss and night fever, should reinforce the hypothesis of mycobacterial infection.⁹ Simultaneous occurrence of respiratory symptoms, such as chronic cough accompanied by poor discharge or sputum, may indicate concomitant pulmonary disease.⁷ Such condition was reported in approximately 75% of patients in a historical series of anal tuberculosis, where individuals also had active or previously treated lung disease.⁷ Suspicion should also be reinforced in cases with clinical conditions resulting in immunosuppression.² Clinical investigation of anti-HIV antibodies is especially important, as the reduction of lymphocyte activity by viral infection allows reactivation of dormant foci of mycobacteria in pulmonary and gastrointestinal sites.² It should be noted, however, that most authors reported the occurrence of anoperineal disease in immunocompetent patients.⁵ Moreover, several studies report that the number of men affected is significantly higher than women, and may reach a ratio of 4:1.^{2,7,9} In our small sample, both patients were male and under 40 years old. Physical examination may contribute significantly to the hypothesis of anal mycobacterial infection. Fistulas often acquire complex features with multiple external orifices and long perineum tracts.⁷ Commonly, ulcer formation is observed in the perianal region, with regular borders, necrotic or fibrin-covered bottom, and discharge of purulent secretion (Fig. 1).^{3,4} Warty and miliary formations have also been described.³ These findings resemble other more common pathologies that are part of differential diagnosis, such as Crohn's disease, herpes, syphilis, skin neoplasms, and traumatic foreign body injuries.² It should also be noted that chronicity is a significant hallmark of the disease.

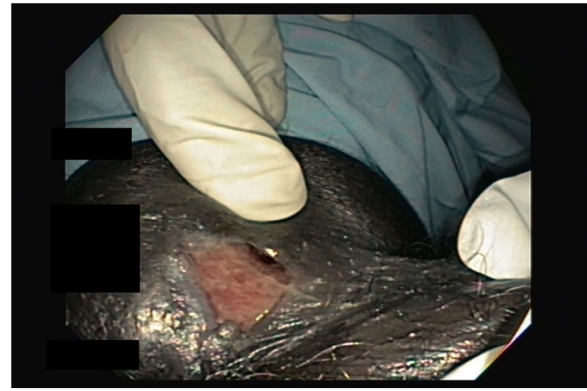


Fig. 1 – Fistulous orifice with perianal ulcer in a patient with mycobacterial infection.

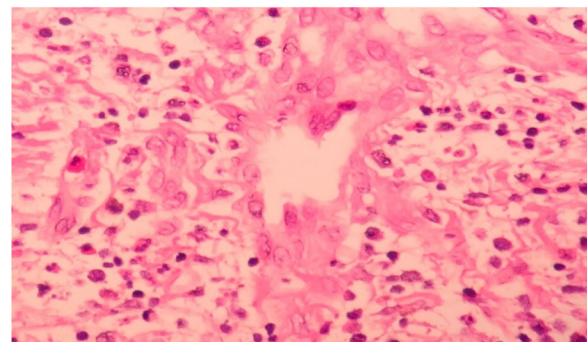


Fig. 2 – Photomicrograph (200×), HE stain, showing dermis with acute inflammatory infiltrate and multinucleated giant cell in the center.

Diagnosis

The perianal mycobacterial infection diagnosis requires a high degree of suspicion by the attending physician. Initially, it is essential that the atypical clinical presentation of perianal disease, whether in its warty, ulcerated form or the formation of complex fistulous tracts, serves to draw the attention of the health professional regarding the possible mycobacterial infection. Indirect diagnostic tests, such as Mantoux, can be performed and will be positive in approximately 75% of non-immunosuppressed patients affected by the disease.⁶ Therefore, a negative test in an immunocompetent individual with a normal chest radiograph provides a solid basis for ruling out the possibility of perianal tuberculosis.⁶ Another alternative, following the analogy of investigating sputum mycobacteria in suspected lung disease, would be to look for acid-resistant bacilli in the secretion eliminated by the anal fistula. A positive test confirms the diagnosis. However, this finding is seen in less than 25% of cases.⁶ If mycobacterial infection is suspected, a biopsy of the perianal lesion should be performed.^{2,4,6} The characteristic histological aspect is that of an epithelioid granuloma with multinucleated giant cells having an area of caseous necrosis (Fig. 2).^{2,4,6} When these findings are identified under microscopy, the bacillus should be screened using Ziehl-Neelsen staining (Fig. 3).^{2,6} The secretion culture in order to identify the type of mycobacteria,

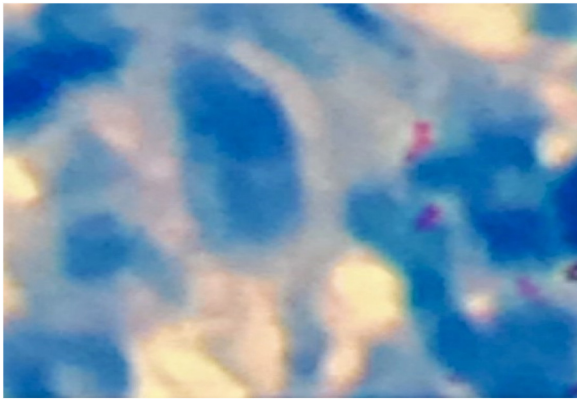


Fig. 3 – Photomicrograph (400×) showing positive Ziehl-Neelsen staining and low bacillus density.

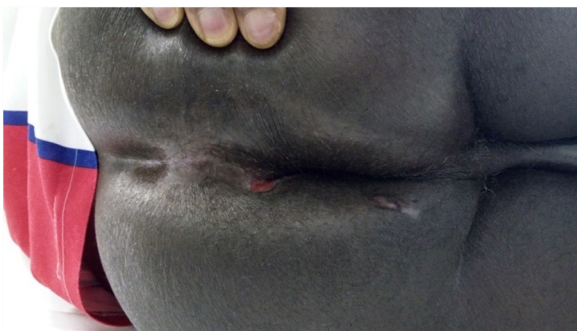

Fig. 4 – Late postoperative period of patient with anal fistula related to mycobacterial infection. Patient was treated for 6 months with tuberculostatics.

as well as its susceptibility to antimicrobial agents, should complete the investigation.⁶ Polymerase Chain Reaction (PCR) screening for bacterial DNA identification has high sensitivity and specificity and is a faster alternative to culture, with an execution time that can reach up to four weeks (Fig. 4).^{1,4,6}

Treatment

The mainstay of treatment for perianal mycobacterial infection is prolonged antibiotic therapy with multiple combined drugs, following the same principle of infections caused by these agents in other organs and systems.^{2,6,9,10} The recommended treatment regimen involves 6 months of treatment, the first two with rifampicin, isoniazid, pyrazinamide, and ethambutol and the remaining four with only rifampicin and pyrazinamide.^{9,10} Some authors, however, have reported a possible need for prolongation of this treatment based on the slow response and tendency to recurrence.⁹ The decision on the continuity of the treatment regimen should be based on clinical evaluation and follow-up, but these same publications state that it should rarely be discontinued before 18 months.⁹ Surgical treatment is restricted to a small set of clinical conditions. The presence of abscess in the region is an indication for immediate surgical drainage.^{2,9} The occurrence of symptomatic stenosis may cause difficulties in long-term management of patients during antimicrobial treat-

ment, and should be corrected early if necessary.^{2,9} The anal fistula approach should not be attempted before the end of drug treatment, as active infection may lead to therapeutic failure.^{2,9} In addition, tract healing and closure is possible with the use of tuberculostatics.^{2,9}

Conclusion

Perianal mycobacterial infection is a major clinical challenge. Although infrequent, it should be present in the differential diagnosis of other clinical entities, such as Crohn's disease and anus neoplasms. In immunosuppressed patients, tuberculosis becomes more common, and clinical variation combined with changes in host physiological responses represent a new challenge for diagnostic elucidation. In the presence of suspected mycobacterial infection, a biopsy is mandatory, combined with clinical tests to identify other disease outbreaks, in addition to screaming for alcohol-resistant bacilli through bacteriological analysis of secretions, culture or bacterial DNA PCR. Drug treatment is the main therapeutic option, and surgery is indicated in the presence of abscesses, anal stenosis, and healing failure of the perianal fistulous form after the end of drug treatment.

Conflicts of interest

The authors declare no conflicts of interest.

Uncited reference

[8].

REFERENCES

1. Takakura Y, Fujimori M, Okugawa K, Hiroyuki E, Ohdan H, Kaneko S, et al. Rare case of sacrococcygeal tuberculosis mimicking as an anal fistula. *Int J Surg Case Rep.* 2018;49:74-7.
2. Mathew S. Anal tuberculosis: report of a case and review of literature. *Int J Surg.* 2008;6:e36-9.
3. Azadi A, Fard PJ, Farahani MS, Khodadadi B, Almasian M. Anal tuberculosis: a non-healing anal lesion. *IDCases.* 2018;12:25-8.
4. Akgun E, Tekin F, Ersin S, Osmanoglu H. Isolated perianal tuberculosis. *Neth J Med.* 2005;63:115-7.
5. Tago S, Hirai Y, Ainoda Y, Fujita T, Takamori M, Kikuchi K. Perianal tuberculosis: a case report and review of the literature. *World J Clin Cases.* 2015;3:848-52.
6. Gupta PJ. Ano-perineal tuberculosis: solving a clinical dilemma. *Afr Health Sci.* 2005;5:345-7.
7. WHO. Global tuberculosis report; 2018.
8. Tai WC, Hu TH, Lee CH, Chen CH, Huang CC, Chuah SK. Ano-perineal tuberculosis: 15 years of clinical experiences in southern Taiwan. *Colorectal Dis.* 2009;12:e114-20.
9. Sahu M, Mishra JK, Sharma A, Fatmi U. A prospective study on tubercular fistula in ano and its management. *J Coloproctol (RIO J).* 2017;37:211-5.
10. Neto IJ, Siá ON, Lopes EA, Macacari RL, Watté HH, Souza RF, et al. Perianal tuberculosis: a rare disease of late diagnosis. *J Coloproctol (RIO J).* 2014;34:124-7.