



Review Article

Safety and effectiveness of laparoscopic peritoneal lavage in Hinchey III diverticulitis[☆]



Miguel António Loureiro Guimarães ^{a,*}, Laura Elisabete Ribeiro Barbosa^{a,b}

^a Universidade do Porto, Faculdade de Medicina, Porto, Portugal

^b Centro Hospitalar São João, Serviço de Cirurgia Geral, Porto, Portugal

ARTICLE INFO

Article history:

Received 26 April 2020

Accepted 13 May 2020

Available online 2 June 2020

Keywords:

Laparoscopy

Lavage

Diverticulitis

Hinchey III

Purulent

ABSTRACT

Introduction: The management of Hinchey III diverticulitis has been subject to investigation over the years. Hartmann's procedure is widely referred as the standard treatment. However, this option is associated with relevant morbidity and mortality which motivated the arise of alternative interventions such as the laparoscopic peritoneal lavage.

Aim: The aim of this review is to synthesize the evidence on the safety and effectiveness of laparoscopic peritoneal lavage in the management of diverticulitis with generalized purulent peritonitis in comparison to resection procedures.

Materials and methods: The bibliographic research was conducted using the electronic database Medline from Pubmed. Of the 358 articles identified, our criterious selection resulted in a total of 27 articles for review.

Results: Overall, laparoscopic lavage revealed low mortality rates with no remarkable differences between procedures. The non-randomized studies tended to show lower recurrence and morbidity rates comparatively to the latest RCTs, in the lavage groups, however, no significant differences have been found.

Discussion and conclusion: In this review, laparoscopic peritoneal lavage proved to be safe and comparatively effective, although not superior to resection, reaching mixed results. We believe it can be applied as a damage control operation to treat or as a bridge to elective resection. Still, more studies are needed to determine indications and factors for the success of laparoscopic lavage.

© 2020 Sociedade Brasileira de Coloproctologia. Published by Elsevier Editora Ltda. This is an open access article under the CC BY-NC-ND license (<http://creativecommons.org/licenses/by-nc-nd/4.0/>).

[☆] Study conducted at Universidade do Porto, Faculdade de Medicina, Departamento de Cirurgia Geral, Porto, Portugal.

* Corresponding author.

E-mail: miguel.guimaraes08@sapo.pt (M.A. Guimarães).

<https://doi.org/10.1016/j.jcol.2020.05.010>

2237-9363/© 2020 Sociedade Brasileira de Coloproctologia. Published by Elsevier Editora Ltda. This is an open access article under the CC BY-NC-ND license (<http://creativecommons.org/licenses/by-nc-nd/4.0/>).

Segurança e eficácia da lavagem peritoneal laparoscópica na diverticulite Hinchey III

R E S U M O

Palavras-chave:

Laparoscopia
Lavagem
Diverticulite
Hinchey III
Purulenta

Introdução: O tratamento da diverticulite por Hinchey III tem sido objeto de investigação ao longo dos anos. A operação tipo Hartmann é amplamente referida como o tratamento padrão. No entanto, esta opção está associada à morbidade e mortalidade relevante, o que motivou o surgimento de intervenções alternativas, como a lavagem peritoneal laparoscópica.

Objetivo: O objetivo desta revisão é sintetizar a evidência sobre a segurança e a eficácia da lavagem peritoneal laparoscópica no tratamento da diverticulite com peritonite generalizada purulenta em comparação com os procedimentos de ressecção.

Materiais e métodos: A pesquisa bibliográfica foi realizada na base de dados eletrônica Medline da Pubmed. Dos 358 artigos identificados, a nossa seleção criteriosa resultou num total de 27 artigos para revisão.

Resultados: No geral, a lavagem laparoscópica revelou baixas taxas de mortalidade sem diferenças significativas entre os procedimentos. Os estudos não randomizados tenderam a mostrar menores taxas de recorrência e morbidade comparativamente aos últimos ensaios clínicos randomizados, nos grupos submetidos à lavagem, no entanto, nenhuma diferença significativa foi encontrada.

Discussão e conclusão: Nesta revisão, a lavagem peritoneal laparoscópica mostrou-se segura e comparativamente eficaz, embora não superior à ressecção, não alcançando resultados constantes. Nós acreditamos que pode ser aplicada como um procedimento de controle de danos para tratamento ou como ponte para cirurgia eletiva. Ainda assim, são necessários mais estudos para determinar indicações e fatores para o sucesso da lavagem laparoscópica.

© 2020 Sociedade Brasileira de Coloproctologia. Publicado por Elsevier Editora Ltda. Este é um artigo Open Access sob uma licença CC BY-NC-ND (<http://creativecommons.org/licenses/by-nc-nd/4.0/>).

Introduction

A colonic diverticulum is a herniation of mucosa and submucosa through the colon muscular layer, in a point of weakness where the vasa recti penetrate the tunica muscularis.¹

Diverticulosis, which refers to the presence of colonic diverticula,² is a common gastrointestinal disorder in the occidental world, with an increasing incidence rate mostly among patients between the ages of 18 and 64 years-old.³ The prevalence of diverticulosis increases with age (5% in 30–39 year-olds and 60% in those over 80).⁴ Likewise, increased body mass index, lack of physical exercise,⁵ non-steroidal anti-inflammatory drugs⁶ and genetics⁷ also play a significant role in its pathophysiology. Differently, high-fiber diet contributes to risk reduction.⁸

Diverticulosis is asymptomatic and often an incidental finding. As the clinical relevance of such finding is not clear, there is no indication for follow-up.⁹ When the presence of colonic diverticula leads to symptoms, this is referred to as diverticular disease. Recently, there has been a development in the taxonomic classification of diverticular disease into distinct conditions, represented in Fig. 1.

Symptomatic Uncomplicated Diverticular Disease (SUDD) is defined as the concomitant presence of diverticula and symptoms, such as abdominal pain, predominantly in the left iliac region, bloating and bowel habit changes (diarrhea, constipation or both), in the absence of macroscopic inflammation.¹⁰

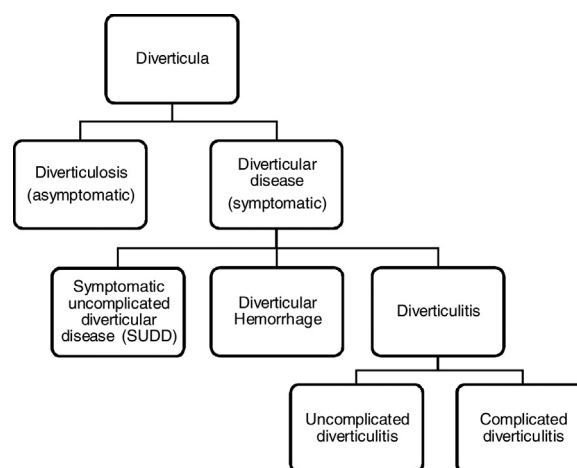


Fig. 1 – Classification of diverticular disease.

Diverticulitis is characterized by the presence of macroscopic inflammation associated with a symptomatic diverticulum. This may happen due to obstruction of the neck of the diverticulum by fecaliths leading to accumulation of mucus and increased pressure with progressive transluminal inflammation.¹¹ Recent evidence suggests that 4%–7% of patients with diverticulosis will develop diverticulitis, which is the most common reason for diverticular disease leading to hospital admission.¹²

Table 1 – Hinchey classification.

Hinchey stage	Definition
I	Pericolic abscess or phlegmon
II	Pelvic or retroperitoneal abscess
III	Generalized purulent peritonitis
IV	Generalized faeculent peritonitis

Diverticulitis can be classified as either uncomplicated or complicated. Uncomplicated diverticulitis is the most common presentation and is characterized by mild inflammation whereas the complicated disease involves a wider spectrum of manifestations ranging from a pericolic abscess to perforation with faeculent peritonitis. To further specify the grade of severity, many classifications were created, being the original Hinchey classification the most used in the literature (Table 1).¹³ It is based on operative findings; however, it is possible to establish a comparison with CT images when evaluating the extension of the inflammation during diagnosis.

Conceptually, the management of acute diverticulitis depends on the extent and clinical manifestations of the disease, which generally correspond to the Hinchey classification.¹³

When it comes to stage I, there is little debate that a local abscess inferior to 5 cm can be resolved without surgery, mostly with outpatient treatment, using antibiotic therapy, although therapeutic escalation may be required in some cases. Differently, for stage II, larger pelvic abscesses are frequently treated with antibiotics and CT guided percutaneous drainage.¹⁴ On the other hand, the treatment for diverticulitis with generalized peritonitis has been subject to investigation over the years.

Initially, it was managed with a three-stage operation, described by Mayo in 1907, which consisted of a colostomy in the acute phase followed by the resection of the affected area and the closure of the stoma.¹⁵

Eventually, this operation was replaced by the Hartmann's procedure in which the disease area is resected, the proximal end is used for a temporary colostomy and the distal end is closed. Unfortunately, this technique is associated with high mortality as documented by Vermeulen et al.¹⁶ Additionally, although the stoma is temporary, most of the times it becomes permanent or when the reversal is feasible, it is associated with significant complications, wound infection and anastomotic leak rates.¹⁷

Despite this, Hartmann's procedure is widely referred as the standard technique for patients with diverticulitis with generalized peritonitis. While it is largely accepted that the faeculent peritonitis (stage IV) requires the resection of the affected area of the colon, the optimal treatment for purulent peritonitis still remains a topic of debate.

In fact, with the improvement of laparoscopic techniques, the opportunity has arisen for the treatment of generalized purulent peritonitis with the advantages of a minimally invasive approach that is, reducing the need for laparotomy and colostomy and contributing to lower mortality and morbidity rates.

Therefore, in 1996, O'Sullivan et al. described the laparoscopic peritoneal lavage as a non-resection procedure in which the peritoneum is irrigated with warm saline and the purulent

material is aspirated and was able to perform this technique with promising results.¹⁸ More recently, a large prospective multicenter study published in 2008 showed favorable results supporting the use of this procedure. For a total of 92 out of 100 patients treated with peritoneal lavage, the registered morbidity and mortality rates were 4% and 3%, respectively and only 2 recurrence cases were documented.¹⁹

To date, several studies have been conducted to clarify the appliance of this procedure, but conflicting results have been found. Also, although many reviews have been published, only a limited number of articles are featured. This review was carried out with the aim of synthesizing the evidence on the safety and effectiveness of laparoscopic peritoneal lavage in the management of diverticulitis with generalized purulent peritonitis in comparison to resection procedures.

Methods

A literature review was performed in August 2019 using the electronic database MEDLINE from Pubmed. The designed search strategy was the following: (((Laparoscop* [Title/Abstract] OR lavage [Title/Abstract] OR drainage [Title/Abstract])) AND ((diverticulitis [Title/Abstract]) AND (((peritonitis [Title/Abstract]) OR perforated [Title/Abstract]) OR purulent [Title/Abstract]) OR hinchey iii [Title/Abstract])).

There was no language or publication date restriction. The reference lists from the included articles were manually evaluated and additional studies were included when relevant. Commentaries, letters, case reports, reviews and guidelines were excluded. Furthermore, articles focused on different procedures or pathologies were also excluded.

The titles and abstracts were screened for applicability of the selected articles. Some abstracts were translated. Any randomized or non-randomized controlled trial or observational study evaluating the safety and effectiveness of laparoscopic peritoneal lavage in the treatment of diverticulitis with generalized purulent peritonitis was considered eligible for this review.

Based on the literature search, 357 studies were identified. An additional study was found in the manual search of the reference lists. Thus, the initial search resulted in 358 publications.

After initial evaluation, 194 were excluded on the basis of their type of article being commentaries, letters, case reports, a review or guidelines. Furthermore, after screening titles and abstracts, 137 were excluded because the investigative question was not relevant, resulting in 27 articles for review (Fig. 2).

Of the 27 full-text articles retrieved, 19 were non-randomized observational studies (5 prospective¹⁹⁻²³ and 14 retrospective²⁴⁻³⁷ series). Three were randomized controlled trials³⁸⁻⁴⁰ comparing laparoscopic lavage to colon resection with short- and long-term⁴¹⁻⁴³ results registered in another 3 separated articles as well as 2 health economic analysis of the treatment approaches.^{44,45}

In order to give context to this review, 18 more articles were selected in a parallel search to support the current evidence on diverticulitis, namely concerning its pathophysiology and management of disease.

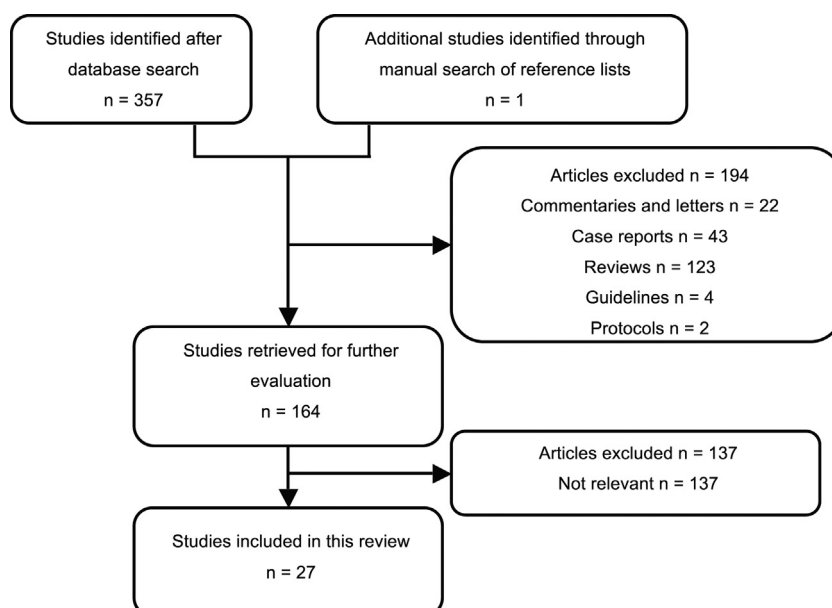


Fig. 2 – Flow chart of identified articles.

Results

For a better understanding of the scientific evidence and organization of the findings, the results will be documented according to the treatment approaches applied and the type of study.

Laparoscopic peritoneal lavage

By the end of first decade of the twentieth century, several observational studies^{19,24-26} have highlighted the possibility of using the laparoscopic lavage as a means of treating diverticulitis with generalized purulent peritonitis.

Franklin and colleagues²⁴ performed this procedure in 40 patients presenting with signs of acute diverticulitis (32 with purulent peritonitis), with no deaths or significant perioperative complications, apart from 6 cases of mild postoperative paralytic ileus and 2 chest infections, which were resolved without consequences. Although 60% of the patients were indicated with a planned sigmoid colectomy at the time of emergency admission, none of the 16 patients treated by laparoscopic lavage alone reported recurrence of diverticulitis during a median follow-up of 96 months.

Another large study from this period, by Myers et al.,¹⁹ collected prospective data from 100 patients. Eight presented with fecal peritonitis and therefore had a Hartmann's procedure. The remaining 92 patients (67 with Hinchey III diverticulitis) were managed with laparoscopic lavage, showing morbidity and mortality rates of 4% and 3%, respectively and a mean length of hospital stay of 8 days. At a median follow-up of 96 months, only 2 patients required further intervention for pelvic abscesses and another 2 presented with recurrence.

Other small series also documented the effectiveness of this method in the treatment of diverticulitis with purulent

peritonitis. In the study by Taylor et al.,²⁵ among 10 patients with Hinchey III diverticulitis initially managed by laparoscopic lavage, only 1 required reintervention, due to persistent symptoms, and no deaths were registered.

In the study by Lam et al.,²⁶ although with few patients with diverticulitis Hinchey III (5), there was a high rate of conversion to resection (60%).

More recent studies have delivered results based on larger numbers of patients with diverticulitis with purulent peritonitis. In 2013, Swank and colleagues²⁷ published a retrospective study of 38 patients with perforated, purulent diverticulitis as a preliminary, short-term evaluation before the start of the Ladies trial.⁴⁰ Peritoneal lavage was successful in controlling the inflammatory condition in 31 of the 38 included patients and with fast recovery. Among the successfully managed cases with lavage, 3 patients underwent resection due to recurrent diverticulitis. Overall 17 patients developed complications and 3 died due to infectious causes and coexisting comorbidities. The authors also highlighted that patients unresponsive to peritoneal lavage showed greater comorbidity, higher preoperative c-reactive protein levels, and a higher Mannheim Peritonitis Index. Furthermore, they concluded that the use of lavage was unsafe for faeculent peritonitis. In 2019, Sneyders et al.²⁸ published the long-term results of this study in a median follow-up of 46 months. They recorded high rates of adverse events with 27 affected patients as well as 17 episodes of recurrent diverticulitis in 12 patients. Overall, 4 deaths were documented due to causes related to or as a direct consequence of diverticulitis. Also, 12 patients required reoperation for disease control.

In the study by Rossi and colleagues,²⁹ among 46 patients with Hinchey III diverticulitis supposed to be treated with laparoscopic lavage, 2 required conversion to resection representing a feasibility of 96%. In addition, 5 in 44 peritoneal lavages failed to control sepsis and required further surgery

for resection. They also registered a global postoperative morbidity rate of 24% and no deaths.

In a long-term follow-up study by Sorrentino et al.,³⁰ of 54 patients with Hinchey III diverticulitis treated with laparoscopic lavage, only 6 patients underwent early reintervention due to treatment failure. Overall, other 4 complications were reported after lavage including 1 death due to pulmonary embolism.

In the study by Radé et al.,³¹ among 47 cases of purulent peritonitis, treatment was successful in 43 patients, with acceptable mortality and morbidity rates, and the remaining 4 underwent reintervention. Furthermore, the authors identified immunosuppression, age 80 years or more and ASA grade III or above, as variables associated with laparoscopic peritoneal lavage failure. In the same year, Horesh et al.³² also presented satisfying results with laparoscopic lavage in a small series with successful management of disease and acceptable rates of recurrence and reoperation.

The findings in Escalante et al.³³ study followed the trend of positive results for laparoscopic lavage in the management of 43 cases of Hinchey III diverticulitis, with major complications and mortality rates of 0%. In addition to the reduced length of hospital stay (4.2 days) no patient required reoperation.

Also, in 2016, Parisi et al.²⁰ found laparoscopic lavage to be successful in 66.7% of 21 patients with purulent peritonitis. Seven needed rehospitalization due to recurrence and of these, 4 required urgent surgery (Hartmann's procedure).

More recently, Greilsamer and colleagues,³⁴ conducted a multicenter study involving 71 patients with diverticulitis with purulent peritonitis managed with laparoscopic peritoneal lavage. This procedure was successful in 80% of the cases with a mean length of stay of 14.9 days. The failure was due to 1 death and 13 reoperations due to persistent sepsis, generalized peritonitis and fecal leak in the drainage. The morbidity rate reported was 39%, and 17 patients were associated with major complications. Similarly to earlier series,³¹ Greilsamer also highlighted immunosuppression and ASA grade III or above, as variables associated with the failure of this approach.

In 2018, the LLO Study³⁵ was published with the goal of documenting the effectiveness of laparoscopic lavage in treating purulent peritonitis in patients with acute diverticulitis, since the main randomized trials had had mixed findings. This series included 231 patients; however, after conversion to open procedure in 19, only 212 underwent lavage. Among these, the postoperative morbidity rate was 33% (with 29 patients requiring further surgery in the same first admission) and the mortality rate was 1.88%. Following discharge after laparoscopic lavage alone, 21 patients needed readmission for various reasons, including 6 diverticulitis recurrences. Overall, the technique was considered to be successful in 172 patients since there were no signs of sepsis and no need for further surgery during the stay at the hospital and the following 60 days after discharge. Nevertheless, during the 11 month follow-up, 46 episodes of acute diverticulitis were recorded.

Laparoscopic peritoneal lavage vs. resection surgery

Laparoscopic peritoneal lavage vs. hartmann's procedure

For almost 20 years, a prospective study by Liang et al.²¹ followed 88 patients with perforated diverticulitis (over 75%

with Hinchey III) after disease management with laparoscopic peritoneal lavage or laparoscopic colonic resection. Peritoneal lavage was over 80 minutes faster and with less intraoperative complications compared to Hartmann's procedure. The resection group also had a higher conversion rate (14.6%). Furthermore, lavage was associated with 4.3% of postoperative complications, while Hartmann's procedure registered 12.5%. One patient died after a Hartmann's procedure while no deaths were associated with lavage. During follow-up, almost half of the patients managed with lavage had a secondary sigmoidectomy performed for source control. In the Hartmann's procedure group, stoma closure was only performed in 72% of patients. Overall laparoscopic lavage had significantly better results.

Another two included articles^{22,36} had findings focusing on lavage effectiveness on more elderly patients. Although with less cases of diverticulitis Hinchey III, these studies showed that laparoscopic peritoneal lavage is safe and effective in the treatment of these particular age group usually more demanding of conservative approaches.

Laparoscopic peritoneal lavage vs. resection with primary anastomosis

In 2009, Karoui and colleagues³⁷ conducted a comparative study with 59 patients with Hinchey III diverticulitis divided into two groups according to the procedure undergone: laparoscopic peritoneal lavage (35) or resection with primary anastomosis (24). There were no significant differences in postoperative mortality and morbidity between the two groups. In the lavage group, only 1 episode of recurrence was reported, being this procedure successful in 97% of the patients. Nine cases were treated with lavage alone and the remaining 25 underwent elective sigmoid resection. In the resection group, the success rate was lower (92%) but yet satisfying, with all the patients having their ileostomy closure. Furthermore, the median length of hospital stay was shorter in the laparoscopic lavage group.

More recently, Catry et al.²³ compared postoperative outcomes in patients with purulent peritonitis after treatment with laparoscopic lavage (15) and resection with primary anastomosis (25). Overall, there were no significant differences in postoperative morbidity and mortality between the two groups. However, the rate of abdominal complications in the lavage group (8/15) was significantly higher compared to resection (3/25). In the lavage group, although sepsis was controlled successfully in 10 patients, 3 of these had further recurrences requiring reoperation. Those with persistent sepsis (5) underwent resection. In the resection group, only 1 patient required reintervention and all surviving patients who had a procedure requiring stoma creation underwent stoma reversal. So, although laparoscopic lavage showed a lower median length of hospital stay, the overall results were in favor of colonic resection.

Randomized controlled trials

The DILALA trial³⁸ suggests that laparoscopic peritoneal lavage is a feasible and safe procedure for the management of patients with diverticulitis with purulent peritonitis without the need of stoma formation. According to Angenete and

colleagues, the short-term results of this trial, from 39 patients in the lavage group and 36 in the Hartmann's procedure group, revealed no significant differences in mortality at day 30 (3/39 vs. 0/36) or at day 90 (3/39 vs. 4/36). Also, overall morbidity did not differ significantly between approaches with identical numbers of reoperations and readmissions within 30 days. However, laparoscopic lavage did result in shorter operating time, recovering time and length of hospital stay. Following these early findings, Thornell et al.⁴¹ published one-year follow-up results which further supported the previous evidence. This time, there were significantly less patients in the laparoscopic lavage group that required at least 1 reoperation within 12 months, compared to the resection group. In 2018, Kohl et al.⁴² reported the two-year follow-up information. Patients in the lavage group had a 45% reduced risk of reoperation (including stoma reversal) within 24 months, compared to the Hartmann's group. No differences in re-admissions or mortality were reported. Based on these outcomes, the authors recommended the use of laparoscopic lavage for Hinchey III diverticulitis.

In another randomized study, the LOLA arm of the LADIES trial⁴⁰ randomized patients with diverticulitis with purulent peritonitis to two interventions: laparoscopic lavage (46) or sigmoidectomy (40). The recruitment was terminated prematurely after an increased number of adverse events in the lavage group (16/46) compared to sigmoidectomy (7/40). The 30 days analysis confirmed this discrepancy, most of which possibly explained with the higher rate of reoperations after lavage. During the following 12 months of follow-up, the incidence of the composite endpoint including major morbidity and mortality revealed no significant differences between approaches. Although the mean operating time was shorter for laparoscopic lavage, the length of postoperative hospital stay was not significantly different. Furthermore, the rate of recurrence was higher among patients treated with lavage (20%) compared to sigmoidectomy (2%).

The largest RCT available, SCANDIV, by Schultz and colleagues³⁹ aimed to compare the outcomes of laparoscopic lavage versus colon resection for a follow-up of 90 days. Considering all the patients with perforated diverticulitis, the results showed no significant differences in mortality (14% in the lavage group vs. 12% in the resection group) nor in severe postoperative complications (31% vs. 26%). However, regarding the target population without faeculent peritonitis, the reintervention rate was significantly higher after lavage (20%) than after resection (6%). Furthermore, the resection group had a much higher number of patients with stoma (43/62). In 2017, Schultz and his team⁴³ revealed the one-year results in which neither mortality nor severe complications were significantly different. An identical percentage of patients needed a secondary operation, including stoma reversals, however, more patients in the lavage group required unplanned reintervention (27% vs. 10%) probably in consequence of more episodes of diverticulitis recurrence (12% vs. 1%). Still, the proportion of patients with a stoma in the resection group was significantly higher (9/65 vs. 26/62). Being so, the authors concluded that laparoscopic lavage did not reduce mortality or severe morbidity and may lead to higher risk of recurrence and early reintervention. These risks though, must be balanced with the disadvantages of resection, including the

possibility of an invasive procedure and the formation of a long-term stoma.

Health economic evaluation

Two trials were the target of economic analyses^{44,45} with the goal of assessing the costs of laparoscopic peritoneal lavage versus resection procedures. The lavage results proved that this technique has an advantage over resection showing significant lower costs with mean differences per patient ranging from –8983€ to –19794€ according to Gehrman and –3513€ as said by Vennix.

Discussion

During the last decades, the advent of minimal invasive methods and the improvement of laparoscopic lavage brought the possibility of managing acute diverticulitis with purulent peritonitis without the need for laparotomy or colostomy and the consequent stoma reversal. The proposed advantages included less deaths and complications related to the procedure as well as fewer wound and stoma complications while maintaining the intestinal continuity.

The first single cohort observational studies^{19,24–26} showed very favorable results, with very low mortality and morbidity as well as high success rates. The following studies reinforced this trend, with promising results in controlling the infection.^{27,29–31,33–35} Nevertheless, some studies^{20,28} reported higher rates of morbidity and unplanned reintervention most likely related to the fact that some patients experienced ongoing sepsis.

When comparing laparoscopic lavage with resection techniques, all non-randomized studies individually showed very low mortality rates with no remarkable differences between procedures. While Liang²¹ showed a significant decrease in postoperative morbidity in the lavage group, Karoui³⁷ and Catry²³ could not find the same outcomes. Oppositely, Catry showed significant higher rates of abdominal complications after lavage. Nonresection of the diseased colon is expected to expose the patients to an increased risk of recurrent diverticulitis in the affected segment. Nonetheless, only three of the included non-randomized studies had sufficient length of follow-up to assess the magnitude of this risk, what doesn't seem enough to extract conclusions.

Another relevant aspect is that although lavage groups reached encouraging successful rates in controlling sepsis, a high percentage of patients were proposed for elective colon resection. Although the authors are not clear on the reasons of performing such procedure, this might be explained as a means to prevent later recurrence or as a source control technique.

Concerning the included RCTs, we extracted mixed results. While Dilala³⁸ seemed to consider laparoscopic lavage a safe and effective procedure, with no notable differences between lavage and resection, except for significantly better results regarding the reoperation rate within 12 months,⁴¹ the other two RCTs weren't so optimistic. The LOLA arm of the Ladies trial⁴⁰ was prematurely ceased due to an increased number of adverse events in the lavage group. Despite these findings,

there were no remarkable differences in the results although the outcomes in the resection group tended to be better. Also, oppositely to Dilala, Scandiv^{39,43} authors concluded that laparoscopic lavage did not reduce mortality or severe morbidity and could lead to higher risk of recurrence and early reintervention. Generally, lavage didn't prove to be more effective than resection, yet it was a safe alternative with comparable outcomes.

Overall, laparoscopic lavage presented with significantly shorter operative time which is a clear advantage as it minimizes the added physiological stress of prolonged anesthesia and operation in a patient with acute abdomen. Also, the length of hospital stay was significantly shorter, in almost all of the included studies, benefiting both patients and the healthcare system.

One thing to watch out for while opting for the laparoscopic lavage is the risk of leaving behind a perforated tumor in situ. This way, all patients treated with lavage should undergo routine colonoscopy to exclude malignancy.

Whereas nonresection exposes the patient to some risk of recurrence, the magnitude of this risk may not justify urgent resection. We believe that the occasional persistent sepsis after laparoscopic lavage can be dealt with ease in most of the cases. This is supported by the fact that, in the studies that showed significantly high early reoperation rates, the mortality and morbidity did not present with the equivalent increase. This inability to demonstrate a statistically important difference is highly relevant: being able to achieve the same outcomes with a less aggressive procedure challenges the need of a resection, a more traumatic surgery.

Beyond this, one of the major proposed advantages is the avoidance of a stoma. Stomas are correlated with reduced quality of life and require further surgery to reverse, with relevant morbidity and mortality associated.

Taking in consideration the need to balance the pros and cons of both lavage and resection, we believe that laparoscopic peritoneal lavage can be applied as a damage control operation capable of containing the inflammation process and ultimately acting as a bridge to elective resection with primary anastomosis. Nonetheless, this minimally invasive approach may be enough in some cases. Either way, patients would be spared the high morbidity associated with the stoma and the classic 2 stage traumatic surgery.

At this point, it is important to mention some limitations that might compromise the results of the included studies and, consequently, our conclusions. Firstly, there is a limited number of available articles on this subject with differences in the intervention methodology. This may result in suboptimal lavage for some participants contributing to poorer outcomes. Another pertinent weakness is the small number of participants in each study, sometimes with different Hinchey grades in addition to III, what can threaten the external validity of the findings. Also, to date, there are only three randomized controlled trials and the great majority of the literature reveals single cohort and retrospective studies.

Some may consider the inclusion of nonrandomized studies as a flaw. However, these represent a relevant source of evidence for a topic still little explored and we believe that it strengthened our review. Another feature that adds value to this study is the large bibliographic search conducted which

resulted in more included articles after careful selection, compared with existing reviews.

After this review, there are two aspects that we think need improvement. Firstly, we noted that the defined outcomes and the length of follow-ups among the available literature are too disparate. We consider it relevant to define a set of outcomes to ensure the uniform analysis and comparability of the results. Some of the pertinent outcomes we propose are: conversion rate, recurrence of diverticulitis, unplanned reintervention, mortality and morbidity, rate of elective resections (in the lavage groups) and rate of stoma reversion (in the resection group).

Furthermore, more investigation needs to be done to identify factors that might affect the success of laparoscopic lavage. So far, studies mention age, higher ASA grades, immunosuppression and higher Mannheim Peritonitis Index as possible candidates.

Conclusion

Diverticulitis remains a common and impactful disease nowadays especially when it presents with generalized peritonitis. Laparoscopic peritoneal lavage has emerged as a suitable alternative to resection procedures in the management of purulent peritonitis.

In this review, this minimally invasive technique proved to be safe and comparatively effective, although not superior to resection, reaching mixed results.

We believe that laparoscopic peritoneal lavage can be applied as a damage control operation to contain the inflammation process or, if necessary, as a bridge to elective resection with primary anastomosis. This could spare patients the high morbidity associated with a traumatic emergency surgery and the formation of a stoma.

Nevertheless, more studies are needed to establish clear indications and to identify factors that might affect the success of laparoscopic lavage.

Conflicts of interest

The authors declare no conflicts of interest.

REFERENCES

1. West AB. The pathology of diverticulitis. *J Clin Gastroenterol.* 2008;42:1137–8.
2. Tursi A, Papa A, Danese S. Review article: the pathophysiology and medical management of diverticulosis and diverticular disease of the colon. *Aliment Pharmacol Ther.* 2015;42:664–84.
3. Weizman AV, Nguyen GC. Diverticular disease: epidemiology and management. *Canadian J Gastroenterol.* 2011;25:385–9.
4. Peppas G, Bliziotis IA, Oikonomaki D, Falagas ME. Outcomes after medical and surgical treatment of diverticulitis: a systematic review of the available evidence. *J Gastroenterol Hepatol.* 2007;22:1360–8.
5. Aune D, Sen A, Leitzmann MF, Norat T, Tonstad S, Vatten LJ. Body mass index and physical activity and the risk of diverticular disease: a systematic review and meta-analysis of prospective studies. *Eur J Nutr.* 2017;56:2423–38.

6. Kvasnovsky CL, Papagrigoriadis S, Bjarnason I. Increased diverticular complications with nonsteroidal anti-inflammatory drugs and other medications: a systematic review and meta-analysis. *Colorectal Dis.* 2014;16:189–96.
7. Rezapour M, Ali S, Stollman N. Diverticular disease: an update on pathogenesis and management. *Gut Liver.* 2018;12:125–32.
8. Unlu C, Daniels L, Vrouenraets BC, Boermeester MA. A systematic review of high-fibre dietary therapy in diverticular disease. *Int J Colorectal Dis.* 2012;27:419–27.
9. Bhucket TPSN. Diverticular disease of the colon. In: Feldman M, Friedman LS, Brandt LJ, editors. *Sleisenger and Fordtran's gastrointestinal and liver disease: pathophysiology, diagnosis, management.* 10th ed. Philadelphia: Elsevier; 2014.
10. Maconi G. Diagnosis of symptomatic uncomplicated diverticular disease and the role of Rifaximin in management. *Acta Biomed.* 2017;88:25–32.
11. Mutter D, Marescaux J. Appendicitis/diverticulitis: minimally invasive surgery. *Digestive Dis (Basel, Switzerland).* 2013;31:76–82.
12. Loffeld RJ. Long-term follow-up and development of diverticulitis in patients diagnosed with diverticulosis of the colon. *Int J Colorectal Dis.* 2016;31:15–7.
13. Hinchey EJ, Schaal PG, Richards GK. Treatment of perforated diverticular disease of the colon. *Adv Surg.* 1978;12:85–109.
14. Boermeester MA, Humes DJ, Velmahos GC, Soreide K. Contemporary review of risk-stratified management in acute uncomplicated and complicated diverticulitis. *World J Surg.* 2016;40:2537–45.
15. Andersen JC, Bundgaard L, Elbrond H, Laurberg S, Walker LR, Stovring J. Danish national guidelines for treatment of diverticular disease. *Danish Med J.* 2012;59:C4453.
16. Vermeulen J, Akkersdijk GP, Gosselink MP, Hop WC, Mannaerts GH, van der Harst E, et al. Outcome after emergency surgery for acute perforated diverticulitis in 200 cases. *Dig Surg.* 2007;24:361–6.
17. Salem L, Flum DR. Primary anastomosis or Hartmann's procedure for patients with diverticular peritonitis? A systematic review. *Dis Colon Rectum.* 2004;47:1953–64.
18. O'Sullivan GC, Murphy D, O'Brien MG, Ireland A. Laparoscopic management of generalized peritonitis due to perforated colonic diverticula. *Am J Surg.* 1996;171:432–4.
19. Myers E, Hurley M, O'Sullivan GC, Kavanagh D, Wilson I, Winter DC. Laparoscopic peritoneal lavage for generalized peritonitis due to perforated diverticulitis. *Br J Surg.* 2008;95:97–101.
20. Parisi A, Gemini A, Desiderio J, Petrina A, Trastulli S, Grassi V, et al. Laparoscopic peritoneal lavage: our experience and review of the literature. *Wideochir Inne Tech Maloinwazyjne.* 2016;11:83–7.
21. Liang S, Russek K, Franklin ME Jr. Damage control strategy for the management of perforated diverticulitis with generalized peritonitis: laparoscopic lavage and drainage vs. laparoscopic Hartmann's procedure. *Surg Endosc.* 2012;26:2835–42.
22. Gentile V, Ferrarese A, Marola S, Surace A, Borello A, Ferrara Y, et al. Perioperative and postoperative outcomes of perforated diverticulitis Hinchey II and III: open Hartmann's procedure vs. laparoscopic lavage and drainage in the elderly. *Int J Surg.* 2014;12 Suppl. 2:S86–9.
23. Catry J, Brouquet A, Peschard F, Vychnevskaja K, Abdalla S, Malafosse R, et al. Sigmoid resection with primary anastomosis and ileostomy versus laparoscopic lavage in purulent peritonitis from perforated diverticulitis: outcome analysis in a prospective cohort of 40 consecutive patients. *Int J Colorectal Dis.* 2016;31:1693–9.
24. Franklin ME Jr, Portillo G, Trevino JM, Gonzalez JJ, Glass JL. Long-term experience with the laparoscopic approach to perforated diverticulitis plus generalized peritonitis. *World J Surg.* 2008;32:1507–11.
25. Taylor CJ, Layani L, Ghusn MA, White SI. Perforated diverticulitis managed by laparoscopic lavage. *ANZ J Surg.* 2006;76:962–5.
26. Lam HD, Tinton N, Cambier E, Navez B. Laparoscopic treatment in acute complicated diverticulitis: a review of 11 cases. *Acta Chir Belg.* 2009;109:56–60.
27. Swank HA, Mulder IM, Hoofwijk AG, Nienhuijs SW, Lange JF, Bemelman WA, et al. Early experience with laparoscopic lavage for perforated diverticulitis. *Br J Surg.* 2013;100:704–10.
28. Sneiders D, Lambrichts DPV, Swank HA, Blanken-Peeters C, Nienhuijs SW, Govaert M, et al. Long-term follow-up of a multicentre cohort study on laparoscopic peritoneal lavage for perforated diverticulitis. *Colorectal Dis.* 2019;21:705–14.
29. Rossi GL, Mentz R, Bertone S, Ojea Quintana G, Bilbao S, Im VM, et al. Laparoscopic peritoneal lavage for Hinchey III diverticulitis: is it as effective as it is applicable? *Dis Colon Rectum.* 2014;57:1384–90.
30. Sorrentino M, Brizzolari M, Scarpa E, Malisan D, Bruschi F, Bertozzi S, et al. Laparoscopic peritoneal lavage for perforated colonic diverticulitis: a definitive treatment? Retrospective analysis of 63 cases. *Tech Coloproctol.* 2015;19:105–10.
31. Rade F, Bretagnol F, Auguste M, Di Guisto C, Hutten N, de Calan L. Determinants of outcome following laparoscopic peritoneal lavage for perforated diverticulitis. *Br J Surg.* 2014;101:1602–6, discussion 6.
32. Horesh N, Zbar AP, Nevler A, Haim N, Gutman M, Zmora O. Early experience with laparoscopic lavage in acute complicated diverticulitis. *Dig Surg.* 2015;32:108–11.
33. Escalante GR, Bustamante-Lopez L, Lizcano A, Acosta MB. Peritoneal lavage in complicated acute diverticulitis. *J Clin Gastroenterol.* 2016;50:S83–5.
34. Greilsamer T, Abet E, Meurette G, Comy M, Hamy A, Lehur PA, et al. Is the failure of laparoscopic peritoneal lavage predictable in hinchey III diverticulitis management? *Dis Colon Rectum.* 2017;60:965–70.
35. Binda GA, Bonino MA, Siri G, Di Saverio S, Rossi G, Nascimbeni R, et al. Multicentre international trial of laparoscopic lavage for Hinchey III acute diverticulitis (LLO Study). *Br J Surg.* 2018;105:1835–43.
36. Boselli C, Gemini A, Cirocchi R, Grassi V, Avenia S, Polistena A, et al. Is it safe and useful, laparoscopic peritoneal lavage in the treatment of acute diverticulitis of octogenarian patients? A multicenter retrospective observational study. *Aging Clin Exp Res.* 2017;29 Suppl. 1:83–9.
37. Karoui M, Champault A, Pautrat K, Valleur P, Cherqui D, Champault G. Laparoscopic peritoneal lavage or primary anastomosis with defunctioning stoma for Hinchey 3 complicated diverticulitis: results of a comparative study. *Dis Colon Rectum.* 2009;52:609–15.
38. Angenete E, Thornell A, Burcharth J, Pommergaard HC, Skullman S, Bisgaard T, et al. Laparoscopic lavage is feasible and safe for the treatment of perforated diverticulitis with purulent peritonitis: the first results from the randomized controlled trial DILALA. *Ann Surg.* 2016;263:117–22.
39. Schultz JK, Yaqub S, Wallon C, Blecic L, Forsmo HM, Folkesson J, et al. Laparoscopic lavage vs primary resection for acute perforated diverticulitis: the SCANDIV randomized clinical trial. *JAMA.* 2015;314:1364–75.
40. Vennix S, Musters GD, Mulder IM, Swank HA, Consten EC, Belgers EH, et al. Laparoscopic peritoneal lavage or sigmoidectomy for perforated diverticulitis with purulent peritonitis: a multicentre, parallel-group, randomised, open-label trial. *Lancet.* 2015;386:1269–77.
41. Thornell A, Angenete E, Bisgaard T, Bock D, Burcharth J, Heath J, et al. Laparoscopic lavage for perforated diverticulitis with purulent peritonitis: a randomized trial. *Ann Intern Med.* 2016;164:137–45.

42. Kohl A, Rosenberg J, Bock D, Bisgaard T, Skullman S, Thornell A, et al. Two-year results of the randomized clinical trial DILALA comparing laparoscopic lavage with resection as treatment for perforated diverticulitis. *Br J Surg.* 2018;105:1128-34.
43. Schultz JK, Wallon C, Blecic L, Forsmo HM, Folkesson J, Buchwald P, et al. One-year results of the SCANDIV randomized clinical trial of laparoscopic lavage versus primary resection for acute perforated diverticulitis. *Br J Surg.* 2017;104:1382-92.
44. Gehrman J, Angenete E, Bjorholt I, Bock D, Rosenberg J, Haglind E. Health economic analysis of laparoscopic lavage versus Hartmann's procedure for diverticulitis in the randomized DILALA trial. *Br J Surg.* 2016;103:1539-47.
45. Vennix S, van Dieren S, Opmeer BC, Lange JF, Bemelman WA. Cost analysis of laparoscopic lavage compared with sigmoid resection for perforated diverticulitis in the Ladies trial. *Br J Surg.* 2017;104:62-8.