









# *Streptococcus gallolyticus* Bacteremia Detected in Apheresis Platelets and Its Link to Colonic Neoplasms

Francisco Costa Beber Lemanski<sup>1</sup>  Anna Laura Duro Barp<sup>1</sup>  Gabriela Kohl Hammacher<sup>1</sup>   
Martina Estacia Da Cas<sup>1</sup>  Cristine Moratelli Wink<sup>2</sup>  Ana Paula dos Santos Voloski<sup>2</sup>   
Adriano Pasqualotti<sup>3</sup>  Cristiane da Silva Rodrigues de Araújo<sup>1,2,3</sup> 

<sup>1</sup> Faculty of Medicine, Universidade de Passo Fundo (UPF), Passo Fundo, RS, Brazil

<sup>2</sup> Hemotherapy Department, Hospital São Vicente de Paulo (HSVP), Passo Fundo, RS, Brazil

<sup>3</sup> Graduate Program in Human Aging, Faculty of Physical Education and Physiotherapy, Universidade de Passo Fundo (UPF), Passo Fundo, RS, Brazil

**Address for correspondence** Francisco Costa Beber Lemanski, Faculdade de Medicina, Universidade de Passo Fundo, Passo Fundo, Rio Grande do Sul, Brazil (e-mail: franlemanski@hotmail.com).

J Coloproctol 2022;42(3):273–276.

## Abstract

**Introduction** *Streptococcus gallolyticus* belongs to the *Streptococcus bovis* complex, and it is a common bacterium colonizing the gastrointestinal tract. Its presence in the blood may suggest an underlying pathology such as a colonic neoplasm. We report herein a case of *S. bovis* bacteremia in an apheresis platelet donor, review similar cases in the literature, and suggest a flowchart for the management of similar cases in other blood donation centers.

**Case Presentation** A 61-year-old subject presented to a Hemotherapy Service to make an apheresis platelet donation. On quality control testing, *S. gallolyticus* was identified in hemoculture, and the donor was called back for follow-up. At first, a new hemoculture was requested, and the patient was referred to the outpatient department of infectious diseases to further investigate pathologies associated with *S. gallolyticus*. A subsequent colonoscopy investigation evidenced a polypoid structure in the ascending colon. Pathology reported the resected specimen as a low-grade tubular adenoma.

**Conclusion** Isolation of *S. bovis* in blood products requires further investigation and should be managed with precision by Hemotherapy Services. A standard protocol for the management of asymptomatic patients with *S. bovis* positive hemoculture, with the requests of a new blood culture, a colonoscopy, and an echocardiogram is crucial, as it may ensure early diagnosis and reduce morbidity and mortality.

## Keywords

- ▶ *Streptococcus gallolyticus*
- ▶ *Streptococcus bovis*
- ▶ colonic neoplasm
- ▶ colorectal cancer
- ▶ apheresis

received  
May 9, 2022  
accepted after revision  
June 7, 2022  
published online  
July 20, 2022

DOI <https://doi.org/10.1055/s-0042-1754384>.  
ISSN 2237-9363.

© 2022. Sociedade Brasileira de Coloproctologia. All rights reserved.

This is an open access article published by Thieme under the terms of the Creative Commons Attribution-NonDerivative-NonCommercial-License, permitting copying and reproduction so long as the original work is given appropriate credit. Contents may not be used for commercial purposes, or adapted, remixed, transformed or built upon. (<https://creativecommons.org/licenses/by-nc-nd/4.0/>)

Thieme Revinter Publicações Ltda., Rua do Matoso 170, Rio de Janeiro, RJ, CEP 20270-135, Brazil

## Introduction

*Streptococcus gallolyticus* ssp. *gallolyticus* (formerly known as *Streptococcus bovis* type I) is a subspecies of the bacterial complex *S. bovis* found in the microbiota of the gastrointestinal tract in ~ 2.5% to 15% of healthy individuals. However, its presence in the blood is not usual, and it indicates a pathological process.<sup>1</sup> Several studies point to its correlation with infectious endocarditis and colonic neoplasms. In addition, when an active infection by the bacteria is identified, the attending physician is responsible for a proper investigation to identify pathologies related to this microorganism.

We herein report a case of *S. bovis* bacteremia detected on a patient after an apheresis platelet donation which took place in a tertiary hospital in Southern Brazil, perform a literature review of similar cases, and suggest a flowchart for the management of this condition.

## Case Report

A 61-year-old male subject attended a Hemotherapy Service in January 2019 to make a voluntary apheresis platelet donation. On the day after, (~ 24 hours later) a closed-system sample was collected for quality control testing of the platelet sample, which consists of microbiological evaluation, platelet count, residual leukocyte count, and pH determination. Bacterial growth was observed both in aerobic and anaerobic bottles in the bacterial screening by the microbial detection system BACT/ALERT (bioMérieux SA, Marcy-l'Étoile, France). The bottles were then sent to our supporting laboratory for identification, and *S. gallolyticus* was isolated. After bacterial growth was observed, the blood component was immediately withdrawn from stock and a new sample was collected for a new culture, which also turned out positive. After that, the blood component was discarded, and the donor was called to return to the service for investigation.

Upon consultation, the donor was asymptomatic. He had made a whole blood donation in 2012 and red cell apheresis donations in 2016 and 2018, with no disturbances. The family history was positive for colon adenocarcinoma: his father, at 84 years old, had undergone curative treatment. He did not have a personal history of neoplasia and had never had a colonoscopy. At first, a new hemoculture was requested, and the donor was referred to the outpatient department of infectious diseases to investigate pathologies associated with *S. gallolyticus* infection.

In July 2019, the patient presented to the Hemotherapy Service for follow-up. Still asymptomatic, his new hemoculture came out negative for *S. gallolyticus*, and he was waiting for an appointment with the infectologist. In November 2019, the donor was called back for a consultation and a colonoscopy was requested, given the patient's known risk factors for colonic malignancies. The colonoscopy findings were of an 8-mm pedunculated polyp in the ascending colon, which was removed by electrocautery snare, and two wide stalk pedunculated polyps in the descending colon measuring

10 mm and 12 mm. The pathology report of the resected specimen showed low-grade tubular adenoma.

The patient herein reported gave his informed consent prior to inclusion in the study.

## Discussion

*Streptococcus bovis* is a Gram-positive bacterium that belongs to group D *streptococci*. Currently, based on DNA studies, *S. bovis* is a complex comprising seven subspecies of bacteria. The most significant ones are *S. gallolyticus* ssp. *gallolyticus* (previously *S. bovis* type I), *S. infantarius* ssp. *infantarius* (previously *S. bovis* type II/1), *S. gallolyticus* ssp. *pasteurianus* (previously *S. bovis* type II/2) and *S. gallolyticus* ssp. *macedonicus*.<sup>2,3</sup> In humans, *S. bovis* acts as a commensal bacterium colonizing the colon.<sup>1,4</sup> Studies<sup>1</sup> estimate that the prevalence of *S. bovis* in healthy human feces ranges from 5% to 60%.

Its presence in the blood is unusual and is correlated with hepatobiliary diseases, endocarditis, and colorectal lesions. Subtypes of *S. bovis* have already been related to the pathogenesis of some diseases: type-I bacteremia is mostly related to endocarditis and colorectal cancer (CRC), whereas the type-II subspecies are frequent in patients with hepatobiliary diseases.<sup>1,2,5</sup> Once the *S. bovis* complex is detected in the blood, the differentiation into subspecies must be performed because of its epidemiology.

We herein report a case of *S. bovis* bacteremia detected on a voluntary donor in an apheresis platelet sample. Platelet components have a much higher rate of bacterial contamination than any other blood component due to their storage at room temperature, although the *S. bovis* complex is not a regular cause of contamination in platelet units.<sup>7</sup> Possible sources of contamination in blood products include donor bacteremia, contamination during the blood collection procedure, contamination of collection bags, and contamination during processing and storage of blood products. Potential contamination of the platelet substrate through the equipment or the patient's skin is substantially reduced, since the collection of platelets by apheresis is performed with sterile and disposable materials, and adequate antisepsis is performed before all procedures. Therefore, when bacterial culture growth was detected in the donor sample, the service initiated an investigation of the donor, considering that the donor's bloodstream was the apparent source of the contamination of the platelet sample.

Although the pathomechanism is still to be fully uncovered, the link between *S. bovis* bacteremia and colonic malignancy has been strongly established in the last years, and *S. gallolyticus* ssp. *gallolyticus* seems to be particularly involved in the process. The most expressive evidence in the literature is regarding *S. bovis* infections such as infective endocarditis or bacteremia as having an etiological role in advanced intestinal polyps and CRC.<sup>7,8</sup> However, it is not clear yet if the pathogen can promote the development of colon carcinoma or if the malignant lesion provides both a microenvironment and a pathway for the bacteria to grow and migrate into the bloodstream.<sup>7</sup> Boleij et al.<sup>9</sup> and Jans and

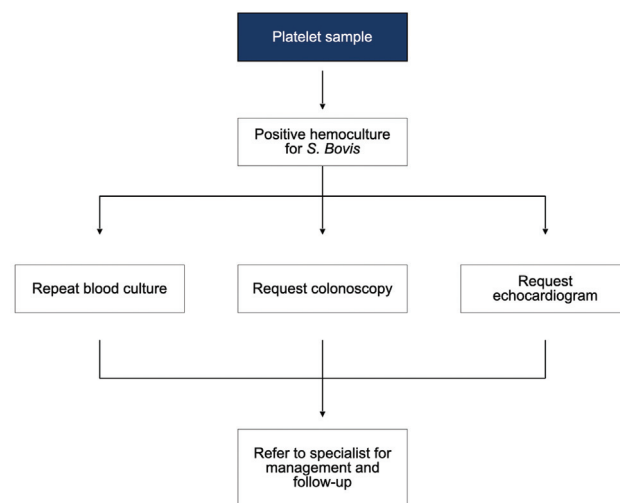
Bolej<sup>10</sup> conducted meta-analyses that indicated a steady association between patients infected with *S. bovis* and colonic neoplasia. The median percentage of patients who had neoplasia was of 60%, and was higher for adenomas (43%) than for carcinomas (18%), but still largely exceeding the disease rate reported in the general asymptomatic population. This could point to *S. bovis* infection being associated with premalignant colonic lesions.

With increasing awareness of the association between fecal microbiota dysbiosis and the development of CRC, research was conducted, and the prevalence of *S. bovis* has been described to range from 15% to 62% in the gastrointestinal tract of healthy individuals.<sup>7,8</sup> Despite that, Boltin et al.<sup>11</sup> were unable to find an association between colonic carriage of *S. bovis* and an increased risk of developing colon carcinoma in a long prospective study. Aware of these contradictions and others conflicting results, in 2015, Pasquereau-Kotula et al.<sup>7</sup> suggested *S. bovis* is “both a passenger and a cancer-promoting bacteria”; therefore, the pathogen is an auxiliary factor that accelerates the development of CRC.

In 2011, Lin C. et al.<sup>12</sup> reported a case of a 51-year-old male donor identified with *S. bovis* bacteremia in an apheresis platelet donation. Once the bacteria were isolated, an investigation was performed, and there were no other particularities on the physical or blood examinations. The fecal occult blood test was negative, and the level of carcinogenic antigen was within normal limits. Later, a colonoscopy revealed a colonic neoplasm, and a biopsy revealed the diagnosis of invasive adenocarcinoma. In 2014, Le Niger et al.<sup>13</sup> published an analysis of a case of an 80-year-old female with an asymptomatic rectal tumor that was discovered because of a platelet concentrate infected with *S. gallolyticus*. In this case, the patient only discovered the tumor because the Hemotherapy Service was aware of the correlation between platelet contamination and CRC and requested further investigation with colonoscopy.

Chang et al.<sup>14</sup> published a case in which *S. bovis* infection was identified in the donor after a patient went into septic shock due to the contaminated platelet transfusion. After the episode, they recommended that the patient perform a colonoscopy, in which a benign polyp was found and removed.<sup>14</sup> Haimowitz et al.<sup>15</sup> published a case report of a regular platelet donor who had a donated platelet sample that cultured positive for *S. bovis*. The woman was also asymptomatic and underwent a colonoscopy after the episode, which showed a mass with 3 cm in diameter in the sigmoid colon.

In addition to these reports, a retrospective study<sup>16</sup> published in 2013 followed blood donors for 14 years and detected *S. bovis* bacteremia in 16 of them (1 in 110,800 donations). From this group, eight underwent colonoscopy and, as a result, two patients were diagnosed with colonic carcinomas and four, with adenomas. The authors<sup>16</sup> also recommend donor follow-up once *S. bovis* bacteremia is detected. Moreover, data from the American Red Cross<sup>17</sup> showed that *S. bovis* contamination was detected in 14 apheresis platelet donations between 2004 and 2008. In this group, colonic cancer was found in four of the patients



**Fig. 1** After identification of *S. bovis* in blood culture, we suggest requesting a new hemoculture to assess the persistence of the pathogen in the blood, a colonoscopy, and an echocardiogram to investigate the presence of polyps in the intestine and infectious endocarditis, respectively. Finally, referral to an infectologist or gastroenterologist for follow-up.

and colonic polyps, in another four.<sup>17</sup> Therefore, the importance of investigating the gastrointestinal tract becomes evident, due to the great relationship between bacteremia by *S. bovis* and intestinal tumor lesions.

In **Fig. 1**, we present a flowchart for the management of *S. bovis*-positive platelet samples in our Hemotherapy Service as the association of *S. gallolyticus* with premalignant lesions and colorectal carcinoma is already well established in the literature. After the identification of bacteremia by *S. gallolyticus*, it is necessary to investigate organic damage related to these bacteria, mainly at the colonic level.<sup>18</sup> The diagnosis of CRC is made by colonoscopy, which offers direct visualization and detection of a colonic polyp (early stage) or advanced neoplasia, followed by biopsy of the changes for histopathological analysis.<sup>19</sup> Given this relationship, investigation for intestinal changes – with colonoscopy – in patients with serum contamination by *S. gallolyticus*, identified in blood control at the Hemotherapy Service, is paramount, as an early diagnosis and intervention reduce the risk of morbidity and mortality due to CRC.<sup>20</sup>

In the context of blood-transfusion safety, identifying the microorganism involved is imperative to determine the most likely origin of the bacteremia, since the relationship involving *S. bovis*, infective endocarditis, and CRC is well established. Thus, screening for colorectal neoplasia with colonoscopy when *S. gallolyticus* is isolated in blood culture is essential, since early diagnosis reduces morbidity and mortality in CRC. We herein emphasize the need for a Hemotherapy Service to have a standard protocol for the management of these patients, requesting a new blood culture, a colonoscopy, and an echocardiogram.

#### Availability of Data and Material

The data regarding the case presentation is available from the corresponding author upon reasonable request. All

the literature data analyzed has been included in the present published article.

**Code Availability**  
Not applicable.

#### Authors' Contributions

All authors contributed to the conception and design of the study. Material preparation and data collection and analysis were performed by Francisco Costa Beber Lemanski, Anna Laura Duro Barp, and Gabriela Kohl Hammacher. The first draft of the manuscript was written by Francisco Costa Beber Lemanski, Anna Laura Duro Barp, Gabriela Kohl Hammacher, Martina Estacia da Cas, Ana Paula dos Santos Voloski, and Cristine Moratelli Wink, and all authors commented on previous versions of the manuscript. Supervision was performed by Cristiane da Silva Rodrigues de Araújo and Adriano Pasqualotti. All authors read and approved the final manuscript.

#### Ethics Approval

All procedures involving human participants were performed in accordance with the ethical standards of the institutional and/or national research committee and with the 1964 Helsinki Declaration and its later amendments or comparable ethical standards. The present study was approved by the Committee for Ethics in Research (CEP) of Hospital São Vicente de Paulo (No. 4.237.941).

#### Consent to Participate

Informed consent was obtained from the participant included in the study.

#### Consent for Publication

The participant has consented to the submission of the case report to the journal.

#### Funding

All equipment used in this research are property of the Hemotherapy Service of Hospital São Vicente de Paulo. The authors did not receive support from any organization for the submitted work.

#### Conflict of Interests

The authors have no conflict of interests to declare. All authors certify that they have no affiliations with or involvement in any organization or entity with any financial interest or non-financial interest in the subject matter or materials discussed in this manuscript.

#### References

- Jans C, Boleij A. The Road to Infection: Host-Microbe Interactions Defining the Pathogenicity of *Streptococcus bovis*/*Streptococcus equinus* Complex Members. *Front Microbiol* 2018;9:603
- Ben-Chetrit E, Wiener-Well Y, Kashat L, Yinnon AM, Assous MV. *Streptococcus bovis* new taxonomy: does subspecies distinction matter? *Eur J Clin Microbiol Infect Dis* 2017;36(02):387–393
- Kaindi DWM, Kogi-Makau W, Lule GN, et al. Colorectal cancer-associated *Streptococcus infantarius* subsp. *infantarius* differ from a major dairy lineage providing evidence for pathogenic, pathobiont and food-grade lineages. *Sci Rep* 2018;8(01):9181
- Jans C, Meile L, Lacroix C, Stevens MJ. Genomics, evolution, and molecular epidemiology of the *Streptococcus bovis*/*Streptococcus equinus* complex (SBSEC). *Infect Genet Evol* 2015;33:419–436
- Corredoira J, Grau I, Garcia-Rodriguez JF, et al. The clinical epidemiology and malignancies associated with *Streptococcus bovis* biotypes in 506 cases of bloodstream infections. *J Infect* 2015;71(03):317–325
- White SK, Schmidt RL, Walker BS, Metcalf RA. Bacterial contamination rate of platelet components by primary culture: a systematic review and meta-analysis. *Transfusion* 2020;60(05):986–996
- Pasquereau-Kotula E, Martins M, Aymeric L, Dramsi S. Significance of *Streptococcus gallolyticus* subsp. *gallolyticus* association with colorectal cancer. *Front Microbiol* 2018;9(APR):614
- Murinello A, Ho C, Tavares P, et al. *Streptococcus Gallolyticus* Bacteraemia associated with colonic adenomatous polyps. *J Port Gastroenterologia*. 2006;13(03):152–158
- Boleij A, van Gelder MMHJ, Swinkels DW, Tjalsma H. Clinical Importance of *Streptococcus gallolyticus* infection among colorectal cancer patients: systematic review and meta-analysis. *Clin Infect Dis* 2011;53(09):870–878
- Jans C, Boleij A. The Road to Infection: Host-Microbe Interactions Defining the Pathogenicity of *Streptococcus bovis*/*Streptococcus equinus* Complex Members. *Front Microbiol* 2018;9:603
- Boltin D, Goldberg E, Bugaevsky O, et al. Colonic carriage of *Streptococcus bovis* and colorectal neoplasia: a prospective 17-year longitudinal case-control study. *Eur J Gastroenterol Hepatol* 2015;27(12):1449–1453
- Lin CY, Tseng SB, Lu PL, et al. Isolation of *Streptococcus bovis* from apheresis platelets of asymptomatic donor warranted colonoscopy investigation: case report and literature review. *Transfusion* 2011;51(09):2023–2027
- Le Niger C, Dalbies F, Narbonne V, et al. Infection bactérienne à *Streptococcus gallolyticus* transmise par transfusion d'un concentré de plaquettes : à propos d'un cas. [Transfusion-transmitted bacterial infection of a apheresis platelet concentrate with *Streptococcus gallolyticus*: Analysis of one case] *Transfus Clin Biol* 2014;21(03):107–110
- Chang AH, Kirsch CM, Mobashery N, Johnson N, Levitt LJ. *Streptococcus bovis* septic shock due to contaminated transfused platelets. *Am J Hematol* 2004;77(03):282–286
- Haimowitz MD, Hernandez LA, Herron RM Jr. A blood donor with bacteraemia. *Lancet* 2005;365(9470):1596
- Lee CK, Chan HM, Ho PL, et al. Long-term clinical outcomes after *Streptococcus bovis* isolation in asymptomatic blood donors in Hong Kong. *Transfusion* 2013;53(10):2207–2210
- Eder AF, Goldman M. How do I investigate septic transfusion reactions and blood donors with culture-positive platelet donations? *Transfusion* 2011;51(08):1662–1668
- Wong HK, Ho PL, Lee CK. *Streptococcus gallolyticus* Bacteremia and Colorectal Carcinoma. *Gastroenterology* 2019;156(01):291–292
- Dekker E, Tanis PJ, Vleugels JLA, Kasi PM, Wallace MB. Colorectal cancer. *Lancet* 2019;394(10207):1467–1480
- Issa IA, Nouredine M. Colorectal cancer screening: An updated review of the available options. *World J Gastroenterol* 2017;23(28):5086–5096