

# EVA brace for treatment of congenital clubfoot in newborns

Cecília Maria Bezerra Freire Campos<sup>a</sup> , Raweny Thayna Gomes dos Santos<sup>b</sup> ,  
Norrara Scarlytt de Oliveira Holanda<sup>b</sup> , Pedro Henrique Silva de Farias<sup>a</sup> ,  
Silvana Alves Pereira<sup>c</sup> 

<sup>a</sup>Hospital Universitário Ana Bezerra – HUAB, Empresa Brasileira de Serviços Hospitalares – EBSEERH, Santa Cruz, RN, Brasil.

<sup>b</sup>Universidade Federal do Rio Grande do Norte – UFRN, Santa Cruz, RN, Brasil.

<sup>c</sup>Departamento de Fisioterapia, Universidade Federal do Rio Grande do Norte – UFRN, Natal, RN, Brasil.

**Abstract:** Introduction: Congenital clubfoot (CC) is an orthopedic deformity characterized by congenital dysplasia of musculoskeletal structures such as muscles, tendons, ligaments, osteoarticular and neurovascular structures, of multifactorial and idiopathic origin. Objective: Offer early intervention for the treatment of congenital clubfoot in newborns, using ethyl vinyl acetate (EVA) to produce braces in the neonatal period. Method: Intervention was performed in newborns of both sexes, with gestational age >37 weeks, diagnosed with flexible congenital clubfoot. The braces were manufactured with 4 mm-thick EVA, Velcro and hot glue, using flat irons and scissors. Results: Fifteen newborns were included in the study, with bilateral CC and 32 braces. An average of 20 cm<sup>2</sup> of EVA was used for each brace and none of the newborns developed pressure sores. Braces were worn initially for 18 hours and no family member expressed any complaint or difficulty in handling the device at home, reporting complete satisfaction. After 60 days of treatment, all the infants in the follow-up achieved a score of 0 on the Pirani scale, but were monitored for a further 30 days because they did not exhibit symmetrical feet. Multivariate analysis revealed differences between assessments ( $p = 0.001$ ), and in pair comparison, only a score of 30 after 60 days was similar ( $p = 0.45$ ). Conclusion: Rapid intervention, performed by a qualified professional using EVA braces, proved to be effective for conservative treatment of CC in newborns.

**Keywords:** *Orthotic Devices, Talipes/Congenital, Infant, Newborn.*

## Órteses de EVA no tratamento para pé torto congênito em recém-nascidos

**Resumo:** Introdução: Pé torto congênito (PTC) é uma deformidade ortopédica caracterizada por uma displasia congênita das estruturas musculoesqueléticas como músculos, tendões, ligamentos, estruturas osteoarticulares e neurovasculares, de origem multifatorial e causa idiopática. Objetivo: Oferecer intervenção precoce no tratamento de pé torto congênito de recém-nascidos e apresentar o uso de Etil Vinil Acetato (EVA) como um material para produção de órteses ainda no período neonatal. Método: Foi realizada intervenção em recém-nascidos de idade gestacional >37 semanas, de ambos os sexos, diagnosticados com pé torto congênito flexível. As órteses foram desenvolvidas com EVA de espessura 4 mm, velcro e cola quente, utilizando-se prancha de cabelo e tesoura para confecção. Resultados: Foram incluídos 15 neonatos no estudo, com PTC bilateral. Para cada confecção de órtese foi usado em média 20 cm<sup>2</sup> de EVA e nenhum recém-nascido evoluiu com úlcera de pressão. As órteses foram mantidas por 18 horas inicialmente e nenhuma família apresentou qualquer queixa ou dificuldade em manipular o material em casa, relatando integral satisfação. Aos 60 dias de tratamento, todos os bebês em acompanhamento alcançaram

**Corresponding author:** Silvana Alves Pereira, Departamento de Fisioterapia, Universidade Federal do Rio Grande do Norte, Av. Sen. Salgado Filho, 3000, Candelária, CEP 59064-741, Natal, RN, Brasil, e-mail: apsilvana@gmail.com

Received on Mar. 25, 2019; 1<sup>st</sup> Revision on May 23, 2019; 2<sup>nd</sup> Revision on June 18, 2019; Accepted on June 26, 2019.



a pontuação 0 pela escala de Pirani, entretanto, por não apresentarem simetria dos pés, foram acompanhados por mais 30 dias. Na análise multivariada, observaram-se diferenças entre as avaliações ( $p = 0,001$ ), e na comparação de pares, apenas a pontuação dos 30 com 60 dias, foram semelhantes ( $p = 0,45$ ). Conclusão: A rápida intervenção, realizada por profissional habilitado, utilizando-se órteses confeccionadas com EVA, mostrou-se eficaz para o tratamento conservador do PTC em recém-nascidos.

**Palavras-chave:** *Órtese, Pé Torto/Congênito, Recém-Nascido.*

## 1 Introduction

Congenital clubfoot (CC), also known as talipes equinovarus, is an orthopedic deformity characterized by congenital dysplasia of the musculoskeletal structures such as muscles, tendons, ligaments, osteoarticular and neurovascular structures, of multifactorial and idiopathic origin (MARANHO; VOLPON, 2011).

Its incidence in Brazil is one in every 1000 live births, with a 2:1 predominance for boys, occurring bilaterally in 50% of the cases (MARANHO; VOLPON, 2011). Northeastern Brazil has recently experienced an increase in CC cases. According to the Department of Informatics of the National Health System (DATASUS), 4,104 CC surgeries were performed between 2013 and 2017, as well as 195 surgery reviews (BRASIL, 2019).

In Maceió between 2002 and 2003, CC was the most frequent anomaly found in a prospective survey of 2,500 newborns in public, private and philanthropic hospitals (PEREIRA et al., 2008). Another more recent investigation was conducted at a teaching hospital located in the hinterland of Northeastern Brazil (CAMPOS, 2017). In this study, the authors reported nine cases of CC for every 1000 live births. One relevant finding is that the newborns were born around the same time, representing a similar gestation period.

The literature describes different conservative and surgical treatments to correct CC, carried out by a multidisciplinary team and initiated during the neonatal period, which provides high response potential because of the good ligament elasticity and articular capsules and tendons that are still being stabilized during this period (CHUEIRE et al., 2016; CURY et al., 2015; MARANHO; VOLPON, 2011).

The use of braces during the neonatal period has been little studied in the literature, and there is still no consensus regarding the best material to use (CAVALCANTI; GALVÃO, 2007). Characteristics such as stiffness, flexibility, volume, cleaning, ease of handling, acquisition cost, resistance to heat and antiallergic properties should be considered

during this selection (AGNELLI; TOYODA, 2003; GRADIM; PAIVA, 2018).

In 2014, a group of researchers in Southeastern Brazil produced an upper limb brace using EVA and other simple, low-cost materials. The authors obtained satisfactory results with EVA, at a cost of BRL15.00, or approximately USD3.50 (CALCHI; CORRÊA; VENTURA, 2014).

Given the plasticity and fragility of the newborn's musculoskeletal system and the need to invest in braces made of simple, low-cost materials, this study aimed to present an intervention for the early treatment of congenital clubfoot of newborns, suggesting EVA as an available material for the production of braces in the neonatal period.

## 2 Method

This is a quasi-experimental interventional study, conducted at the Rehabilitation Unit of a Maternity School in Rio Grande do Norte state, Brazil. In compliance with Resolution 466/12, all the mothers or legal guardians gave written informed consent.

A study was conducted with a non-random sample of newborns of both sexes, with gestational age >37 weeks, born in the hospital and diagnosed with flexible, non-teratogenic CC, degree  $\neq$  zero according to the Pirani scale, on at least one side, recruited during the first 72 hours of life.

Newborns with other neurological, traumatic or degenerative malformations were excluded from the study. Patient recruitment occurred by active search or referral by the multiprofessional team between March and September 2017. All the newborns recruited were assessed for inclusion criteria and informed of the aims of the study and procedures to be performed.

Congenital clubfoot was classified according to the protocol described by Chaweerat et al. (2014). The protocol involves evaluating the degree of foot mobility based on equinovarus reducibility, adduction and supination (CHAWEERAT et al., 2014).

The degree of stiffness was numerically quantified using the Pirani scale, which is based on six clinical

signs that quantify the degree of stiffness from the signs in two regions, the forefoot and hindfoot. The score varies from 0 to 6 and the higher the score, the worse the foot deformity (JAQUETO et al., 2016). When the score was  $\neq 0$ , and the foot flexible to passive mobilization, it was recommended that the newborns receive outpatient care with the use of a brace.

The mold was removed to manufacture the brace, and delivery, instructions and outpatient referrals were made in the first three days of life (while in the maternity ward) by the same occupational therapist. The braces were constructed individually by the occupational therapist, using 4 mm EVA, flat irons, scissors, Velcro and hot glue (Figure 1).

The braces were initially worn for approximately 18 hours a day. In this phase, the parents were instructed to remove the device only for cleaning while the newborn was being bathed. After 15 days, the brace was worn for 12 hours a day, preferably while the child was sleeping, and after 30 days, only at night between six and eight hours daily.

Reassessments were conducted at the Rehabilitation Outpatient facility after 15 days in the first month and monthly thereafter for 3 months. The newborn

was discharged when foot symmetry and a score of 0 on the Pirani scale was achieved, in addition to the absence of complaints from the parents or guardians. All the families were contacted by telephone one week before the meeting to establish the date and place of the assessment.

All the reassessments were carried out by the occupational therapist and photographed. The parents or guardians were instructed on the care and handling of the braces and asked to report their degree of satisfaction with the treatment. Instructions were standardized with recommendations regarding time of daily use, cleaning and maintaining skin integrity (use of  $\frac{3}{4}$  socks, if necessary).

Satisfaction was investigated using narrative interviews of the parents' experiences with brace care (CURY et al., 2006; PERUZZOLO; BARBOSA; SOUZA, 2018). Three questions were asked randomly during the interview ("Describe putting on and taking off the device at home?" "What do you think of him/her using the device?", "Do you see any change in foot position? If so, show it to me here").

The data were tabulated in the IBM SPSS statistical program, version 20 and analysis of variance for repeated measures was used to compare the Pirani scores. Variables were considered non-similar at  $p < 0.05$ .

### 3 Results

A total of 1,543 births with gestational age  $>37$  weeks were recorded at the hospital during the study period, 17 of whom were recruited for functional diagnosis. Two of the newborns were excluded for not meeting the inclusion criteria, and referred to an orthopedist for treatment of severe rigid equinus and abnormally tight Achilles tendon not correctable by passive mobilization.

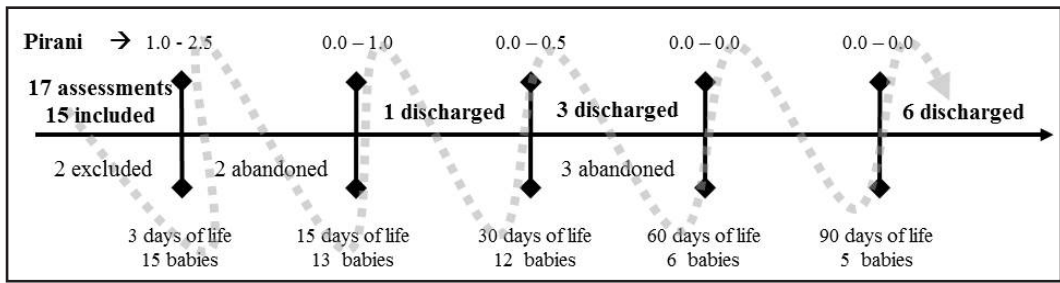
All 15 newborns included in the study exhibited bilateral CC, 65% were boys, 10 achieved a score of 0 on the Pirani scale and were discharged and five discontinued treatment. The five families that interrupted treatment did so because of improved CC position and did not return for reassessment. Figure 2 depicts the treatment flowchart.

After 60 days of treatment, all the babies achieved a score of 0 on the Pirani scale; however, they were monitored for a further 30 days since they did not exhibit foot symmetry.

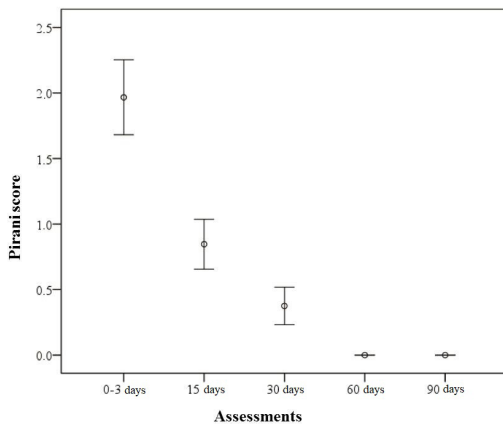
Variations in measures and the confidence interval (95% CI) of the Pirani score of all the assessments are shown in Figure 3. Multivariate analysis demonstrated differences between assessments ( $p = 0.001$ ), and in



**Figure 1.** Model of the brace developed in the study. All the devices were manufactured individually from a mold created by the occupational therapist, using 4 mm-thick EVA, flat irons, scissors, Velcro and hot glue.



**Figure 2.** Treatment flowchart during the 90-day follow-up. The grey dotted line represents the chronological order of treatment. The vertical bars denote the time of assessments, with a description of the minimum and maximum scores on the Pirani scale (upper part of the vertical bar) and the number of babies treated (lower part of the vertical bar). The number of newborns excluded, discharged and/or who discontinued treatment are presented in chronological order on the horizontal bar.



**Figure 3.** Variations in measures and the confidence interval (95% CI) of the Pirani scores of all assessments (0-3 days; 15 days; 30 days, 60 days and 90 days) ( $p = 0.001$ ). Repeated measures ANOVA.

pair comparison, only the score of 30 after 60 days was similar ( $p = 0.45$ ). In this analysis, comparison between 60 and 90 days was excluded, since all the babies had achieved a score of 0 on the Pirani scale.

An average of 20 cm<sup>2</sup> of EVA was used for each brace. None of the newborns developed pressure sores, none of the families complained of difficulty putting on or removing the device at home, and all were 100% satisfied with the results and use of the EVA brace.

### 4 Discussion

The newborns that received early intervention for congenital clubfoot improved only with conservative treatment. All the families were satisfied with the use of EVA when asked about the appearance of their newborn’s foot, corroborating

the results of Kumar, Suman and Manjhi (2017) and Kulambi et al. (2017)

These authors consider the conservative treatment a positive method for resolving the deformity and report that parents were satisfied with the appearance of their newborn’s foot. Both describe the evolution of CC in pediatric patients after conservative treatment and serial plaster casting.

Serial casting is widely indicated for the conservative treatment of CC in newborns and older children (SILVA et al., 2014; AGNELLI; TOYODA, 2003; RADLER; MINDLER, 2016; BOECHAT et al., 2012). However, the fact that it is a rigid bandage underscores the need for care in the neonatal period. In newborns, rigid immobilization can cause a decrease in strength, loss of flexibility and/or atrophy (BOECHAT et al., 2012; SU; NAN, 2014).

Corroborating these findings and reinforcing the indication of lighter braces, Su and Nan (2014) demonstrated that immobilizing newborns in the conservative treatment of CC can be achieved by more flexible devices. Su and Nan (2014) attached a Velcro strap above the newborn’s knee as a therapeutic strategy. The authors treated 56 feet and 52 achieved normal appearance within 3 to 6 months of treatment. In line with our results, none of the patients treated with the brace was referred for tenotomy. Some of the newborns in our study exhibited normal foot appearance after 15 days and after 3 months, 100% were discharged due to a reduction in deformity.

It seems that strong, lightweight noninvasive tools, such as that used here, are very promising in the conservative treatment of CC in the neonatal

phase (BOECHAT et al., 2012; SU; NAN, 2014). During this phase of life, handling objects, exploring the environment and relating with people are essential tasks for developing autonomy (SANTANA; BRAGA, 2012).

The selection of materials to manufacture braces should consider aspects such as strength, flexibility, durability and weight, especially when used in newborns, given the fragility of their skin and their low endurance (VIEIRA; PEREIRA, 2007; SILVA et al., 2015; AGNELLI; TOYODA, 2003; CARO et al., 2014).

The aim of using the EVA brace was to favor these activities, since the material allows movement of the limbs and exploration of the environment. However, despite the fact that the EVA brace demonstrates satisfactory results in resolving the deformity and satisfying parents, the abandonment rate was high, hindering outpatient follow-up. This limitation requires new follow-up strategies to favor treatment continuity. An important strategy may be empowering parents to care for their child diagnosed with CC.

Family empowerment and the close proximity between them and the newborn is a strong factor in development, lowers anxiety and insecurity levels, in addition to raising self-efficacy and emotional attachment (REYNOLDS et al., 2013; PERUZZOLO et al., 2015). Chaweerat et al. (2014) devised an empowerment strategy by comparing the evolution of the CC deformity in newborns passively immobilized by their parents at home.

Another relevant finding was the large number of cases. The frequency of CC was 11/1000 births, corroborating the findings of two other studies, also conducted in Northeastern Brazil (CAMPOS, 2017; PEREIRA et al., 2008).

The northeastern region exhibits a greater trend to consanguineous relationships, high number of pregnancies and low incidence of prenatal care, thereby increasing the risk of developing congenital anomalies (CANALS CIFUENTES; CAVADA; NAZER, 2014; VLAHOV et al., 2007). Family planning and health education, population orientation, reduced maternal age, vaccination programs, and control of abortion-inducing drugs are public policies and economic measures that could change the distribution of congenital anomalies (FONTOURA; CARDOSO, 2014; SANTOS et al., 2016; GRADIM; PAIVA, 2018).

## 5 Conclusion

Rapid intervention by a qualified professional using EVA braces proved to be a powerful resource in the conservative treatment of CC in newborns.

## References

- AGNELLI, L. B.; TOYODA, C. Y. Estudo de materiais para confecção de órtese e sua utilização prática por terapeutas ocupacionais no Brasil. *Cadernos de Terapia Ocupacional da UFSCar*, São Carlos, v. 11, n. 2, p. 1-12, 2003.
- BOECHAT, J. C. S. et al. A síndrome do imobilismo e seus efeitos sobre o aparelho locomotor do idoso. *Revista Científica Internacional InterSciencePlace*, Campos dos Goytacazes, v. 1, n. 22, p. 89-193, 2012.
- BRASIL. Departamento de Informática do SUS – DATASUS. *Procedimentos Hospitalares do SUS: banco de dados*. Brasília, 2019.
- CALCHI, A. M.; CORRÊA, G. H. G.; VENTURA, F. C. Desenvolvimento de órtese de membros superiores com baixo custo visando uma melhoria de vida dos pacientes da apae-jaú. In: ENCONTRO CIENTÍFICO DO GEPRO, 4., 2014, Jaú. *Anais... Jaú: Gepro*, 2014. p. 1-10.
- CAMPOS, C. M. B. F. Órteses de EVA no tratamento para Pé Torto Congênito em RN: relato de experiência da terapia ocupacional no HUAB. In: SIMPÓSIO CIENTÍFICO DO HOSPITAL UNIVERSITÁRIO ANA BEZERRA, 1., 2017, Santa Cruz. *Anais... Santa Cruz: Hospital Universitário Ana Bezerra*, 2017.
- CANALS CIFUENTES, C. A.; CAVADA, C. G.; NAZER, H. J. Identification of risk factors for congenital malformations. *Revista Médica de Chile*, Santiago, v. 142, n. 11, p. 1431-1439, 2014. PMID:25694289.
- CARO, C. C. et al. A dispensação de órteses, próteses e meios auxiliares de locomoção (OPM) no Departamento Regional de Saúde da 3ª Região do Estado de São Paulo. *Cadernos de Terapia Ocupacional da UFSCar*, São Carlos, v. 22, n. 3, p. 521-529, 2014. <http://dx.doi.org/10.4322/cto.2014.073>.
- CAVALCANTI, A.; GALVÃO, C. *Terapia ocupacional: fundamentação e prática*. Rio de Janeiro: Guanabara Koogan, 2007.
- CHAWEERAT, R. et al. The effectiveness of parent manipulation on newborns with postural clubfoot: a randomized controlled Trial. *Journal of the Medical Association of Thailand*, Bangkok, v. 97, n. 9, p. 68-72, 2014. Supplement 9. PMID:25365893.
- CHUEIRE, A. J. F. G. et al. Tratamento do pé torto congênito pelo método de Ponseti. *Revista Brasileira de Ortopedia*, São Paulo, v. 51, n. 3, p. 313-318,

2016. <http://dx.doi.org/10.1016/j.rbo.2015.06.005>. PMID:27274485.
- CURY, L. A. et al. Análise da eficácia do tratamento pelo método de ponseti no pé torto congênito idiopático. *Revista da Faculdade de Ciências Médicas de Sorocaba*, Sorocaba, v. 17, n. 1, p. 33-36, 2015.
- CURY, V. C. R. et al. Efeitos do uso de órtese na mobilidade funcional de crianças com paralisia cerebral. *Brazilian Journal of Physical Therapy*, São Carlos, v. 10, n. 1, p. 67-74, 2006. <http://dx.doi.org/10.1590/S1413-3552006000100009>.
- FONTOURA, F. C.; CARDOSO, M. V. L. M. L. Associação das malformações congênitas com variáveis neonatais e maternas em unidades neonatais numa cidade do nordeste brasileiro. *Texto & Contexto - Enfermagem*, Florianópolis, v. 23, n. 4, p. 907-914, 2014. <http://dx.doi.org/10.1590/0104-07072014002320013>.
- GRADIM, L. C. C.; PAIVA, G. Modelos de órteses para membros superiores: uma revisão da literatura. *Cadernos Brasileiros de Terapia Ocupacional*, São Carlos, v. 26, n. 2, p. 479-488, 2018. <http://dx.doi.org/10.4322/2526-8910.ctoAR1174>.
- JAQUETO, P. A. et al. Resultados funcionais e clínicos alcançados em pacientes com pé torto congênito tratados pela técnica de Ponseti. *Revista Brasileira de Ortopedia*, São Paulo, v. 51, n. 6, p. 657-661, 2016. <http://dx.doi.org/10.1016/j.rbo.2015.11.006>. PMID:28050536.
- KULAMBI, V. et al. Treatment of idiopathic clubfoot by Ponseti method: a prospective evaluation. *International Journal of Research in Orthopaedics*, Karnataka, v. 3, n. 4, p. 1-5, 2017. <http://dx.doi.org/10.18203/issn.2455-4510.IntJResOrtho20172876>.
- KUMAR, R.; SUMAN, S. K.; MANJHI, L. B. Evaluation of outcome of treatment of idiopathic clubfoot by ponseti technique of manipulation and serial plaster casting. *International Journal of Orthopaedics Sciences*, Jharkhand, v. 3, n. 4, p. 23-27, 2017. <http://dx.doi.org/10.22271/ortho.2017.v3.i4a.05>.
- MARANHO, D. A.; VOLPON, J. B. Pé torto congênito. *Acta Ortopédica Brasileira*, São Paulo, v. 19, n. 3, p. 163-169, 2011. <http://dx.doi.org/10.1590/S1413-78522011000300010>.
- PEREIRA, R. J. S. et al. Frequência de malformações congênitas das extremidades em recém-nascidos. *Revista Brasileira de Crescimento e Desenvolvimento Humano*, São Paulo, v. 18, n. 2, p. 155-162, 2008. <http://dx.doi.org/10.7322/jhgd.19877>.
- PERUZZOLO, D. L. et al. Contribuições à clínica da terapia ocupacional na área da intervenção precoce em equipe interdisciplinar. *Cadernos de Terapia Ocupacional da UFSCar*, São Carlos, v. 23, n. 2, p. 295-303, 2015. <http://dx.doi.org/10.4322/0104-4931.ctoAO0515>.
- PERUZZOLO, D. L.; BARBOSA, D. M.; SOUZA, A. P. R. Terapia ocupacional e o tratamento de bebês em intervenção precoce a partir de uma Hipótese de Funcionamento Psicomotor: estudo de caso único. *Cadernos Brasileiros de Terapia Ocupacional*, São Carlos, v. 26, n. 2, p. 409-421, 2018. <http://dx.doi.org/10.4322/2526-8910.ctoAO1155>.
- RADLER, C.; MINDLER, G. T. *Kindlicher Klumpfuß Rezidivbehandlung*. Viena: Spital Speising GmbH, 2016.
- REYNOLDS, L. C. et al. Parental presence and holding in the neonatal intensive care unit and associations with early neurobehavior. *Journal of Perinatology*, Philadelphia, v. 33, n. 8, p. 636-641, 2013. <http://dx.doi.org/10.1038/jp.2013.4>. PMID:23412640.
- SANTANA, M. F.; BRAGA, A. P. M. Utilização de órteses de porcelana fria para a realização no ato de brincar da criança com déficit motor. *Revista Brasileira em Promoção da Saúde*, Fortaleza, v. 25, n. 2, p. 51-61, 2012. <http://dx.doi.org/10.5020/18061230.2012.s51>.
- SANTOS, J. L. G. et al. Zika virus and measures of legal interventions in public health. *Journal of Human Growth and Development*, São Paulo, v. 26, n. 3, p. 393-397, 2016. <http://dx.doi.org/10.7322/jhgd.122919>.
- SILVA, A. P. et al. Método TherapyTaping®: bandagem elástica como recurso terapêutico na clínica fonoaudiológica. *Distúrbios da Comunicação*, São Paulo, v. 6, n. 4, p. 805-808, 2014.
- SILVA, D. O. et al. Caracterização das órteses utilizadas por crianças com paralisia cerebral atendidas no centro de reabilitação física em Cascavel-PR. *Revista de Atenção à Saúde*, São Caetano do Sul, v. 13, n. 43, p. 18-22, 2015.
- SU, Y.; NAN, G. Manipulation and brace fixing for the treatment of congenital clubfoot in newborns and infants. *BMC Musculoskeletal Disorders*, London, v. 15, n. 1, p. 363-367, 2014. <http://dx.doi.org/10.1186/1471-2474-15-363>. PMID:25361737.
- VIEIRA, A. P. S.; PEREIRA, M. N. F. *Utilização de órteses no setor de Saúde da Criança e do Adolescente da Clínica de Fisioterapia da Universidade São Francisco*. 2007. 47 f. Monografia (Graduação em Fisioterapia) – Universidade São Francisco, Bragança Paulista, 2007.
- VLAHOV, D. et al. Urban as a determinant of health. *Journal of Urban Health*, Cary, v. 84, n. 3, p. 16-26, 2007. Supplement 1. <http://dx.doi.org/10.1007/s11524-007-9169-3>. PMID:17356903.

---

### **Author's Contributions**

Cecília Maria Bezerra Freire Campos, Raweny Thayna Gomes dos Santos, Norrara Scarlytt de Oliveira Holanda, Pedro Henrique Silva de Farias and Silvana Alves Pereira contributed equally to writing the manuscript. All authors approved the final version of the text.

### **Funding Source**

Office of the Vice-President of Graduate Studies of the Federal University of Rio Grande do Norte and Ana Bezerra University Hospital (EBSERH/UFRN).