



## Original article

# Fluorodeoxyglucose-positron emission tomography staging can replace bone marrow biopsy in Hodgkin's lymphoma. Results from Brazilian Hodgkin's Lymphoma Study Group



Juliano Júlio Cerci<sup>a,\*</sup>, Mateos Bogoni<sup>a</sup>, Valeria Buccheri<sup>b</sup>,  
Elba Cristina Sá de Camargo Etchebehere<sup>c</sup>, Talita Maira Bueno da Silveira<sup>d</sup>,  
Otavio Baiocchi<sup>e</sup>, Carlos de Araujo Cunha Pereira Neto<sup>a</sup>, Marcelo Tatit Sapienza<sup>b</sup>,  
Jose Flavio Gomes Marin<sup>d</sup>, José Cláudio Meneghetti<sup>f</sup>, Yana Novis<sup>c</sup>,  
Carmino Antonio de Souza<sup>g</sup>, Carlos Chiattoni<sup>d</sup>, Marcia Torresan<sup>g</sup>, Celso Dario Ramos<sup>g</sup>

<sup>a</sup> Quanta Diagnóstico e Terapia, Curitiba, PR, Brazil

<sup>b</sup> Universidade de São Paulo (USP), Instituto do Câncer do Estado de São Paulo (ICESP), São Paulo, SP, Brazil

<sup>c</sup> Hospital Sírio Libanês, São Paulo, SP, Brazil

<sup>d</sup> Hospital Samaritano, São Paulo, SP, Brazil

<sup>e</sup> Universidade Federal de São Paulo (Unifesp), São Paulo, SP, Brazil

<sup>f</sup> Universidade de São Paulo (USP), Hospital das Clínicas (HC), Instituto do Coração (InCor), São Paulo, SP, Brazil

<sup>g</sup> Universidade Estadual de Campinas (Unicamp), Campinas, SP, Brazil

## ARTICLE INFO

## Article history:

Received 24 January 2018

Accepted 6 March 2018

Available online 24 April 2018

## Keywords:

Hodgkin's lymphoma

FDG-PET

Positron-emission tomography

Bone marrow biopsy

Lymphoma staging

## ABSTRACT

**Objective:** To investigate, in a large prospective multicenter study, whether 2-[18F]-fluoro-2-deoxy-D-glucose-positron emission tomography is sufficiently accurate to identify clinically important bone marrow involvement by Hodgkin's lymphoma to replace routine bone marrow biopsy in a developing tropical country.

**Methods:** Patients newly diagnosed with Hodgkin's lymphoma were recruited from six cancer centers in Brazil. All were staged by the results of positron emission tomography/computed tomography that were centrally reviewed and by iliac crest bone marrow biopsy. Patients were classified as having marrow disease if they had lymphoma identified by marrow biopsy histology or had focal 2-[18F]-fluoro-2-deoxy-D-glucose marrow uptake that resolved following chemotherapy.

**Results:** A total of 246 participants were recruited from six different centers and 62 (25.2%) were judged to have Hodgkin's lymphoma in the bone marrow. Positron emission tomography and biopsies were concordant in 206 patients (83%). Positron emission tomography correctly identified marrow disease in 59/62 patients (95.1%) and marrow biopsy in 25/62 patients (40.3%). In 22/62 (35.4%) patients, the two techniques were concordant in the diagnosis of marrow involvement. Of the forty discordant results, positron emission tomography

\* Corresponding author at: Quanta Diagnóstico e Terapia, Rua Almirante Tamandaré, 1000, Alto da XV, Curitiba, CEP: 80045-170, PR, Brazil.  
E-mail address: [cercijuliano@hotmail.com](mailto:cercijuliano@hotmail.com) (J.J. Cerci).

<https://doi.org/10.1016/j.htct.2018.03.002>

2531-1379/© 2018 Associação Brasileira de Hematologia, Hemoterapia e Terapia Celular. Published by Elsevier Editora Ltda. This is an open access article under the CC BY-NC-ND license (<http://creativecommons.org/licenses/by-nc-nd/4.0/>).

found bone marrow involvement in 37 patients, upstaging 22 to stage IV and having an impact on therapeutic decision in nine cases given their reallocation from early to advanced stage. Three false negative positron emission tomography results were obtained with bone marrow biopsy giving positive findings. All three cases were classified as stage IV regardless of bone marrow findings implying no modification in the clinical management. The sensitivity, specificity and accuracy of positron emission tomography for detecting bone marrow disease were 95%, 100% and 98% and for bone marrow biopsy they were 40%, 100% and 84%, respectively.

**Conclusion:** We conclude that positron emission tomography can replace marrow biopsy in Brazilian patients with Hodgkin's lymphoma without compromising clinical management.

© 2018 Associação Brasileira de Hematologia, Hemoterapia e Terapia Celular. Published by Elsevier Editora Ltda. This is an open access article under the CC BY-NC-ND license (<http://creativecommons.org/licenses/by-nc-nd/4.0/>).

## Introduction

In the last decades, positron emission tomography (PET) with 2-[18F]-fluoro-2-deoxy-D-glucose (FDG) has become the established modality for staging Hodgkin's lymphoma (HL), and international guidelines for its use in lymphomas were harmonized in recent years.<sup>1–4</sup>

Defining prognosis has been a cornerstone of patient management and trial design in HL. In addition, bone marrow biopsy (BMB) has been standard in HL staging, although it is often performed even when the likelihood of involvement is low. Patients with early-stage disease rarely have bone marrow involvement in the absence of a suggestive FDG-PET finding, and those with advanced-stage disease rarely have bone marrow involvement in the absence of disease-related symptoms or other evidence of advanced-stage disease. Different studies have suggested that if a PET/computed tomography (CT) is performed, the need for BMB is questionable in the evaluation of patients with HL.<sup>5–7</sup> However, substantial data is not found in the literature about this issue in patients from developing countries, where disease presentation tends to be more advanced at diagnosis,<sup>8</sup> potentially increasing the incidence of marrow involvement. Furthermore, those countries generally have an elevated prevalence of chronic infectious diseases that could theoretically increase the rate of false positive PET results.<sup>9–11</sup>

This study is part of a Brazilian collaborative project, supported by the Brazilian Society of Nuclear Medicine (SBMN) and the Brazilian Association of Hematology, Hemotherapy and Cellular Therapy (ABHH), to investigate applications of PET/CT in the evaluation of HL patients. Here we evaluate the utility of FDG-PET to detect bone marrow involvement in comparison with BMB as part of initial diagnostic staging of patients with HL in six centers.

## Methods

Patients were recruited from six major Brazilian cancer centers: Quanta Diagnóstico e Terapia, Instituto do Câncer do Estado de São Paulo (ICESP), Hospital Sírio Libanês, Hospital Samaritano, Universidade Federal de São Paulo (UNIFESP)

and Universidade Estadual de Campinas (Unicamp). The study received Research Ethics Committee approval in all participating institutions and written informed consent was obtained from study participants.

### Diagnosis and staging

Diagnosis of de novo HL was made by biopsy of sites of primary lymph node or extranodal disease. Under 18-year-old and pregnant patients were excluded. All patients were staged by unilateral BMB and by FDG-PET/CT scans. Bone marrow from the iliac crest was biopsied and assessed by a local senior hematopathologist.

Whole-body FDG-PET/CT imaging was acquired following standard protocols regarding uptake time (60–90 min) after the intravenous administration of 296–444 MBq (8–12 mCi) of FDG with a maximum interval of 14 days between BMB and PET scanning. Scanners were calibrated and images scaled for reading according to local protocols. Staging scans were performed prior to treatment.

FDG-PET/CT was classified as negative for bone marrow involvement in the absence of any focal area of increased bone marrow uptake or in the presence of diffuse bone marrow uptake. FDG-PET/CT was considered positive in the presence of focal FDG uptake regardless of diffuse uptake.

### Quality control

PET scans were centrally reviewed by two nuclear medicine physicians (JJC, CACPN). For the purpose of this study, all scans having abnormal FDG-uptake in bone marrow recorded in the database were examined to confirm and classify the pattern of marrow involvement.

### Categorizing marrow disease and data analysis

Since histological examination of all sites is not possible, FDG-PET/CT and BMB results were combined in a reference standard in order to establish the diagnostic accuracy of the methods. Positive concordant findings at FDG-PET and BMB were interpreted as true positives. Concordant negative findings were interpreted as true absence of disease. In discordant cases with focal FDG uptake in marrow, resolution of the

**Table 1 – Clinical characteristics of the included patients (n = 246).**

Variable	n (%)
Males	121 (49.1)
B symptoms	176 (71.5)
Bulky disease	153 (62.1)
Staging	
I	5 (2.0)
II	85 (34.6)
III	42 (17.1)
IV	114 (46.3)

abnormal uptake in response to chemotherapy was taken as evidence of true marrow disease, even with no evidence of bone marrow involvement by histological analysis (biopsy findings in these cases were considered not representative, i.e., false negatives). FDG-PET with no apparent marrow disease was considered false negative in patients with a positive BMB.

### Statistical analysis

The diagnostic accuracies were analyzed in terms of sensitivity, specificity, positive predictive value (PPV), and negative predictive value (NPV). The Statistical Package for the Social Sciences (SPSS) version 10.0 for Windows (SPSS Inc., Chicago, IL) was used for the statistical analysis.

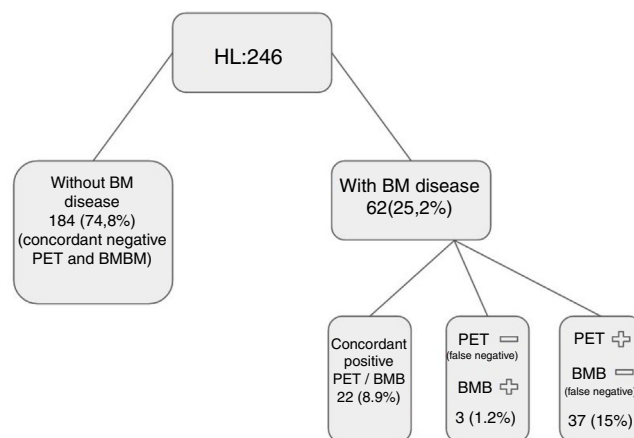
## Results

Overall, 246 patients with complete data available for evaluation were enrolled. One hundred and twenty-one patients were male (49%) with a median age of 33 years (interquartile range: 24–38).

The clinical characteristics of the 246 patients are presented in Table 1. The marrow was considered to be positive for lymphoma in 62 patients (25.2%). Patients were considered to have evidence of marrow disease (true positive), if lymphoma was identified histologically by BMB histology or had focal bone marrow FDG-uptake at PET that resolved following chemotherapy, irrespective of iliac crest histology. Based on this definition, PET correctly identified marrow disease in 59/62 patients (95.1%) and marrow biopsy in 25/62 patients (40.3%).

In 22/62 (35.4%) patients, PET scan and marrow biopsy were concordant for the diagnosis of marrow involvement and in 40 patients results were discordant (Figure 1).

All 37 patients with positive PET results and discordant marrow biopsy presented true bone marrow involvement given the resolution of the focal marrow FDG uptake areas following chemotherapy. As a result of PET performance, nine patients were upstaged from stage II to IV (hence, therapeutic decision was changed for this group), 13 were upstaged from stage III to IV, and 11 were already classified as stage IV prior to PET scanning. Three false negative PET results were found (after positive findings in BMB). In all three cases, patients were already classified as stage IV, thus the clinical decision was not changed.



**Figure 1 – positron emission tomography (PET)/computed tomography (CT) versus bone marrow biopsy (BMB): Patients were considered to have evidence of marrow disease (true positive) if lymphoma was identified histologically by BMB histology, or they had focal bone marrow 2-[18F]-fluoro-2-deoxy-D-glucose (FDG)-uptake at PET that resolved following chemotherapy, irrespective of iliac crest histology. Based on this definition, PET correctly identified marrow disease in 59/62 patients (95.1%), marrow biopsy in 25/62 patients (40.3%). In 22/62 (35.4%) patients, PET scan and BMB were concordant in the diagnosis of marrow involvement, and in 40 patients, results were discordant.**

**Table 2 – Overall sensitivity, specificity and accuracy comparing positron emission tomography (PET) with bone marrow biopsy (BMB) to detect bone marrow disease.**

	Variable – % (95% confidence interval)			
	Sensitivity	Specificity	PPV	NPV
PET	95 (0.85–0.98)	100 (0.97–1.0)	100 (0.92–1.0)	98 (0.95–0.99)
BMB	40 (0.28–0.53)	100 (0.97–1.0)	100 (0.83–1.0)	83 (0.77–0.87)

PPV: positive predictive value; NPV: negative predictive value.

Overall sensitivity, specificity and accuracy of PET for detecting bone marrow disease were 95%, 100% and 98% and for BMB they were 40%, 100% and 84%, respectively (Table 2).

## Discussion

This paper reports part of a collaborative project to examine the utility of PET scanning for staging HL in Brazilian patients. The overarching purpose was to assess whether published studies from Western Europe and USA comparing BMB and FDG-PET in Hodgkin's lymphoma<sup>5–8,12–14</sup> are generalizable to clinical practice in Brazil given the singularities of our country.

Although the exact rate of patients classified as having advanced stage disease nationwide due to their bone marrow status is unknown, Brazil presents a higher rate of advanced stage HL patients than other populations, thus, it also has a relatively greater number of eligible patients for

bone marrow disease assessment, given the higher incidence in advanced stage groups.<sup>15</sup> Furthermore, there is still a relatively high incidence of chronic infectious diseases in Brazil, such as tuberculosis, paracoccidioidomycosis, leishmaniasis, histoplasmosis, etc.,<sup>9,16-18</sup> that can potentially involve bone marrow and could increase the rate of false-positive results of FDG-PET.<sup>19</sup> In addition, the possibility of simultaneous occurrence of lymphoma and specific chronic infections has been reported.<sup>11,20</sup>

This report focuses on the comparison of PET and BMB to identify bone marrow involvement in patients with newly diagnosed HL.

### What we found

Based on information from both PET and BMB, 24% of cases were considered to have bone marrow involvement by HL. As reported by others, PET had greater sensitivity than BMB (PET 98% vs. BMB 40%) with the same specificity (100%). PET identified marrow disease not identified by BMB in 37/62 (59.6%) cases, which translated into upstaging patients to stage IV in 9% of the cohort.

### Comparison with other studies

In a metaanalysis involving five studies regarding PET bone marrow assessments in HL patients (with a total of 191 patients), Pakos et al.<sup>21</sup> reached independent estimates for sensitivity and specificity of 76% and 92%, respectively. In a similar, more recent metaanalysis, Adams et al.<sup>7</sup> reported pooled estimates of 96.9% and 99.7%, respectively. The results of this study were quite similar with sensitivity and specificity values for bone marrow disease detection by PET of 95% and 100%, respectively. Furthermore, concordant results between BMB and FDG-PET have been reported in the range of 70–80%,<sup>21,22</sup> also similar to the findings of this study in Brazil [206/246 (83%) concordant PET and marrow biopsy results]. It is interesting to point out the similar high specificity of FDG-PET in this study as in the mentioned metaanalyses although the prevalence of infectious diseases potentially affecting bone marrow is higher in Brazil than in developed countries. This can be explained by the low incidence of involvement of the bone marrow by tropical infectious diseases; reports of simultaneous lymphoma and tropical infections are anecdotal.<sup>11,20</sup> In addition, bone marrow involvement by these infections are more common in immunocompromised individuals, such as those co-infected with human immunodeficiency virus (HIV) or with allograft transplants<sup>16</sup>; these patients were not included in the current study.

### Clinical implications

The 1989 Cotswold modification of the Ann Arbor staging criteria abandoned the routine use of invasive procedures such as explorative laparotomy for HL staging, in the wake of improved imaging diagnosis with CT.<sup>23</sup> Routine BMB was restricted to patients with CT-assessed stage III/IV disease or stage II disease with adverse ‘unfavorable’ factors, and only then if a positive finding would alter the therapeutic conduct. Although very few patients with early stage HL have a positive BMB<sup>24,25</sup>

some guidelines still recommend the inclusion of BMB in the routine staging work-up of patients with newly diagnosed HL.<sup>26</sup> In the general practice, it is common to perform routine BMB for advanced stage HL due to the higher prevalence of bone marrow involvement, despite the fact that in advanced stage disease a positive BMB is much less likely to have a therapeutic impact than in early stage disease.<sup>27,28</sup> The reason to perform BMB is the possible impact on treatment strategy. The reasons not to perform BMB are: (1) it is an unpleasant procedure for the patient, (2) it may delay the initiation of chemotherapy and (3) cost, especially in less developed countries. On the basis of these results BMB would have had an impact on the treatment of only a single patient if staging was performed with CT only, but with PET/CT staging, BMB had no therapeutic impact on any of the 246 patients.<sup>29</sup> These results are also in line with a larger study presented recently by El-Galaly et al.<sup>13</sup> These authors reviewed the experience of three Danish institutions where both BMB and PET/CT have been performed routinely to stage all patients with HL for several years. The study included 392 patients with HL, including 202 patients with early stage disease and 190 patients with advanced stage disease (according to PET/CT-based staging). Not a single patient with early stage disease had a positive BMB. Four patients with advanced stage disease had positive BMB despite normal FDG uptake in the bones and marrow. However, the treatment strategy was unaffected in all four patients. Therefore, similar to what was observed in this study, BMB was performed on several HL patients without a single therapeutic consequence.

In Brazil, PET was introduced later in comparison to developed countries, mainly due to financial reasons. Regarding the workup for HL, even after promising results from the first international PET studies, it was only after strenuous verification of its local cost-effectiveness that PET started to be incorporated into Brazilian practice.<sup>8</sup> The present study corroborates the cost-effectiveness of FDG-PET in HL in Brazil. It demonstrates that, even in a tropical developing country with higher prevalences of advanced HL and infectious diseases, FDG-PET is accurate to identify clinically important bone marrow involvement by HL and can replace routine BMB in most cases. Staging BMB may be restricted to patients whose images or laboratory tests are suggestive of bone marrow involvement and in those with a potential change in treatment.

---

## Conclusions

Our experience with a large multicenter cohort of Brazilian HL patients further confirms the findings of other international studies that FDG-PET is a reliable method to evaluate bone marrow, including in developing countries. When PET/CT analysis is performed during the oncological workup, BMB does not increase the detection of bone marrow involvement with clinical significance and does not affect the therapeutic decision.

---

## Conflicts of interest

The authors declare no conflicts of interest.

## REFERENCES

1. Urba WJ, Longo DL. Hodgkin's disease. *New Engl J Med.* 1992;326(10):678–87.
2. Juweid ME, Stroobants S, Hoekstra OS, Mottaghy FM, Dietlein M, Guermazi A, et al. Use of positron emission tomography for response assessment of lymphoma: consensus recommendations of the Imaging Subcommittee of the International Harmonization Project in Lymphoma. *J Clin Oncol.* 2006;10(25):571–8.
3. Allen-Auerbach M, de Vos S, Czernin J. PET/computed tomography and lymphoma. *Radiol Clin North Am.* 2013;51(5):833–44.
4. Cheson BD. Role of functional imaging in the management of lymphoma. *J Clin Oncol.* 2011;29(14):1844–54.
5. Adams HJ, Kwee TC, Fijnheer R, Dubois SV, Nievelstein RA, de Klerk JM. Bone marrow FDG-PET/CT in Hodgkin lymphoma revisited: do imaging and pathology match? *Ann Nucl Med.* 2015;29(2):132–7.
6. The role of bone marrow biopsy and FDG-PET/CT in identifying bone marrow infiltration in the initial diagnosis of high grade non-Hodgkin B-cell lymphoma and Hodgkin lymphoma. Accuracy in a multicenter series of 372 patients. *Am J Hematol.* 2016;91(5):E300.
7. Adams HJ, Kwee TC, de Keizer B, Fijnheer R, de Klerk JM, Littooj AS, et al. Systematic review and meta-analysis on the diagnostic performance of FDG-PET/CT in detecting bone marrow involvement in newly diagnosed Hodgkin lymphoma: is bone marrow biopsy still necessary? *Ann Oncol.* 2014;25(5):921–7.
8. El-Galaly TC, d'Amore F, Mylam KJ, de Nully Brown P, Bøgsted M, Bukh A, et al. Routine bone marrow biopsy has little or no therapeutic consequence for positron emission tomography/computed tomography-staged treatment-naive patients with Hodgkin lymphoma. *J Clin Oncol.* 2012;30(36):4508–14.
9. Colombo TE, Soares MM, D'Ávila SC, Nogueira MC, de Almeida MT. Identification of fungal diseases at necropsy. *Pathol Res Pract.* 2012;208(9):549–52.
10. Yamamura M, Santos Neto M, Chiaravalloti Neto F, Arroyo LH, Ramos AC, de Queiroz AA, et al. Areas with evidence of equity and their progress on mortality from tuberculosis in an endemic municipality of southeast Brazil. *Infect Dis Poverty.* 2017;6(1):134.
11. Ruiz e Resende LS, Yasuda AG, Mendes RP, Marques SA, Niéro-Melo L, Defaveri J, et al. Paracoccidioidomycosis in patients with lymphoma and review of published literature. *Mycopathologia.* 2015;179(3–4):285–91.
12. Zwarthoed C, El-Galaly TC, Canepari M, Ouvrier MJ, Viotti J, Ettaiche M, et al. Prognostic value of bone marrow tracer uptake pattern in baseline PET scan in Hodgkin Lymphoma: results from an International Collaborative Study. *J Nucl Med.* 2017;58(8):1249–54.
13. El-Galaly TC, d'Amore F, Brown PdN, Christiansen I, Specht L, Loft A, et al. Routine bone marrow biopsy adds little diagnostic information in patients with newly diagnosed Hodgkin lymphoma undergoing PET/CT staging. *Blood.* 2011;118 Suppl. 1. Abstract 2627.
14. Puccini B, Nassi L, Minoia C, Volpetti S, Ciancia R, Riccomagno PC, Di Rocco A, et al. Fondazione Italiana Linfomi Postgraduate Master course. Role of bone marrow biopsy in staging of patients with classical Hodgkin's lymphoma undergoing positron emission tomography/computed tomography. *Ann Hematol.* 2017;96(7):1147–53.
15. Cerci JJ, Trindade E, Buccheri V, Fanti S, Coutinho AM, Zanoni L, et al. Consistency of FDG-PET accuracy and cost-effectiveness in initial staging of patients with Hodgkin lymphoma across jurisdictions. *Clin Lymphoma Myeloma Leuk.* 2011;11(4):314–20.
16. Ibrahim KY, Carvalho NB, Mimicos EV, Yeh-Li H, Sotto MN, França FO. Cutaneous and bone marrow histoplasmosis after 18 years of renal allograft transplant. *Mycopathologia.* 2014;178(3–4):273–8.
17. Hou S, Shen J, Tan J. Case report: multiple systemic disseminated tuberculosis mimicking lymphoma on 18F-FDG PET/CT. *Medicine (Baltimore).* 2017;96(29):e7248.
18. Resende LS, Mendes RP, Bacchi MM, Marques SA, Barraviera B, Souza LR, et al. Infiltrative myelopathy by paracoccidioidomycosis. A review and report of nine cases with emphasis on bone marrow morphology. *Histopathology.* 2006;48(4):377–86.
19. Clement PW, David Li K. Peripheral blood and bone marrow involvement by visceral leishmaniasis. *Blood.* 2017;130(5):692. PMID: 28775162.
20. Kaae J, Nørgaard P, Himmelstrup B. Visceral leishmaniasis diagnosed in a patient with MALT lymphoma. *Eur J Intern Med.* 2007;18(3):235–7.
21. Pakos EE, Fotopoulos AD, Ioannidis JP. 18F-FDG PET for evaluation of bone marrow infiltration in staging of lymphoma: a meta-analysis. *J Nucl Med.* 2005;46(6):958–63.
22. Hong J, Lee Y, Park Y, Kim SG, Hwang KH, Park SH, et al. Role of FDG-PET/CT in detecting lymphomatous bone marrow involvement in patients with newly diagnosed diffuse large B-cell lymphoma. *Ann Hematol.* 2012;91(5):687–95.
23. Lister TA, Crowther D, Sutcliffe SB, Glatstein E, Canellos GP, Young RC, et al. Report of a committee convened to discuss the evaluation and staging of patients with Hodgkin's disease: Cotswolds meeting. *J Clin Oncol.* 1989;7:1630–6.
24. Levis A, Pietrasanta D, Godio L, Vitolo U, Ciravegna G, Di Vito F, et al. A large-scale study of bone marrow involvement in patients with Hodgkin's lymphoma. *Clin Lymphoma.* 2004;5(1):50–5.
25. Howell SJ, Grey M, Chang J, Morgenstern GR, Cowan RA, Deakin DP, et al. The value of bone marrow examination in the staging of Hodgkin's lymphoma: a review of 955 cases seen in a regional cancer centre. *Br J Haematol.* 2002;119(2):408–11.
26. Engert A, Eichenauer DA, Dreyling M. Hodgkin's lymphoma: ESMO Clinical Practice Guidelines for diagnosis, treatment and follow-up. *Ann Oncol.* 2010;21 Suppl 5, v168-71.
27. Hasenclever D, Diehl V. A prognostic score for advanced Hodgkin's disease International prognostic factors project on advanced Hodgkin's disease. *N Engl J Med.* 1998;339(21):1506–14.
28. Adams HJA, Kwee TC. Assessing baseline bone marrow status in advanced-stage Hodgkin lymphoma: does it have any purpose? *Ann Hematol.* 2017;96(6):1047–8.
29. Richardson SE, Sudak J, Warbey V, Ramsay A, McNamara CJ. Routine bone marrow biopsy is not necessary in the staging of patients with classical Hodgkin lymphoma in the <sup>18</sup>F-fluoro-2-deoxyglucose positron emission tomography era. *Leuk Lymphoma.* 2012;53(3):381–5.